

# Laparoscopic Trachelectomy for Cervical Stump ‘Carcinoma *in situ*’

Rafique B Parkar, M A Hassan<sup>1</sup>, David Otieno<sup>2</sup>, Richard Baraza<sup>3</sup>

Consultant Obstetrician and Gynecologist, Specialist in Hysteroscopy and Laparoscopy, P.O. Box 520, Sarit Center, Nairobi, <sup>1</sup>Consultant Obstetrician and Gynecologist, P.O. Box 19821 - 00202, Nairobi, <sup>2</sup>Consultant Anesthetist, Nairobi, <sup>3</sup>Consultant Surgeon and Urologist, Nairobi, Kenya

## ABSTRACT

A 43-year-old, who underwent a subtotal hysterectomy for postpartum hemorrhage following a normal delivery, 10 years ago, presented with a history of persistent vaginal discharge and post-coital bleeding. A pap smear reported moderate dysplasia, and a subsequent colposcopic biopsy reported severe dysplasia with crypt extension. The patient underwent a laparoscopic trachelectomy, and histology of the stump reported cervical squamous carcinoma *in situ*, with no microinvasion.

**Key words:** Cervical stump, hysterectomy, trachelectomy

## INTRODUCTION

The laparoscopic removal of a cervical stump following a supra cervical (subtotal) hysterectomy was first described by Nezhat *et al*, and they concluded that the cervical stump could be removed laparoscopically by an experienced surgeon.<sup>[1]</sup> The advantages of the laparoscopic approach included possible stump adhesiolysis, providing adequate postoperative vault support, and assessment of the pelvic lymph nodes.<sup>[1]</sup>

## CASE REPORT

The 43-year-old, presented with a history of persistent p v discharge and occasional post-coital bleeding.

There was no relevant past medical history. She had undergone Subtotal Hysterectomy in 1994, due to postpartum hemorrhage following a normal delivery. A colposcopic biopsy done in January 2009, reported severe dysplasia of the cervix, with a human papillomavirus

(HPV) effect and crypt extension. There was a strong family history of cancer of the cervix, as her mother had succumbed to the disease.

On general examination she was in fair general condition, well-built and well-nourished, with adequate hydration. There was no pallor, cyanosis, icterus or any significant lymphadenopathy. She had no pedal or sacral edema. The vital signs were stable.

The cardiovascular, respiratory, and the central nervous systems were clinically within normal. An abdominal examination revealed a midline subumbilical scar. There was no tenderness. The liver and the spleen were not palpable. There was no evidence of any intra-abdominal free fluid. The bowel sounds were normal. On internal examination, the external genitalia were normal and the vaginal mucosa healthy. The uterus was absent and the cervical stump was appreciated. The right and left adnexa had no tenderness or mass appreciated clinically. The pouch

### Address for correspondence:

Dr. Rafique B Parkar,  
Consultant Obstetrician and Gynecologist,  
Specialist in Hysteroscopy and Laparoscopy, P.O. Box 520,  
Sarit Center, 00606, Nairobi, Kenya.  
E-mail: rafsan@africaonline.co.ke

### Access this article online

Quick Response Code:



Website:  
[www.gynecendoscopy.org](http://www.gynecendoscopy.org)

DOI:  
10.4103/0974-1216.85287

of douglas appeared empty. There was minimal discharge evident on the examining finger.

The hemoglobin was 13.3 g/dl, blood sugar was 5.3 mmols/L, urea and Electrolytes were normal. She was blood group O positive.

An initial diagnosis of ABNORMAL PAP SMEAR was entertained and the patient opted for a Laparoscopic Trachelectomy, with the option of a Laparotomy, after discussing all her options.

### THE OPERATION

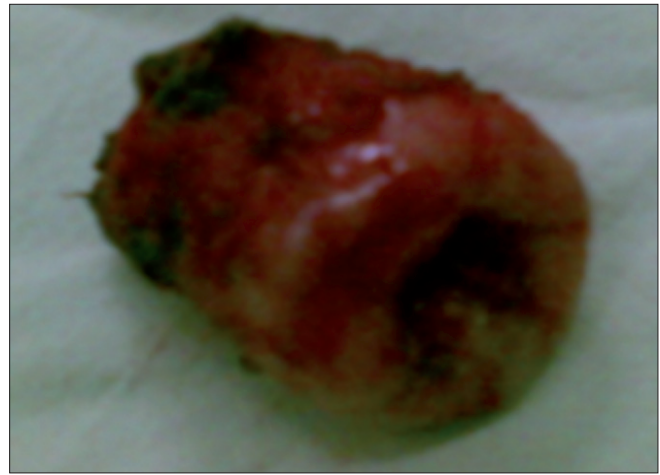
During laparoscopy, a good view was obtained. The liver and gall bladder appeared normal. The uterus was absent. The ovarian fossa and uterosacral ligaments were devoid of any endometriotic lesions. The right ovary was absent and the left appeared normal. Bilateral ureteral peristalsis was evident. There were dense adhesions in the pouch of douglas involving the bowel and the cervical stump. On the left side the adhesions extended to the pelvic side wall. The pelvic lymph nodes were clearly visualized (after intracervical methylene blue injection) and did not appear to be enlarged.

The bladder was firmly adherent anteriorly. Gentle adhesiolysis was undertaken using sharp dissection, bipolar cautery, and a harmonic scalpel. The bladder was adequately reflected caudally. The vaginal vault was subsequently opened over the ceramic cup of a clermont ferrand elevator. The cervical stump was delivered and sent for histological evaluation [Figure 1]. The vault was closed using intracorporeal sutures. The postoperative observations were stable and the urine clear. The estimated blood loss was 100 ml. A cystoscopy with retrograde ureteral catheterization, to confirm the integrity of the bladder and ureters, was undertaken.

At one week of follow-up the patient was well. The histology showed cervical squamous carcinoma *in situ*. A postoperative intravenous urogram (IVU) confirmed that both the ureters and bladder were intact.

### DISCUSSION

Subtotal hysterectomy was developed as a procedure in the 1990s, and is regarded as a safe option to total abdominal hysterectomy in the management of benign uterine conditions and in obstetrics, due to severe postpartum hemorrhage.<sup>[2]</sup> Okaro *et al*, in an assessment of the long-term outcomes of laparoscopic supracervical hysterectomy analyzed the case records of 70 consecutive women undergoing the procedure.



**Figure 1:** The cervical stump after Laparoscopic trachelectomy

Of these, 24.3% (17 cases) reported symptoms related to the cervical stump, within 14 months of the original surgery. In his series 14 of these patients underwent laparoscopic trachelectomy, one had only laparoscopic adhesiolysis and two underwent a laparotomy with trachelectomy due to dense bowel adhesions on the cervical stump.<sup>[3]</sup> Histologically the stumps showed endometriosis (23.5%) and mild dysplasia in 7.6%<sup>[3]</sup> of the patients. In this case our patient presented with persistent p v discharge and occasional post-coital bleeding. The subsequent pap smears were abnormal.

In a retrospective of 41 patients undergoing laparoscopic subtotal hysterectomy, Van der Stege *et al*, noted that 98% of the patients were satisfied with their procedure, with 10% of them having monthly spotting.<sup>[4]</sup> They concluded that although laparoscopic hysterectomy for benign diseases was a satisfactory procedure, special attention should be paid to careful management of the cervical stump.<sup>[4]</sup>

Hilger *et al*, reviewed the indications of 310 trachelectomies performed at the Mayo Clinic from 1974 to 2003. They included stump prolapse (4%), fibroid mass (1%), cervical dysplasia (6%), carcinoma *in situ* (5%), irregular bleeding (2%), and cervicitis (53%). The complications following vaginal trachelectomies were encountered in 80% of the procedures against 37% in the abdominal procedure.<sup>[5]</sup> In our report the cervical stump confirmed carcinoma *in situ*.

### ACKNOWLEDGMENT

The authors would like to thank their colleagues, administration, and staff of the Nairobi Hospital, as also the patient, for allowing us to publish this case.

## REFERENCES

1. Nezhat CH, Nezhat F, Roemisch M, Seidman DS, Nezhat C. Laparoscopic trachelectomy for persistent pelvic pain and endometriosis. *Fert Steril* 1996;66:925-8.
2. Jenkins TR. Laparoscopic supracervical hysterectomy. *Am J Obstet Gynecol* 2004;191:1875-84.
3. Okaro EO, Jones KD, Sutton C. Long term outcomes following laparoscopic supracervical hysterectomy. *BJOG* 2001;108:1017-20.
4. Van der Stege JG, van Beek JJ. Problems related to the cervical stump at follow up in laparoscopic supracervical hysterectomy. *JSLs* 1999;3:335-6.
5. Hilger WS, Pizarro AR, Magrina JF. Removal of the retained cervical stump. *Am J Obstet Gynecol* 2005;193:2117-21.

**How to cite this article:** Parkar RB, Hassan MA, Otieno D, Baraza R. Laparoscopic trachelectomy for cervical stump 'Carcinoma *in situ*'. *J Gynec Endosc Surg* 2011;2:58-60.

**Source of Support:** Nil. **Conflict of Interest:** None declared.

## Announcement

## iPhone App



Download  
iPhone, iPad  
application

FREE

A free application to browse and search the journal's content is now available for iPhone/iPad. The application provides "Table of Contents" of the latest issues, which are stored on the device for future offline browsing. Internet connection is required to access the back issues and search facility. The application is Compatible with iPhone, iPod touch, and iPad and Requires iOS 3.1 or later. The application can be downloaded from <http://itunes.apple.com/us/app/medknow-journals/id458064375?ls=1&mt=8>. For suggestions and comments do write back to us.