

# Anatomic Variations in the Palmar Cutaneous Branch of the Median Nerve Among Adults in Lagos, Nigeria

Bolaji O Mofikoya, Andrew O Ugburo

Department of Surgery, Hand Rehabilitation Burns and Plastic Surgery Unit, College of Medicine, University of Lagos PMB12003, Idiaraba Surulere, Lagos, Nigeria

## ABSTRACT

Dysesthesias due to palmar cutaneous branch of median nerve injuries infrequently follow carpal tunnel release surgeries. **Objective:** To determine the course of palmar cutaneous branch of the median nerve in wrist of adult Nigerians, identify the common variations, determine its relations to the palmaris longus (PL) in the region of the distal wrist crease. And on these basis, suggest a safe incision for carpal tunnel surgery in Nigerians. **Materials and Methods:** Detailed anatomic dissection of the palmar cutaneous branch of the median nerve was carried out with the aid of a loupe magnification on 40 Nigerian cadaver wrists. The origin, course in the distal forearm, wrist and proximal palm was traced. Measurements of the distances between the radial and ulnar branches of the nerve and the PL were made. The distance between origin of the nerve and the distal wrist crease was measured as well. The common branching pattern of the nerve was noted. **Results:** The palmar cutaneous branch of the median nerve was present in all dissected wrists. The mean distance of the radial branch to PL was 0.81 cm (SD  $\pm$  0.3 cm), while the ulnar branch was 0.3 cm (SD  $\pm$  0.1 cm). from same structure. The mean distance from the origin to the distal wrist crease is 4.5 cm (SD  $\pm$  2.1 cm). We noted the terminal distal branching pattern of the nerve to be highly variable. **Conclusion:** The Palmar cutaneous branch of the median nerve is safe with an incision made at least 0.5 cm ulnar to the PL in carpal tunnel surgeries in Nigerians.

**KEYWORDS:** Carpal tunnel surgery, median nerve, palmar cutaneous branch

## Address for correspondence:

Dr. Bolaji O Mofikoya,  
Department of Surgery, Hand Rehabilitation Burns and  
Plastics Surgery Unit, College of Medicine University of Lagos PMB12003,  
Surulere, Lagos, Nigeria.  
E-mail: bmofikoya@yahoo.com

## Access this article online

### Quick Response Code:



Website: [www.nigerianjsurg.com](http://www.nigerianjsurg.com)

DOI:  
10.4103/1117-6806.103112

the anatomic variation of this nerve in the various races and its potential surgical importance.<sup>[6,7]</sup> We therefore sought to define the anatomic variations among adults in Lagos and provide a reference point for surgeons in Nigeria and Africa in general.

## MATERIALS AND METHODS

We carried out dissections on a series of 40 cadaver wrists (29 males and 11 females) at the Skills center of the College of Medicine University of Lagos and the Lagos University Teaching Hospital Lagos, Nigeria. All dissections were done under  $\times 4.5$  loupe magnification.

In all the cadaveric dissections an incision was made over the anterior middle third of the forearm. This was extended distally between the Palmaris longus (PL) and the flexor carpi radialis (FCR). The distal wrist crease was identified and used as a reference point. The PCBMN was then traced from its origin to its terminal branches in the palm. The relationships of the PCBMN and the FCR, PL and the transverse carpal ligament were noted and the variations were also noted.

Any accessory PCBMN proximally and distally was also identified. The following measurements were taken with the aid of a measuring tape to the nearest millimeter under loupe magnification.

1. The distance between the origin of the PCBMN and distal wrist crease.
2. The distance between the most radial branch of the PCBMN

## INTRODUCTION

The operative decompression of the carpal tunnel is one of the commonest elective surgical procedures carried out on the hand. One of most troublesome sequela is the painful neuroma which follows the damage to the palmar cutaneous branch of the median nerve (PCBMN).<sup>[1-3]</sup> Attention has been called to the injury to PCBMN as a cause of the painful dysesthesia that follows carpal tunnel surgery.<sup>[3]</sup> Several workers have suggested that a curved longitudinal incision located on the ulnar side of the ring finger is the best incision that protects the PCBMN.<sup>[4]</sup> Others have concluded that incision 1 cm ulnar to the axis of the third metacarpal will avoid damage to the PCBMN.<sup>[5]</sup> A number of workers have carried out detailed anatomic studies to identify

and the PL at the level of the distal wrist crease.

3. The distance between the most ulnar branch of the PCBMN and the PL at the level of the distal wrist crease.

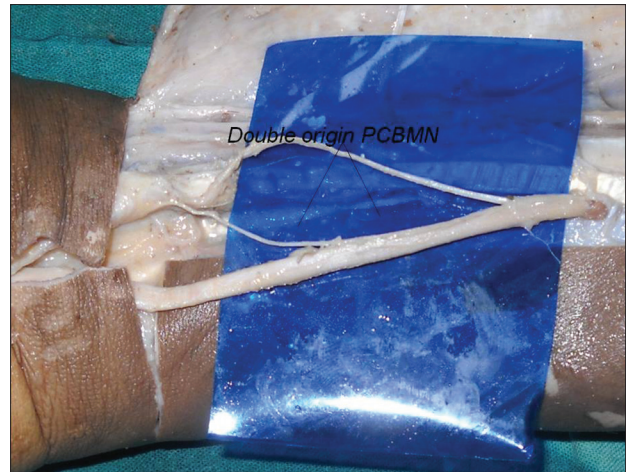
The mean of the various measurements were calculated.

## RESULTS

Forty wrist dissections were done. The PCBMN was present in all 40 wrists. The median nerve was identified between the tendon of PL and FCR in the cadaveric dissections. The nerve had two origins joining distally in one specimen [Figure 1]. It subsequently travelled radial to the median nerve for some distance before crossing to the ulnar surface of the FCR. It was observed to lie within the sheath of the FCR. We observed the PCBMN to always enter the palm deep to the splayed out tendon of the PL. The distal divisions of the PCBMN in our study were highly variable. The type A pattern in which there was major radial and ulnar branches each with its own subdivisions predominated in 21 wrists. The type B in which there was a sub-branch before the final Y division was seen in the 11 specimen observed. The remaining eight wrists had a highly variable terminal which was not observed to follow any particular pattern. The branches of the PCBMN then pierced the palmar fascia to lie in the subcutaneous fascia of the palm. The PCBMN originated from the volar-radial side of the median nerve in 37 specimens. In three wrists it arose from the ulnar border of the median nerve. The mean distance between the radial branch of PCBMN and the PL was 0.81 cm with a range of 0.4-1.8 cm ( $SD \pm 0.3$  cm). The mean distance between the ulnar branch of the PCBMN and the PL was 0.3 cm with a range of 0.1-0.4 cm ( $SD \pm 0.1$  cm). The mean distance of the origin of PCBMN to the distal wrist crease was 4.5 cm ( $SD \pm 2.1$  cm). In our study no PCBMN passed through the PL tendon. We also did not observe any communication between the PCBMN and the superficial branch of the radial nerve.

## DISCUSSION

The palmar cutaneous branch of the Median nerve is known to be vulnerable in procedures involving the distal forearm and the palms particularly in carpal tunnel release. It is the last branch of the median nerve to be given off in the forearm. Up to a third of all complications related to carpal tunnel release is attributable to PCBMN injury.<sup>[1]</sup> In our study we found mean distance from the origin to the distal wrist crease was 4.5 cm. This was comparable to the findings of Bezeera.<sup>[8]</sup> Other workers have reported widely varied values from 3.2 cm reported by Cheung *et al.*<sup>[9]</sup> to 8.6 cm reported by Hobbs.<sup>[5]</sup> We found the PCBMN was present in all our dissections and originated from the volar- radial surface of the nerve in 92.6% of cases, similar to the findings by other workers.<sup>[9,10]</sup> The mean distance between the most ulnar division of the nerve and the PL tendon was 0.3 cm while the mean distance between the PL and the most radial branch was 0.81 cm. We noted a PCBMN with a collateral origin in one wrist (1.9%).



**Figure 1:** A double origin palmar cutaneous branch of median nerve in one of the cadaveric dissections

From our observations it appears that incisions for carpal tunnel release made 0.4 cm medial to and 1.8 cm lateral to the PL are at risk of damaging some of the fibres of the PCBMN. Though, other workers<sup>[4,5]</sup> have recommended a well placed incision over the ulnar side of the axis of the ray of the ring finger, there has been uncertainty concerning this, as the axis of the ring finger has found to be ambiguous and highly variable depending on whether the digit is in flexion or extension.<sup>[11]</sup> We used the PL as a reference point in our study as it is easily recognizable and suggest that in Nigerians undergoing carpal tunnel surgery release, the incision made 0.5 cm ulnar to the medial border of the PL at the level of the distal wrist crease is safe. The limitations of this work include the non discrimination between male and female's wrist in the measurements, as well as small sample size. Though the incidence of PL agenesis among Nigerians is low,<sup>[12,13]</sup> when absent, we suggest the incision should be ulnar to the interthenar depression (this depression is best visualized by placing the wrist in full extension and looking in line with plane of the palm).

## CONCLUSION

The PCBMN in the wrist of the Nigerian is likely to be safe when a carpal tunnel release incision is made at least 0.5 cm ulnar to the PL.

## REFERENCES

1. MacDonald RI, Lichtman DM, Hanlon JJ, Wilson JN. Complications of surgical release for carpal tunnel syndrome. *J Hand Surg Am* 1978;3:70-6.
2. Brown RA, Gelberman RH, Seiler JG 3<sup>rd</sup>, Abrahamsson SO, Weiland AJ, Urbaniak JR, *et al.* Carpal tunnel release. A prospective, randomized assessment of open and endoscopic methods. *J Bone Joint Surg Am* 1993;75:1265-75.
3. Carroll RE, Green DP. The significance of the palmar cutaneous nerve at the wrist. *Clin Orthop Relat Res* 1972;83:24-8.
4. Taleisnik J The palmar cutaneous branch of the median nerve and the approach to the carpal tunnel. An anatomical study. *J Bone Joint Surg Am* 1973;55:1212-7.

5. Hobbs RA, Magnussen PA, Tonkin MA. Palmar cutaneous branch of the median nerve. *J Hand Surg Am* 1990;15:38-43.
6. Lanz U. Anatomical variations of the median nerve in the carpal canal. *J Hand Surg Am* 1977;2:44-53.
7. Stanic MF, Eskinja N, Stosić A. Anatomical variations of the median nerve in the carpal tunnel. *Int Orthop* 1995;19:30-4.
8. Bezerra AJ, Carvalho VC, Nucci A. An anatomical study of the palmar cutaneous branch of the median nerve. *Surg Radiol Anat* 1986;8:183-8.
9. Cheung JW, Shyu JF, Teng CC, Chen TH, Su CH, Shyr YM, *et al.* The anatomical variations of the palmar cutaneous branch of the median nerve in Chinese adults. *J Chin Med Assoc* 2004;67:27-31.
10. Dasilva MF, Moore DC, Weiss AC, Akelman MD, Sikirica M. Anatomy of the palmar cutaneous branch of the median nerve: Clinical significance. *J Hand Surg Am* 1996;21:639-43.
11. Watch maker GP, Weber D, Mackinnon SE. Avoidance of transection of the palmar cutaneous branch of the median nerve in carpal tunnel release. *J Hand Surg Am* 1996;21:644-50.
12. Mbaka GO, Akinlolu AA, Ayanuga AO, Shailie PD, Adefule AK, *et al.* The incidence of agenesis of *Palmaris longus* among the yoruba tribe in Nigeria. *Niger J Med Rehabil* 2008;13:11-4.
13. Enye LA, Saalu LC, Osinubi AA. Prevalence of agenesis of *Palmaris longus* muscle among students in two Lagos based Medical schools. *Int J Morphol* 2010;28:849-54.

**How to cite this article:** Mofikoya BO, Ugboro AO. Anatomic variations in the palmar cutaneous branch of the median nerve among adults in Lagos, Nigeria. *Niger J Surg* 2012;18:85-7.

**Source of Support:** Nil. **Conflict of Interest:** None declared.

#### Announcement

##### iPhone App



Download  
iPhone, iPad  
application

FREE

A free application to browse and search the journal's content is now available for iPhone/iPad. The application provides "Table of Contents" of the latest issues, which are stored on the device for future offline browsing. Internet connection is required to access the back issues and search facility. The application is Compatible with iPhone, iPod touch, and iPad and Requires iOS 3.1 or later. The application can be downloaded from <http://itunes.apple.com/us/app/medknow-journals/id458064375?ls=1&mt=8>. For suggestions and comments do write back to us.