



**POSTER PRESENTATION**

**Open Access**

# Quantitative non-contrast T1 mapping of left ventricle in children and young adults

Keyur Parekh\*, Cynthia K Rigsby, Roger A deFreitas, Bruce S Spottiswoode, Michael Markl

From 17th Annual SCMR Scientific Sessions  
New Orleans, LA, USA. 16-19 January 2014

## Background

Quantification of myocardial T1 values is a promising tool that may be used to quantify myocardial fibrosis. The purpose of our study is to establish a preliminary reference value of normal left ventricular (LV) myocardium in children and young adults using non-contrast T1 mapping.

## Methods

The HIPAA compliant prospective study was IRB approved. Sixteen patients (mean age 15.4 years; range 5-25 years) underwent cardiac magnetic resonance (CMR) (1.5-T) including non-contrast short axis T1 mapping (modified Look-Locker [MOLLI] sequence). Twelve patients with no intrinsic myocardial abnormality based on clinical history, standard biomarkers and echocardiographic criteria were compared with 3 patients having cardiac dysfunction and 1 patient with hypertrophic cardiomyopathy (HCM). Short axis images were manually contoured to outline the epicardium and endocardium using AHA 16-segment model yielding 192 normal myocardial segments, 48 segments in patients with cardiac dysfunction, and 16 segments in a patient with HCM. Patient groups were compared using one-way analysis of co-variance (ANOVA). Chi-squared test was performed to compare appropriateness of discrete data. Receiver operating characteristic (ROC) curve was used to obtain a cut-off value of T1 relaxation time. Statistical significance was defined as  $p < 0.05$ .

## Results

Myocardial T1 values in the normals ( $982.1 \pm 30.0$  ms) were significantly different ( $p < 0.001$ ) when compared to patients with cardiac dysfunction ( $1021.0 \pm 34.8$  ms) and hypertrophic cardiomyopathy ( $1039.7 \pm 20.8$  ms). Non-contrast myocardial T1 cutoff of 1005 ms conceded

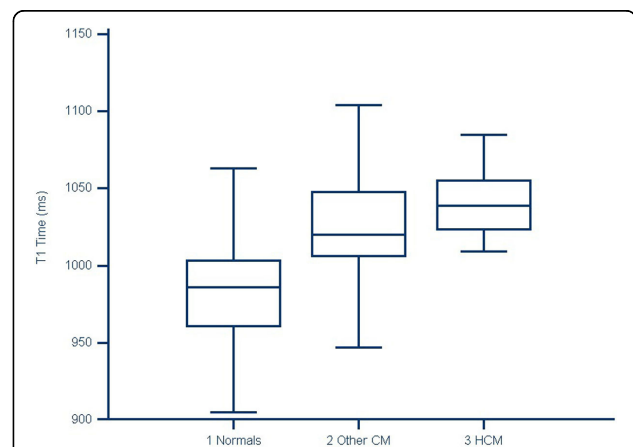
a sensitivity of 80% and specificity of 83% when compared to patients with cardiomyopathy ( $p < 0.001$ ).

## Conclusions

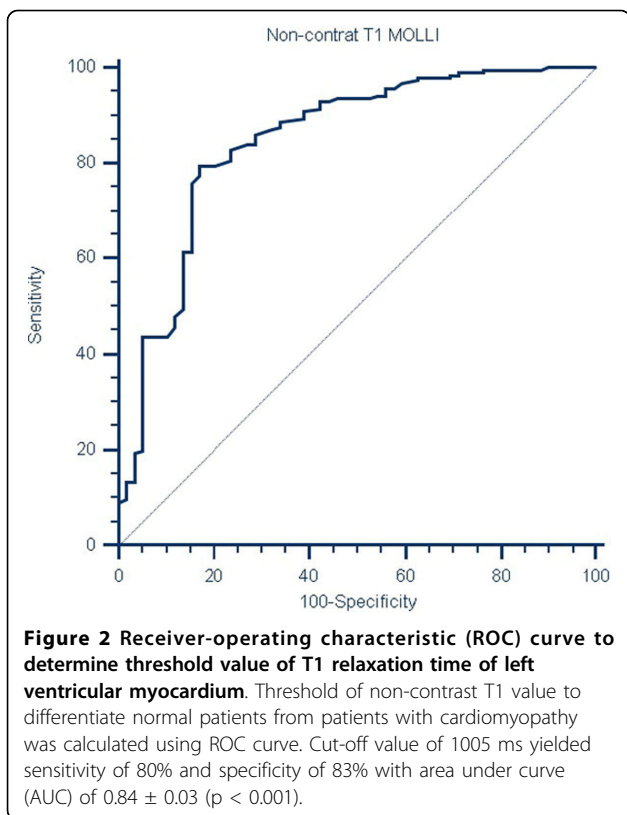
The normal non-contrast T1 values of LV myocardium in children and young adults obtained can be used as a baseline for comparison to patients with underlying myocardial abnormalities. Enrollment is underway to validate our results in a larger cohort.

## Funding

None.



**Figure 1 Non-contrast myocardial T1 values in normal and cardiomyopathy (non-hypertrophic and hypertrophic) patients in children and young adults.** Mean values of left ventricular myocardium using non-contrast T1 MOLLI in normal population is  $982.1 \pm 30.0$  ms. Non-hypertrophic cardiomyopathy (CM) and hypertrophic cardiomyopathy (HCM) has mean values of  $1021.0 \pm 34.8$  ms and  $1039.7 \pm 20.8$  ms. Values between these three groups were significantly different with  $p < 0.001$ .



Published: 16 January 2014

doi:10.1186/1532-429X-16-S1-P268

**Cite this article as:** Parekh et al.: Quantitative non-contrast T1 mapping of left ventricle in children and young adults. *Journal of Cardiovascular Magnetic Resonance* 2014 **16**(Suppl 1):P268.

**Submit your next manuscript to BioMed Central and take full advantage of:**

- Convenient online submission
- Thorough peer review
- No space constraints or color figure charges
- Immediate publication on acceptance
- Inclusion in PubMed, CAS, Scopus and Google Scholar
- Research which is freely available for redistribution

Submit your manuscript at  
[www.biomedcentral.com/submit](http://www.biomedcentral.com/submit)

 **BioMed Central**