

# Corticosteroid injection treatment for dactylitis in psoriatic arthritis

Antonio Carriero<sup>ID</sup>, Ennio Lubrano<sup>ID</sup>, Valentina Picerno, Angela Anna Padula and Salvatore D'Angelo<sup>ID</sup>

*Ther Adv Musculoskel Dis*

2021, Vol. 13: 1–12

DOI: 10.1177/  
1759720X211041864

© The Author(s), 2021.  
Article reuse guidelines:  
sagepub.com/journals-  
permissions

**Abstract:** Dactylitis – a hallmark clinical feature of psoriatic arthritis (PsA) – that occurs in 30–50% of PsA patients, is a marker of disease severity for PsA progression, an independent predictor of cardiovascular morbidity and impairs the motor functions of PsA patients. There is a paucity of evidence for the treatment due to the absence of randomized controlled trials assessing dactylitis as a primary endpoint and current practice arises from the analysis of dactylitis as a secondary outcome. Corticosteroid (CS) injections for dactylitis in PsA patients are a therapeutic treatment option for patients with isolated dactylitis or for patients with flares in tendon sheaths, despite stable and effective systemic treatment. The aim of this narrative review is to briefly illustrate the clinical aspects of dactylitis in PsA, the imaging and clinimetric tools used to diagnose and monitor dactylitis, the current treatment strategies and principally to provide a comprehensive picture of the clinical efficacy and safety with ultrasound-guide and blind techniques of CS injections for dactylitis in PsA patients.

**Keywords:** corticosteroid, dactylitis, injection, psoriatic arthritis, tenosynovitis, therapy, treatment, ultrasound

Received: 30 March 2021; revised manuscript accepted: 6 August 2021.

## Introduction

Dactylitis, derived from the Greek word ‘daktylos’ meaning finger and also known as ‘sausage-shaped’ digit, is a diffuse finger or toe swelling due to an underlying inflammatory or infiltrative disorder.<sup>1,2</sup> Dactylitis can also be defined as uniform swelling such that the soft tissues between the metacarpophalangeal (MCP) and the proximal interphalangeal (PIP) and the distal interphalangeal (DIP) joints and the digital tuft are diffusely swollen to the extent that the actual joint swelling can no longer be independently recognized.<sup>3,4</sup> The different forms of dactylitis can be classified as inflammatory infectious (tuberculous dactylitis, syphilitic dactylitis, and blistering distal dactylitis), inflammatory non-infectious (spondyloarthritis (SpA) dactylitis, sarcoid dactylitis and gouty dactylitis) and non-inflammatory (sickle cell dactylitis).<sup>2</sup>

In SpA dactylitis, there is a diffuse swelling of the entire digit due to synovitis, tenosynovitis, and soft-tissue inflammation.<sup>2</sup> Dactylitis, although is

more frequent in psoriatic arthritis (PsA), is one of the clinical manifestations of all the SpA, a group of interrelated diseases which includes, ankylosing spondylitis, PsA, reactive arthritis, arthritis associated with inflammatory bowel disease, and the undifferentiated forms.<sup>1,2,5–7</sup>

Dactylitis occurs in 30–50% of PsA patients, often in early disease<sup>8</sup> and may sometimes occur for a long time in isolation as the only clinical manifestation of PsA and there are also patients with psoriasis who only exhibit, for years, dactylitis.<sup>1</sup> The point prevalence of dactylitis in PsA is >50% in some contemporary randomized controlled trials (RCTs) that include tumor necrosis factor inhibitors (TNFi) and interleukin (IL)-17–IL-23 axis cytokine inhibitors (i).<sup>3</sup>

The aim of this narrative review is to briefly illustrate the clinical aspects of dactylitis in PsA, the imaging and clinimetric tools used to diagnose and monitor dactylitis, the current treatment strategies and principally to provide a comprehensive picture

Correspondence to:

**Antonio Carriero**  
Rheumatology Institute of Lucania (IReL), Rheumatology Department of Lucania, San Carlo Hospital of Potenza and Madonna delle Grazie Hospital of Matera, Via Petrone snc, 85100 Potenza (PZ), Italy

PhD Scholarship in Translational and Clinical Medicine, Department of Medicine and Health Sciences, University of Molise, Campobasso, Italy  
[carrieroantonio@hotmail.it](mailto:carrieroantonio@hotmail.it)

**Ennio Lubrano**  
Department of Medicine and Health Sciences, University of Molise, Campobasso, Italy

**Valentina Picerno**  
**Angela Anna Padula**  
**Salvatore D'Angelo**  
Rheumatology Institute of Lucania (IReL), Rheumatology Department of Lucania, San Carlo Hospital of Potenza and Madonna delle Grazie Hospital of Matera, Potenza, Italy

of the clinical efficacy and safety with ultrasound-guide and blind techniques of corticosteroid (CS) injections for dactylitis in PsA patients.

### Clinical aspects, imaging, and clinimetric assessment

#### Clinical aspects

Dactylitis ('sausage'-shaped fingers or toes) – considered a hallmark clinical feature of PsA – is clinically presented with sausage-like swelling of both digits of the hands (Figure 1(a) and (b)) and feet. Digits involved are presented with swelling and slight redness that are due to flexor tenosynovitis and marked adjacent soft-tissue swelling with a variable degree of small joint synovitis.<sup>1,9–11</sup>

Physical examination in acute dactylitis shows swelling, tenderness, and pain mostly along the flexor tendons of the involved digit<sup>1,12</sup> and the digit swollen is so marked that the patient cannot flex his finger. Asymmetry versus the contralateral

digit also favors dactylitis diagnosis.<sup>10</sup> Sometimes, there is also pain and swelling in the joints of the dactylitic finger or toe. There is no need to obtain imaging evaluation for the clinical diagnosis since physical examination has the same specificity and sensitivity as magnetic resonance imaging (MRI) for the diagnosis of flexor tenosynovitis.<sup>2,12–14</sup>

Diagnosis of PsA dactylitis by personal medical history is more difficult. In this case, there are only two possibilities for the diagnosis: (a) to show a photograph of finger or toe dactylitis to the patient for confirmation; (b) to examine the routine radiograph obtained by the patient's physician at the time of the sausage-like swelling looking for the typical diffuse soft-tissue swelling on X-rays.<sup>2,15</sup>

Tender dactylitis, for yet unclear mechanisms, is a marker of disease severity for PsA progression in general. In fact, significantly greater joint damage and erosions occur in dactylitic in comparison to non-dactylitic digits and digits that show only arthritis.<sup>5,10,11</sup> Furthermore, dactylitis can be an independent predictor of cardiovascular morbidity<sup>10</sup> and impairs the motor functions required for daily living.<sup>16</sup>

#### Imaging

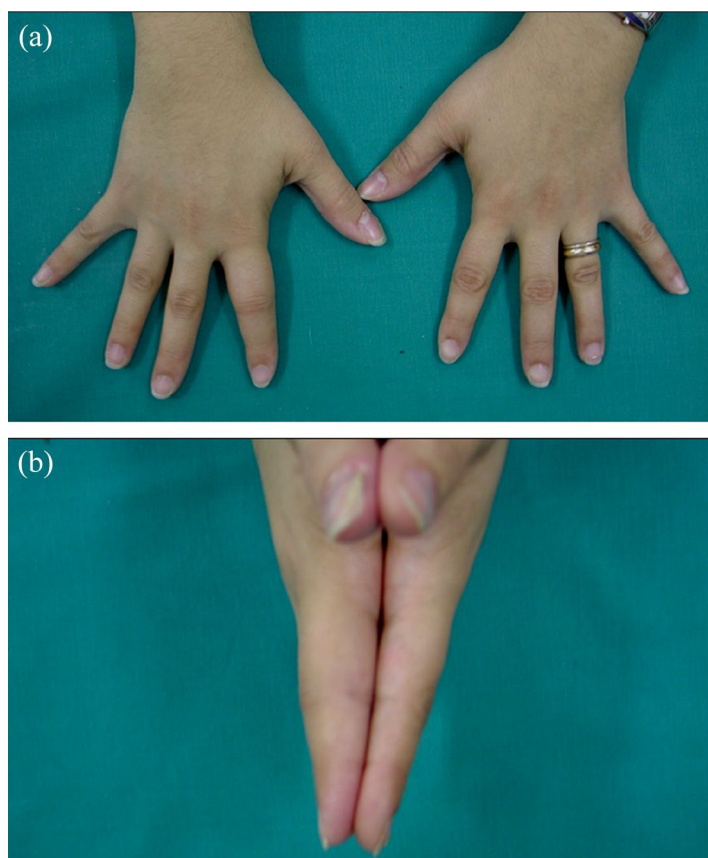
Ultrasound (US) and MRI have been used for diagnosing early PsA and have provided additional clues to the pathogenesis of the disease and permitting to differentiate PsA from rheumatoid arthritis (RA).<sup>17</sup>

US can detect tenosynovitis, pseudotenosynovitis, extracapsular inflammatory changes, dactylitis, joint synovitis, subcutaneous edema, and abnormalities of the accessory pulleys<sup>3</sup> (Figures 2 and 3).

Extra-tendon soft-tissue inflammation and small joint enthesophytes at flexor tendon insertions seen by US has been shown in patients with PsA-related tenosynovitis but not with RA-related tenosynovitis.<sup>18</sup>

US is a useful tool in PsA management for diagnosis, monitoring therapy and as an instrument guidance approach to steroid injections at the level of inflamed joints, tendon sheaths, and entheses.<sup>17</sup>

The first US and MRI studies established that dactylitis is due to flexor tenosynovitis and marked



**Figure 1.** (a) Dactylitis of the second digit of the right hand (frontal view). (b) Dactylitis of the second digit of the right hand compared to the contralateral (lateral view).

adjacent soft-tissue swelling with a variable degree of joint synovitis occurring in 17–66% of the dactylitis.<sup>12,13,19,20</sup>

MRI in particular has contributed to better understand PsA pathogenesis by establishing that entheses is the primary target of inflammation.<sup>17,21</sup>

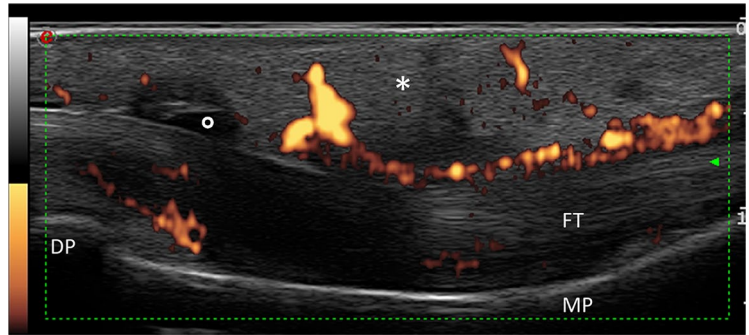
In 2008, Healy and co-workers reported in their MRI study on PsA dactylitis that bone edema ranged from small areas adjacent to the joint capsule insertions to edema involving the whole phalanx supporting the hypothesis by McGonagle on a primary involvement of the entheses in dactylitis.<sup>2,22</sup>

In a comprehensive MRI study of PsA-related dactylitis nine features were found including synovitis, bone edema, osteitis, subcutaneous edema, flexor tenosynovitis, extensor tenosynovitis, inflammatory changes of the plantar and/or volar plates and/or the collateral ligaments, erosions and sesamoiditis at the thumb and great toe.<sup>22</sup>

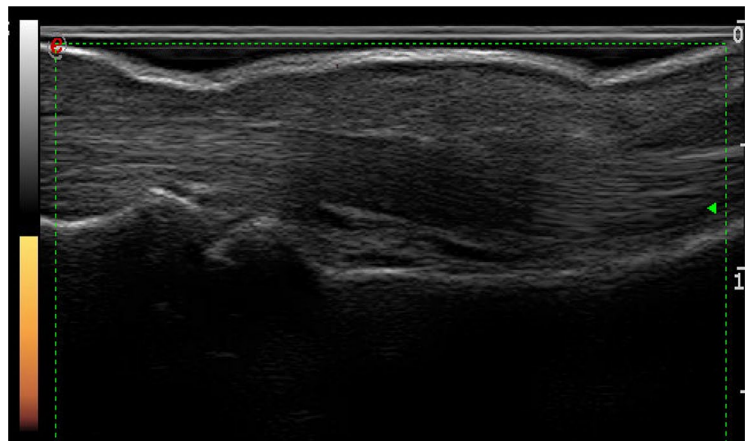
Finally, European League Against Rheumatism (EULAR) recommendations on the use of imaging in the management of PsA suggest the use of US or MRI (with the last considered secondary for the lower availability and high costs) when peripheral involvement (dactylitis, enthesitis, tenosynovitis, bursitis and arthritis) is suspected.<sup>17,23</sup>

#### *Clinimetric assessment*

The recognition that dactylitis is a distinct entity from arthritis led to the introduction of dactylitis digit counts as an outcome measure in some RCTs. Since it was difficult to make an objective score for the severity or extent of dactylitis, various methods have so far been used.<sup>9</sup> Initially, the most straightforward method was to count affected digits (score range 0–20). Afterwards, the Dactylitis Severity Score (DSS) was developed and frequently used.<sup>24,25</sup> In 2005, Helliwell and colleagues developed a clinically objective and validated instrument for dactylitis called the Leeds dactylometer.<sup>26</sup> This instrument led to the development of a more objective measure, the Leeds Dactylitis Index (LDI) that quantifies both the size and tenderness so that the score can differentiate between tender and non-tender dactylitis and which was able to identify improvements in dactylitis in RCTs where dactylitis was a secondary outcome measure.<sup>26–29</sup>



**Figure 2.** Tenosynovitis of the III right flexor tendon characterized by marked synovial proliferation, a moderate increase of the tendon thickness and a thickened and hypoechoic peritendineal tissue. Synovial sheath widening (circle) associated with soft-tissue edema (asterisk). Power Doppler function revealed diffuse and severe vascular signal inside and around the tendon sheath (Grade 3). DP, distal phalanx; FT, flexor tendon; MP, medial phalanx.



**Figure 3.** US follow-up after 4 weeks of the same tendon. Note the dramatic reduction of the power Doppler signal (Grade 0) and gray scale score (Grade 0) with the resolution of the flexor tenosynovitis and the soft-tissue edema.

#### **Current treatment strategies**

The natural clinical course of dactylitis is largely unknown. In some patients, acute dactylitis is often the inaugural feature of PsA and may resolve without any treatment or it may remain the only manifestation of PsA for months to years.<sup>10</sup>

Dactylitis is a critical domain in PsA clinical trials and treatment algorithms and is associated with more erosive forms and more active form of PsA thus, early diagnosis and therapy, favors better outcomes. Unfortunately, as highlighted in the Group for Research and Assessment of Psoriasis and Psoriatic Arthritis (GRAPPA) recommendation,<sup>30</sup>

there is paucity of evidence in this field due to the absence of RCTs assessing dactylitis as a primary endpoint and current practice arises from the analysis of dactylitis as a secondary outcome.

To date there is only one study addressing dactylitis as a primary endpoint, the GO-DACT study,<sup>31</sup> a multicentre, randomized, double-blind, placebo-controlled, phase-3b trial of golimumab plus methotrexate (MTX) versus placebo plus MTX, in MTX-naïve and biologic disease-modifying anti-rheumatic drugs (bDMARDs) naïve patients with PsA and active dactylitis. The primary endpoint was DSS change from baseline to week 24. The GO-DACT trial showed that the combination of golimumab plus MTX is associated with significantly greater clinical improvements in dactylitis in comparison with MTX monotherapy.<sup>31</sup>

Dactylitis has been treated with non-steroidal anti-inflammatory drugs (NSAIDs), CS injections, conventional synthetic (cs) DMARDs, targeted synthetic (ts) DMARDs and bDMARDs.<sup>32–34</sup> Compared with bDMARDs, csDMARDs alone are less effective.<sup>9</sup> tsDMARDs such as apremilast and tofacitinib have also been shown to be effective in the treatment of dactylitis.<sup>3</sup>

According to the recommendation by GRAPPA<sup>30</sup> most physicians use NSAIDs and CS injections as first-line therapy, although they have not been formally studied in RCTs.<sup>30</sup> According to GRAPPA recommendation, for resistant cases, csDMARDs such as MTX, leflunomide (LEF), sulfasalazine (SSZ) or a tsDMARDs such as apremilast (a phosphodiesterase 4 inhibitor (PDE-4i)) are recommended. For resistant cases, biologics such as TNFi or IL-12/23i should be initiated. In case of TNFi failure or IL-12/23i failure, it is recommended switching to another bDMARDs (TNFi, IL-12/23i, IL-17i) or to a PDE-4i.

In the updated 2019 EULAR recommendations,<sup>35</sup> local CS injections are proposed as initial therapy or adjunctive therapy in PsA.

### CS injections

CS injection for dactylitis in PsA patients is a therapeutic treatment option for patients with isolated dactylitis or in patients with flares in tendon sheaths, despite stable and effective DMARDs treatment.

Local treatment with steroid injection into the tenosynovial sheath is widely used by many

clinicians in everyday clinical practice despite this therapeutic strategy is largely empirical because there is lack of data on dactylitis therapy and because randomized, double-blind placebo-controlled trials have not been conducted.<sup>35</sup> While intra-articular CS gives positive results for a few weeks, injections into tendon sheaths often give months of relief.<sup>36</sup>

Steroid injection could be performed also into the joint (MCP, PIP and DIP) at the same time of intratenosynovial sheath injection because synovitis and tenosynovitis are integral features of dactylitis.<sup>3</sup>

### Contraindications and side effects

Absolute contraindications for local CS injection are local infection at dactylitis site and allergy to CS preparation or anesthetics (if used); relative contraindications are anticoagulation therapy or bleeding diathesis, systemic infection and uncontrolled diabetes.<sup>37</sup>

Adverse reactions<sup>37</sup> of dactylitis CS injection include the following:

- Acute reactions (during injection–within 1 hour): vasovagal reaction, pain, local ecchymosis and bleeding and anaphylaxis for anesthetic.
- Intermediate reactions (hours–days): post-injection flare of pain, facial flushing, menstrual irregularity, pain at the finger, hyperglycemia usually with no clinical risk also in patients with diabetes mellitus.<sup>38</sup>
- Late reactions: tendon rupture, infection, skin depigmentation and skin atrophy.

Tendon rupture is a recognized complication of CS injections,<sup>39–42</sup> but no instance of tendon rupture after more than 300 CS injections for idiopathic and rheumatoid digital flexor tenosynovitis was found by Gray and colleagues.<sup>43</sup>

### Type of CS preparations

There is little evidence to guide medication selection for CS injections for dactylitis, and most recommendations are based on a combination of clinical experience and personal preference.

Common local injectable CS preparations for dactylitis include triamcinolone acetonide, triamcinolone hexacetonide, methylprednisolone acetate, dexamethasone sodium phosphate and

**Table 1.** Steroid dosing and equivalents.

| Corticosteroid <sup>a</sup>    | Common used dosage (mg) | Prednisone equivalent dose (mg) | Relative potency to hydrocortisone | Approximate duration of action (days) |
|--------------------------------|-------------------------|---------------------------------|------------------------------------|---------------------------------------|
| Triamcinolone acetonide        | 40                      | 50                              | 5                                  | 14                                    |
| Methylprednisolone acetate     | 40                      | 50                              | 5                                  | 8                                     |
| Triamcinolone hexacetonide     | 20                      | 25                              | 5                                  | 21                                    |
| Dexamethasone sodium phosphate | 4                       | 25                              | 25                                 | 6                                     |
| Betamethasone sodium phosphate | 2                       | 15                              | 30                                 | 6                                     |

<sup>a</sup>CSs are listed in order of prevalence of use in our experience.

betamethasone sodium phosphate (see Table 1). Long-acting insoluble CS have been developed to enhance anti-inflammatory effect and have a longer duration of action resulting in a prolonged clinical benefit despite a higher incidence of cutaneous side effects.<sup>36,44</sup> Triamcinolone hexacetonide is the least soluble – as well as the least rapid for onset of action – of the commonly used CS, followed by triamcinolone acetonide.<sup>44,45</sup> In our experience, the most commonly used CS for PsA dactylitis injections is triamcinolone acetonide followed by methylprednisolone acetate.

#### *Therapeutic scheme*

For stenosing tenosynovitis, single CS injection is considered to be the best method of care, and in the event of full reduction of symptoms and then recurrence, a second injection may be used.<sup>46,47</sup> Single local injection with triamcinolone acetonide is effective and safe for treating trigger finger and the effects of steroid injections last up to 12 months.<sup>48</sup> For trigger finger, in patients with partial improvement, optimal timing of the next injection appears to be after 69 days.<sup>49,50</sup>

In a 10-year single-center retrospective study of US CS tendon sheath injections in juvenile idiopathic arthritis, only 58/926 (6.3%) tendon sheaths required a repeat injection and only 2 minor – with no major complications – were observed, exhibiting a high technical success rate and safety.<sup>51</sup>

There are no data for the optimal timing for a further injection for dactylitis in PsA, but in our experience, a second injection – 4 weeks after the

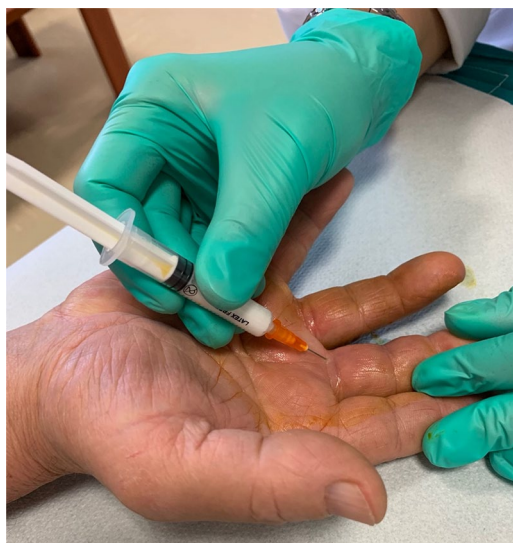first – could be necessary in the limited cases of patients with partial response. Moreover, CS injection should be guided by the response to previous injections, the availability of other therapies, clinical judgment and patient preferences but we rarely inject a single digit more than two or three times.

#### *Adding anesthetics*

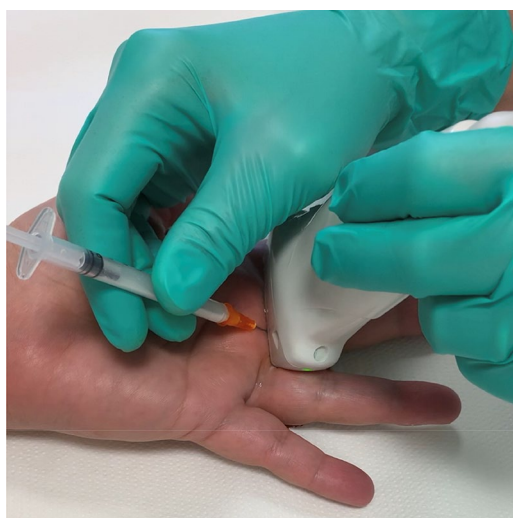Reasons to mix local anesthetics with CS for dactylitis injection (lidocaine 1%-2%, xylocaine 1% or bupivacaine 0.25%) are diagnostic (relieved pain immediately indicates accurate injection), therapeutic (to bridge the interval before the CS yields effect) and preventive (diminishing post-injection pain and flare, diminishing the risk of skin atrophy injecting a dose of anesthetics after CS injection to clear the needle track). As with the choice of CS, the choice of local anesthetics is based more on personal preference and experience than on evidence.<sup>37,44,50</sup> In our clinical practice, we do not mix local anesthetics for the increased risk of allergy and vasovagal reactions.

#### *General injection technique*

Informed consent must be obtained before performing the procedure discussing risks (risk of pain, bleeding, cutaneous atrophy or skin discoloration, steroid flare reaction, and rare risk of infection, tendon rupture, and possible failure to improve), benefits and alternatives with the patients. To start, wash your hands because injections must be performed using aseptic technique or with no touch technique. Prepare equipment for CS injection: 1 mL syringes with fine needle



**Figure 4.** Blind corticosteroid injection for PsA dactylitis.



**Figure 5.** US-guided corticosteroid injection for PsA dactylitis.

(25 Gauge, 0.5 mm × 16 mm), triamcinolone acetonide 40 mg/mL (0.5–1 mL) or methylprednisolone acetate 40 mg/mL (0.5–1 mL), local anesthetic if needed (0.5 mL of bupivacaine 0.25%, 0.5 mL of xylocaine 1% or 0.5 mL lidocaine 1–2%), isopropyl alcohol, chlorhexidine or povidone iodine, topical analgesia with ethyl chloride cooling spray and bandage. Position the patient with the hand supine on the table with supplemental lighting if available. Identify and mark the site of injection with a skin pencil or by

a pressure mark with tip of an ear speculum to guide needle placement. Clean overlying skin with povidone iodine, chlorhexidine or isopropyl alcohol. Use ethyl chloride spray which gives immediate anesthesia. Put on sterile gloves or do not touch the injection site. The patient and the physician should be in a comfortable position and the syringe should be in the dominant hand. Enter the skin with an angle of 45° with proximal to distal direction and advance until the tip of the needle is at the injection site (Figures 4 and 5). Drawback the plunger to make sure the needle tip is not located within a vessel and inject CS into the tendon sheath and if resistance is met, withdraw slightly the syringe and reposition before further injection of CS because injection should not be given into a tendon for the risk of rupture. We place more or less 1 mL of CS in the affected tendon sheath and then we remove the needle applying bandage or a sticking plaster. After the injection, the patient has to flex and extend the digit to help the spreading of the CS within the flexor tendon sheath. The patient is then again advised for absolute rest of the injected area for 1 day and limited use for 2 weeks and reminded that, for the characteristic of the CS preparation, the full benefit of the procedure will be experienced in 1 or 2 weeks. If the patient experiences a local reaction starting after 48 hours – despite the risk is very low using no touch technique or aseptic technique – there is a need for evaluation for infection.<sup>37,44,50,52</sup>

#### *Blind CS injection technique*

A blind CS injection (Figure 4), if given correctly, is an effective method to treat dactylitis. For CS injection into digital flexor sheath there is a need of knowledge of the local anatomy to minimize risk and maximize benefit.

The flexor tendon sheath is a membranous structure that surrounds the flexor tendons from the metacarpal neck to the volar plate of the DIP. It is attached longitudinally to the underlying bony structures. The sheath is thick over the bones and thin in areas overlying the joints, to allow digital flexion. The A1 pulley marks the proximal border of the flexor sheath and overlies the metacarpal neck. The proximal border can be roughly defined by the distal palmar crease.<sup>53</sup>

The injection is placed at the base of the digit (Figure 4), through the flexor crease where the digit meets the hand. Place the needle in the

midline of the finger, through the finger flexion crease at the base of the finger, and angle it approximately 45° distally, with the bevel of the needle facing distally (see Figure 4). Advance the needle through the skin until the resistance encountered by the needle is decreased, indicating that the needle is within the flexor sheath. The plunger of the syringe should depress easily, indicating that the needle is most likely in the flexor tendon sheath.

Proper needle placement requires attention to anatomical landmarks and lack of resistance during injection.<sup>43</sup> Injection from a midlateral approach at the proximal phalangeal level is also been described.<sup>52</sup>

#### *Toe dactylitis*

In the feet, the most commonly affected toe is the fourth.<sup>3</sup> Like finger dactylitis, toe dactylitis is due to flexor tenosynovitis, and extensor tenosynovitis may be present in addition.<sup>13</sup>

CS injection for toe dactylitis is placed at the plantar base of the involved toe entering the skin with an angle of 45° and advancing the tip of the needle with proximal to distal direction. The remaining procedure is the same as for finger dactylitis.

#### *US-guided CS injection technique*

US-guided CS injection (Figures 2, 3 and 5) can be performed using a high-frequency linear transducer (6–18 MHz). The digit to be injected is prepared in a sterile fashion, and the US probe is swept along the tendon in both transverse and longitudinal planes to identify a location along the tendon sheath that permits a safe injection. The needle that appears as a hyper-reflective line is advanced under direct US visualization into the tendon sheath in the transverse or longitudinal approach and is directly visualized ensuring that the tip is located within the tendon sheath. The transverse approach (out of plane) is favored because it provides better visualization and permits to direct and place the needle tip away from the tendon fibers.<sup>51,54</sup> At the injection, CS is visualized spreading within the tendon sheath verifying the correct placement of the drug. This could be followed by injection of local anesthetic to clear the needle track and help prevent cutaneous atrophy.<sup>51</sup>

#### *US-guided or blind CS injection for dactylitis*

An early RA study, comparing US and clinical examination in the detection of flexor tenosynovitis, found that clinical examination is a valuable tool for detecting flexor tenosynovitis for its high specificity and positive predictive values, but a negative clinical examination does not exclude inflammation and an US should be considered.<sup>55</sup>

Blind intra-articular injections in peripheral joints achieve good accuracy with a satisfactory clinical response in RA when performed by a trained physician.<sup>56</sup>

Luz and colleagues<sup>57</sup> demonstrated that US did not increase the accuracy of wrist injections for RA when they were performed by an experienced rheumatologist.

In a systematic review with meta-analysis,<sup>58</sup> based on one trial (moderate quality), injection into the tendon sheath of the long head of the biceps brachii resulted more accurately performed using US guidance than by the blind method<sup>59</sup> and based on another trial (low quality), the US group had a greater reduction in pain and greater improvement in function with no significant difference between groups for adverse events.<sup>60</sup>

As for trigger finger treatment, true intra-sheath injection offered no apparent advantage over subcutaneous injection in the treatment of trigger digits<sup>61</sup> and the use of US-guided injection of CS showed no superior clinical benefits compared to the blinded technique.<sup>62</sup> US guidance offers no advantage over landmark guidance, other than greater accuracy of intra-sheath placement of CS for trigger finger.<sup>50</sup>

In the triple-blinded randomized clinical trial of Mardani-Kivi and co-workers, it was found that extra-sheath CS injection and intra-sheath CS injection of the finger flexor tendon under US guidance in patients with trigger finger are equally effective.<sup>63</sup>

Utilizing US guidance for CS injections into tendon sheaths has shown clinical advantage to conventional blind injections in the adult RA population in terms of accuracy and effectiveness of the therapy.<sup>54</sup>

In the randomized comparative study of Gutierrez and colleagues,<sup>54</sup> the short-term efficacy of local CS injection for tenosynovitis – in patients with

inflammatory chronic arthritis (including 32 PsA patients) – was demonstrated the superiority of US-guided CS injection over conventional blind injection in terms of better outcomes measured by functional, clinical and US scores. Furthermore, US-guided CS injection resulted less painful than the conventional blind injection. Despite US-guided CS injection is more time-consuming than the blind approach (6–10 minutes), on the light of these results, the US-guided approach should be considered the standard approach for tenosynovitis in rheumatological practices.<sup>54</sup>

In our experience (data not published), US resulted a valuable tool for diagnosis, CS injection and treatment follow-up of dactylitis in PsA.

#### *Current evidence for steroid injection*

The anti-flogistic effect of local CS injection in para-articular disorders was first reported by Howard in 1953.<sup>64</sup>

A systematic review of the efficacy of CS injections of tendon sheaths, excluding stenosing tenosynovitis of the wrist and hand, found that low-quality studies suggest that tendon sheath injections may provide at least short-term improvement in pain.<sup>65</sup>

In a model to estimate the costs and outcomes associated with treatment strategies for trigger finger was found that offering 3 CS injections before surgery is a cost-effective strategy. The results were sensitive to the probability of injection site fat necrosis, success rate of steroid injections, time to symptom relief after a steroid injection, and cost of treatment.<sup>66</sup> Non-rheumatoid flexor tenosynovitis resolved in 100% of a small group of patients treated with CS injection and persistent benefit was noted in 93%.<sup>67</sup> In a recent comprehensive literature review on common chronic pain conditions of the hand was found that when the etiology of the pain is inflammatory, CS injections provide significant pain relief and increased functionality and that 10–20 mg of methylprednisolone or triamcinolone injections are the most common steroids used for small joint pain. One study in particular showed that triamcinolone injections compared to methylprednisolone had greater improvements in patient-reported pain and functionality.<sup>46</sup>

In a randomized double-blind study, tenosynovitis remission in RA was achieved more frequently

in the US-guided intratendosynovial CS injection group than in the intramuscular CS injection group.<sup>68</sup> In the study of Gray and colleagues,<sup>43</sup> reviewing the results of intratendon sheath CS injection in 173 episodes of flexor tenosynovitis in 46 RA patients, was found that 93% of the episodes resolved completely for 3 or more months (median: 25 months), the likelihood of a favorable response did not diminish with treatment of recurrent flexor tenosynovitis in a given digit and that tenosynovitis did not recur in 59% of cases.

To the best of our knowledge, there is only one observational study addressing the effectiveness of steroid injection in psoriatic dactylitis.<sup>69</sup> Girolimetto and colleagues found that one local CS injection of 20 mg of methylprednisolone acetate was able to lead to an improvement of dactylitis-related symptoms and digit swelling for at least 3 months in about 90% of cases.<sup>69</sup>

In our experience (data not published), US-guided triamcinolone acetonide injection for dactylitis in PsA patients, resulted in a complete resolution of 8 out of 10 dactylitis at 4 weeks.

Another study investigated the short-term efficacy of CS loco-regional treatment performed under US guidance in tenosynovitis of patients with chronic inflammatory arthritis – including 11 PsA patients – found a significant improvement for the VAS pain, the tenderness score and the sonographic scorings for Gray Scale (GS) and Power Doppler (PD).<sup>70</sup> Similar results were reported by Girolimetto and colleagues showing that clinical improvements of active dactylitis are linked to the regression of US evidence of extra-capsular inflammation (particularly flexor tenosynovitis and soft-tissue edema) at 1 and 3 months after local CS injection. These findings suggest the pivotal role of tenosynovitis and extra-articular disease for symptoms in PsA dactylitis.<sup>71</sup>

#### **Conclusion**

CS injections can be recommended as a safe and effective treatment for dactylitis in PsA, especially if long-lasting CS preparation are injected in the flexor tendon sheath with a US-guided technique.

Future studies using dactylitis as a primary outcome measure will determine the most appropriate treatment for this painful and damaging condition. Given the importance and frequency of dactylitis in PsA, such studies should include



both robust and quantifiable clinical indices (e.g. LDI and DSS), as well as imaging tools, the latter of which are particularly promising as valid and sensitive measure for diagnosis, treatment and follow-up of dactylitis in PsA.

### Conflict of interest statement

The authors declared no potential conflicts of interest with respect to the research, authorship and/or publication of this article.

### Funding

The authors received no financial support for the research, authorship and/or publication of this article.

### ORCID iDs

Antonio Carriero  <https://orcid.org/0000-0002-3112-6488>

Ennio Lubrano  <https://orcid.org/0000-0001-6189-5328>

Salvatore D'Angelo  <https://orcid.org/0000-0002-7442-1110>

### References

- Olivieri I, Scarano E, Padula A, *et al.* Dactylitis, a term for different digit diseases. *Scand J Rheumatol* 2006; 35: 333–340.
- Olivieri I, Scarano E, D'Angelo S, *et al.* Dactylitis. In: FitzGerald O and Gladman D (eds) *Oxford textbook of psoriatic arthritis*. Oxford: Oxford University Press, 2019, pp. 117–122.
- McGonagle D, Tan AL, Watad A, *et al.* Pathophysiology, assessment and treatment of psoriatic dactylitis. *Nat Rev Rheumatol* 2019; 15: 113–122.
- Rothschild BM, Pingitore C and Eaton M. Dactylitis: implications for clinical practice. *Semin Arthritis Rheum* 1998; 28: 41–47.
- Siegel EL, Orbai AM and Ritchlin CT. Targeting extra-articular manifestations in PsA: a closer look at enthesitis and dactylitis. *Curr Opin Rheumatol* 2015; 27: 111–117.
- Taylor W, Gladman D, Helliwell P, *et al.* Classification criteria for psoriatic arthritis: development of new criteria from a large international study. *Arthritis Rheum* 2006; 54: 2665–2673.
- D'Angelo S, Mennillo GA, Cutro MS, *et al.* Sensitivity of the classification of psoriatic arthritis criteria in early psoriatic arthritis. *J Rheumatol* 2009; 36: 368–370.
- Veale D, Rogers S and Fitzgerald O. Classification of clinical subsets in psoriatic arthritis. *Br J Rheumatol* 1994; 33: 133–138.
- Yamamoto T. Optimal management of dactylitis in patients with psoriatic arthritis. *Open Access Rheumatol* 2015; 7: 55–62.
- Kaeley GS, Eder L, Aydin SZ, *et al.* Dactylitis: a hallmark of psoriatic arthritis. *Semin Arthritis Rheum* 2018; 48: 263–273.
- Vieira-Sousa E and Alves P. Dactylitis: more than just arthritis. *Acta Reumatol Port* 2015; 40: 210–212.
- Olivieri I, Barozzi L, Favaro L, *et al.* Dactylitis in patients with seronegative spondylarthropathy. Assessment by ultrasonography and magnetic resonance imaging. *Arthritis Rheum* 1996; 39: 1524–1528.
- Olivieri I, Barozzi L, Pierro A, *et al.* Toe dactylitis in patients with spondyloarthropathy: assessment by magnetic resonance imaging. *J Rheumatol* 1997; 24: 926–930.
- Olivieri I, Scarano E, Padula A, *et al.* Fast spin echo-T2-weighted sequences with fat saturation in toe dactylitis of spondyloarthritis. *Clin Rheumatol* 2008; 27: 1141–1145.
- Olivieri I, Montaruli M, Scarano E, *et al.* Usefulness of plain film radiography in the diagnosis of dactylitis by history-taking. *J Rheumatol* 2005; 32: 1379.
- Kavanaugh A, Helliwell P and Ritchlin CT. Psoriatic arthritis and burden of disease: patient perspectives from the population-based Multinational Assessment of Psoriasis and Psoriatic Arthritis (MAPP) survey. *Rheumatol Ther* 2016; 3: 91–102.
- D'Angelo S, Palazzi C, Gilio M, *et al.* Improvements in diagnostic tools for early detection of psoriatic arthritis. *Expert Rev Clin Immunol* 2016; 12: 1209–1215.
- Tinazzi I, McGonagle D, Zabotti A, *et al.* Comprehensive evaluation of finger flexor tendon enthesal soft tissue and bone changes by ultrasound can differentiate psoriatic arthritis and rheumatoid arthritis. *Clin Exp Rheumatol* 2018; 36: 785–790.
- Kane D, Greaney T, Bresnihan B, *et al.* Ultrasonography in the diagnosis and management of psoriatic dactylitis. *J Rheumatol* 1999; 26: 1746–1751.

20. Wakefield RJ, Emery P and Veale D. Ultrasonography and psoriatic arthritis. *J Rheumatol* 2000; 27: 1564–1565.
21. Olivieri I, D'Angelo S, Scarano E, *et al.* What is the primary lesion in SpA dactylitis? *Rheumatology* 2008; 47: 561–562.
22. Healy PJ, Groves C, Chandramohan M, *et al.* MRI changes in psoriatic dactylitis – extent of pathology, relationship to tenderness and correlation with clinical indices. *Rheumatology* 2008; 47: 92–95.
23. Mandl P, Navarro-Compán V, Terslev L, *et al.* EULAR recommendations for the use of imaging in the diagnosis and management of spondyloarthritis in clinical practice. *Ann Rheum Dis* 2015; 74: 1327–1339.
24. Antoni CE, Kavanaugh A, Kirkham B, *et al.* Sustained benefits of infliximab therapy for dermatologic and articular manifestations of psoriatic arthritis: results from the infliximab multinational psoriatic arthritis controlled trial (IMPACT). *Arthritis Rheum* 2005; 52: 1227–1236.
25. Ritchlin C, Rahman P, Kavanaugh A, *et al.* Efficacy and safety of the anti-IL-12/23 p40 monoclonal antibody, ustekinumab, in patients with active psoriatic arthritis despite conventional non-biological and biological anti-tumour necrosis factor therapy: 6-month and 1-year results of the phase 3, multicentre, double-blind, placebo-controlled, randomised PSUMMIT 2 trial. *Ann Rheum Dis* 2014; 73: 990–999.
26. Helliwell PS, Firth J, Ibrahim GH, *et al.* Development of an assessment tool for dactylitis in patients with psoriatic arthritis. *J Rheumatol* 2005; 32: 1745–1750.
27. Mease PJ, Fleischmann R, Deodhar AA, *et al.* Effect of certolizumab pegol on signs and symptoms in patients with psoriatic arthritis: 24-week results of a Phase 3 double-blind randomised placebo-controlled study (RAPID-PsA). *Ann Rheum Dis* 2014; 73: 48–55.
28. Ferguson EG and Coates LC. Optimisation of rheumatology indices: dactylitis and enthesitis in psoriatic arthritis. *Clin Exp Rheumatol* 2014; 32(5, Suppl. 85): S113–S117.
29. Healy PJ and Helliwell PS. Measuring dactylitis in clinical trials: which is the best instrument to use? *J Rheumatol* 2007; 34: 1302–1306.
30. Coates LC, Kavanaugh A, Mease PJ, *et al.* Group for research and assessment of psoriasis and psoriatic arthritis 2015 treatment recommendations for psoriatic arthritis. *Arthritis Rheumatol* 2016; 68: 1060–1071.
31. Vieira-Sousa E, Alves P, Rodrigues AM, *et al.* GO-DACT: a phase 3b randomised, double-blind, placebo-controlled trial of GOLimumab plus methotrexate (MTX) versus placebo plus MTX in improving DACTylitis in MTX-naive patients with psoriatic arthritis. *Ann Rheum Dis* 2020; 79: 490–498.
32. D'Angelo S, Carriero A, Gilio M, *et al.* Safety of treatment options for spondyloarthritis: a narrative review. *Expert Opin Drug Saf* 2018; 17: 475–486.
33. D'Angelo S, Cantini F, Ramonda R, *et al.* Effectiveness of adalimumab for the treatment of psoriatic arthritis: an Italian real-life retrospective study. *Front Pharmacol* 2019; 10: 1497.
34. Ramonda R, Lorenzin M, Carriero A, *et al.* Effectiveness and safety of secukinumab in 608 patients with psoriatic arthritis in real life: a 24-month prospective, multicentre study. *RMD Open* 2021; 7: e001519.
35. Gossec L, Baraliakos X, Kerschbaumer A, *et al.* EULAR recommendations for the management of psoriatic arthritis with pharmacological therapies: 2019 update. *Ann Rheum Dis* 2020; 79: 700–712.
36. Gershon SL. Injecting joints and tendons with steroids. *Can Fam Physician* 1983; 29: 2184–2188.
37. Jacobs JW and Michels-van Amelsfort JM. How to perform local soft-tissue glucocorticoid injections? *Best Pract Res Clin Rheumatol* 2013; 27: 171–194.
38. Catalano LW 3rd, Glickel SZ, Barron OA, *et al.* Effect of local corticosteroid injection of the hand and wrist on blood glucose in patients with diabetes mellitus. *Orthopedics* 2012; 35: e1754–e1758.
39. Mills SP, Charalambous CP and Hayton MJ. Bilateral rupture of the extensor pollicis longus tendon in a professional goalkeeper following steroid injections for extensor tenosynovitis. *Hand Surg* 2009; 14: 135–137.
40. Nguyen ML and Jones NF. Rupture of both the abductor pollicis longus and extensor pollicis brevis tendons after steroid injection for de quervain tenosynovitis. *Plast Reconstr Surg* 2012; 129: 883e–886e.
41. Unverferth LJ and Olix ML. The effect of local steroid injections on tendon. *J Sports Med* 1973; 1: 31–37.
42. Cigna E, Özkan Ö, Mardini S, *et al.* Late spontaneous rupture of the extensor pollicis longus tendon after corticosteroid injection for

- flexor tenosynovitis. *Eur Rev Med Pharmacol Sci* 2013; 17: 845–848.
43. Gray RG, Kiem IM and Gottlieb NL. Intratendon sheath corticosteroid treatment of rheumatoid arthritis-associated and idiopathic hand flexor tenosynovitis. *Arthritis Rheum* 1978; 21: 92–96.
  44. Stephens MB, Beutler AI and O'Connor FG. Musculoskeletal injections: a review of the evidence. *Am Fam Physician* 2008; 78: 971–976.
  45. Gray RG, Tenenbaum J and Gottlieb NL. Local corticosteroid injection treatment in rheumatic disorders. *Semin Arthritis Rheum* 1981; 10: 231–254.
  46. Urits I, Smoots D, Anantuni L, *et al.* Injection techniques for common chronic pain conditions of the hand: a comprehensive review. *Pain Ther* 2020; 9: 129–142.
  47. Sheikh E, Peters JD, Sayde W, *et al.* A prospective randomized trial comparing the effectiveness of one versus two (staged) corticosteroid injections for the treatment of stenosing tenosynovitis. *Hand* 2014; 9: 340–345.
  48. Peters-Veluthamaningal C, Winters JC, Groenier KH, *et al.* Corticosteroid injections effective for trigger finger in adults in general practice: a double-blinded randomised placebo controlled trial. *Ann Rheum Dis* 2008; 67: 1262–1266.
  49. Usmani RH, Abrams SS and Merrell GA. Establishing an efficient care paradigm for trigger finger. *J Hand Surg Asian Pac Vol* 2018; 23: 356–359.
  50. Merry SP, O'Grady JS and Boswell CL. Trigger finger? Just shoot! *J Prim Care Community Health* 2020; 11: 2150132720943345.
  51. Peters SE, Laxer RM, Connolly BL, *et al.* Ultrasound-guided steroid tendon sheath injections in juvenile idiopathic arthritis: a 10-year single-center retrospective study. *Pediatr Rheumatol Online J* 2017; 15: 22.
  52. Carlson CS Jr and Curtis RM. Steroid injection for flexor tenosynovitis. *J Hand Surg Am* 1984; 9: 286–287.
  53. Akhtar S and Burke FD. Study to outline the efficacy and illustrate techniques for steroid injection for trigger finger and thumb. *Postgrad Med J* 2006; 82: 763–766.
  54. Gutierrez M, Di Matteo A, Rosemffet M, *et al.* Short-term efficacy to conventional blind injection versus ultrasound-guided injection of local corticosteroids in tenosynovitis in patients with inflammatory chronic arthritis: a randomized comparative study. *Joint Bone Spine* 2016; 83: 161–166.
  55. Hmamouchi I, Bahiri R, Srifi N, *et al.* A comparison of ultrasound and clinical examination in the detection of flexor tenosynovitis in early arthritis. *BMC Musculoskelet Disord* 2011; 12: 91.
  56. Lopes RV, Furtado RN, Parmigiani L, *et al.* Accuracy of intra-articular injections in peripheral joints performed blindly in patients with rheumatoid arthritis. *Rheumatology* 2008; 47: 1792–1794.
  57. Luz KR, Furtado RN, Nunes CC, *et al.* Ultrasound-guided intra-articular injections in the wrist in patients with rheumatoid arthritis: a double-blind, randomised controlled study. *Ann Rheum Dis* 2008; 67: 1198–1200.
  58. Aly AR, Rajasekaran S and Ashworth N. Ultrasound-guided shoulder girdle injections are more accurate and more effective than landmark-guided injections: a systematic review and meta-analysis. *Br J Sports Med* 2015; 49: 1042–1049.
  59. Hashiuchi T, Sakurai G, Morimoto M, *et al.* Accuracy of the biceps tendon sheath injection: ultrasound-guided or unguided injection? A randomized controlled trial. *J Shoulder Elbow Surg* 2011; 20: 1069–1073.
  60. Zhang J, Ebraheim N and Lause GE. Ultrasound-guided injection for the biceps brachii tendinitis: results and experience. *Ultrasound Med Biol* 2011; 37: 729–733.
  61. Taras JS, Raphael JS, Pan WT, *et al.* Corticosteroid injections for trigger digits: is intrasheath injection necessary? *J Hand Surg Am* 1998; 23: 717–722.
  62. Cecen GS, Gulabi D, Saglam F, *et al.* Corticosteroid injection for trigger finger: blinded or ultrasound-guided injection? *Arch Orthop Trauma Surg* 2015; 135: 125–131.
  63. Mardani-Kivi M, Karimi-Mobarakeh M, Babaei Jandaghi A, *et al.* Intra-sheath versus extra-sheath ultrasound guided corticosteroid injection for trigger finger: a triple blinded randomized clinical trial. *Phys Sportsmed* 2018; 46: 93–97.
  64. Howard LD Jr, Pratt DR and Bunnell S. The use of compound F (hydrocortone) in operative and non-operative conditions of the hand. *J Bone Joint Surg Am* 1953; 35-A: 994–1002.
  65. Cushman DM, Carefoot A, Lisenby S, *et al.* A systematic review of the efficacy of corticosteroid injections of tendon sheaths, excluding stenosing tenosynovitis of the wrist and hand. *Am J Phys Med Rehabil* 2021; 100: 683–688.

66. Zhuang T, Wong S, Aoki R, *et al.* A cost-effectiveness analysis of corticosteroid injections and open surgical release for trigger finger. *J Hand Surg Am* 2020; 45: 597–609.e597.
67. Lapidus PW and Guidotti FP. Stenosing tenovaginitis of the wrist and fingers. *Clin Orthop Relat Res* 1972; 83: 87–90.
68. Ammitzbøll-Danielsen M, Østergaard M, Fana V, *et al.* Intramuscular versus ultrasound-guided intratenosynovial glucocorticoid injection for tenosynovitis in patients with rheumatoid arthritis: a randomised, double-blind, controlled study. *Ann Rheum Dis* 2017; 76: 666–672.
69. Girolimetto N, Macchioni P, Citriniti G, *et al.* Effectiveness of steroid injection for hand psoriatic dactylitis: results from a multicentre prospective observational study. *Clin Rheumatol* 2020; 39: 3383–3392.
70. Di Geso L, Filippucci E, Meenagh G, *et al.* CS injection of tenosynovitis in patients with chronic inflammatory arthritis: the role of US. *Rheumatology* 2012; 51: 1299–1303.
71. Girolimetto N, Macchioni P, Possemato N, *et al.* Musculoskeletal ultrasound in monitoring clinical response to treatment in acute symptomatic psoriatic dactylitis: results from a multicentre prospective observational study. *J Clin Med* 2020; 9: 3127.

Visit SAGE journals online  
[journals.sagepub.com/  
home/tab](https://journals.sagepub.com/home/tab)

 SAGE journals