

Clinical Aspects, Diagnosis and Management of Cerebral Vein and Dural Sinus Thrombosis: A Literature Review

Abdulla Al-Sulaiman

Department of Neurology, College of Medicine, Imam Abdulrahman Bin Faisal University, Dammam, Saudi Arabia

Abstract

Cerebral vein and dural sinus thrombosis (CVST) is an uncommon cause of stroke, but its delayed diagnosis carries significant morbidity and mortality. Several studies have reported higher incidence of CVST than that previously reported. The clinical presentation of CVST varies and can be atypical. Advancement in neuroimaging modalities has made it possible to make an early diagnosis and initiate management with a wide range of therapeutic options, including direct oral anticoagulants and endovascular treatment. This narrative review summarizes the epidemiology, clinical aspects, diagnosis and management of CVST.

Keywords: Anticoagulation, cerebral vein, direct oral anticoagulants, dural sinus, neuroimaging, thrombosis

Address for correspondence: Dr. Abdulla Al-Sulaiman, Department of Neurology, College of Medicine, Imam Abdulrahman Bin Faisal University, Dammam, Saudi Arabia.

E-mail: aalsulaiman@iau.edu.sa

Received: 28-01-2019 **Revised:** 10-04-2019 **Accepted:** 16-07-2019 **Published:** 28-08-2019

INTRODUCTION

Cerebral vein and dural sinus thrombosis (CVST) is an uncommon cause of stroke, with an annual incidence of about 5/million, most commonly affecting those in younger age groups and females.^[1-3] Its clinical manifestations vary, and thus can delay the diagnosis. The most common symptom is headache,^[4] followed by focal lobar syndrome, seizures, encephalopathy and cranial nerve palsies.^[5] In addition to gender and age, the common risk factors of CVST are thrombophilia, pregnancy, postpartum period, infections and malignancy.^[6-8] In the recent past, computed tomography (CT) and magnetic resonance imaging (MRI) are increasingly being used, which has helped physicians to diagnose CVST more frequently even in patients with atypical presentation.^[3] The mainstay of treatment is recanalization of occluded sinus or vein via antithrombotic therapy or endovascular

treatment, while adequate symptomatic treatment is required for headache, seizures and intracranial hypertension. Management of the underlying etiology and complications is of utmost importance.^[7] Accordingly, this review was conducted to provide an update of the epidemiology, clinical aspects, diagnosis and management of CVST, including discussing the recent European Stroke Organization (ESO) guidelines and the interventional management of such patients, as well as highlights areas of future studies.

For this narrative review, the author searched PubMed, Web of Science and Google Scholar until 2019 using the keywords “cerebral venous sinus thrombosis,” “dural venous sinus thrombosis,” and “diagnosis and management of cerebral venous thrombosis,” and all relevant and current studies were included in the following review.

This is an open access journal, and articles are distributed under the terms of the Creative Commons Attribution-NonCommercial-ShareAlike 4.0 License, which allows others to remix, tweak, and build upon the work non-commercially, as long as appropriate credit is given and the new creations are licensed under the identical terms.

For reprints contact: reprints@medknow.com

How to cite this article: Al-Sulaiman A. Clinical aspects, diagnosis and management of cerebral vein and dural sinus thrombosis: A literature review. Saudi J Med Med Sci 2019;7:137-45.

Access this article online	
Quick Response Code:	Website: www.sjmms.net
	DOI: 10.4103/sjmms.sjmms_22_19

EPIDEMIOLOGY

Incidence

CVST comprises 0.5%–3% of all strokes.^[2] The current epidemiological data on CVST are scarce and vary between countries. Previously, the annual incidence of CVST in adults and children has been estimated as 3–4 and 7/million, respectively.^[8] In 1995, a study found that in Riyadh, Saudi Arabia, the annual incidence of CVST was <10/million.^[9] However, recently, several countries have reported higher incidence: in Iran, the incidence of CVST has been reported as 12.3–13.5/million,^[10,11] whereas in the Netherlands and South Australia, it has been reported as 13.2 and 15.7/million, respectively.^[12,13] These higher incidences can be due to better methods being used for making a diagnosis, such as neurovascular imaging, as well as due to the fact of females more commonly using hormonal contraceptives, which is a major risk factor for CVST; however, environmental and genetic factors may also be the contributing factors and should be investigated.

Gender and age

Although few studies have reported no gender-related differences,^[13] most studies have shown females to be more frequently affected by CVST than males.^[1,3,14–16] A recent systematic analysis validated the female preponderance by demonstrating that the proportion of female patients increased from 54.8% in 1966 to 81–69.8% in 2001–14,^[17] which could be explained by more frequent use of oral contraceptives (OCs) by females in the recent past. In terms of age, in 2004, Ferro *et al.*^[1] reported the median age of CVST diagnosis as 37 years. In two other studies, the median age was found to be 49 years (range: 40–61 years)^[13] and 30 years (range: 6–76 years).^[18] Notably, the age of CVST patients is lower than that of patients with arterial strokes.^[3]

CLINICAL MANIFESTATIONS

The clinical manifestations of CVST are diverse and depend on the location of thrombus, duration of illness and the associated brain parenchymal changes.^[2] Broadly, it can be categorized into the following four major syndromes: (1) intracranial hypertension, (2) focal cerebral dysfunction, (3) encephalopathy and (4) seizures with or without focal neurological deficits (FNDs).^[19]

Headache

Headache is the most common symptom, affecting about 70%–90% of CVST patients.^[1,9,16,20–24] Headache can be explained by the stretching of nerve fibers in vessel wall due to increased intracranial pressure (ICP), the release of pro-inflammatory mediators from the clot and/or subarachnoid hemorrhage (SAH).^[25,26]

Isolated headache is reported in up to 25%–40% of CVST patients. Usually, the headache is diffuse, but, sometimes, may mimic migraine and thunderclap/cluster headaches.^[27,28] If caused by increased ICP, headaches can be associated with transient visual impairment or papilledema.^[25] The presence of seizures or other FNDs along with headache may suggest an underlying venous infarction.^[29] In some cases, an increased ICP can occur in isolation and may be mistaken as idiopathic intracranial hypertension.^[1,30] These diversities in headache pose a diagnostic challenge for treating physicians.

Focal neurological deficits

The presence of FNDs may help in the localization of thrombus.^[1,27] FNDs such as hemiparesis, monoparesis, aphasia, visual field defects including cortical blindness, cranial nerve palsies or hemisensory disturbances can present in up to 18%–72% of patients.^[16,20,31] The most common FNDs are motor deficits (19%–39% of the patients) and aphasia (19%–24% of the patients).^[1,31,32] Transient ischemic attack has also been noted in few cases.^[1,2,28,33,34]

Solitary or multiple cranial nerves can be involved, which can sometimes be the sole presentation of CVST.^[32] The involvement of III, IV, V, VI, VII, VIII, IX, X and XII cranial nerves has been reported.^[28] Isolated sixth nerve palsy without intracranial hypertension has been reported with inferior petrosal sinus thrombosis^[35] and transverse sinus thrombosis.^[36] Isolated trigeminal neuropathy^[37] and facial neuropathy^[38,39] have also been reported. In a study by Duman *et al.*,^[20] cranial nerve palsies were detected in 11% of patients with CVST.

Visual field defects have been reported in 10.8%–26.5% of patients with CVST.^[16,20] If FNDs are accompanied by headache, the diagnosis may be easier, but when occurring in isolation, the diagnosis may be delayed.

Seizures

Seizures are relatively common in CVST, affecting about 20%–47% of the patients.^[16,20,31,40,41] In nearly half of the cases, seizure remains focal, but can also generalize and even lead to status epilepticus.^[8] Seizures are more frequently observed in patients with supratentorial hemorrhagic lesions, FNDs and thrombosis of superior sagittal sinus (SSS) or cortical veins.^[1,42]

Papilledema and altered consciousness

Papilledema is a common feature in CVST, affecting 28%–80% of CVST patients.^[1,9,16,31] However, it is rare in patients without headache.^[1] In one study, papilledema was

found to be associated with a median admission delay of 13 days after the onset of symptoms.^[43]

Altered level of consciousness is a well-reported feature. It was observed in 17.8% and 14% of the patients in the VENOST^[20] and ISCVT^[1] studies, respectively. de Bruijn *et al.*^[31] found impaired consciousness (Glasgow Coma Scale [GCS] <14) in 39% and coma (GCS <8) in 15% of the cases and reported coma as an independent predictor of poor outcome. It is more frequently observed in patients having deep-venous system thrombosis (DVST);^[2] DVST can lead to bilateral thalamic lesions that can manifest as delirium or amnesia.^[44]

Less common presentations

Few cases of nonaneurysmal SAH secondary to CVST have been reported.^[45] In one study, ten patients were found to have SAH. Localized SAH, particularly when confined to the parasagittal or dorsolateral convexity of the brain, may suggest the underlying CVST.^[46] Psychiatric manifestations can sometimes be the only presentation, and diagnosis is difficult in such cases.^[47-49]

ETIOLOGY AND RISK FACTORS

The etiology of CVST is often multifactorial, and thus identifying one risk factor should not limit the physicians from carrying out complete workup to determine other possible factors.^[25] In the ISCVT study, 44% of patients were identified as having more than one risk factor.^[1] Although >100 causative factors have been described in literature, the etiology of CVST remains unidentified in 13%–20% of the cases.^[1,16,50] Table 1 summarizes the key etiologies and risk factors of CVST, with prothrombotic conditions being the leading causes.^[51]

Prothrombotic conditions (congenital/acquired)

In a recent study from India, prothrombotic conditions were the cause of CVST in 62.8% of patients.^[18] Prothrombotic genetic factors have been recognized to play a pivotal role in the pathogenesis of CVST. Hyperhomocysteinemia is a known risk factor for venous thrombosis, and the role of MTHFR/C677T mutation has also been studied.^[52] In a meta-analysis, six genes with six polymorphisms were identified; of these, factor V Leiden/G1619A and prothrombin/G20210A were found to be significantly associated with the risk of CVST in adults, while MTHFR/C677T was also found to be associated. Polymorphisms in plasminogen activator inhibitor-1, protein Z and Janus kinase-2 did not show any significant association.^[53]

Female-specific risk factors

Usage of OCs, pregnancy and peripartum period are the female-specific factors that increase their risk for

Table 1: Common risk factors for cerebral venous sinus thrombosis^[3,8,55]

Prothrombotic conditions
Genetic prothrombotic conditions
Protein S, C, antithrombin deficiencies
Factor V Leiden and prothrombin G20210A mutations
Homocysteinemia caused by genetic mutations in MTHFR gene
Acquired prothrombotic conditions
Antiphospholipid syndrome
Hyperhomocysteinemia
Nephrotic syndrome
Cyanotic congenital heart disease
Pregnancy and puerperium
Drugs with prothrombotic action
Hormone replacement therapy
Androgens
Medroxyprogesterone acetate
L-asparaginase, cyclosporine
Tamoxifen
Steroids
Intravenous immunoglobulin
Lithium
Sildenafil
Infections
Central nervous system
Meningitis, empyema
Ear, sinus, mouth, face and neck
Otitis, mastoiditis, tonsillitis, stomatitis, sinusitis and cellulitis
Systemic infections
Sepsis, endocarditis, tuberculosis, human immunodeficiency virus and malaria
Malignancy
Central nervous system (meningioma)
Solid tumor outside the central nervous system
Hematological (leukemias, lymphomas)
Hematological condition
Anemias (sickle cell disease and trait, iron deficiency and folic acid deficiency) paroxysmal nocturnal hemoglobinuria
polycythemia (primary or secondary), thrombocytopenia (primary or secondary)
Inflammatory diseases
Behçet's disease, systemic lupus erythematosus, Sjögren's syndrome, Wegener's granulomatosis, temporal arteritis
thromboangiitis, obliterans, IBD and sarcoidosis
Physical precipitants and procedures
Head trauma, lumbar puncture (intracranial hypotension), myelography, intrathecal medications, spinal anesthesia, radical neck surgery, irradiation, neurosurgical procedures and jugular and subclavian catheters
Other miscellaneous conditions
Dehydration, diabetic ketoacidosis, exercise (needs to be established) and obesity (in women using OCs)

Ferro and Canhão.^[3] Copyrights reserved to Springer Nature. Reproduced and adapted here after obtaining license for reuse from publisher. MTHFR – Methylene tetrahydrofolate reductase; OCs – Oral contraceptives; IBD – Inflammatory bowel disease

CVST.^[1,51,54] In the ISCVT study, estrogen (in OCs, hormone replacement therapy and pregnancy) was identified as a risk factor in 65% of the females.^[1] Women undergoing *in vitro* fertilization are also at an increased risk of CVST.^[55] In addition to OCs, other modes of hormonal contraception such as transdermal patch and vaginal ring are also associated with the increased risk of CVST.^[56] In pregnant women, the highest risk has been observed in the third trimester and in the postpartum period.^[57]

Infections

Infection is an important cause of CVST, although it has become less prominent over the years.^[1] About 8% of the patients in the VENOST study and 20% of those in a study from India had CVST due to infection.^[18,20] Further, low-to-middle-income countries have a higher frequency of this etiology, ranging from 18% to 34% of all CVST cases.^[22,51,58,59] In Saudi Arabia, this etiology has been reported to account for 7%–9.9% of CVST cases.^[9,16,24]

Malignancy and anticancer medications

In the VENOST study, 5.2% of the patients were reported to have malignancy-related CVST. Further, this cause of CVST was found in statistically significantly higher number of patients aged >50 years ($P < 0.001$), and breast cancer and hematological malignancies were the most common malignancies.^[20] Other studies have reported CVST due to malignancy in 2.3%,^[18] 4.5%,^[24] 7.4%,^[1] and 9.9% of the patients.^[16] In addition to malignancies, treatment with anticancer medications such as L-asparaginase has also been found to be a risk factor of CVST.^[3]

Inflammatory bowel diseases

Inflammatory bowel diseases are another well-recognized risk factor for CVST, found in 1.6% of the cases.^[1] As compared to Crohn's disease, ulcerative colitis is more likely to cause CVST, and is more frequent in young women.^[60] Ferro *et al.*^[1] found Behçet's disease to be a rare cause of CVST, accounting for only 1% of the patients. However, in a recent study from Turkey, this etiology accounted for 9.4% of the patients.^[20] In Saudi Arabia, there have been vastly different findings: Daif *et al.*^[9] reported that Behçet's disease was the underlying etiology in 25% of the patients, whereas Algahtani *et al.*^[16] found it to be the cause of CVST in only 1 of the 111 patients (0.9%).

Lifestyle causes

The association between CVST and lifestyle-related factors such as obesity, exercise and smoking has been studied. Smoking has not been found to be significantly associated with CVST.^[61,62] Zuurbier *et al.*^[63] found that for females using OCs, being obese and overweight increases the risk for CVST. Interestingly, for females who did not use OCs, there was no such association.^[63] Finally, although a case report has described recurrent CVST in relation to marathon training sessions, further studies are required to establish an association between strenuous exercise/physical activity and CVST.^[64]

DIAGNOSIS OF CVST

The diagnosis of CVST should be made on clinical ground and supportive imaging studies and should always be considered in patients with the following:^[8]

1. New onset of unusual headache
2. Symptoms of FNDs in the absence of known vascular risk factors
3. Intracranial hypertension
4. Evidence of hemorrhagic infarctions on neuroimaging, especially if the infarctions are multiple and not following arterial vascular territories.

Laboratory investigations

Detailed laboratory investigations are important for determining the underlying cause of CVST, and thus initiating appropriate treatments to avoid recurrence. However, routine screening for thrombophilia and malignancy has been found to have no effect on the disease outcome,^[65] and was accordingly not recommended in the ESO guideline for the diagnosis and management of CVST.

Role of D-Dimer in the diagnosis of CVST

Measuring serum D-dimer levels before neuroimaging is beneficial in patients presenting with headache suggestive of CVST. Kosinski *et al.*^[66] found that D-dimer levels in patients with CVST are positively correlated with the extent of thrombosis and negatively correlated with the duration of symptoms. However, D-dimer measurement is not recommended in patients presenting with isolated headache and when the duration of symptoms is >1 week, as these are associated with false-negative results.^[65]

Neuroradiological investigations

CT scanning, CT venography (CTV), MRI, magnetic resonance venogram (MRV) and digital subtraction angiography (DSA) are the currently available neuroimaging modalities for the diagnosis of CVST. CTV and MRV provide comparable results in the evaluation of CVST, and are thus the choice of technique depending on the patient's clinical situation, institutional expertise and resources available.^[66]

Computed tomography scanning, venography and perfusion imaging

CT scan of the brain is often the first-utilized imaging technique in an emergency setting. It helps to rule out other causes such as cerebral neoplasm and subdural hematoma and can show parenchymal changes suggestive of CVST. It should be noted that noncontrast CT scan can be normal in 25%–30% of CVST cases.^[2]

CVST can be diagnosed on CT by direct and indirect signs. Direct signs can be false-positive results for dehydration, elevated hematocrit and reduced flow.^[51,67] The direct signs of CVST (i.e., seeing thrombus within the involved venous sinus or veins) are string/cord sign on plain CT (seen in cortical veins thrombosis as hyperdense, elongated images);

dense triangle sign (corresponds to thrombus in the posterior part of SSS) and empty delta sign (seen in contrast-enhanced CT scan when there is an intraluminal filling defect due to thrombus surrounded by contrast in SSS).^[67]

Indirect signs are erosion and changes in mastoid and middle ear in infective lateral venous sinus thrombosis; reduced ventricular size due to increased ICP; obstructive hydrocephalus; hemorrhagic and nonhemorrhagic infarctions; contrast enhancement of falx and tentorium; bilateral thalamic edema; micro-juxtacortical hemorrhages and cerebral convexity SAH.^[51,67]

CTV can confirm the diagnosis of CVST by showing the filling defect, enhancement of venous wall and augmented collateral venous drainage.^[68] A Hounsfield unit of >70 has been found to be highly specific for the diagnosis of acute CVST.^[69] CT and CTV findings of patients with CVST are shown in Figures 1 and 2. Whole-brain CT perfusion imaging can be supportive in the diagnosis of CVST by detecting perfusion abnormalities that correspond to venous rather than arterial territorial infarctions. Mokin *et al.*,^[70] in their study on ten patients with CVST who had whole-brain (320-detector-row) CT perfusion imaging along with CTV, found that all perfusion abnormalities were adjacent to the thrombosed sinuses and were different in pattern from arterial territorial infarctions. CT perfusion imaging was also identified as an important prognostic tool by Gupta *et al.*,^[71] who concluded that it can be utilized to assess the clinical outcome.

Magnetic resonance imaging/magnetic resonance venogram

MRI has greater sensitivity in detecting brain parenchymal changes, blood clot, blood flow and petechial

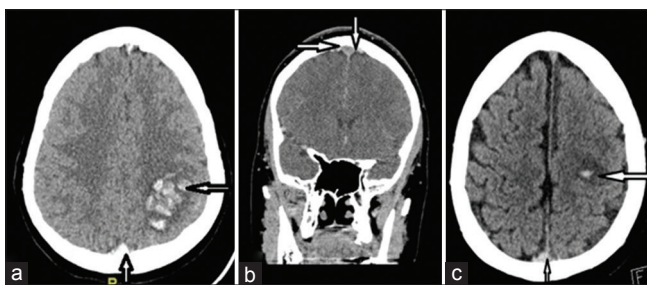


Figure 1: Radiological findings in computed tomography and computed tomography venography of patients with CVST: (a) Plain noncontrast computed tomography scan axial view showing dense triangle sign and left parietal heterogenous hemorrhage in a patient with superior sagittal sinus thrombosis. (b) Coronal image of computed tomography venography of the same patient (a) showing filling defect in superior sagittal sinus. (c) Plain noncontrast computed tomography scan axial view of another patient showing dense triangle sign and left parietal small hemorrhage surrounded by hypodensity in a patient with superior sagittal sinus (these two patients were admitted under our care and relevant permissions were obtained for the use of these images)

hemorrhages.^[72] A study protocol should include diffusion-weighted images (DWIs), fluid-attenuated inversion recovery (FLAIR) images, T1 sequence (with and without contrast), T2 sequence and venography. MRV should include time-of-flight and phase-contrast sequences.^[72] Single-slice phase-contrast angiography can be carried out in <30 s, and has been found to have a high sensitivity and specificity.^[73]

Patterns of venous infarction seen on MRI are different from those of arterial strokes. It can be often bilateral, which helps distinguish CVST from arterial territorial infarcts. Conventional MRI sequences including T1-, T2- and T2*-weighted gradient echo (GRE); susceptibility-weighted images; FLAIR and DWI are more accurate than unenhanced CT scan. For diagnosing CVST, these techniques have an overall sensitivity of 72%–84% and a specificity of 90%–95%.^[74] Contrast-enhanced three-dimensional GRE T1-weighted imaging has a 93% sensitivity and a 100% specificity in diagnosing CVST, and is considered even more accurate than the conventional MRI sequences.^[75]

Digital subtraction angiography

In the recent past, the use of invasive angiography as a diagnostic investigation has declined significantly. DSA is used in cases where noninvasive imaging modalities are inconclusive, to exclude dural fistula or when chemical/mechanical endovascular thrombolytic therapy is being considered.

Based on the above descriptions, the following are the summarization of recommendations for selecting diagnostic imaging modalities in cases with CVST:

- MRV and CTV can be used as a reliable alternative to DSA for confirming the diagnosis^[65]
- CTV can be used as a reliable alternative to MRV for confirming the diagnosis^[65]

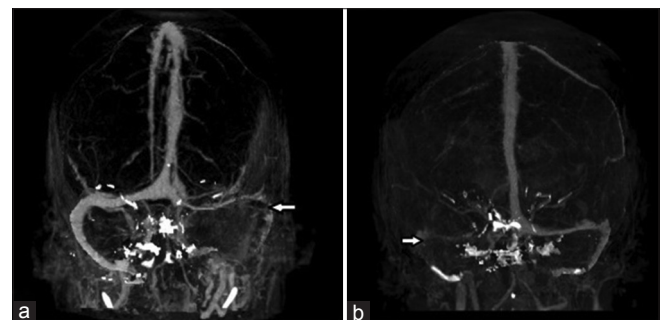


Figure 2: Maximum intensity projection images of computed tomography venography showing (a) nonvisualization of left transverse and sigmoid sinus and (b) nonvisualization of left transverse and sigmoid sinus

- A combination of MRI/MRV or CT/CTV studies should be performed in suspected cases^[76]
- DSA is indicated only when the diagnosis cannot be reliably established with noninvasive imaging modalities.^[76]

MANAGEMENT OF CVST

The mainstay of treatment is stabilizing the patient, initiating anticoagulation therapy and treating the underlying cause when presenting as infection and complications. Highlights from the 2017 ESO recommendations^[65] for the management of CVST are summarized in Table 2.

Anticoagulation

Although systemic anticoagulation is considered the first-line treatment in the management of CVST,^[2] its use is controversial especially in patients likely to have poor outcome and in those with cerebral hemorrhage. However, both the American Heart Association/American Stroke Association (AHA/ASA) and the European Federation of Neurological Societies recommend that anticoagulation therapy should be initiated in CVST patients even if parenchymal hemorrhage is identified.^[77]

Selection of anticoagulant is an ongoing debate, but it is recommended to initiate low-molecular-weight heparin (LMWH) or unfractionated heparin (UFH) therapy at the earliest. A randomized controlled trial demonstrated

that patients receiving LMWH had significantly lower mortality than those receiving UFH.^[15] In situations where anticoagulation is contraindicated or the patient continues to deteriorate despite anticoagulation, chemical or mechanical endovascular thrombolytic therapy can be considered.^[8] However, strong evidence for recommending endovascular treatment is yet lacking.^[78]

Following the acute-phase treatment, long-term anticoagulants such as Vitamin K antagonist (warfarin) should be continued with a target to achieve an international normalized ratio of 2–3.^[79] Currently, direct oral anticoagulants (DOACs) are gaining attention as potential therapy in CVST. In the acute-phase treatment, DOACs have been found to be comparable with warfarin in preventing the recurrence of venous thromboembolism.^[80] The advantages of DOACs over Vitamin K antagonists are rapid onset of action, fewer drug interactions and relatively predictable pharmacokinetics. Therefore, DOACs can be considered as potential therapeutic option in patients for whom warfarin cannot be considered despite being recommended as a first-line treatment.^[81,82] Although DOACs have not been recommended, off-label use is being practiced by physicians.^[83] Currently, three commonly used DOACs in the treatment of CVST are apixaban, rivaroxaban (factor Xa inhibitors) and dabigatran (direct thrombin inhibitor).^[84] In a recent study, Covut *et al.*^[85]

Table 2: Summary of highlights from European Stroke Organization recommendations related to anticoagulation for the management of cerebral vein and dural sinus thrombosis^[69]

Management consideration	Recommendations
Anticoagulation in acute-phase treatment of CVST	Treatment of adult patients with acute CVST with heparin in therapeutic dosage is recommended, including in those with ICH at baseline
Type of heparin to be used in acute phase	LMWH instead of UFH is recommended; however, this does not apply to patients with contraindication for LMWH or circumstances where fast reversal of the anticoagulant effect is required
Thrombolysis and thrombectomy compared with anticoagulation in acute phase	No recommendations Good clinical practice point Panel did not suggest thrombolysis in acute CVST patients with a pretreatment low risk of poor outcome
Duration of anticoagulation therapy	Oral anticoagulants (Vitamin K antagonists) for a variable period of 3–12 months after CVST are recommended to prevent the recurrence of CVST and other VTE Good clinical practice point Patients with recurrent VTE or prothrombotic condition may need permanent anticoagulation
Use of new direct oral anticoagulants such as factor Xa or thrombin inhibitors	Use of new DOACs is not recommended, especially in acute phase
Use of AEDs	AEDs in patients with CVST are recommended to prevent early recurrent seizures with supratentorial lesions and seizures. However, the panel did not give any recommendations to prevent using AEDs to prevent remote post-CVST seizures
Treatment of CVST in pregnant and puerperal women	Treatment with subcutaneous LMWH in patients with acute CVT is recommended
Using contraceptives after CVST	Women in childbearing age group with a prior history of CVST should be told about the risks of combined hormonal contraception and given advice against its use
Prophylactic use of antithrombotic drugs in pregnant women with a prior history of CVST	Prophylactic use of subcutaneously LMWH is recommended for women with a prior history of CVST during pregnancy/puerperium having no contraindication for prophylaxis or indication for anticoagulation in therapeutic dosage

AEDs – Anti-epileptic drugs; CVST – Cerebral vein and dural sinus thrombosis; LMWH – Low-molecular-weight heparin; UFH – Unfractionated heparin; VTE – Venous thromboembolism; DOACs – Direct oral anticoagulants; CVT – Cerebral vein thrombosis; ICH – Intracranial hemorrhage

found that none of the nine CVST patients managed with apixaban and rivaroxaban developed any serious bleeding or thromboembolic event in the median follow-up of 12 months. Apixaban was also found to be safe and an effective alternative to warfarin in another small case series.^[82] Another factor Xa inhibitor that has been reported to improve flow in two patients with deep CVST is edoxaban.^[86] It should be noted that although studies to date are suggestive of DOACs being safe and effective, large-scale studies are required to provide strong evidence for its use as first-line therapy.

Thrombolysis

Several case series have reported the therapeutic effect of systemic thrombolysis in managing CVST. In 2014, Viegas *et al.*,^[87] in their systematic review of 16 reports where a total of 26 patients received systemic thrombolysis as a treatment for acute CVST, it was found that 88% of the patients became independent, but there were two deaths due to intracranial hemorrhage. Nonetheless, several studies have found the use of various thrombolytics to have good-to-excellent clinical outcome.^[76] However, further studies are required to determine if systemic thrombolysis can be used in the place of anticoagulants as first-line treatment for patients with CVST.

Neurointerventional procedures

Neurointerventional procedures in the management of CVST are considered in patients who have clinical deterioration despite receiving proper anticoagulation therapy or in whom anticoagulation therapy is contraindicated, such as thrombocytopenia, bleeding disorders or recent major hemorrhages.^[76] Various endovascular treatment methods available are pharmacological thrombolysis, direct aspiration thrombectomy, stent-retriever thrombectomy, balloon thrombectomy, balloon angioplasty and stenting and AngioJET™.^[76] Although according to the AHA/ASA, there is lack of sufficient evidence to support systemic and endovascular thrombolysis in CVST, these therapeutic options may be considered in expert centers.^[7] Najjar *et al.*^[88] reported successful recanalization in two patients with extensive CVST using suction thrombectomy technique. Currently, there is no evidence for recommending any endovascular procedure over another, and thus different approaches can be used.^[76]

Decompressive hemicraniectomy

Nearly 5% of cases with CVST can have a malignant course with signs of high ICP and transtentorial herniation. In such cases, a decompressive surgery can be a lifesaving procedure that allows a better functional outcome and improves survival rate.^[89,90]

CONCLUSION

The diagnosis of CVST is based on clinical presentation and confirmed by neuroimaging. Presence of direct and indirect radiological signs on CT scan can help make a diagnosis of CVST in emergency settings. Further, CTV and MRV have comparable efficacy. Anticoagulation is the mainstay of treatment. In addition, the use of DOACs and endovascular treatment has shown therapeutic potential; however, large-scale randomized controlled trial data are required before their use is widely recommended. Currently, A clinical trial comparing efficacy and safety of dabigatran etexilate with warfarin in patients with cerebral venous and dural sinus thrombosis (RE-SPECT CVT),^[91] Thrombolysis or Anticoagulation for Cerebral Venous Thrombosis trial^[92] and the benefit of EXtending oral antiCOAgulation treatment after acute cerebral vein thrombosis trial^[93] are ongoing trials that would likely provide clearer evidence regarding the use of non-vitamin K antagonist oral anticoagulants and thrombectomy in patients with CVST. Finally, future studies are also needed to clarify if systemic thrombolysis can be an alternative for anticoagulation therapy as the mainstay of treatment.

Peer review

This article was peer reviewed by two independent and anonymous reviewers.

Financial support and sponsorship

Nil.

Conflicts of interest

There are no conflicts of interest.

REFERENCES

1. Ferro JM, Canhão P, Stam J, Boussier MG, Barinagarrementeria F; ISCVT Investigators. *et al.* Prognosis of cerebral vein and dural sinus thrombosis: Results of the international study on cerebral vein and dural sinus thrombosis (ISCVT). *Stroke* 2004;35:664-70.
2. Boussier MG, Ferro JM. Cerebral venous thrombosis: An update. *Lancet Neurol* 2007;6:162-70.
3. Ferro JM, Canhão P. Cerebral venous sinus thrombosis: Update on diagnosis and management. *Curr Cardiol Rep* 2014;16:523.
4. Tanislav C, Siekmann R, Sieweke N, Allendörfer J, Pabst W, Kaps M, *et al.* Cerebral vein thrombosis: Clinical manifestation and diagnosis. *BMC Neurol* 2011;11:69.
5. Algahtani HA, Aldarmahi AA. Cerebral venous sinus thrombosis. *Neurosciences* 2014;19:11-6.
6. Narayan D, Kaul S, Ravishankar K, Suryaprabha T, Bandaru VC, Mridula KR, *et al.* Risk factors, clinical profile, and long-term outcome of 428 patients of cerebral sinus venous thrombosis: Insights from Nizam's institute venous stroke registry, Hyderabad (India). *Neurol India* 2012;60:154-9.
7. Saposnik G, Barinagarrementeria F, Brown RD Jr., Bushnell CD, Cucchiara B, Cushman M, *et al.* Diagnosis and management of cerebral venous thrombosis: A statement for healthcare professionals from the

- American Heart Association/American Stroke Association. *Stroke* 2011;42:1158-92.
8. Stam J. Thrombosis of the cerebral veins and sinuses. *N Engl J Med* 2005;352:1791-8.
 9. Daif A, Awada A, al-Rajeh S, Abduljabbar M, al Tahan AR, Obeid T, *et al*. Cerebral venous thrombosis in adults. A study of 40 cases from Saudi Arabia. *Stroke* 1995;26:1193-5.
 10. Janghorbani M, Zare M, Saadatnia M, Mousavi SA, Mojarrad M, Asgari E. Cerebral vein and dural sinus thrombosis in adults in Isfahan, Iran: Frequency and seasonal variation. *Acta Neurol Scand* 2008;117:117-21.
 11. Ghiasian M, Mansour M, Mazaheri S, Pirdehghan A. Thrombosis of the cerebral veins and sinuses in Hamadan, West of Iran. *J Stroke Cerebrovasc Dis* 2016;25:1313-9.
 12. Coutinho JM, Zuurbier SM, Aramideh M, Stam J. The incidence of cerebral venous thrombosis: A cross-sectional study. *Stroke* 2012;43:3375-7.
 13. Devasagayam S, Wyatt B, Leyden J, Kleinig T. Cerebral venous sinus thrombosis incidence is higher than previously thought: A retrospective population-based study. *Stroke* 2016;47:2180-2.
 14. Piazza G. Cerebral venous thrombosis. *Circulation* 2012;125:1704-9.
 15. Misra UK, Kalita J, Chandra S, Kumar B, Bansal V. Low molecular weight heparin versus unfractionated heparin in cerebral venous sinus thrombosis: A randomized controlled trial. *Eur J Neurol* 2012;19:1030-6.
 16. Algahtani HA, Abdu AP, Shami AM, Hassan AE, Madkour MA, Al-Ghamdi SM, *et al*. Cerebral venous sinus thrombosis in Saudi Arabia. *Neurosciences (Riyadh)* 2011;16:329-34.
 17. Zuurbier SM, Middeldorp S, Stam J, Coutinho JM. Sex differences in cerebral venous thrombosis: A systematic analysis of a shift over time. *Int J Stroke* 2016;11:164-70.
 18. Kalita J, Chandra S, Kumar B, Bansal V, Misra UK. Cerebral venous sinus thrombosis from a tertiary care teaching hospital in India. *Neurologist* 2016;21:35-8.
 19. Bushnell C, Saposnik G. Evaluation and management of cerebral venous thrombosis. *Continuum (Minneapolis)* 2014;20:335-51.
 20. Duman T, Uluduz D, Mide I, Bektas H, Kablan Y, Goksel BK, *et al*. A multicenter study of 1144 patients with cerebral venous thrombosis: The VENOST study. *J Stroke Cerebrovasc Dis* 2017;26:1848-57.
 21. Souirti Z, Messouak O, Belahsen F. Cerebral venous thrombosis: A Moroccan retrospective study of 30 cases. *Pan Afr Med J* 2014;17:281.
 22. Sidhom Y, Mansour M, Messelmani M, Derbali H, Fekih-Mrissa N, Zaouali J, *et al*. Cerebral venous thrombosis: Clinical features, risk factors, and long-term outcome in a Tunisian cohort. *J Stroke Cerebrovasc Dis* 2014;23:1291-5.
 23. Wang B, Peng C, Zhou MK, Guo J, He L. Clinical characteristics and prognosis of patients with cerebral venous sinus thrombosis in Southwest China. *Sichuan Da Xue Xue Bao Yi Xue Ban* 2014;45:515-8.
 24. Kajtazi NI, Zimmerman VA, Arulneyam JC, Al-Shami SY, Al-Senani FM. Cerebral venous thrombosis in Saudi Arabia. Clinical variables, response to treatment, and outcome. *Neurosciences (Riyadh)* 2009;14:349-54.
 25. Thorell SE, Parry-Jones AR, Punter M, Hurford R, Thachil J. Cerebral venous thrombosis-a primer for the haematologist. *Blood Rev* 2015;29:45-50.
 26. Wasay M, Kojan S, Dai AI, Bobustuc G, Sheikh Z. Headache in cerebral venous thrombosis: Incidence, pattern and location in 200 consecutive patients. *J Headache Pain* 2010;11:137-9.
 27. Alvis-Miranda HR, Milena Castellar-Leones S, Alcalá-Cerra G, Rafael Moscote-Salazar L. Cerebral sinus venous thrombosis. *J Neurosci Rural Pract* 2013;4:427-38.
 28. Luo Y, Tian X, Wang X. Diagnosis and treatment of cerebral venous thrombosis: A Review. *Front Aging Neurosci* 2018;10:2.
 29. Giroto M, Ferro JM, Canhão P, Stam J, Bousser MG, Barinagarrementeria F, *et al*. Predictors of outcome in patients with cerebral venous thrombosis and intracerebral hemorrhage. *Stroke* 2007;38:337-42.
 30. Stienen A, Weinzierl M, Ludolph A, Tibussek D, Häusler M. Obstruction of cerebral venous sinus secondary to idiopathic intracranial hypertension. *Eur J Neurol* 2008;15:1416-8.
 31. de Bruijn SF, de Haan RJ, Stam J. Clinical features and prognostic factors of cerebral venous sinus thrombosis in a prospective series of 59 patients. For the cerebral venous sinus thrombosis study group. *J Neurol Neurosurg Psychiatry* 2001;70:105-8.
 32. Sparaco M, Feleppa M, Bigal ME. Cerebral venous thrombosis and headache a case-series. *Headache* 2015;55:806-14.
 33. Uzar E, Ekici F, Acar A, Yucel Y, Bakir S, Tekbas G, *et al*. Cerebral venous sinus thrombosis: An analyses of 47 patients. *Eur Rev Med Pharmacol Sci* 2012;16:1499-505.
 34. Paciaroni M, Palmerini F, Bogousslavsky J. Clinical presentations of cerebral vein and sinus thrombosis. *Front Neurol Neurosci* 2008;23:77-88.
 35. Mittal SO, Siddiqui J, Katirji B. Abducens nerve palsy due to inferior petrosal sinus thrombosis. *J Clin Neurosci* 2017;40:69-71.
 36. Sotoodehnia M, Safaei A, Rasooli F, Bahreini M. Unilateral sixth nerve palsy. *Am J Emerg Med* 2017;35:934.e1-2.
 37. Tsimiklis CA, Gragnaniello C, Abou-Hamden A. Venous sinus thrombosis secondary to tuberculous meningitis: A novel cause of trigeminal neuralgia. *BMJ Case Rep* 2014;2014:bcr2014207238.
 38. Straub J, Magistris MR, Delavelle J, Landis T. Facial palsy in cerebral venous thrombosis: Transcranial stimulation and pathophysiological considerations. *Stroke* 2000;31:1766-9.
 39. O'Connor L, Croxson G, McCluskey P, Halmagyi GM. A 43-year-old woman presenting with subacute, bilateral, sequential facial nerve palsies, then developing pseudotumour cerebri. *BMJ Case Rep* 2015;2015:bcr2015211399.
 40. Karadas S, Milanlioglu A, Gönüllü H, Sayin R, Aydin MN. Cerebral venous sinus thrombosis presentation in emergency department in Van, Turkey. *J Pak Med Assoc* 2014;64:370-4.
 41. Ferro JM, Canhão P, Bousser MG, Stam J, Barinagarrementeria F, ISCVT Investigators. Early seizures in cerebral vein and dural sinus thrombosis: Risk factors and role of antiepileptics. *Stroke* 2008;39:1152-8.
 42. Mahale R, Mehta A, John AA, Buddaraju K, Shankar AK, Javali M, *et al*. Acute seizures in cerebral venous sinus thrombosis: What predicts it? *Epilepsy Res* 2016;123:1-5.
 43. Ferro JM, Lopes MG, Rosas MJ, Fontes J; VENOPORT Investigators. Delay in hospital admission of patients with cerebral vein and dural sinus thrombosis. *Cerebrovasc Dis* 2005;19:152-6.
 44. Kothare SV, Ebb DH, Rosenberger PB, Buonanno F, Schaefer PW, Krishnamoorthy KS. Acute confusion and mutism as a presentation of thalamic strokes secondary to deep cerebral venous thrombosis. *J Child Neurol* 1998;13:300-3.
 45. Geraldes R, Sousa PR, Fonseca AC, Falcão F, Canhão P, Pinho e Melo T. Nontraumatic convexity subarachnoid hemorrhage: Different etiologies and outcomes. *J Stroke Cerebrovasc Dis* 2014;23:e23-30.
 46. Panda S, Prashantha DK, Shankar SR, Nagaraja D. Localized convexity subarachnoid haemorrhage a sign of early cerebral venous sinus thrombosis. *Eur J Neurol* 2010;17:1249-58.
 47. Hassan KM, Kumar D. Reversible diencephalic dysfunction as presentation of deep cerebral venous thrombosis due to hyperhomocysteinemia and protein S deficiency: Documentation of a case. *J Neurosci Rural Pract* 2013;4:193-6.
 48. Xue SF, Ma QF, Ma X, Jia JP. Isolated cortical vein thrombosis: A widely variable clinicoradiological spectrum. *Eur Neurol* 2013;69:331-5.
 49. Kaaniche F, Chaari A, Turki O, Chelly H, Bouaziz M. Post-trauma cerebral thrombophlebitis revealed by psychiatric disorders. *J Mal Vasc* 2015;40:192-5.
 50. Masuhr F, Mehraein S, Einhäupl K. Cerebral venous and sinus thrombosis. *J Neurol* 2004;251:11-23.
 51. Ferro JM, Canhão P, Aguiar de Sousa D. Cerebral venous thrombosis. *Presse Med* 2016;45:e429-50.

52. Lauw MN, Barco S, Coutinho JM, Middeldorp S. Cerebral venous thrombosis and thrombophilia: A systematic review and meta-analysis. *Semin Thromb Hemost* 2013;39:913-27.
53. Marjot T, Yadav S, Hasan N, Bentley P, Sharma P. Genes associated with adult cerebral venous thrombosis. *Stroke* 2011;42:913-8.
54. Khan M, Wasay M, Menon B, Saadatina M, Venketasubramanian N, Gunaratne P, *et al.* Pregnancy and puerperium-related strokes in Asian women. *J Stroke Cerebrovasc Dis* 2013;22:1393-8.
55. Coutinho JM, Ferro JM, Canhão P, Barinagarrementeria F, Cantú C, Bousser MG, *et al.* Cerebral venous and sinus thrombosis in women. *Stroke* 2009;40:2356-61.
56. Fugate JE, Robinson MT, Rabinstein AA, Wijidicks EF. Cerebral venous sinus thrombosis associated with a combined contraceptive ring. *Neurologist* 2011;17:105-6.
57. Bousser MG, Crassard I. Cerebral venous thrombosis, pregnancy and oral contraceptives. *Thromb Res* 2012;130 Suppl 1:S19-22.
58. Khealani BA, Wasay M, Saadah M, Sultana E, Mustafa S, Khan FS, *et al.* Cerebral venous thrombosis: A descriptive multicenter study of patients in Pakistan and Middle East. *Stroke* 2008;39:2707-11.
59. Korathanakun P, Petpichetchian W, Sathirapanya P, Geater SL. Cerebral venous thrombosis: Comparing characteristics of infective and non-infective aetiologies: A 12-year retrospective study. *Postgrad Med J* 2015;91:670-4.
60. Katsanos AH, Katsanos KH, Kosmidou M, Giannopoulos S, Kyritsis AP, Tsianos EV, *et al.* Cerebral sinus venous thrombosis in inflammatory bowel diseases. *QJM* 2013;106:401-13.
61. Ciccone A, Gatti A, Melis M, Cossu G, Boncoraglio G, Carriero MR, *et al.* Cigarette smoking and risk of cerebral sinus thrombosis in oral contraceptive users: A case-control study. *Neurol Sci* 2005;26:319-23.
62. Tufano A, Guida A, Coppola A, Nardo A, Di Capua M, Quintavalle G, *et al.* Risk factors and recurrent thrombotic episodes in patients with cerebral venous thrombosis. *Blood Transfus* 2014;12 Suppl 1:s337-42.
63. Zuurbier SM, Arnold M, Middeldorp S, Broeg-Morvay A, Silvis SM, Heldner MR, *et al.* Risk of cerebral venous thrombosis in obese women. *JAMA Neurol* 2016;73:579-84.
64. Richard S, Lacour JC, Frotscher B, Enea A, Mione G, Ducrocq X. Report of a recurrent cerebral venous thrombosis in a young athlete. *BMC Neurol* 2014;14:182.
65. Ferro JM, Bousser MG, Canhão P, Coutinho JM, Crassard I, Dentali F, *et al.* European Stroke Organization guideline for the diagnosis and treatment of cerebral venous thrombosis – Endorsed by the European academy of neurology. *Eur J Neurol* 2017;24:1203-13.
66. Kosinski CM, Mull M, Schwarz M, Koch B, Biniek R, Schläfer J, *et al.* Do normal D-dimer levels reliably exclude cerebral sinus thrombosis? *Stroke* 2004;35:2820-5.
67. Wasay M, Azeemuddin M. Neuroimaging of cerebral venous thrombosis. *J Neuroimaging* 2005;15:118-28.
68. Rodallec MH, Krainik A, Feydy A, Hélias A, Colombani JM, Jullès MC, *et al.* Cerebral venous thrombosis and multidetector CT angiography: Tips and tricks. *Radiographics* 2006;26 Suppl 1:S5-18.
69. Garetier M, Rousset J, Pearson E, Tissot V, Gentric JC, Nowak E, *et al.* Value of spontaneous hyperdensity of cerebral venous thrombosis on helical CT. *Acta Radiol* 2014;55:1245-52.
70. Mokin M, Ciambella CC, Masud MW, Levy EI, Snyder KV, Siddiqui AH, *et al.* Whole-brain computed tomographic perfusion imaging in acute cerebral venous sinus thrombosis. *Interv Neurol* 2016;4:104-12.
71. Gupta RK, Bapuraj JR, Khandelwal N, Khurana D. Prognostic indices for cerebral venous thrombosis on CT perfusion: A prospective study. *Eur J Radiol* 2014;83:185-90.
72. Connor SE, Jarosz JM. Magnetic resonance imaging of cerebral venous sinus thrombosis. *Clin Radiol* 2002;57:449-61.
73. Adams WM, Lait RD, Beards SC, Kassner A, Jackson A. Use of single-slice thick slab phase-contrast angiography for the diagnosis of dural venous sinus thrombosis. *Eur Radiol* 1999;9:1614-9.
74. Patel D, Machnowska M, Symons S, Yeung R, Fox AJ, Aviv RI, *et al.* Diagnostic performance of routine brain MRI sequences for dural venous sinus thrombosis. *AJNR Am J Neuroradiol* 2016;37:2026-32.
75. Sari S, Verim S, Hamcan S, Battal B, Akgun V, Akgun H, *et al.* MRI diagnosis of dural sinus – Cortical venous thrombosis: Immediate post-contrast 3D GRE T1-weighted imaging versus unenhanced MR venography and conventional MR sequences. *Clin Neurol Neurosurg* 2015;134:44-54.
76. Lee SK, Mokin M, Hetts SW, Fifi JT, Bousser MG, Fraser JF, *et al.* Current endovascular strategies for cerebral venous thrombosis: Report of the SNIS standards and guidelines committee. *J Neurointerv Surg* 2018;10:803-10.
77. Coutinho J, de Bruijn SF, Deveber G, Stam J. Anticoagulation for cerebral venous sinus thrombosis. *Cochrane Database Syst Rev* 2011;8:CD002005.
78. Stam J, Majoie CB, van Delden OM, van Lienden KP, Reekers JA. Endovascular thrombectomy and thrombolysis for severe cerebral sinus thrombosis: A prospective study. *Stroke* 2008;39:1487-90.
79. Behrouzi R, Punter M. Diagnosis and management of cerebral venous thrombosis. *Clin Med (Lond)* 2018;18:75-9.
80. Khan M, Wasay M. New oral anticoagulants (noacs) for cerebral venous thrombosis. *Pak J Neurol Sci* 2017;12:3-4.
81. Mendonça MD, Barbosa R, Cruz-e-Silva V, Calado S, Viana-Baptista M. Oral direct thrombin inhibitor as an alternative in the management of cerebral venous thrombosis: A series of 15 patients. *Int J Stroke* 2015;10:1115-8.
82. Rao SK, Ibrahim M, Hanni CM, Suchdev K, Parker D, Rajamani K, *et al.* Apixaban for the treatment of cerebral venous thrombosis: A case series. *J Neurol Sci* 2017;381:318-20.
83. van Es N, Coppens M, Schulman S, Middeldorp S, Büller HR. Direct oral anticoagulants compared with Vitamin K antagonists for acute venous thromboembolism: Evidence from phase 3 trials. *Blood* 2014;124:1968-75.
84. Field TS, Camden MC, Al-Shimemeri S, Lui G, Lee AY. Off-label use of novel anticoagulants for treatment of cerebral venous thrombosis: A Canadian survey. *Int J Stroke* 2017;12:NP16-8.
85. Covut F, Kewan T, Perez O, Flores M, Haddad A, Daw H, *et al.* Apixaban and rivaroxaban in patients with cerebral venous thrombosis. *Thromb Res* 2019;173:77-8.
86. Shimizu Y, Tsuchiya K, Fujisawa H. Deep venous thrombosis with decreased cerebral blood flow to the thalamus was completely restored by factor Xa inhibitor. *J Stroke Cerebrovasc Dis* 2019;28:e39-43.
87. Viegas LD, Stolz E, Canhão P, Ferro JM. Systemic thrombolysis for cerebral venous and dural sinus thrombosis: A systematic review. *Cerebrovasc Dis* 2014;37:43-50.
88. Najjar AA, Rasheedi JK, Kurdi KI, Hasan AA, Almekhlafi MA, Baeesa SS. Endovascular suction thrombectomy for severe cerebral venous sinus thrombosis: A report of two cases. *J Taibah Univ Med Sci* 2018;13:87-92.
89. Zhang S, Zhao H, Li H, You C, Hui X. Decompressive craniectomy in hemorrhagic cerebral venous thrombosis: Clinico-radiological features and risk factors. *J Neurosurg* 2017;127:709-15.
90. Clavijo A, Khan AA, Mendoza J, Montenegro JH, Johnson ED, Adeleye AO, *et al.* The role of decompressive craniectomy in limited resource environments. *Front Neurol* 2019;10:112.
91. A Clinical Trial Comparing Efficacy and Safety of Dabigatran Etxilate with Warfarin in Patients with Cerebral Venous and Dural Sinus Thrombosis (RE-SPECT CVT). Available from: <https://www.clinicaltrials.gov/ct2/show/NCT02913326>. [Last accessed on 2019 Jan 20].
92. Coutinho JM, Ferro JM, Zuurbier SM, Mink MS, Canhão P, Crassard I, *et al.* Thrombolysis or anticoagulation for cerebral venous thrombosis: Rationale and design of the TO-ACT trial. *Int J Stroke* 2013;8:135-40.
93. Miranda B, Aaron S, Arauz A, Barinagarrementeria F, Borhani-Haghighi A, Carvalho M, *et al.* The benefit of extending oral anticoagulation treatment (EXCOA) after acute cerebral vein thrombosis (CVT): EXCOA-CVT cluster randomized trial protocol. *Int J Stroke* 2018;13:771-4.