

# Effectiveness of Preoperative Lymphoscintigraphy for the Detection of Cervical Lymph Node Metastasis in Patients with Oral Squamous Cell Carcinoma

Md. Ahsan Habib, Quazi Billur Rahman, Shakhawat Hossain, Ashik Abdullah Imon, Gokul Chand Kundu

Department of Oral and Maxillofacial Surgery, Bangabandhu Sheikh Mujib Medical University, Shahbag, Dhaka-1000, Bangladesh

## Abstract

**Background:** Oral squamous cell carcinoma (OSCC) is one of the most common malignant tumor. OSCC is the malignancy of squamous epithelium of oral cavity, which is the sixth most common malignancy reported worldwide and one with highest mortality rate among all malignancies. **Aims:** The aims of this study is to assess the diagnostic performance of lymphoscintigraphy (LSG) for the detection of cervical lymph node metastasis in patients with OSCC. **Materials and Methods:** This was a prospective study done in Oral and Maxillofacial Surgery Department and National Institute of Nuclear Medicine and Allied Science, Bangabandhu Sheikh Mujib Medical University during July 2015–June 2016. Thirty-six patients with OSCC were included in this study. Radioisotope technique was used in the detection of cervical metastases in patients with histologically proven OSCC. Patients were assessed by LSG after diagnosis of OSCC, and then, it was compared with postoperative histopathology report. **Results:** Lymphoscintigraphically out of 36 patients, 23 had lymphatic channel obstruction where histologically 20 patients had lymph node metastasis. There were 20 true positive cases, 13 true negative cases, and 3 false positive cases but no false negative case was found. The test of validity result reveals that sensitivity 100.0%, specificity 81.25%, accuracy 96.66%, positive predictive value 86.96%, and negative predictive value 100.0%. **Conclusion:** LSG for the detection of cervical lymph node metastasis has an important role for the management of OSCC. It is also cost-effective and decreases the morbidity.

**Keywords:** Cervical lymph node, lymphoscintigraphy, oral squamous cell carcinoma

## INTRODUCTION

Oral squamous cell carcinoma (OSCC) is very common malignancy of the world population and more than 274,000 new cases reports in every year.<sup>[1]</sup> Oral cancer is the sixth most common cancers in the world, and OSCC is more than 90% of all oral cancers.<sup>[2,3]</sup> The affected people are mainly in the developing countries, and it is much more common malignancy of Southeast Asia.<sup>[4]</sup> The incidence of oral malignancy is 30%–50% in India,<sup>[5]</sup> 30% in Sri Lanka and it occurs one-third of all malignancies in Pakistan while in the UK and USA, it occurs only for 2% of all malignancies.<sup>[6]</sup> OSCC has poor prognosis, and it is improved very less despite of advances of medical, surgical, and biochemical sciences. Local recurrence and nodal metastasis are important issues for the prognosis of OSCC.<sup>[7]</sup> The presence or absence of nodal metastasis is very useful factor for staging, treatment planning, and prognosis. The incidence of occult metastases in patients with OSCC is

very high, and it is greater than 30%.<sup>[1,8,9]</sup> In the past, a bulk of work has been done to find a reliable procedure for detecting occult metastases, of which tumor depth appears to be the best available procedure.<sup>[10]</sup> However, the tumor depth and other primary tumor characteristics are still insufficient to negate the need for surgical staging of the cervical nodal basin.<sup>[11,12]</sup> Elective neck dissection is the current gold-standard staging procedure for the clinically node-negative neck, but still, the over treatment is about 70%. Previously, Elective neck dissection (END) invariably took the form of a modified radical neck dissection; however, there is increasing evidence that

**Address for correspondence:** Dr. Quazi Billur Rahman,  
Department of Oral and Maxillofacial Surgery, Bangabandhu Sheikh  
Mujib Medical University, Shahbag, Dhaka-1000, Bangladesh.  
E-mail: billu2002bd@yahoo.com

This is an open access article distributed under the terms of the Creative Commons Attribution-NonCommercial-ShareAlike 3.0 License, which allows others to remix, tweak, and build upon the work non-commercially, as long as the author is credited and the new creations are licensed under the identical terms.

**For reprints contact:** reprints@medknow.com

**How to cite this article:** Habib MA, Rahman QB, Hossain S, Imon AA, Kundu GC. Effectiveness of preoperative lymphoscintigraphy for the detection of cervical lymph node metastasis in patients with oral squamous cell carcinoma. *Ann Maxillofac Surg* 2017;7:30-6.

### Access this article online

#### Quick Response Code:



**Website:**  
www.amsjournal.com

**DOI:**  
10.4103/ams.ams\_176\_16

selective neck dissection is as efficacious as comprehensive neck dissection in treating the negative neck.<sup>[7]</sup> The shift toward more conservative surgical procedures has occurred in the last two decades, facilitated by the work undertaken by Lindberg.<sup>[13]</sup>

Oral malignancies usually spread through regional lymph node and it is the frequent pathway for the spread of oral malignancy. Nodal metastasis at the time of diagnosis is an important and adverse prognostic factor, and it decreases 50% survival rate of 5 years. The low sensitivity and accuracy (68%) of clinical examination and palpation of cervical lymph nodes prevent its use as sole staging procedure.<sup>[1,8]</sup> The success of sentinel lymph node biopsy in this regard has been revealed in breast cancer, however, its use in OSCC is still unclear due to frequent skip metastasis and proximity of lymph nodes to the primary tumor.

For making treatment decisions, imaging plays an important role, and it must be able to detect metastatic nodes in patients with early stage of tumor. In addition, these techniques must be sufficiently sensitive to detect micrometastasis and also be specific enough so that frequent false-negative result does not lead to universal prescription of elective neck treatment, resulting unnecessary morbidity. Computed tomography (CT) scan, magnetic resonance imaging (MRI), and ultrasonography are better staging tools, but the sensitivities and specificities are relatively low (40%–60%). Despite of improved resolution and software analysis, these techniques are still insufficiently sensitive for revealing occult neck metastasis because 20% to 45% of patients staged as N0 using these techniques exhibit occult metastasis. F-fluorodeoxyglucose positron emission tomography (PET) is useful in patient with T3-T4 head and neck cancers, but it is not good enough in patients with early lesion-like T1-T2N0 and also the sensitivity of PET is 67.9%.<sup>[8,14,15]</sup> On the other hand, the sensitivity of lymphoscintigraphy (LSG) is considering 100%. LSG provides a minimally invasive method of determining the lymph node status of the cervical node basin. This technique could be a useful diagnostic tool to screen cervical metastases that are below the threshold of manual palpation. It potentially improves the accuracy of histological nodal staging and avoids over treating three-quarters of this patient population, decreasing associated morbidity, and cost effectively.<sup>[16]</sup>

### Aims and objective

- To assess the diagnostic performance of LSG for the detection of cervical lymph node metastasis in patients with OSCC
- To study the metastatic involvement of lymph node in relation to the size of OSCC
- To compare of lymphoscintigraphical analysis of cervical lymph node with postoperative histopathology report in patient with OSCC.

## MATERIALS AND METHODS

This was a prospective study done in Oral and Maxillofacial Surgery Department and The National Institute of Nuclear

Medicine and Allied Science, Bangabandhu Sheikh Mujib Medical University (BSMMU), Dhaka Bangladesh, during July 2015–June 2016. Thirty-six patients with OSCC were included in this study. LSG was performed for the detection of lymph node metastases in patients with histologically proven OSCC. Patients were assessed with the radioisotope technique after diagnosis, and then, it was compared with postoperative histopathology report.

A dose of 37 MBq of <sup>99m</sup>Tc-labeled nanocolloid was prepared as a 2 ml solution for injection. Two injections of approximately. Four milliliter were given over each mastoid process. The patient was scanned between 3 and 4 h later with a wide field of view gamma camera. Anteroposterior and lateral views were taken of the head and neck with the patient positioned to keep the injection sites out of the field of views. Imaging was terminated when the count density of any of the lymph nodes (if visualized) was approximately 50 counts/pixel. The time for this was typically 2 min and if no nodes were apparent, imaging was terminated after a further 2 min. All images were photographed for subsequent assessment.<sup>[17]</sup>

The gamma camera images were accepted for further analysis. The accepted images were assessed as follow:

- Figure 1 shows similar positive image patterns bilaterally was judged as normal
- Figure 2 shows in those images, in which no activity was apparent at the root of the neck, this side was considered as abnormal (perfusion defect)
- Figure 3 shows in those images, in which activity was apparent at the root of the neck, but with an area of reduced activity above this, this side was considered abnormal (gap defect).

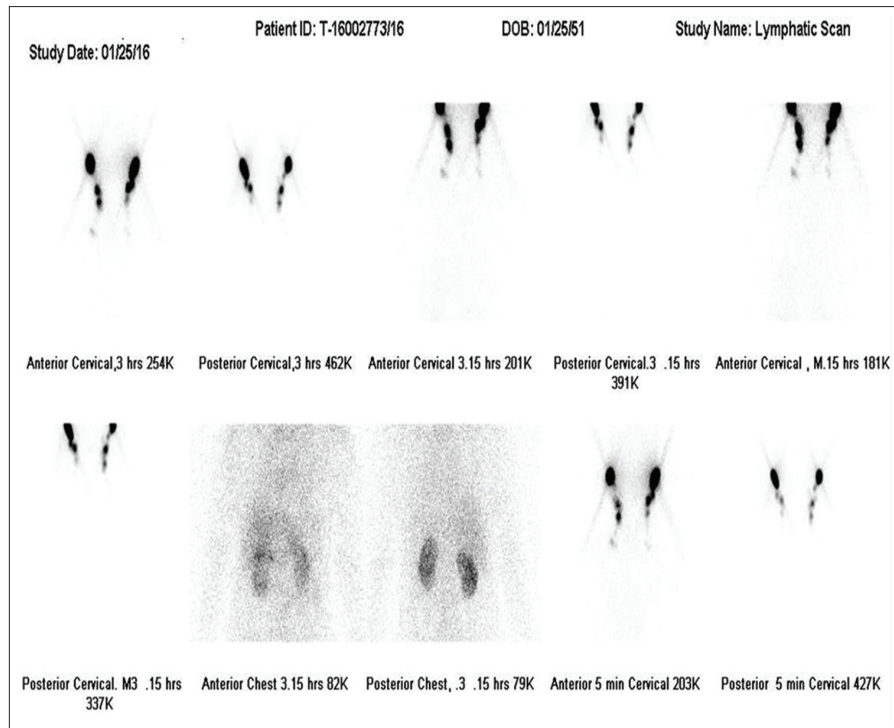
After LSG, these results were compared with postoperative histopathology report to find out the true positive, true negative, false positive, false negative and sensitivity, specificity of the lymphoscintigraphy.

### Ethics

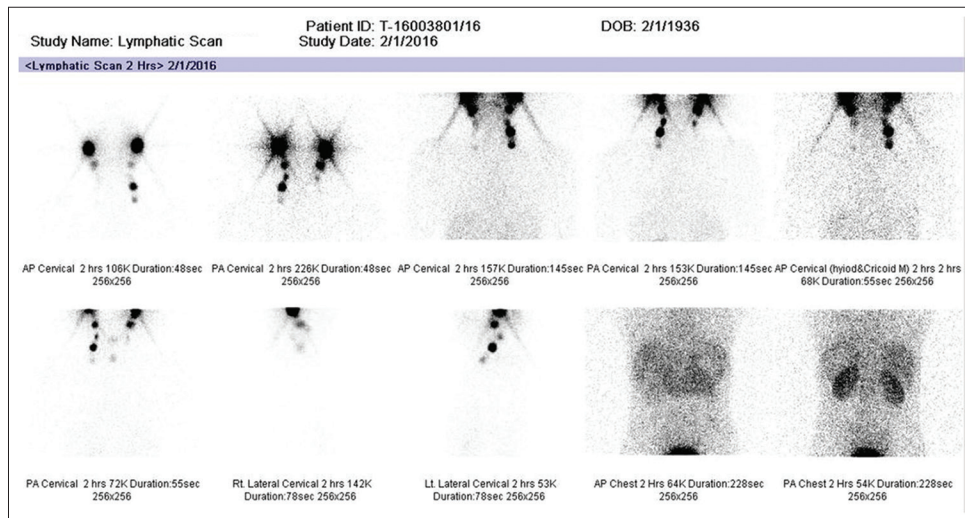
Ethical clearance for the study was taken from the Institutional Review Board, BSMMU, Dhaka, Bangladesh. Permission for the study was taken from the concerned department. The entire study participants were thoroughly appraised about the nature, purpose, and implications of the study as well as entire spectrum of benefits and risk of the study. Interest of the participants was not be compromised to safeguard their rights and health. All study participants were assured of adequate treatment of my complications developed in relation to study purpose. Participants were assured that all information and records would be kept confidential. Patients were given freedom to withdraw themselves from the study anytime. Written consent of all the study participants was taken free of duress and without exploiting any weakness of the participants.

### Statistics

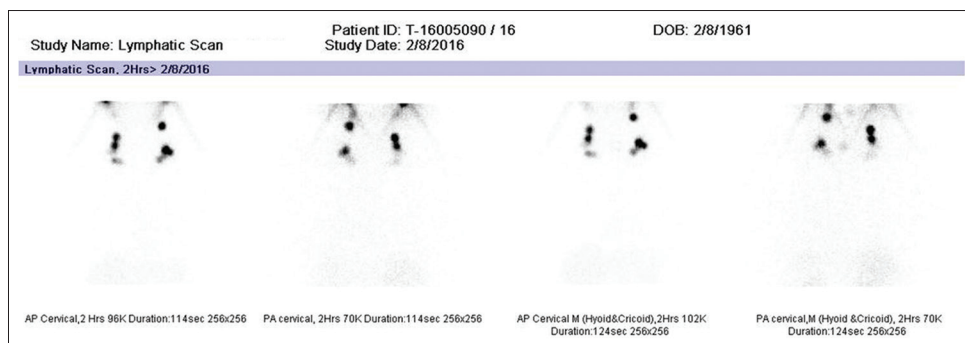
The computer-based statistical analysis was carried out with appropriate technique and systems. Data were processed and



**Figure 1:** Similar positive image patterns bilaterally was judged as normal



**Figure 2:** In those images in which no activity was apparent at the root of the neck, this side was considered as abnormal (perfusion defect)



**Figure 3:** In those images in which activity was apparent at the root of the neck, but with an area of reduced activity above this, this side was considered abnormal (gap defect)

analyzed by Statistical Program for Social Sciences version 22. The summarized data were presented in the form of tables and graphs, and diagnostic test was done for sensitivity, specificity, negative predictive value (NPV), and positive predictive value (PPV).

## RESULTS

This study was carried in 36 patients, of which 16 (44.4%) were male, and the rest of 20 (55.6%) were female patients. Male:female ratio was 1:1.25. The mean age of the patients was  $56.2 \pm 14.76$  years. Sixteen patients belong to age below 50 years, 15 (41.7%) patients were in 51–70 years, and 5 (13.9%) patients were above 70 years. In this study considering the site of lesion it was found that 12 (33.33%) patients had malignancy at Buccal mucosa, 4 (11.1%) had at vestibule, 5 (13.9%) had at Retromolar area, 8 (22.2%) had at Tongue and 7 (19.4%) patients had malignancy at maxilla [Table 1]. Regarding the tumor size, 3 (8.3%) patients were T1 in tumor size, 9 (25.0%) patients were T2 in tumor size, 11 (30.6%) patients were T3 in tumor size and 13 (36.1%) patients were T4 in tumor size [Table 2].

Those patients were evaluated by histopathology and lymphoscintigraphy, where 23 patients had lymphatic channel obstruction, but 20 patients had lymphatic metastasis [Table 3]. There were 20 true positive cases, 3 false positive cases, and 13 true negative cases those were free from lymph node metastasis and lymphatic channel obstruction. In this study,

**Table 1: Distribution of the study patients according to site of lesion (n=36)**

Site of lesion	Number of patients (%)
Buccal mucosa	12 (33.3)
Vestibule	4 (11.1)
Retromolar area	5 (13.9)
Tongue	8 (22.2)
Maxilla	7 (19.4)
Total	36 (100)

**Table 2: Distribution of the patients by tumor size (n=36)**

Tumor size	Number of patients (%)
T1 (<2 cm in diameter)	3 (8.3)
T2 (2-4 cm in diameter)	9 (25.0)
T3 (>4 cm in diameter)	11 (30.6)
T4 (invade to adjacent tissue)	13 (36.1)
Total	36 (100.0)

**Table 3: Distribution of the patients by lymphoscintigraphical analysis (n=36)**

Lymphoscintigraphical status	Number of patients (%)
Abnormal image (obstruction present)	23 (63.9)
Normal image (obstruction absent)	13 (36.1)
Total	36 (100.0)

we found no false negative cases. On lymphoscintigraphy, out of 36, 1 (33.3%) patient had abnormal image, but no metastasis was found on histopathology of T1 category, 5 (55.6%) had abnormal image but 4 (44.4%) had metastasis of T2 category, 7 (63.6%) patients had abnormal image and node metastasis of T3, 10 (76.9%) cases had abnormal image, but on histopathology, 9 (69.2%) lymph node metastasis was found of T4 category patients [Table 4 and 5].

There were 13 patients who had no lymphatic channel obstruction and also histopathologically had no metastasis. Among 13 patients who had lymphatic channel obstruction at Level I, 2 patients had no metastasis, and 11 patients had Level I metastasis histopathologically. Seven patients who had lymphatic channel obstruction at Level II but histopathologically, 4 patients had metastasis at Level I and 3 patients had metastasis at level II. Lymphoscintigraphically, three patients had obstruction at Level III, but histopathologically, one patient had no metastasis, and two patients had metastasis at Level II [Table 6].

Several statistics can be calculated to show the validity of the diagnostic test. It was observed that sensitivity 100.0%, specificity 81.25%, accuracy 96.66%, PPV 86.96%, and NPV 100.0% [Table 7].

## DISCUSSION

Standard treatment of OSCC patients consists of wide local excision and regional lymphadenectomy as well as excision of fibrofatty tissue of lymphatic drainage basin. LSG has been shown to be helpful in detecting the lymphatic drainage pattern of OSCC. Therapeutic outcome is mainly influenced by the presence of nodal metastasis for the management of patients with OSCC.

Ultrasonography, CT scan, and MRI can detect abnormally enlarged nodes, but borderline-sized nodes and extracapsular spread cannot reliably be differentiated.<sup>[18]</sup> The sensitivity of ultrasound, MRI and CT are 87%, 36%, and 42%,<sup>[14]</sup> respectively. This lack of accurate and reliable diagnostic methods for detecting metastatic lymph nodes is a serious shortcoming in the preoperative assessment of patients with OSCC.

In this study, LSG was performed preoperatively in a total of 36 patients with histologically proven OSCC. The age range of the patient was 28–100 years. The mean age of the patients was  $56.25 \pm 14.76$  years, and 16 (44.4%) were male, the rest of 20 (55.6%) were female patients. Male:female ratio was 1:1.25. Ikram *et al.*<sup>[19]</sup> noted of the 42 patients, 32 (76%) were male and 10 (24%) were female. The mean age of all the patients was  $52 \pm 7.5$  years with a range of 31–75 years. These findings are nearly similar with this study. Khalili and Alyani<sup>[20]</sup> reported out of 826, cases 55% were men and 45% were women. The mean age was  $59 \pm 13.7$  years (with a range of 18–85 years) in all cases.

In our study, regarding the site of the lesion, it was found that 12 (33.3%) patients had lesion at buccal mucosa,

**Table 4: Association of lymphoscintigraphical image with tumor size (n=36)**

Tumor size	n	Lymphoscintigraphical analysis		Chi-square test
		Abnormal image, n (%)	Normal image, n (%)	
T1	3	1 (33.3)	2 (66.7)	$\chi^2=2.443$ , df=3, P=0.486
T2	9	5 (55.6)	4 (44.4)	
T3	11	7 (63.6)	4 (36.4)	
T4	13	10 (76.9)	3 (23.1)	
Total	36	23 (63.8)	13 (36.2)	

**Table 5: Association of lymph node metastasis with tumor size (n=36)**

Tumor size	n	Postoperative histopathological report		Chi-square test
		Metastasis, n (%)	Nonmetastasis, n (%)	
T1	3	0	3 (100.0)	$\chi^2=5.476$ , df=3, P=0.140
T2	9	4 (44.4)	5 (55.6)	
T3	11	7 (63.6)	4 (36.4)	
T4	13	9 (69.2)	4 (30.8)	
Total	36	20 (55.5)	16 (44.5)	

**Table 6: Relation of lymphoscintigraphical obstruction level with postoperative histopathological lymph node metastasis level (n=36)**

	Lymphoscintigraphical obstruction level		Histopathological metastasis level		
	Level	Number of patients	No metastasis	Metastasis	
				Level I	Level II
No obstruction		13	13	0	0
Obstruction	I	13	2	11	0
	II	7	0	4	3
	III	3	1	0	2
Total		36	16	15	5

**Table 7: Test of validity**

Lymphoscintigraphical report	Histology report	Impression
Abnormal image	Metastasis	True positive (n=20)
Abnormal image	Nonmetastasis	False positive (n=3)
Normal image	Nonmetastasis	True negative (n=13)
Normal image	Metastasis	False negative (n=0)
Validity parameters	Value (%)	
Sensitivity	100.00	
Specificity	81.25	
Accuracy	96.6	
Positive predictive value	86.96	
Negative predictive value	100.00	

4 (11.1%) patients had at vestibule, 5 (13.9%) Patients had at retromolar area, 8 (22.2%) patients had on tongue, and 7 (19.4%) patients had lesion at maxilla. Shenoi *et al.*<sup>[21]</sup> noted the alveolus of mandible was the most frequently involved site, accounting for 135 cases (45.76%), and then, buccal mucosa 70 cases (23.73%), tongue was 54 cases (18.31%), and maxillary alveolus in 17 (5.76%) patients. Nine patients

had involvement of lip (3.05%), in six patients (2.03%) floor of mouth, and in four patients had palate (1.36%). Feller and Lemmer<sup>[3]</sup> reported oral SCC affects the tongue in 20%–40% of cases and the floor of the mouth in 15%–20% of the cases of all cases of OSCC.

In the present study, regarding the tumor size, 13 (36.1%) patients were T4, 11 (30.6%) were T3, 9 (25.0%) were T2, and 3 (8.3%) were T1. Among 36 cases of OSCC, 3 cases were T1 category where no metastasis was found. We found 4 (44.4%) metastasis out of 9 patients of T2 category, 7 (63.6%) metastasis out of 11 patients of T3 category, and 9 (69.2%) metastasis of T4 category out of 13 patients. Akhter *et al.*<sup>[22]</sup> found 2 cases of T1 category but no lymph node metastasis in that group, 29 cases were of T2 category, and 37.9% were metastasis, 7 cases of T3 category and 3 (42.8%) were metastasis, 2 cases were in T4 category, but 1 (50.0%) was metastasis. These findings are similar to our study. Another study done by Ehsan-ul-Haq *et al.*<sup>[23]</sup> was noted most of the cases were T3 and T4 size (30% and 38%, respectively). The overall rate of cervical lymph node metastases was 60% (30/50) which included 59% metastases in cases of oral tongue and 62% cases of floor of the mouth. No metastases

were observed in T1-sized lesion of floor of the mouth. The overall highest cervical lymph node metastasis was found in T4 lesions (79%).

In the current study, there were 13 patients who had no lymphatic channel obstruction and also histopathologically had no metastasis. Among 13 patients who had lymphatic obstruction at Level I, histopathologically 2 patients had no metastasis, and 11 patients had Level I metastasis. Seven patients who had lymphatic channel obstruction at Level II; however, histopathologically, 4 patients had metastasis at Level I and 3 patients at Level II. Lymphoscintigraphically, three patients had obstruction at Level III, but histopathologically one patient had no metastasis, and two patients had metastasis at Level II. Ehsan-ul-Haq *et al.*<sup>[23]</sup> performed a study in cases of squamous cell carcinoma of tongue and floor of the mouth, out of 60% ( $n = 30$ ) positive metastatic lymph nodes (pN+) were found. Level I and II were the most frequently involved in 30% ( $n = 9$ ) cases. While isolated Level II was the second highest 23% ( $n = 7$ ) and Levels I, II, and III combined were the third most frequently involved metastatic groups, 17% ( $n = 5$ ). Metastasis to Level IV and Level V was infrequent. Their findings are similar to our study.

In this study, 100% nodal metastases were found at Levels I–III. Other study 90% nodal metastasis was found at Levels I–III. Metastasis to Level IV and Level V were very rare, and no metastatic node was found at isolated Level IV or V.<sup>[24]</sup> This is in agreement with Dias *et al.*<sup>[25]</sup> This result supports that a conservative approach like a selective supraomohyoid neck dissection (Level I–III) should be enough if there is no other indication for radical neck dissection.

In the present study, histologically, 20 (55.5%) cases out of 36 had lymph node metastasis, but lymphoscintigraphically we found 23 (63.8%) patients who had lymphatic channel obstruction. There were 3 (8.3%) false positive cases and no false negative case. The test of validity results was observed that sensitivity 100%, specificity 81.25%, accuracy 96.66%, PPV 86.96%, and NPV 100%. Sri-Pathmanathan and Railton<sup>[17]</sup> reported 100% sensitivity in detecting pathologically confirmed neck metastases. They found 32% of the false-positives cases and no false negative case. Poyoux *et al.*<sup>[26]</sup> studied over 30 patient's where sensitivity was 86%, and he found one false negative case which was the first case.

The diagnostic performance of LSG was good enough in detecting lymph node metastasis in OSCC and is definitely superior to conventional imaging techniques. LSG would be a promising test in the identification of regional lymph nodes metastasis preoperatively in OSCC patients. It will be helpful for the surgeon to plan the surgery and it will decrease postoperative complications related to unnecessary extensive lymph node dissection.

## CONCLUSION

LSG for the detection of cervical lymph node metastasis has an important role for the management of OSCC. The success

of lymphoscintigraphy depends on good communication between all the individual components: imaging, surgery, and histopathology. The multidisciplinary team setting should be utilized for the discussion of every patient, and regular follow-up for patient outcomes. It is also cost-effective, and it will decrease morbidity.

## Acknowledgments

By the name of Almighty Allah, the most merciful, the creator of life and his mysteries for giving me strength and ability to complete this research work.

I am grateful and proud to express my high regards and profound respect to my teacher and honorable supervisor Prof. Dr. Quazi Billur Rahman, Chairman and Professor, Oral and Maxillofacial Surgery Department, BSMMU, Dhaka, Bangladesh, for his valuable guidance, wholehearted cooperation, and constructive advice to make this work complete.

I express my sincere gratefulness and profound respect to Prof. Dr. Rokeya Begum, Professor, National Institute of Nuclear Medicine and Allied Science, Dhaka, for her moral support, constructive criticism, and untiring practical cooperation during the procedure of this study. I am extremely grateful to all respected teachers of Oral and Maxillofacial Surgery Department, BSMMU for their cooperation and inspiration.

## Financial support and sponsorship

Nil.

## Conflicts of interest

There are no conflicts of interest.

## REFERENCES

- Alkureishi LWT, Burak Z, Alvarez JA, Ballinger J, Blide A, Britten AJ, *et al.* Joint practice guidelines for radionuclide lymphoscintigraphy for sentinel node localization in oral/oropharyngeal squamous cell carcinoma. *Eur J Nucl Med Mol Imaging* 2009;36:1915-36.
- Agnihotri A, Raikwar S. Assessment of deep cervical lymph nodes in oral cancer. *Natl J Med dent Res* 2013;2:50-5.
- Feller L, Lemmer J. Oral squamous cell carcinoma: Epidemiology, clinical presentation and treatment. *J Cancer Ther* 2012;3:263-8.
- World Health Organization. Control of oral cancer in developing countries. A WHO meeting. *Bull World Health Organ* 1984;62:817-30.
- Henk JM. Malignant tumours of the oral cavity. In: Language JD, editor. *Management of Malignant Disease Series*. London: Edward Arnold; 1986. p. 2-8.
- Cawson R, Odel EW. *Essentials of Oral Pathology and Oral Medicine*. 6<sup>th</sup> ed. Philadelphia: Churchill Livingstone; 1998. p. 128.
- Cheng A, Schmidt BL. Management of the N0 neck in oral squamous cell carcinoma. *Oral Maxillofac Surg Clin North Am* 2008;20:477-97.
- Thomsen JB, Sørensen JA, Grupe P, Karstoft J, Krøgdahl A. Staging N0 oral cancer: Lymphoscintigraphy and conventional imaging. *Acta Radiol* 2005;46:492-6.
- Vigili MG, Tartaglione G, Rahimi S, Mafera B, Pagan M. Lymphoscintigraphy and radioguided sentinel node biopsy in oral cavity squamous cell carcinoma: Same day protocol. *Eur Arch Otorhinolaryngol* 2007;264:163-7.
- Kane SV, Gupta M, Kakade AC, D' Cruz A. Depth of invasion is the most significant histological predictor of subclinical cervical lymph node metastasis in early squamous carcinomas of the oral cavity. *Eur J Surg Oncol* 2006;32:795-803.

11. Alkureishi LW, Ross GL, Shoaib T, Soutar DS, Robertson AG, Sorensen JA, *et al.* Does tumor depth affect nodal upstaging in squamous cell carcinoma of the head and neck? *Laryngoscope* 2008;118:629-34.
12. Goerkem M, Braun J, Stoeckli SJ. Evaluation of clinical and histomorphological parameters as potential predictors of occult metastases in sentinel lymph nodes of early squamous cell carcinomas of the oral cavity. *Ann Surg Oncol* 2009;15:245-8.
13. Lindberg R. Distribution of cervical lymph node metastases from squamous cell carcinoma of the upper respiratory and digestive tracts. *Cancer* 1972;29:1446-9.
14. Rana S, Angadi PV, Hallikerimath S, Kale AD. Detection of metastases in oral squamous cell carcinoma: Still a diagnostic impasse. *Gulf J Oncolog* 2014;1:108-15.
15. Klutmann S, Bohuslavizki KH, Brenner W, Hoft S, Kroger S, Werner JA. Lymphoscintigraphy in tumors of the head and neck using double tracer technique. *J Nucl Med* 1999;40:776-82.
16. Alkureishi LW, Burak Z, Alvarez JA, Ballinger J, Bilde A, Britten AJ, *et al.* Joint practice guidelines for radionuclide lymphoscintigraphy for sentinel node localization in oral/oropharyngeal squamous cell carcinoma. *Ann Surg Oncol* 2009;16:3190-210.
17. Sri-Pathmanathan R, Railton R. Lymphoscintigraphy in the detection of cervical metastases from oral carcinoma: A pilot study. *Ann R Coll Surg Engl* 1989;71:281-4.
18. Anzai Y, Brunberg JA, Lufkin RB. Imaging of nodal metastases in the head and neck. *J Magn Reson Imaging* 1997;7:774-83.
19. Ikram M, Akhtar S, Junaid M, Dhari T, Zaman M, Hussain R, *et al.* Sentinel node localisation using pre-operative lymphoscintigraphy and intraoperative gamma probe in early oral cavity cancer. *J Pak Med Assoc* 2013;63:976-9.
20. Khalili M, Alyani Z. Clinicopathologic parameters associated with regional lymph node metastasis in oral squamous cell carcinoma: A retrospective study. *Iran J Pathol* 2008;3:140-6.
21. Sheno R, Devrukhkar V, Chaudhuri, Sharma BK, Sapre SB, Chikhale A. Demographic and clinical profile of oral squamous cell carcinoma patients: A retrospective study. *Indian J Cancer* 2012;49:21-6.
22. Akhter M, Hossain S, Rahman QB, Molla MR. A study on histological grading of oral squamous cell carcinoma and its co-relationship with regional metastasis. *J Oral Maxillofac Pathol* 2011;15:168-76.
23. Ehsan-ul-Haq M, Warraich RA, Abid H, Sajid MA. Cervical lymph node metastases in squamous cell carcinoma of tongue and floor of mouth. *J Coll Physicians Surg Pak* 2011;21:55-6.
24. Shah JP. Patterns of cervical lymph node metastasis from squamous carcinomas of the upper aerodigestive tract. *Am J Surg* 1990;160:405-9.
25. Dias FL, Lima RA, Kligerman J, Farias TP, Soares JR, Manfro G, *et al.* Relevance of skip metastases for squamous cell carcinoma of the oral tongue and the floor of the mouth. *Otolaryngol Head Neck Surg* 2006;134:460-5.
26. Payoux P, Dekeister C, Lopez R, Lauwers F, Esquerré JP, Paoli JR. Effectiveness of lymphoscintigraphic sentinel node detection for cervical staging of patients with squamous cell carcinoma of the head and neck. *J Oral Maxillofac Surg* 2005;63:1091-5.