

CASE REPORT

Kikuchi's Disease: An Unusual Presentation and a Therapeutic Challenge

Ali Mahmood,^{a*} Rabia Mir,^b Salama R. Salama,^c Rameen M. Miarrostami,^d Claudia Lapidus,^e and Fernando Pujol^f

^aNew York Methodist Hospital and St. Joseph Mercy Oakland Hospital and Medical Center; ^bDepartment of Pathology and Laboratory Medicine, New York Methodist Hospital, New York; ^cDepartment of Pulmonary and Critical Care Medicine, New York Methodist Hospital, New York; ^dJoan and Sanford I. Weill Medical College of Cornell University and Department of Pulmonary and Critical Care Medicine, New York Methodist Hospital, New York; ^eDepartment of Radiology, New York Methodist Hospital, New York; ^fDepartment of Medicine, Joan and Sanford I. Weill Medical College of Cornell University, Department of Medicine/College of Medicine at SUNY, HSC at Downstate, Brooklyn, New York.

Kikuchi's disease, or necrotizing histiocytic lymphadenitis, is a rare disease that presents predominantly in young women in their 20s and 30s from the Far East. Our case depicts an African-American male, in his sixth decade of life, presenting with Kikuchi's disease, making our case unusual. The clinical presentation, together with laboratory and pathological tests described here, specifically the utilization of immunohistochemistry, aid in establishing a diagnosis. We advocate the use of steroids as symptomatic therapy and provide a novel and successful therapeutic regimen. We do not recommend antibiotic therapy until an infectious etiology is confirmed.

INTRODUCTION

Kikuchi's disease, or necrotizing histiocytic lymphadenitis, is a rare disease, characterized by the presence of enlarged and inflamed lymph nodes. Literature reviews have estimated that up to 80 percent of the patients are of Far Eastern descent, with the disease showing a preponderance toward women [1]. Only six of the 108 patients surveyed in a study of Kikuchi's dis-

ease diagnosis were African-American and showed an age range from 11 to 75 years [1], while the typical age of presentation is in the third to fourth decades of life. Our patient, a 51-year-old African-American male, is therefore unusual as a patient with this disease.

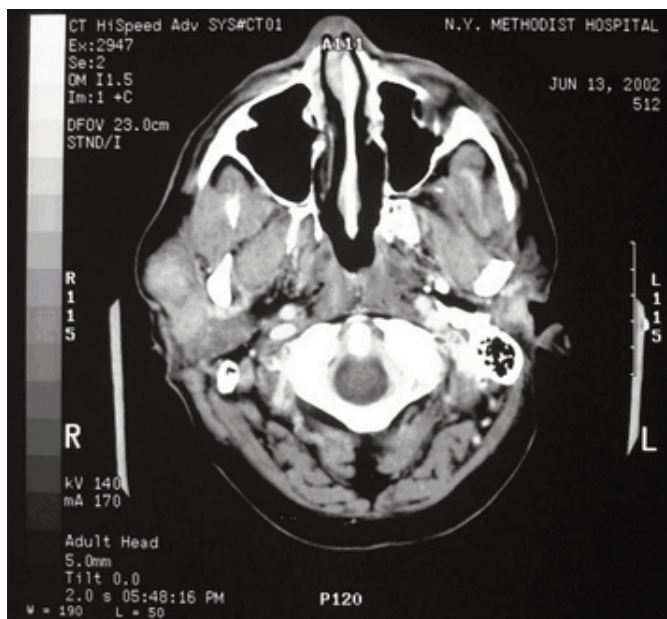
The epidemiology of Kikuchi's disease is widespread, spanning the globe from Japan, where it was first described in 1972, to the United States, and including Europe,

*To whom all correspondence should be addressed: Ali Mahmood, M.D., 3267 Camden Drive, Troy, MI 48084. Tel: 248-770-4326; E-mail: StrikerMD@hotmail.com.

†Abbreviations: CMV, cytomegalovirus; CT, computed tomography; EBV, Epstein-Barr virus; FNA, fine needle aspiration; FNAC, fine needle aspiration cytology; HHV-6, human herpes virus 6; SLE, systemic lupus erythematosus.

Conflict of Interest: Please note that all authors aforementioned have reviewed the manuscript and agree to its submission in the present state. There is not one author who has any financial obligation or influence from the publication of this case report. There have been no submissions to other journals of this case report. All potential conflicts of interest have been disclosed.

Figure 1. Computed tomography scan of the neck in a patient with Kikuchi's disease. Computed tomography scan of the neck done on day 3, depicting enlargement and heterogeneous enhancement of the right parotid gland.



the Middle East, and South America [2-5]. The first documented cases outside of Japan were described by Pileri et al., depicting cases in West Germany, Iran, Italy, Korea, and Spain [6]. This was shortly followed by the first cases reported in the United States [1,7]. There has been no strong genetic predisposition established for this disease. Rare familial cases have been reported primarily from Japan and Saudi Arabia [2,5]. Here, we report a case study of a 51-year-old African-American male with Kikuchi's disease and describe a novel and successful tapered steroidal therapeutic regime. Our patient had no pertinent travel history. He was raised in New York City and knew of no family member who had an illness with symptoms similar to his.

CASE HISTORY

A 51-year-old African-American male presented to the emergency room with a history of intermittent fever, chills, poor appetite, nausea, vomiting, and cough with productive white sputum for the past 10 days. He also complained of progressively worsening right-sided facial swelling, particularly around the parotid region, and severe peri-orbital edema, all of which had

originated four weeks prior to presentation. He had noticed a seven- to eight-pound weight loss within those four weeks as well. He worked in a homeless shelter as an administrator. He was diagnosed and treated for tuberculosis in 1985.

Upon physical examination, the patient was febrile, 104.1°F, had significant peri-orbital edema, along with enlarged and tender lymph nodes in the right parotid region, pre-tragal area, and the anterior cervical region. His laboratory results are given in Table 1, revealing marked neutropenia and lymphopenia.

HOSPITAL COURSE

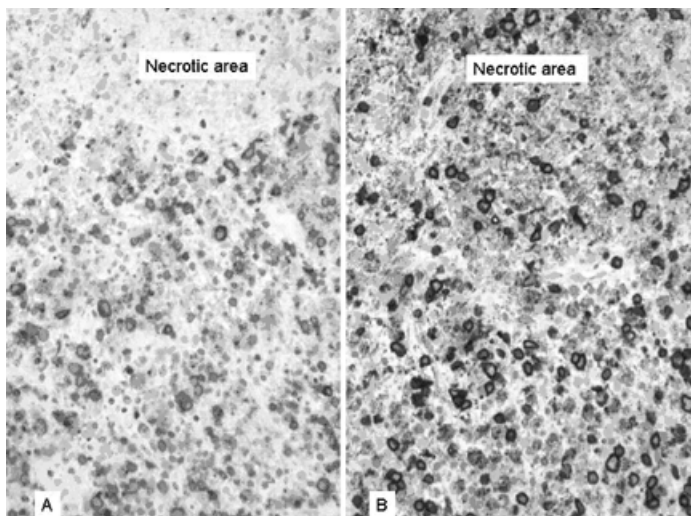
The patient was started on ceftriaxone and azithromycin immediately upon admission, without improvement. On the second admission day, his antibiotic regimen was changed to ceftriaxone and clindamycin, which the patient received for 15 days, but he remained completely unresponsive to therapy. A computed tomography (CT) scan of the head and neck on hospital day three confirmed cervical lymphadenopathy, inflammation of the right parotid gland, and peri-orbital edema (Figure 1). The patient underwent fine needle aspiration (FNA) of

Table 1. Laboratory work-up results of a patient with Kikuchi's disease (all abnormal values are boldfaced).

Complete blood count		Reference Range
White Blood Cells (K/uL)	1.7	4.8 - 10.8
PMN (%)	59.2	42.2 - 75.2
Lymphocytes (%)	33.6	20.5 - 51.1
Eosinophils (%)	0.1	0.0 - 7.0
Monocytes (%)	5.8	1.7 - 9.3
Platelets (K/uL)	189	130 - 400
Hemoglobin (g/dL)	12.4	14.0 - 18.0
Mean Corpuscular Volume (fL)	79.4	80.0 - 94.0
Sedimentation Rate (mm/Hr)	35	0 - 9
Basic metabolic profile		
Sodium (mmol/L)	129	135 - 145
Potassium (mmol/L)	3.1	3.5 - 5.0
Chloride (mmol/L)	94	97 - 107
CO ₂ (mmol/L)	30	24 - 32
BUN (mg/dL)	8.0	8 - 22
Creatinine (mg/dL)	0.8	0.8 - 1.5
Glucose (mg/dL)	135	65 - 110
Liver function tests		
Total bilirubin (mg/dL)	0.4	0.2 - 1.0
AST (alanine aminotransferase U/L)	117	7 - 40
ALT (aspartate aminotransferase U/L)	60	1 - 40
ALP (alkaline phosphatase U/L)	120	30 - 115
LDH (lactate dehydrogenase)	815	100 - 225
Protein, total (g/dL)	5.9	6.0 - 8.0
Albumin (g/dL)	3.0	3.5 - 5.0
Hepatitis C antibody	Positive	Negative
Hepatitis screening	Hepatitis A & B Negative	Negative
C3 complement (mg/dL)	160.0	76.0 - 181.0
C4 complement (mg/dL)	50.7	12.0 - 52.4
ANA Screen	Negative	Negative
Anti-dsDNA	Negative	Negative
Rheumatoid factor (IU/mL)	25.0	0.0 - 11.0
HIV	Negative	Negative
HTLV - I/II	Non-reactive	Non-reactive
CMV AB, IGM (ISR)	2.34	0.0 - 0.9
CMV AB, IGG (ISR)	0.64	0.0 - 0.9
EBV Capsid AB, IGM (ISR)	0.0	0.0 - 0.9
EBV Capsid AB, IGG (ISR)	2.16	0.0 - 0.9
EBV EA AB IgG (strength of signal)	1.34	Neg: 0 - 0.9 Equivocl: 0.91 - 1.09 Pos: > 1.1
All blood cultures	Negative	Negative
All bone marrow cultures	Negative	Negative

Figure 2. Immunoreactivity used in lymph nodes of a patient with Kikuchi's disease.

A. Immunoreactivity for HECA-452 in plasmacytoid monocytes.
 B. Immunoreactivity for PG-M1 (an epitome of CD-68) in plasmacytoid monocytes (immunohistochemistry).



the parotid gland on day nine, which revealed mild acute and chronic inflammation of salivary acinar units and duct epithelium. An excisional lymph node biopsy was performed on day 10. Ceftriaxone and clindamycin were discontinued on day 16. He had his final fever spike on day 20. A gallium scan on day 22 showed infection/inflammation of the right parotid gland, and he was started on intravenous methylprednisolone-succinate 60 mg every 12 hours on day 22. His condition improved, the peri-orbital swelling decreased, and he remained afebrile. The patient was started on oral steroids — prednisone 40 mg per day — on hospital day 24 and was discharged the following day, with a tapered regimen of oral steroids to complete his treatment: prednisone 40 mg daily for three days, 30 mg daily for three days, 20 mg daily for three days, and 10 mg for one day. The patient returned to the emergency room two weeks following discharge, suffering from symptoms of *Clostridium difficile* colitis.

RADIOGRAPHIC FINDINGS

The contrast-enhanced CT scan of the neck revealed enlargement and heterogeneous enhancement of the right parotid gland (Figure 1). Multiple cervical lymph nodes were also noted. These were less than 15 millimeters in size and were uniform in attenuation.

PATHOLOGICAL FINDINGS

The lymph node architecture was extensively effaced by diffuse necrosis that was predominantly paracortical and spared occasional reactive follicles. Necrotic areas contained apoptotic bodies and were surrounded by a cellular proliferation, which included variable proportions of round, pale cells with blastic morphology consistent with plasmacytoid monocytes, transformed lymphocytes, and predominant histiocytes, often with crescentic nuclei. Neutrophils were absent.

Immunophenotyping disclosed that the cells surrounding necrotic areas were mainly activated T-cells, expressing either CD4 or CD8 antigen, and some small CD20 positive B-cells. The immunostain with HECA-452 (directed against cutaneous lymphocyte antigen) highlighted numerous transformed lymphocytes and plasmacytoid monocytes. The latter, along with many macrophages, also expressed PG-M1 (against macrophage-restricted CD68 epitope) (Figure 2). Within the remaining lymphoid areas, CD20 positive B-cells and CD3 positive T-cells were distributed as expected in reactive lymphoid tissue.

A PCR from extracted DNA for immunoglobulin heavy-chain and T-cell receptor gamma chain gene rearrangements failed to reveal a monoclonal cell population. *In situ* hybridization for Epstein-Barr virus-encoded RNA was negative.

The histological findings, together with the immunologic and molecular studies, supported a reactive lymphoid process consistent with the diagnosis of necrotizing histiocytic lymphadenitis (Kikuchi's disease).

DISCUSSION

The etiology of Kikuchi's disease is not entirely known. It has been linked to sequela of infection by human herpes virus 6, cytomegalovirus (CMV), and even human T-lymphotropic virus 1 [8-11]. Recent reports had suggested links between Kikuchi's disease and HHV-8 or Epstein-Barr virus (EBV). These, however were discredited by George et al. [12]. Some case reports have linked Kikuchi's disease to systemic lupus erythematosus (SLE) as well, as patients who attributed their symptoms to Kikuchi's disease went on to develop SLE. This mitigates the hypothesis that Kikuchi's disease may be an autoimmune disease. Serologic tests confirmed that our patient was not infected by any of these pathogens. Although his EBV capsid antibody titers were above the normal limit, signifying a past infection, the *in situ* hybridization for EBV-encoded RNA was negative, indicating he was not actively infected.

The clinical presentation of Kikuchi's disease is very similar to malignant lymphoma, tuberculosis, and systemic lupus erythematosus [13-16]. Laboratory analysis revealed leukopenia and lymphopenia without eosinophilia or basophilia. Elevated erythrocyte sedimentation rate, C reactive protein, and serum lactate dehydrogenase and transaminases were observed [17] (Table 1). He had had a prior infection with tuberculosis, his sputum was repeatedly cultured for acid-fast bacilli and was negative, and he had no evidence of SLE.

The pathologic hallmark of Kikuchi's disease is the presence of an enlarged lymph node with paracortical necrotic foci, which are devoid of neutrophils and surrounded by plasmacytoid monocytes, immunoblasts and crescentic histiocytes. Immunohistochemistry was helpful in identifying characteristic plasmacytoid monocytes. The latter are non-

phagocytic natural type 1 interferon, producing cells more likely involved in cytotoxic immune reactions. Recent studies using CD68 and HECA-452 antibodies, on paraffin-embedded sections, revealed that these antibodies, together with CD4, marked the plasmacytoid monocytes [5,18]. This co-expression of CD68 (PG-M1) and HECA-452 in the plasmacytoid monocytes has been previously reported in Kikuchi's disease.

These histological findings are sufficiently distinctive to permit an accurate diagnosis of Kikuchi's disease, provided systemic lupus erythematosus has been excluded by the appropriate serologic tests. Malignant lymphoma, especially T-cell non-Hodgkins lymphoma, can be mistaken for Kikuchi's disease. Loss of pan T-cell antigens by immunostains and determination of the monoclonality of T cells by molecular studies are necessary for confirming the diagnosis of T-cell lymphoma.

It is possible to use fine needle aspiration cytology (FNAC) to confirm the diagnosis of Kikuchi's disease, but the focal involvement can be completely missed, as illustrated by the equivocal FNAC in our patient. Excisional biopsy eventually was undertaken in our case, which consisted of obtaining diagnostic tissue and a representative picture of its architecture, along with removal of the swollen mass or masses.

Cross-sectional imaging findings in patients with Kikuchi disease have been described as the presence of clusters of many small or mildly enlarged lymph nodes that appeared abnormal, mostly not because of their size but because of the increased number. On CT and MR examination, the lymph nodes were uniform in attenuation and intensity. The cervical lymph nodes are commonly involved, but supraclavicular, axillary, mediastinal, celiac, peripancreatic, and inguinal chain lymph nodes have been reported. The abnormality of the right parotid region in our patient can be attributed to inflammation of the right parotid lymph nodes.

The course of Kikuchi's disease is relatively benign and self limited [8,19,20]. Nevertheless, many therapeutic regimens

have been suggested for shortening its course by reducing swelling and fever spikes. The swelling in our patient was clinically noteworthy, particularly in the right peri-orbital region, where he was unable to open his eye. While we do not advocate the use of any therapy to treat Kikuchi's disease, steroid therapy is recommended by some to alleviate the related symptoms, such as the marked swelling. Steroid therapy, particularly prednisone, can benefit patients suffering from symptoms such as severe edema and fever, although our patient became afebrile two days prior to the start of his steroid regimen [3,21]. One case report described the use of chloroquine to alleviate symptoms over a five-month period [2]. Another case study described the use of minocycline, which alleviated symptoms in 10 days, encouraging the idea that this disease might be the result of microorganism, rather than an autoimmune etiology [22]. These, however, were the results of single case reports with no follow-up studies to our knowledge. We discourage antibiotic use for Kikuchi's disease, particularly as no causative microorganism has been identified and the detrimental side effects these regimens can have, as witnessed in our patient. We encourage the use of a tapered steroid regimen, as it was efficacious and of short duration. Our patient was placed on a steroidal regimen, previously described, and responded dramatically with complete alleviation of the peri-orbital swelling within two weeks; the patient also maintained his afebrile state throughout the entire course. The proposed steroid therapy with a dosage regimen is unique to our knowledge in the realm of Kikuchi's disease management.

Our case report reinforces the idea that although Kikuchi's disease does predominantly affect young women, it can appear at all ages, irrespective of gender. The constellation of clinical findings consisting of regional lymphadenopathy, fever, marked leukopenia in the presence of characteristic histiocytic necrotizing lymphadenitis, and pathological analysis provide the diagnosis. Although many treatment regimens have been recommended, there has not been any

established therapy for this disease, nor have any therapeutic trials been undertaken to our knowledge.

ACKNOWLEDGEMENTS: We thank Dr. Ralph Carmel for his helpful review of the manuscript and Matthew J. Dinzey for his help with the images.

REFERENCES

1. Dorfman RF, Berry GJ. Kikuchi's histiocytic lymphadenitis: An analysis of 108 cases with emphasis on differential diagnosis. *Sem Diagn Path.* 1988;5:329-45.
2. Amir A, Amr SS, Sheikh SS. Kikuchi-Fujimoto's disease: report of familial occurrence in two human leucocyte antigen-identical non-twin sisters. *J Int Med.* 2002;252:79-83.
3. Rakic L, Arrese JE, Thiry A, Pierard GE. Kikuchi-Fujimoto lymphadenitis with cutaneous involvement. *J Eur Acad Dermatol Venereol.* 1999;13:118-22.
4. Mannara GM, Boccato P, Rinaldo A, La Rosa F, Ferlito A. Histiocytic necrotizing lymphadenitis (Kikuchi-Fujimoto disease) diagnosed by fine needle aspiration biopsy. *J Otorhinolaryngol Relat Spec.* 1999;61:367-71.
5. Asano S, Akaike Y, Muramatsu T, et al. Necrotizing lymphadenitis: a clinicopathological and immunohistochemical study of four familial cases and five recurrent cases. *Virchows Arch Pathol Anat.* 1991;418:215-23.
6. Pileri S, Kikuchi M, Helbron D, Lennert K. Histiocytic necrotizing lymphadenitis without granulocytic infiltration. *Virchows Arch A Pathol Anat Histol.* 1982;395:257-71.
7. Turner RR, Martin J, Dorfman RF. Necrotizing lymphadenitis: a study of 30 cases. *Am J Surg Pathol.* 1983;7:115-123.
8. Lopez C, Oliver M, Olavarria R, Sarabia MA, Chopite M. Kikuchi-Fujimoto necrotizing lymphadenitis associated with cutaneous lupus erythematosus: a case report. *Am J Dermatopathol.* 2000;22:328-33.
9. Martinez-Vazquez C, Hughes G, Bordon J, Alonso-Alonso J, Anibarro-Garcia A, Redondo-Martinez E, Touza-Rey F. Histiocytic necrotizing lymphadenitis, Kikuchi-Fujimoto's disease, associated with systemic lupus erythematosus. *QJM.* 1997;90:531-3.
10. Bataille V, Harland CC, Behrens J, Cook MG, Holden CA. Kikuchi disease (histiocytic necrotizing lymphadenitis) in association with HTLV1. *Br J Dermatol.* 1997; 136:610-2.
11. Spies J, Foucar K, Thompson CT, and LeBoit PE. The histopathology of cutaneous lesions of Kikuchi's disease (necrotizing lymphadenitis): a report of five cases. *Am J Surg Pathol.* 1999;23:1040-7.
12. George TI, Jones CD, Zehnder JL, Warnke RA, Dorfman RF. Lack of human herpesvirus

- 8 and Epstein-Barr virus in Kikuchi's histiocytic necrotizing lymphadenitis. *Hum Pathol.* 2003;34:130-5.
13. Jayaraj SM, Lloyd J, Frosh AC, Patel KS. Kikuchi-Fujimoto's syndrome masquerading as tuberculosis. *J Laryngol Otol.* 1999;113:82-4.
 14. Garcia CE, Girdhar-Gopal HV, Dorfman DM. Kikuchi-Fujimoto disease of the neck. Update. *Ann Otol Rhinol Laryngol.* 1993;102:11-15.
 15. Baumgartner BJ, Helling ER. Kikuchi's disease: a case report and review of the literature. *Ear Nose Throat J.* 2002;81:331-5.
 16. Komocis A, Tovari E, Pajor L, Czirjak L. Histiocytic necrotizing lymphadenitis preceding systemic lupus erythematosus. *J Eur Acad Dermatol Venereol.* 2001;15:476-80.
 17. Sierra ML, Vegas E, Blanco-Gonzalez JE, Gonzalez A, Martinez P, Calero MA. Kikuchi's disease with multisystemic involvement and adverse reaction to drugs. *Pediatrics.* 1999;104:24.
 18. Pileri SA, Facchetti F, Ascani S, et al. Myeloperoxidase expression by histiocytes in Kikuchi's and Kikuchi-like lymphadenopathy. *Am J Pathol.* 2001;159:915-24.
 19. Aguiar JI, Paniago AM, Aguiar ES, Cunha R, Odashiro M, Takita L. Kikuchi's disease: report of two cases and a brief review of the literature. *Braz J Infect Dis.* 2000;4: 208-11.
 20. Louis N, Hanley M, Davidson NM. Kikuchi-Fujimoto disease: a report of two cases and an overview. *J Laryngol Otol.* 1994;108:1001-4.
 21. Jang YJ, Park KH, Seok HJ. Management of Kikuchi's disease using glucocorticoid. *J Laryngol Otol.* 2000;114:709-11.
 22. Takada K, Suzuki K, Hidaka T, et al. Immediate remission obtained by minocycline in a patient with histiocytic necrotizing lymphadenitis. *Int Med.* 2001;40:1055-8.