

Locked Plate Fixation of Proximal Humeral Fractures Through an Extended Deltoid Split Approach with Use of a Shoulder Strap Incision

Ashok S. Gavaskar, MS Ortho, Naveen Tummala, MS Ortho, Parthasarathy Srinivasan, DNB Ortho, Vinoth Kumar, DNB Ortho, Ramakanth Rajagopalan, DNB Ortho, and Prasad Sorganvi, MS Ortho

Based on an original article: *J Orthop Trauma*. 2013 Feb;27(2):73-6.

Introduction

The shoulder strap approach involves an anterolateral deltoid split with use of an inverted U incision, providing excellent lateral exposure for locked plate fixation of complex proximal humeral fractures.

Locked plate fixation is a successful technique for osteosynthesis of unstable proximal humeral fractures. The anteriorly based deltopectoral approach is conventionally used for fracture fixation. However, surgeons using that approach may find it difficult to obtain adequate lateral exposure to reduce the displaced greater tuberosity and insert fixed-angle screws and may need to perform excessive deltoid retraction¹. The anterolateral deltoid-splitting approach has emerged as a safe and effective alternative to the deltopectoral approach for internal fixation of these fractures².

The deltoid split approach can be performed with either a longitudinal anterolateral incision or a shoulder strap incision³. The shoulder strap incision is performed by raising a distally based skin flap from the tip of the acromion. This “bra strap” incision is beneficial from a cosmetic standpoint and provides excellent access, especially in obese and muscular patients, without the need for skin retraction.

Step 1: Positioning of the Patient and the Image Intensifier (Video 1)

Proper positioning of the image intensifier is important for uninterrupted fluoroscopy.

- Place the patient in a beach-chair position.
- Drape the shoulder area free and make it amenable for fluoroscopy.
- Position the patient's head and secure it with tape to avoid unwanted movements during surgery.
- Position the image intensifier on the opposite

side, and maneuver it to obtain true anteroposterior (Grashey) and modified axial views of the shoulder.

Step 2: Skin Incision (Video 1)

The tip of the acromion is a useful landmark and serves as the proximal extent of the incision.

- Make the skin incision in an inverted U-shaped fashion with the proximal apex centered on the tip of the acromion (Fig. 1).
- Carry the anterior and posterior limbs of the incision distally. The distal extent depends on the length of the chosen plate; aim to accommodate a three-holed plate. Further distal fixation, if needed, can be performed through stab incisions.
- Infiltrate a long-acting local anesthetic mixed with 0.5% epinephrine to minimize bleeding from the flap and provide postoperative pain relief.

Step 3: Raise the Distally Based Fasciocutaneous Flap (Video 1)

Raise a broad-based full-thickness fasciocutaneous flap.

- Raise a full-thickness flap, dissecting deep to the muscular fascia, without undermining the skin (Fig. 2).
- Proximal extension, if required, can be performed by elevating a portion of the anterior deltoid with a sliver of bone from the clavicle.
- Distal extension of the flap is not recommended to minimize the chance of necrosis.
- If a longer plate is needed, place distal screws through separate stab incisions.
- In the rare situation in which deltopectoral access is needed, obtain it through the anterior part of the incision.

Step 4: Creation of the Proximal Working Window (Video 2)

Split the deltoid anteriorly to minimize the chances of denervation.

- Split the deltoid between the anterior and middle portions of the muscle (Fig. 3). This interval is marked by a relatively avascular raphe.
- Split the muscle bluntly for a distance of 4 to 6 cm from the tip of the acromion. The distal extent is limited by the presence of the axillary nerve.
- After splitting the muscle, incise the underlying subdeltoid bursa to expose the fractured segments (Fig. 4).
- After identification of the axillary nerve, create the distal working window for placement of screws into the distal segment.

Step 5: Identification and Protection of the Axillary Nerve (Video 2)

Leave a cuff of deltoid muscle to protect the axillary nerve.

- The axillary nerve courses the deltoid muscle transversely in a posterior-to-anterior direction, supplying innervation to the muscle. Its course lies at a distance of 4 to 6 cm distal to the tip of the acromion.
- Pass a finger under the deltoid through the proximal working window with the shoulder abducted to 40°.
- Identify the nerve as a palpable cord coursing transversely under the belly of the muscle. Then create the distal working window, leaving a cuff of muscle around the nerve (Fig. 5).
- Introduce right-angled forceps from the distal working window and use a wire loop to isolate and protect the axillary nerve.

Step 6: Placement of Traction Cuff Sutures (Video 2)

The cuff sutures are helpful in reduction of the proximal fracture segments and improve stability of three and four-part fractures.

- Pass three heavy (number-5) nonabsorbable Ethibond sutures (Ethicon) at the tuberosity-rotator cuff junction, in the anterior, posterior, and superior cuff regions (Fig. 6).
- The sutures are guided into the eyelets of the plate (PHILOS, Synthes) before positioning of the plate on the proximal part of the humerus. The sutures are tied to the plate at the end of

the procedure.

- The superior cuff suture can be used to manipulate and reduce the humeral head out of a varus position.
- When treating a patient with a three or four-part fracture, place two additional sutures into the anterior and posterior aspects of the cuff and tie them together to reduce the tuberosities.

Step 7: Reduction of the Head and Tuberosity Fragments (Video 3)

Avoid varus reduction and reestablish the relationship between the humeral head and the greater tuberosity.

- Reduce the head fragment in an atraumatic manner.
- For valgus impacted fractures, broad-based elevators and bone tamps can be used to disimpact the head.
- Traction sutures, Kirschner wires used as joysticks, and sometimes endosteal struts are useful to reduce the head fragment out of varus (Fig. 7).
- After reducing the head fragment, reduce the tuberosity fragments to each other and hold them in place with the cuff sutures. In patients with a three or four-part fracture, the biceps tendon can be tenodesed with use of drill holes into the proximal part the humerus below the intertubercular sulcus.
- Kirschner wires can also be used to provisionally hold the reduced proximal fracture fragments together and to the distal shaft fragment.
- Make sure that placement of Kirschner wires does not impede plate placement on the lateral aspect of the shaft.
- Place two Kirschner wires for provisional fracture fixation: one from the greater tuberosity to the inferomedial aspect of the neck and one from the anterior aspect of the shaft into the head.
- Reduction is satisfactory if the medial calcar is reconstructed to reestablish the Gothic arch and the greater tuberosity is reduced to 6 to 8 mm below the top of the humeral head.
- Confirm fracture reduction using true antero-posterior and modified axial fluoroscopic views⁴ before applying the plate.

Step 8: Plate Placement (Video 4)

Proper plate positioning is important to maximize the possibility of using all proximal screw options and to minimize chances of impingement.

- With the traction cuff sutures already passed

through the eyelets of the plate, slide the plate under the axillary nerve under direct vision. Shoulder abduction eases the tension on the nerve.

- Make sure to center the plate over the greater tuberosity and on the humeral shaft.
- The proximal tip of the plate should be at least 6 to 8 mm below the superior extent of the humeral head to prevent subacromial impingement.
- The plate should sit posterior to the bicipital groove on the greater tuberosity.
- Center the plate accurately on both the proximal and the distal segments to make use of all possible screw options.

Step 9: Fracture Fixation (Video 4)

As is necessary with all locked internal fixators, reduce the fracture before fixing the plate; the order of fixation may vary with the type of fracture.

- Fix the proximal (anatomical) portion of the plate first with multiple locked screws.
- If necessary, place a cortical screw ("reduction screw") first into the shaft segment through the oblong hole of the PHILOS plate to reduce the shaft under the humeral head (Fig. 8). Use the reduction screw only if there is medial displacement of the shaft or else it may lateralize the shaft and leave the humeral head unsupported.
- The inferomedial calcar screws (row D in the PHILOS plate) are important to prevent varus instability⁵ (Fig. 9).
- Make sure that the screw tip in the humeral head reaches subchondral bone to improve holding strength⁶.
- Subchondral screw placement can be facilitated by continuous fluoroscopy and palpable "sounding."⁷
- Placement of five, six, or seven locking screws, including the important calcar screws, into the humeral head is recommended for complex three and four-part fractures⁸.
- In patients with osteoporosis, endosteal strut grafts can be used to provide structural support and to prop up the humeral head to prevent varus displacement⁹.

Results

In our study of fifty patients with a displaced three or four-part fracture treated with this approach, all flaps healed well without any necrosis and no infections were seen¹⁰. Anatomical reduction of the head and tuberosity fragments with a normal head-shaft angle (120° to 150°) was achieved in forty-two patients. Electrodiag-

nostic evaluation performed as part of the study showed transient dysfunction of the anterior portion of the axillary nerve in four (8%) of the fifty patients.

Initial varus malreduction was seen in four patients (8%) and further loss of reduction (varus of >20°) was seen in two patients. Osteonecrosis of the humeral head was seen in two patients (4%). Revision to acromioplasty was performed in three patients (6%). The mean normalized Constant and Murley score¹¹ at one year was 80.2 ± 7.7.

What to Watch For

Indications

- The approach is best suited for displaced two-part surgical neck fractures, three-part (greater tuberosity) fractures, and valgus impacted fractures.
- The shoulder strap incision is especially useful in obese patients when a deltoid split approach is contemplated.
- The incision is cosmetically preferable to the straight anterolateral incision.
- The incision heals predictably as it is along the relaxed skin tension lines¹².
- The shoulder strap approach can also be used successfully for humeral head replacement procedures¹³.

Contraindications

- Anterior fracture-dislocations are difficult to treat through the approach.
- Atraumatic retrieval of the dislocated head fragment may be difficult because of the lack of medial access.
- Attempts at retrieval of the head fragment may increase the tension on the axillary nerve, making it vulnerable to injury.
- Complex head-splitting fractures are difficult to fix through the approach¹⁴.

Pitfalls & Challenges

- With the patient in a beach-chair position, it is very important to obtain proper fluoroscopic views to assess fracture reduction and screw position in the humeral head. True anteroposterior (Grashey) views (i.e., with the shoulder in slight external rotation) and modified axial views can be easily obtained with the image intensifier from the opposite side.
- The possibility of injury to the anterior portion of the axillary nerve is the main challenge and chief limitation of the approach. Leaving a cuff of muscle ensheathing the axillary nerve helps

to protect the nerve throughout the course of the procedure.

- The axillary nerve lies close to the calcar screw holes in the PHILOS plate, and it can be challenging to insert those screws safely. Abduction of the shoulder brings the axillary nerve above the calcar screw holes, making it safer to insert the screws (Fig. 10).
- Fracture-dislocations and head-split fractures are challenging to fix because of a lack of direct access to the articular segments.
- The prevalence of neurophysiological dysfunction of the anterior portion of the axillary nerve is higher with fracture-dislocations than it is with three and four-part fractures.
- Improper plate positioning is one of the important pitfalls encountered with this approach. It is important to position the plate properly in the craniocaudal and anteroposterior planes.
- It is advisable to make sure that the calcar screws will go into the inferomedial portion of the humeral head before finalizing the plate position in the craniocaudal plane.
- Proper plate placement in the anteroposterior plane will prevent plate offset on the shaft. It also allows safe and accurate placement of the divergent locking screws (row C in the PHILOS plate) in the humeral head without the risk of penetration (Fig. 11).

be safely approached and fixed satisfactorily through the deltoid split approach.

- Use of a shoulder strap incision for the deltoid split approach results in a more cosmetically acceptable scar and is more convenient, especially in obese patients, and obviates the need for skin retraction.
- The incision is made along the relaxed skin tension lines of the shoulder girdle and heals predictably.
- The approach provides superior access to the lateral side compared with the deltopectoral approach and allows gentle reduction of the displaced greater tuberosity fragments.
- Because the approach provides virtually no access to the anteromedial aspect of the proximal part of the humerus, it is less useful for fracture-dislocations.
- The approach is also better from a biological standpoint as it does not interfere with the blood supply to the humeral head.
- The axillary nerve should be protected throughout the procedure, especially during fracture manipulation and screw insertion.
- We encountered transient electrophysiological dysfunction of the axillary nerve supplying the anterior deltoid in 8% of our fifty patients¹⁰. No permanent deficits were noted. Nerve dysfunction was more frequent after treatment of anterior fracture-dislocations.

Clinical Comments

- Most complex proximal humeral fractures can

Ashok S. Gavaskar, MS Ortho

Vinoth Kumar, DNB Ortho

Ramakanth Rajagopalan, DNB Ortho

Prasad Sorganvi, MS Ortho

Department of Orthopaedic Traumatology, Parvathy Hospital, 63A/44, Gandhi Road, Choolaimedu, Chennai 600094, India. E-mail address for A.S. Gavaskar: gavaskar.ortho@gmail.com

Naveen Tummala, MS Ortho

Dhruv Clinics, Thiruvannamiyur, Chennai 600041, India

Parthasarathy Srinivasan, DNB Ortho

Mehta Hospital, Chetpet, Chennai 600031, India

Disclosure: None of the authors received payments or services, either directly or indirectly (i.e., via his or her institution), from a third party in support of any aspect of this work. None of the authors, or their institution(s), have had any financial relationship, in the thirty-six months prior to submission of this work, with any entity in the biomedical arena that could be perceived to influence or have the potential to influence what is written in this work. Also, no author has had any other relationships, or has engaged in any other activities, that could be perceived to influence or have the potential to influence what is written in this work. The complete **Disclosures of Potential Conflicts of Interest** submitted by authors are always provided with the online version of the article.

References

1. Wu CH, Ma CH, Yeh JJ, Yen CY, Yu SW, Tu YK. Locked plating for proximal humeral fractures: differences between the deltopectoral and deltoid-splitting approaches. *J Trauma*. 2011 Nov;71(5):1364-70.
2. Gardner MJ, Lorich DG, Werner CML, Helfet DL. Second-generation concepts for locked plating of proximal humerus fractures. *Am J Orthop (Belle Mead NJ)*. 2007 Sep;36(9):460-5.
3. Robinson CM, Page RS. Severely impacted valgus proximal humeral fractures. *J Bone Joint Surg Am*. 2004 Sep;86(Pt 2)(Suppl 1):143-55.
4. Shenton AF, Olney D. The modified axial view: an alternative radiograph in shoulder injuries. *Arch Emerg Med*. 1987 Sep;4(3):201-3.
5. Gardner MJ, Weil Y, Barker JU, Kelly BT, Helfet DL, Lorich DG. The importance of medial support in locked plating of proximal humerus fractures. *J Orthop Trauma*. 2007 Mar;21(3):185-91.
6. Liew AS, Johnson JA, Patterson SD, King GJ, Chess DG. Effect of screw placement on fixation in the humeral head. *J Shoulder Elbow Surg*. 2000 Sep-Oct;9(5):423-6.
7. Bengard MJ, Gardner MJ. Screw depth sounding in proximal humerus fractures to avoid iatrogenic intra-articular penetration. *J Orthop Trauma*. 2011 Oct;25(10):630-3.
8. Ong CC, Kwon YW, Walsh M, Davidovitch R, Zuckerman JD, Egol KA. Outcomes of open reduction and internal fixation of proximal humerus fractures managed with locking plates. *Am J Orthop (Belle Mead NJ)*. 2012 Sep;41(9):407-12.
9. Chow RM, Begum F, Beaupre LA, Carey JP, Adeeb S, Bouliane MJ. Proximal humeral fracture fixation: locking plate construct \pm intramedullary fibular allograft. *J Shoulder Elbow Surg*. 2012 Jul;21(7):894-901. Epub 2011 Jul 22.
10. Gavaskar AS, Chowdary N, Abraham S. Complex proximal humerus fractures treated with locked plating utilizing an extended deltoid split approach with a shoulder strap incision. *J Orthop Trauma*. 2013 Feb;27(2):73-6.
11. Constant CR, Murley AH. A clinical method of functional assessment of the shoulder. *Clin Orthop Relat Res*. 1987 Jan;(214):160-4.
12. Borges AF. Relaxed skin tension lines. *Dermatol Clin*. 1989 Jan;7(1):169-77.
13. Robinson CM, Khan L, Akhtar A, Whittaker R. The extended deltoid-splitting approach to the proximal humerus. *J Orthop Trauma*. 2007 Oct;21(9):657-62.
14. Gavaskar AS, Tummala NC. Locked plate osteosynthesis of humeral head-splitting fractures in young adults. *J Shoulder Elbow Surg*. 2014 Dec 1. Epub 2014 Dec 1.

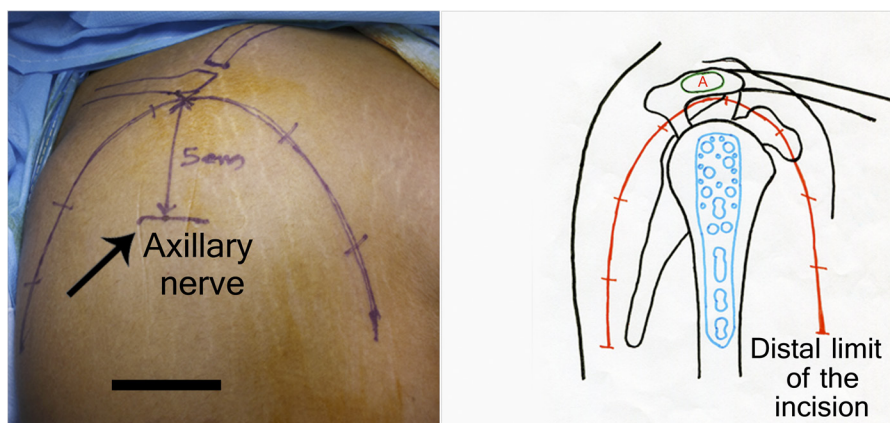


Fig. 1

Intraoperative view of the right shoulder and line diagram showing the shoulder strap incision. The position of the axillary nerve (arrow) is marked at 5 cm from the acromion. The incision extends proximally up to the tip of the acromion (A), and the distal limit should accommodate a three-holed plate (black solid line on the photograph).

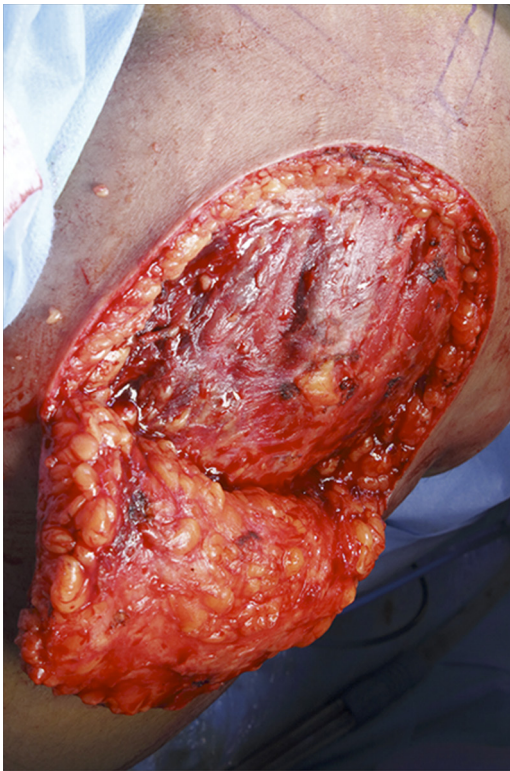

Fig. 2

The distally based full-thickness skin flap should be raised without undermining the skin.

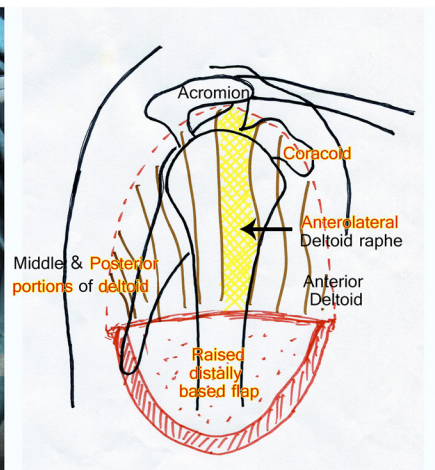
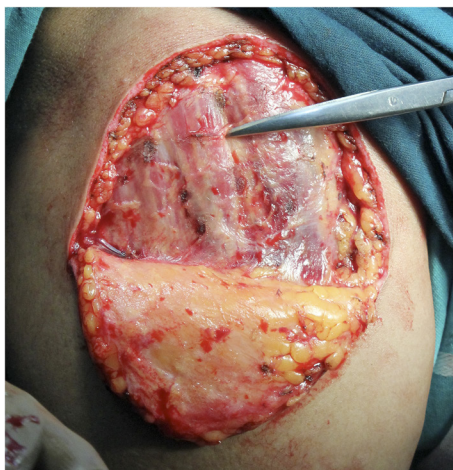

Fig. 3

The deltoid raphe (shaded yellow in the line diagram) between the anterior and middle portions of the deltoid represents a “watershed” area and provides a relatively avascular plane.

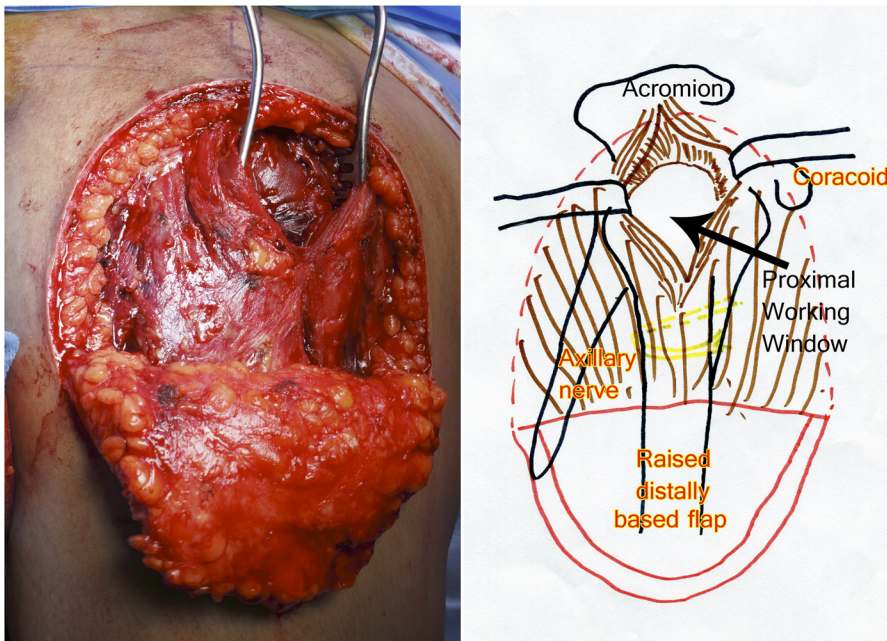


Fig. 4

The proximal working window is created, exposing the underlying subdeltoid bursa (black solid arrow). The distal working window is created after identifying the axillary nerve (outlined in yellow in the line diagram) by palpation.

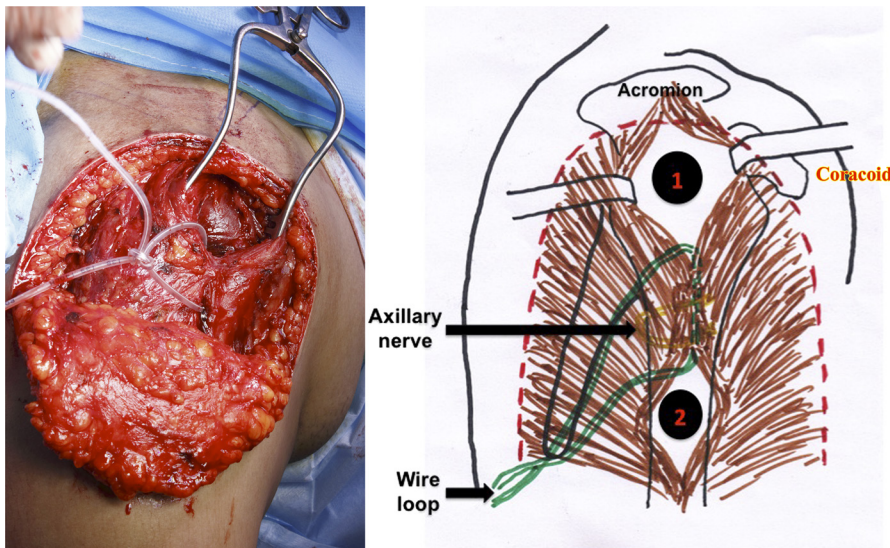


Fig. 5

One centimeter of the deltoid muscle is left as a cuff around the axillary nerve to minimize the possibility of an inadvertent injury. A wire loop (green) is used to protect the nerve throughout the procedure. 1 = proximal window, and 2 = distal window.

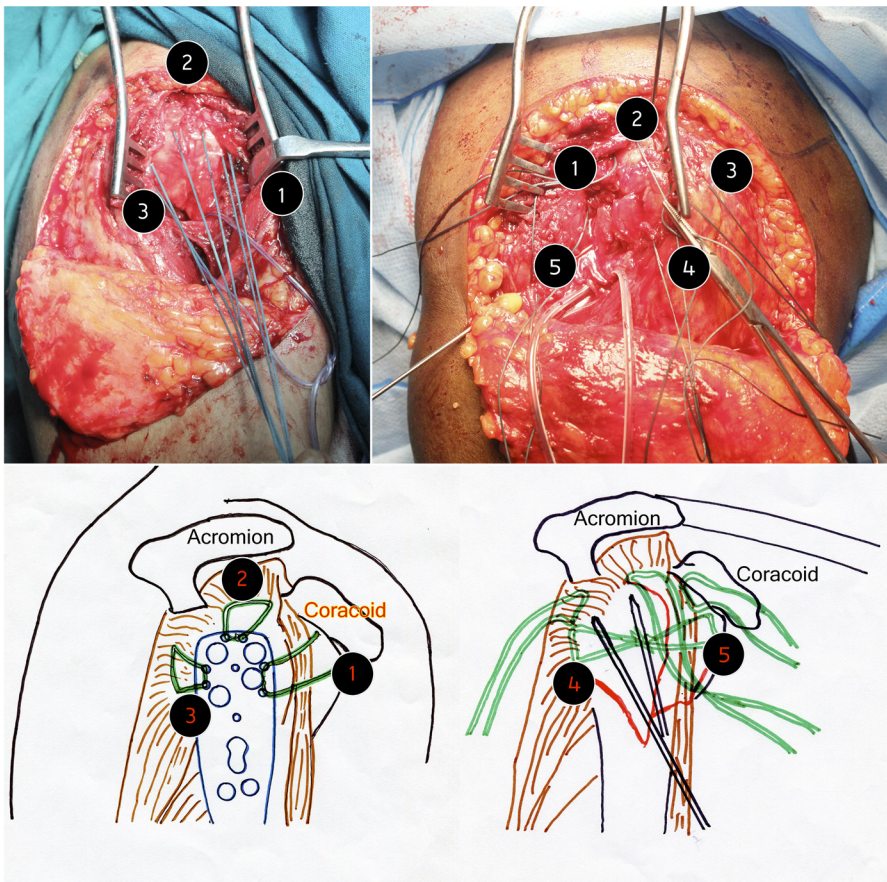


Fig. 6

Three heavy nonabsorbable traction sutures (green in bottom left line diagram) are placed in the cuff-bone junction in the anterior (1), superior (2), and posterior (3) portions of the rotator cuff. Additional sutures are placed in the posterior (4) and anterior (5) portions of the cuff to reduce the tuberosities in patients with a three or four-part fracture.

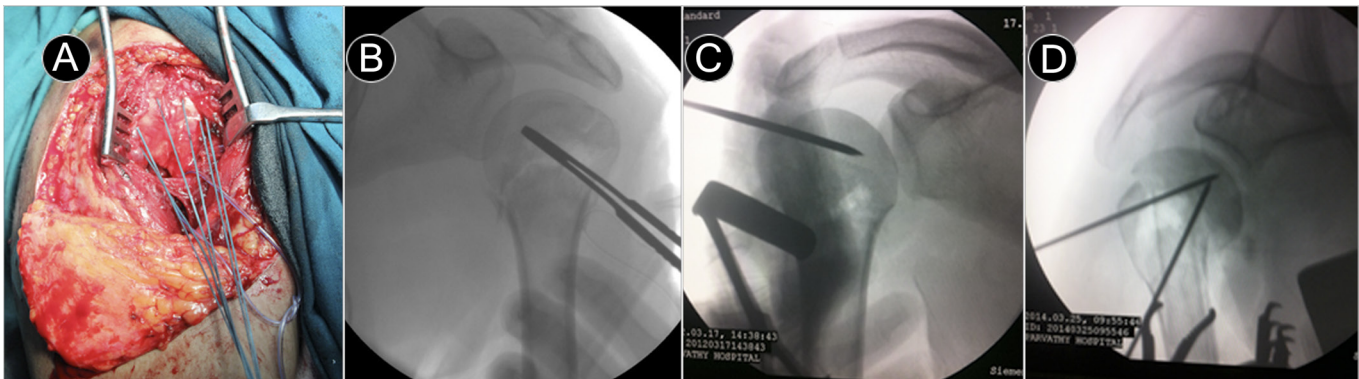


Fig. 7

Fracture reduction techniques. Cuff sutures (A), blunt elevators (B), and Kirschner wires (C and D) can be used to manipulate the head fragment and achieve reduction. Intramedullary fibular struts can also be used in patients with osteoporosis or medial comminution.

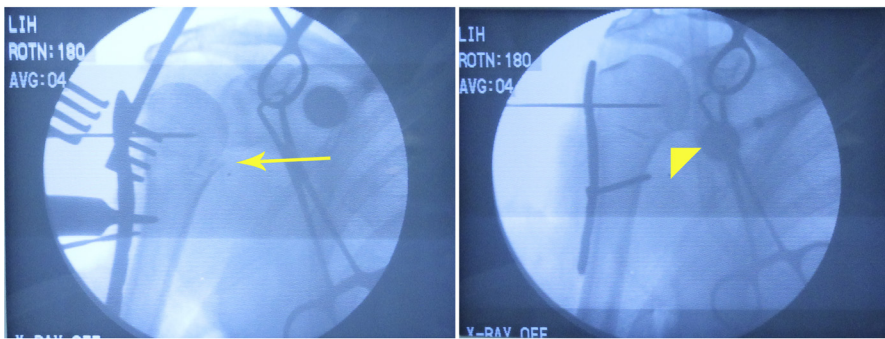


Fig. 8

A medially displaced shaft (arrow) can be reduced under the humeral head by using a cortical screw through the oblong hole in the shaft segment of the PHILOS plate to reconstruct the medial calcar (arrowhead).

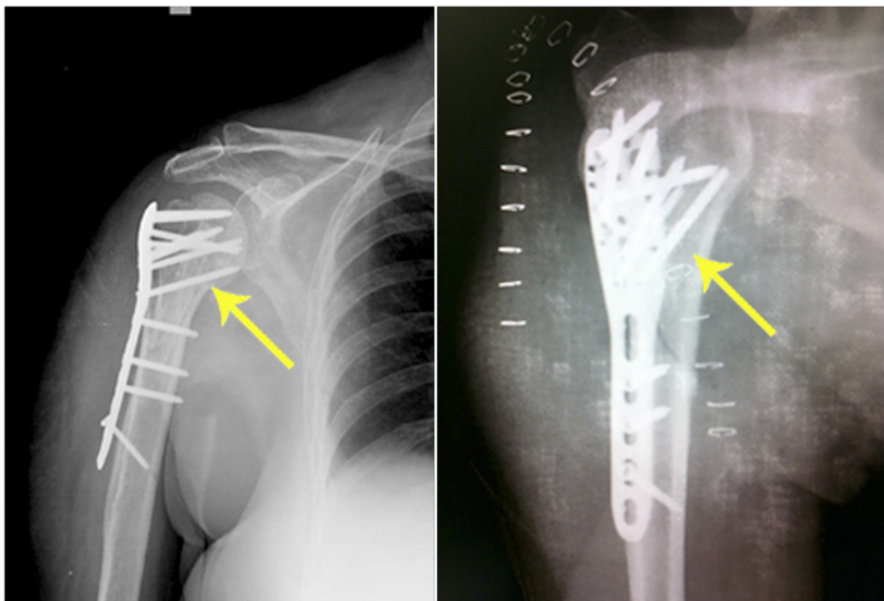


Fig. 9

The two inferomedial (calcar support) screws (arrows) are extremely important in preventing varus deformation in three and four-part fractures. The screws should be placed well inferiorly to improve purchase and to provide the desired effect.

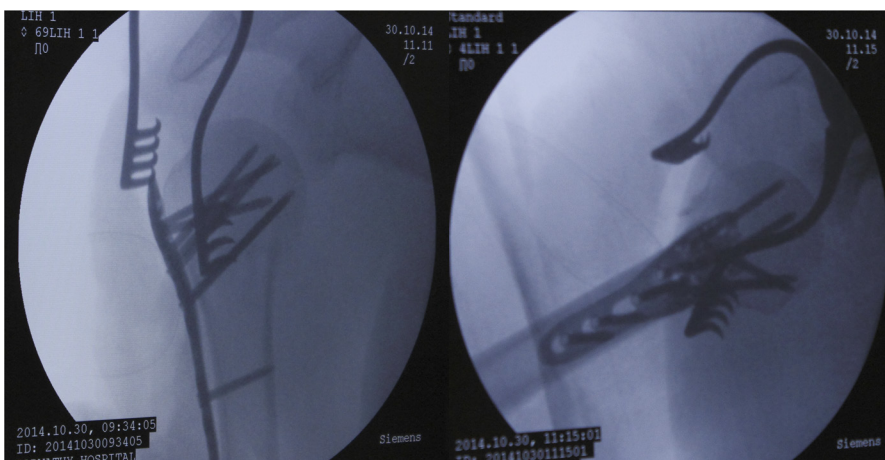


Fig. 10

True anteroposterior fluoroscopic views made with the shoulder in 10° of external rotation and the arm perpendicular to the image intensifier and modified axial views made with the shoulder abducted and internally rotated are important for fracture reduction, plate placement, and screw insertion.

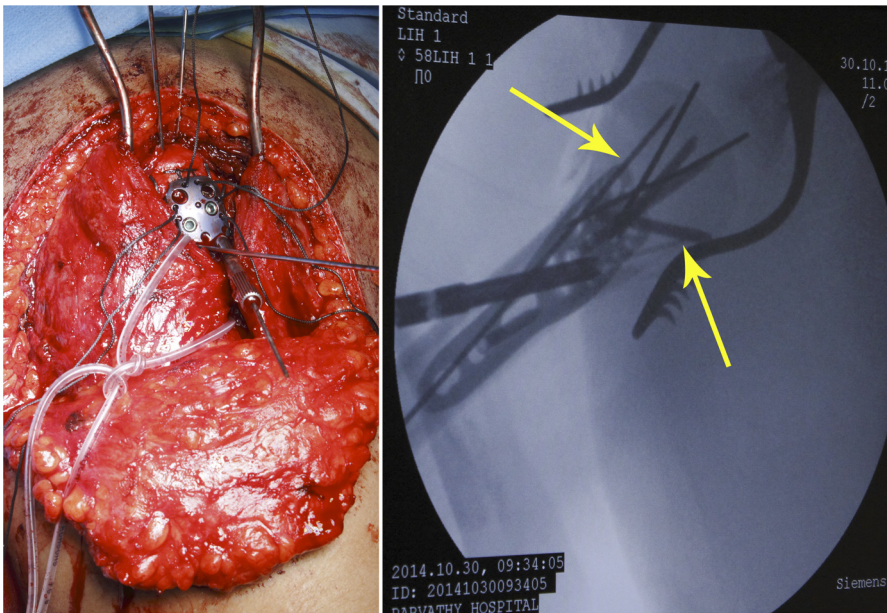


Fig. 11

The divergent screws through row C of the plate can easily penetrate the humeral head. This can be prevented by accurate plate positioning on the humeral head and by using the axial view to verify screw position.