

Case Report

---

# Voluntary Flutter Presenting During Ophthalmoscopy: A Case Report

Nikita Thomas Matt J. Dunn J. Margaret Woodhouse

School of Optometry and Vision Sciences, Cardiff University, Cardiff, UK

## Keywords

Voluntary flutter · Voluntary nystagmus · Saccadic · Autism spectrum disorder · Direct ophthalmoscopy

## Abstract

Voluntary flutter (sometimes known as “voluntary nystagmus”) is a conjugate saccadic oscillation of the eyes that occurs in some healthy individuals. It has no relation to pathological nystagmus, which can manifest in infancy or become acquired later in life. This report presents an unusual case of voluntary flutter that presented in a 20-year-old male with autism spectrum disorder during ocular examination via direct ophthalmoscopy. Refraction and ocular motor balance were normal, and visual acuity was good in each eye (–0.10 logMAR). During direct ophthalmoscopy, a fine intermittent tremor was initiated. The patient was referred for further assessment, and eye movements were recorded at 1,000 Hz with an EyeLink 1000 eye tracker. Upon request, the patient could manifest voluntary flutter again and sustain the eye movements with effort during convergence. The voluntary flutter consisted of back-to-back saccadic oscillations in a predominantly horizontal direction, with an average frequency of 13 Hz and an amplitude of ~8°, both reducing over time. We speculate that the discomfort induced by the proximity of the clinician during direct ophthalmoscopy examination may have triggered the eye oscillations. Although the oscillations typically manifest during convergence, atypical forms of voluntary flutter can also occur during divergence. Voluntary flutter can be a useful differential diagnosis in patients with a recently onset apparent “nystagmus,” and no other neurological signs and symptoms.

© 2022 The Author(s).  
Published by S. Karger AG, Basel

---

Correspondence to:  
J. Margaret Woodhouse, [woodhouse@cardiff.ac.uk](mailto:woodhouse@cardiff.ac.uk)

## Introduction

Some healthy individuals can voluntarily produce high-frequency eye movements, referred to as “voluntary flutter” (also known variously as voluntary nystagmus, psychogenic flutter, voluntary ocular fibrillation, voluntary ocular oscillation, psychological nystagmus, hysterical nystagmus, and ocular shuddering) [1–4]. Although voluntary flutter is associated with oscillopsia [1] and lid fluttering [1, 2], it has no relation to pathological nystagmus, which may develop in infancy or may be acquired later in life. Many individuals are aware of their ability to produce voluntary flutter and may do so as a “party trick” to amuse others [1–3]. A survey conducted by Zahn [4] found that 8% of a University age population possessed this ability, and that of these individuals, 79% knew of relatives who could also induce it. A recent report indicates that some individuals may produce voluntary flutter involuntarily [5]. Although the presentation of voluntary flutter is relatively rare, it is a repeated cause of referral, especially in older children [6].

Here, we present findings from a patient in whom voluntary flutter presented during ocular examination via direct ophthalmoscopy. We hypothesize that these eye oscillations were initiated by the discomfort induced from the proximity of the clinician during funduscopy, which has not been noted before in the literature. Analysis of the eye movements revealed the back-to-back horizontal saccadic oscillations typical of voluntary flutter. The patient was eventually able to also elicit these eye movements on request, with convergence.

## Case Report/Case Presentation

A 20-year-old male attended for a routine sight test. He had a diagnosis of autism spectrum disorder but was otherwise fit and healthy with no systemic disease or regular medications. Refraction and ocular motor balance were unremarkable, and visual acuity was good (−0.10 logMAR in each eye). Pupil responses, vestibulo-ocular responses, and convergence were all normal. During direct ophthalmoscopy, a fine intermittent tremor was noted in the eye under examination. On questioning, the patient was unaware that his eyes were moving. The patient was referred for nystagmus eye movement recordings comprising:

- Fixation on each of five fixation points across the horizontal midline spanning  $\pm 20^\circ$  (to assess the presence of a null zone, indicating infantile nystagmus) for 10 s each.
- Fifteen seconds monocular fixation in the primary position with each eye (to check for latent nystagmus).
- Fifteen seconds binocular convergence (to check for dampening or exacerbation of infantile nystagmus).
- Seven minutes' central fixation (to check for periodic alternating nystagmus).

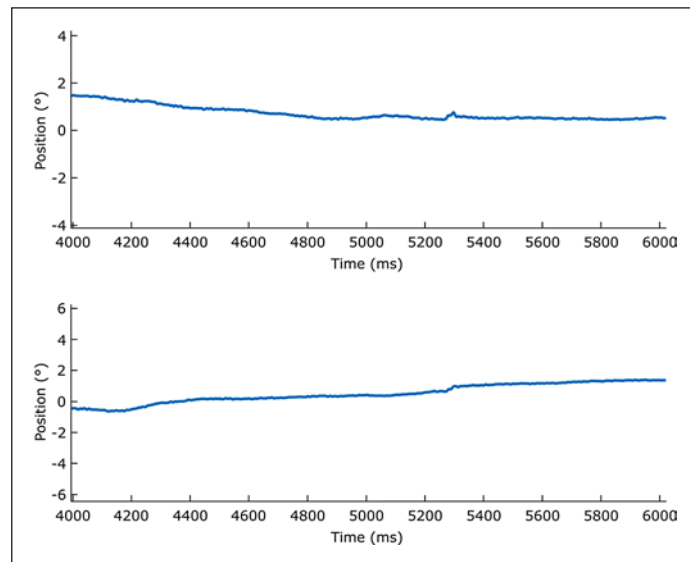
Eye movements were recorded at 1,000 Hz with the head stabilized by a chinrest using an EyeLink 1000 (SR Research, Ottawa, ON, Canada). A red fixation cross of diameter  $2^\circ$  was presented in the primary position (straight ahead) at a distance of 1 m on a large (2,000 × 1,430 mm) screen. Room lights were extinguished prior to stimulus presentation. Nystagmus was also assessed clinically by an optometrist using a pen torch.

### *Eye Movement Findings*

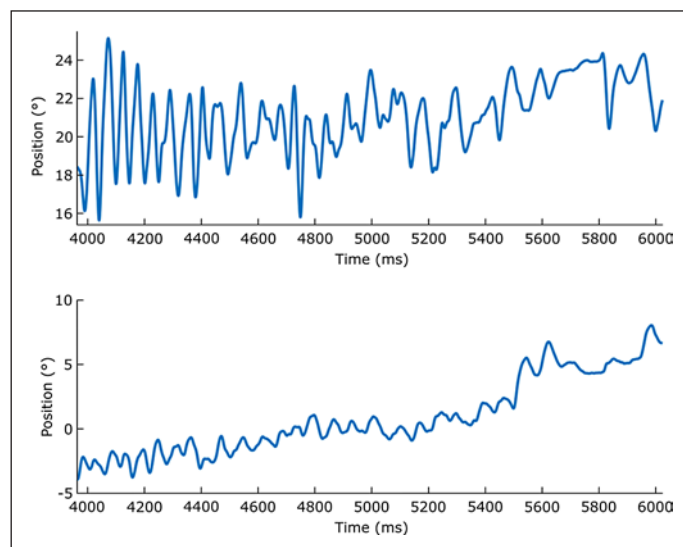
Figure 1 shows the eye movement recording obtained during binocular fixation in the primary position. Similar results were obtained under monocular viewing conditions.

As no nystagmus was detected using high-speed eye tracking, the patient was asked whether he was aware of being able to voluntarily oscillate the eyes. Interestingly, although the patient was unaware of his eye movements during the initial direct ophthalmoscopy examination, he was eventually able to voluntarily produce similar high-frequency eye movements

**Fig. 1.** Eye trace under binocular viewing conditions showing stable fixation. The upper trace shows horizontal eye movements; vertical eye movements are in the lower trace.



**Fig. 2.** Eye movement trace showing voluntary flutter in a 2-s time window. The upper trace shows horizontal eye movements; vertical eye movements are in the lower trace.



with convergence. These eye movements were primarily horizontal and after repeated efforts, they could be maintained for approximately 4–5 s. These were the same eye movements that were initially observed during ocular examination with direct ophthalmoscopy. Figure 2, recorded from the left eye, shows voluntary flutter performed by the patient over a 2-s period.

The upper eye movement trace in Figure 2 shows back-to-back horizontal saccadic oscillations with an average frequency of 13 Hz, reducing over time. Amplitude also reduces over time, beginning at  $\sim 8^\circ$  and reducing to  $\sim 3^\circ$  during the “burst.”

## Discussion/Conclusion

Voluntary flutter is a voluntarily induced, conjugate saccadic oscillation of the eyes. Although voluntary flutter is typically manifest in a predominantly horizontal direction [1, 2, 5, 7], Krohel and Griffin [8] reported a rare instance of vertical voluntary flutter in a patient with

hypertropia and a fourth-nerve palsy. Some studies have also recorded oblique eye movements (similar horizontal and vertical amplitude) in individuals exhibiting voluntary flutter [9, 10]. In the patient in this case, the voluntary flutter was primarily horizontal, with a small vertical element as well. Voluntary flutter has been reported as having a low amplitude, around 2 and 5° [11], and a high maximum frequency varying from 22 to 30 Hz [2, 4]. It is important to note that the rhythmic eye movements of physiological (e.g., optokinetic nystagmus) and pathological nystagmus (e.g., infantile nystagmus) are generally characterized by “drifts” away from fixation (slow phases) and fast phases back toward it [12]. The eye movements of the patient in this case did not exhibit a slow phase; rather, the oscillations consisted of back-to-back saccades, which are indicative of voluntary flutter, not nystagmus.

The saccadic oscillations characteristic of voluntary flutter are often, but not always, triggered by convergent eye movements [1, 4, 5, 9, 13]. The patient in this case confirms that convergence can indeed aid the manifestation of voluntary flutter, although this contradicts the primary observation of voluntary flutter during direct ophthalmoscopy, as the patient had been instructed to fixate a distance target during the examination. Given the strong links between convergence and the manifestation of voluntary flutter, it is also possible that the patient had been tensing and/or converging due to the proximity of the examiner, which in turn might have triggered the voluntary flutter. However, the extent to which the initiation of these eye movements is dependent on convergence is not entirely clear in this patient, as voluntary flutter can also occur independently of convergence. Furthermore, the presence of autism spectrum disorder may have exacerbated tension within the patient, due to reduced “personal space” that has previously been reported in these individuals [14]. However, it should be noted that this is only a speculation and previous reports have neither identified anxiety, stress, or autism spectrum disorder as precursors to the initiation of voluntary flutter. There is also no evidence within the literature that the light itself from the direct ophthalmoscope could have initiated the voluntary flutter.

In most cases, fixation or visual stimuli do not affect the expression of voluntary flutter; however, one report detailed the case of a 27-month-old who could also manifest voluntary flutter on divergent eye movements [3]. The authors of this case report could not define the exact mechanism of the oscillation but suggested that the patient may have an instability in the neural integrator of the brainstem/cerebellum that is also linked to voluntary control associated with ocular alignment [15]. Although individuals who can induce voluntary flutter do not always need to converge to do so [11], voluntary flutter exhibited on divergence is atypical, and most symptoms associated with voluntary flutter are amplified during convergence tasks, e.g., reading [2, 10].

The saccadic oscillations of voluntary flutter are similar to the eye movements observed in “ocular flutter” – a rare disorder characterized by rapid back-to-back horizontal saccadic oscillations [10]. Voluntary flutter has also been previously misdiagnosed as opsoclonus – a similar condition to ocular flutter, but with saccades that occur in any direction [4]. However, in contrast to these pathological acquired conditions, voluntary flutter has no relation to pathology [4]. An important difference between voluntary flutter and acquired pathological eye oscillations is the duration and frequency of the movements. The duration of voluntary flutter is typically very short (between 4 and 35 s [2, 4, 10, 12] with a high frequency [2, 4]). However, pathological eye oscillations are typically present either continuously or for longer durations with lower frequencies. Furthermore, patients that are able to manifest voluntary flutter may not always be aware that these eye movements are under voluntary control [10], and indeed, some patients may demonstrate bursts of voluntary flutter involuntarily [5]. Consequently, voluntary flutter can be a useful differential diagnosis for patients with a recent onset apparent “nystagmus” and no other corresponding neurological signs and symptoms [4, 10].

A definitive etiology for voluntary flutter is still unknown. However, Zee and Robinson [7] proposed that the etiology of ocular flutter lies in an abnormality of the omnidirectional

“pause” (omnipause) neurons located in the medial region of the paramedian pontine reticular formation. During fixation, excitatory “burst” neurons are inhibited by these pause neurons, thus preventing saccades [16]. Interestingly, ocular flutter has previously been shown in a patient with a localized lesion in the paramedian pontine reticular formation [17], adding weight to the Zee and Robinson [7] model. As these saccadic oscillations are very similar to voluntary flutter, Yee et al. [10] proposed that the activity of the omnipause neurons in this neural circuit is also modulated in individuals with voluntary flutter, albeit volitionally. More recently, Ramat et al. [13] proposed that unstable positive feedback loops created by both excitatory and inhibitory burst neurons are responsible for saccadic oscillations in healthy observers. Voluntary flutter is also known to exist among members of the same family [2], and Aschoff et al. [12] suggested that the ability to induce voluntary flutter is an autosomal dominant trait. However, a specific gene underlying this potential trait has not been identified.

In conclusion, voluntary flutter is a rapid oscillation of the eyes that has a short duration and high frequency. Despite the relatively rare occurrence of voluntary flutter, it is a persistent cause of referral, especially in older children [6]. In most cases, it is initiated voluntarily, although it may occasionally occur involuntarily. While typical forms of voluntary flutter are usually manifest during convergence, atypical forms can also be exhibited during divergence. If high-frequency nystagmus-like eye movements are observed, the clinician is advised to enquire whether the patient is aware of having the ability to “shake their eyes,” to prevent needless referral. Although our patient was eventually somewhat aware that the high-frequency eye movements were under voluntary control, not all patients manifesting this form of flutter are aware of the voluntary aspect. Voluntary flutter (whether truly “voluntary” or not) should therefore be considered when determining differential diagnosis of recent onset apparent “nystagmus” in the absence of other neurological signs and symptoms.

## Acknowledgments

We thank the patient for consenting to allow us to present this case. We also thank Lawrence Wilkinson and Simon Rushton for loan of equipment used in the diagnosis.

## Statement of Ethics

This study adhered to the tenets of the Declaration of Helsinki. Ethical approval from the Cardiff University Research Ethics and Audit Committee (School of Optometry and Vision Sciences, Cardiff University) was exempted as this was a single case report. Written informed consent was obtained from the patient for publication of the details of their medical case and any accompanying images.

## Conflict of Interest Statement

The authors have no conflicts of interest to declare.

## Funding Sources

No funding was received.

## Author Contributions

J. Margaret Woodhouse conducted the initial sight test in which voluntary flutter was first observed. Matt J. Dunn collected data during eye movement recording and assessment. Nikita Thomas drafted and revised the manuscript.

## Data Availability Statement

All data generated or analyzed during this study are included in this article. Further inquiries can be directed to the corresponding author Dr. Margaret Woodhouse.

## References

- 1 Shults WT, Stark L, Hoyt WF, Ochs AL. Normal saccadic structure of voluntary nystagmus. *Arch Ophthalmol*. 1977;95(8):1399–404.
- 2 Neppert B, Rambold H. Familial voluntary nystagmus. *Strabismus*. 2006;14(2):115–9.
- 3 Lewis RF, Traish AS, Lessell S. Atypical voluntary nystagmus. *Neurology*. 2009;72(5):467–9.
- 4 Zahn JR. Incidence and characteristics of voluntary nystagmus. *J Neurol Neurosurg Psychiatry*. 1978;41(7):617–23.
- 5 Rosenberg ML. Involuntary “voluntary” nystagmus. *J Neuroophthalmol*. 2021;41(4):e688–91.
- 6 Osborne D, Theodorou M, Lee H, Ranger M, Hedley-Lewis M, Shawkat F, et al. Supranuclear eye movements and nystagmus in children: a review of the literature and guide to clinical examination, interpretation of findings and age-appropriate norms. *Eye*. 2019;33(2):261–73.
- 7 Zee DS, Robinson DA. A hypothetical explanation of saccadic oscillations. *Ann Neurol*. 1979;5(5):405–14.
- 8 Krohel G, Griffin JF. Voluntary vertical nystagmus. *Neurology*. 1979;29(8):1153–4.
- 9 Hotson JR. Convergence-initiated voluntary flutter: a normal intrinsic capability in man. *Brain Res*. 1984;294(2):299–304.
- 10 Yee RD, Spiegel PH, Yamada T, Abel LA, Suzuki DA, Zee DS. Voluntary saccadic oscillations, resembling ocular flutter and opsoclonus. *J Neuroophthalmol*. 1994;14(2):95–101.
- 11 Jarrett A, Emery JM, Coats AC, Justice J Jr. Voluntary nystagmus. *Ann Ophthalmol*. 1977;9(7):853–9.
- 12 Aschoff JC, Becker W, Rettelbach R. Voluntary nystagmus in five generations. *J Neurol Neurosurg Psychiatry*. 1976;39(3):300–4.
- 13 Ramat S, Leigh RJ, Zee DS, Optican LM. Ocular oscillations generated by coupling of brainstem excitatory and inhibitory saccadic burst neurons. *Exp Brain Res*. 2005;160(1):89–106.
- 14 Asada K, Tojo Y, Osanai H, Saito A, Hasegawa T, Kumagawa S. Reduced personal space in individuals with Autism spectrum disorder. *PLoS One*. 2016;11(1):e0146306.
- 15 Arnold DB, Robinson DA, Leigh RJ. Nystagmus induced by pharmacological inactivation of the brainstem ocular motor integrator in monkey. *Vision Res*. 1999;39(25):4286–95.
- 16 Horn AK, Büttner-Ennever JA, Wahle P, Reichenberger I. Neurotransmitter profile of saccadic omnipause neurons in nucleus raphe interpositus. *J Neurosci*. 1994;14(4):2032–46.
- 17 Schon F, Hodgson TL, Mort D, Kennard C. Ocular flutter associated with a localized lesion in the paramedian pontine reticular formation. *Ann Neurol*. 2001;50(3):413–6.