

# Ruptured Posterior Circulation Aneurysms with Bilateral Internal Carotid Artery Occlusion: Surgical Nuance

## Abstract

**Background:** Craniotomy and surgical clipping is the standard modality of treatment in patients of cerebral aneurysms. However, the surgical clipping of aneurysm may pose serious difficulties in the case of a bilateral carotid artery occlusion. The endovascular treatment has shown promising results in this disease. **Methods:** A retrospective study of all patients of posterior circulation aneurysms in the background of carotid occlusive disease at our department was performed. The aim of this study was to describe the clinical, radiological characteristics, and the treatment of this rare entity. **Results:** Four patients were treated from January 2009 to October 2015. The mean age of our patients was 34 years with ages that ranged from 17 to 45 without any gender predominance. The mean period between onset of symptoms and diagnosis was 6 weeks. Angiographic localization of the disease was observed in all patients. All patients were treated by endovascular techniques. The postoperative course has been satisfactory with a complete neurological recovery in all patients. **Conclusions:** Rupture of posterior circulation aneurysms in the setting of bilateral internal carotid artery occlusion is extremely rare. Treatment is exclusively endovascular intervention. The functional outcome of ruptured posterior circulation aneurysms in setting of bilateral carotid occlusive disease is particularly favorable with good neurological recovery.

**Keywords:** Basilar apex, carotid occlusion, cerebral aneurysms, Moyamoya disease, posterior cerebral artery

## Introduction

Craniotomy and surgical clipping is the standard modality of treatment in patients of cerebral aneurysms. However, in the case of a bilateral carotid artery occlusion, the surgical clipping of aneurysm may pose serious difficulties.<sup>[1-8]</sup> The endovascular treatment has shown promising results in this disease.<sup>[9,10]</sup> We discuss the management dilemmas and review the relevant literature.

## Methods

A retrospective study of all patients having ruptured aneurysms of posterior circulation with bilateral carotid occlusive disease at our department between January 2009 and October 2015, was performed. The consents of the relevant patients and institutional approval for the study and publication were obtained.

The purpose of this paper is to report our cases and review the clinical presentation, radiological appearance, and treatment of this distinct clinicopathological entity. Aneurysms of posterior circulation without

carotid occlusive diseases were excluded from our study. The data were collected and analyzed from medical files in the hospital archives.

## Results

A total of four patients were admitted and treated during the period mentioned above. The average age of our patients was 34 years with ages that ranged from 17 to 45 years. Two women aged 17, 35 and two men aged 39 and 45.

The diagnosis was established in all cases based on clinical findings, computed tomography scan, and digital subtraction angiography (DSA) findings. The period between onset of symptoms and diagnosis ranged from 4 days to 14 weeks with an average of 6 weeks. Headache and neck rigidity were common symptoms of all patients, whereas left ptosis was additional finding in the patient of aneurysm in P1 segment of the left posterior cerebral artery (PCA). Both male patients were smokers and had strong family history of ischemic heart disease (IHD). One

**Nitin Narayan Dange,**  
**Amit Mahore,**  
**Ashwini Kumar Patil<sup>1</sup>,**  
**Juhi Kawale<sup>2</sup>**

*Departments of Neurosurgery,  
<sup>1</sup>Neurology and <sup>2</sup>Internal  
Medicine, Seth Gordhandas  
Sunderdas Medical College  
and King Edward Memorial  
Hospital, Mumbai, Maharashtra,  
India*

### Address for correspondence:

*Dr. Amit Mahore,  
Department of Neurosurgery,  
Second Floor, King Edward  
Memorial Hospital,  
Parel, Mumbai - 400 012,  
Maharashtra, India.  
E-mail: amit2mahore@yahoo.  
co.in*

### Access this article online

**Website:** www.asianjns.org

**DOI:** 10.4103/ajns.AJNS\_19\_17

### Quick Response Code:



**How to cite this article:** Dange NN, Mahore A, Patil AK, Kawale J. Ruptured posterior circulation aneurysms with bilateral internal carotid artery occlusion: Surgical nuance. Asian J Neurosurg 2018;13:1008-10.

This is an open access journal, and articles are distributed under the terms of the Creative Commons Attribution-NonCommercial-ShareAlike 4.0 License, which allows others to remix, tweak, and build upon the work non-commercially, as long as appropriate credit is given and the new creations are licensed under the identical terms.

**For reprints contact:** reprints@medknow.com

of them had hypertriglyceridemia and the other had hyperhomocysteinemia.

Females had no family history of IHD or habit of tobacco consumption [Table 1]. Figure 1 shows salient findings of cerebral DSA.

Of the four patients, the aneurysms were located at the basilar apex in two cases and PCA in two cases [Figure 1].

All patients were treated by endovascular intervention. Two patients had stent-assisted coiling whereas the other two were treated by coiling alone. The postoperative course has been satisfactory, with a complete recovery of neurological functions in all patients [Table 1].

### Discussion

Only few sporadic cases of similar aneurysms treated by endovascular methods have been described in the English

literature.<sup>[2]</sup> Bilateral internal carotid artery occlusion leads to abnormally increased blood flow through the posterior circulation. It increases the hemodynamic stress, especially at basilar artery apex and posterior cerebral arteries.<sup>[4-6]</sup> The alteration of local hemodynamic is considered to be a causative factor for the occurrence of these aneurysms. Most of these are asymptomatic and are incidentally detected on DSA. However, these are potentially dangerous as a rupture can lead to life-threatening subarachnoid hemorrhage (SAH).<sup>[5,7]</sup>

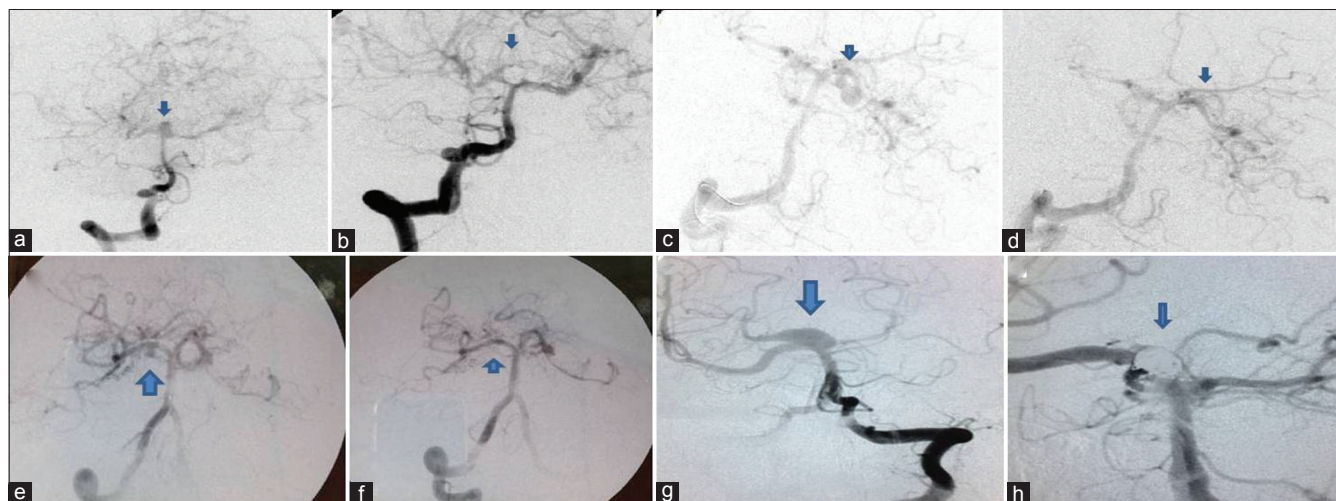
Atherosclerosis, Moyamoya disease, and inflammatory vasculopathies are the leading causes of bilateral internal carotid artery stenosis.<sup>[2,11-13]</sup> In our series, out of total 4 cases, 2 were due to atherosclerosis and Moyamoya disease each.

These patients may present clinically with features of either ischemia secondary to internal carotid artery

**Table 1: Summary of clinical characteristics, management, and results of our patients**

Case	1	2	3	4
Age (years)	39	45	17	35
Gender	Male	Male	Female	Female
Symptoms	Headache	Headache, ptosis	Headache	Headache
Site of aneurysm	Basilar apex	Left PCA (P1 segment)	Right PCA (P1 segment)	Basilar apex
Treatment	Stent-assisted coiling	Coiling	Coiling	Stent-assisted coiling
Result	Complete recovery	Complete recovery	Complete recovery	Complete recovery
Follow-up	6 years	5 years	3 years	1 year and 4 months
Biochemistry	Hypertriglyceridemia	Hyperhomocysteinemia	Normal	Normal
Tobacco consumption	Yes	Yes	No	No
Diabetes	No	Yes	No	No
Family history of IHD or ischemic stroke	Early fatal AMI in father	Early AMI in father and grand father	No	No

IHD – Ischemic heart disease; AMI – Acute myocardial infarct; PCA – Posterior cerebral artery



**Figure 1:** (a) Cerebral digital subtraction angiography showing basilar top aneurysm with good cross flow and filling of entire intracranial circulation from the right vertebral artery. (b) Postprocedure image showing complete obliteration of aneurysm with detachable platinum coils. (c) Cerebral digital subtraction angiography showing left posterior cerebral artery (P1 segment) aneurysm and filling of entire intracranial circulation from right vertebral artery. (d) Complete obliteration of aneurysm using coils with patent distal circulation. (e) Cerebral digital subtraction angiography showing right posterior cerebral artery (P1 segment) aneurysm. Entire intracranial circulation is filling from right vertebral artery. (f) Aneurysm completely obliterated using detachable coils with patent distal circulation. (g) Cerebral digital subtraction angiography showing basilar top aneurysm with filling of whole intracranial circulation from left vertebral artery. (h) Aneurysm completely obliterated by coils with patent distal circulation

stenosis or with features of hemorrhage secondary to ruptured posterior circulation aneurysms or a combination of both.<sup>[11,12]</sup> Moreover, most of these patients are on antiplatelet therapy, which can make hemorrhage more devastating.

Conservative management for these aneurysms can lead to dismal results.<sup>[5,7]</sup> Conventionally, these aneurysms can be managed by open surgery with craniotomy and clipping. However, there are several shortcomings to this approach. First, their anatomical locations with close vicinity to important neurovascular structures make surgical access difficult, if not impossible. Second, proximal control using temporary clips is virtually not feasible in view of already compromised anterior circulation and vertebrobasilar system being the sole source of blood supply. Third, due to high internal pressure in the vertebrobasilar system, it is dangerous to clip these aneurysms. It highlights the fact that the posterior circulation aneurysms are difficult to clip in the acute stage.<sup>[2,3,13]</sup> Endovascular treatment offers a viable alternative as these shortcomings of craniotomy and surgical clipping are overcome. These are flow-related aneurysms; therefore, endovascular treatment using coils provides excellent results with good intraprocedure obliteration rates and lasting benefits in terms of regrowth or rebleed as seen on follow-up.<sup>[2,11]</sup>

## Conclusions

Endovascular treatment is safe and effective for treatment of ruptured aneurysms of posterior circulation in patients with bilateral carotid artery occlusion as it overcomes the limitations of traditional surgical clipping.

## Financial support and sponsorship

Nil.

## Conflicts of interest

There are no conflicts of interest.

## References

- Shibuya T, Hayashi N. A case of posterior cerebral artery aneurysm associated with idiopathic bilateral internal carotid artery occlusion: Case report. *Surg Neurol* 1999;52:617-22.
- Kim SS, Park DH, Lee NJ, Kang SH, Lim DJ, Chung YG, *et al.* Coil embolization of a ruptured basilar tip aneurysm associated with bilateral cervical internal carotid artery occlusion: A case report and literature review. *J Cerebrovasc Endovasc Neurosurg* 2012;14:44-9.
- Molyneux A, Kerr R, Stratton I, Sandercock P, Clarke M, Shrimpton J, *et al.* International Subarachnoid Aneurysm Trial (ISAT) of neurosurgical clipping versus endovascular coiling in 2143 patients with ruptured intracranial aneurysms: A randomised trial. *Lancet* 2002;360:1267-74.
- Araki T, Fujiwara H, Yasuda T, Suyama T, Taki W. A case of aneurysmal subarachnoid hemorrhage associated with bilateral common carotid artery occlusion. *No Shinkei Geka* 2002;30:853-8.
- Yamanaka C, Hirohata T, Kiya K, Yoshimoto H, Uozumi T. Basilar bifurcation aneurysm associated with bilateral internal carotid occlusion. *Neuroradiology* 1987;29:84-8.
- Kazumata K, Terasaka S, Ishikawa T, Asaoka K, Ushikoshi S, Ajiki M, *et al.* Ruptured P1-2 junction aneurysm associated with bilateral agenesis of the internal carotid artery. *No Shinkei Geka* 2008;36:523-8.
- Masuzawa T, Shimabukuro H, Sato F, Furuse M, Fukushima K. The development of intracranial aneurysms associated with pulseless disease. *Surg Neurol* 1982;17:132-6.
- Ito M, Sato K, Tsuji O, Wachi A, Naito S. Multiple aneurysms associated with bilateral carotid occlusion and venous angioma: Surgical management risk-case report. *J Clin Neurosci* 1994;1:62-8.
- Konishi Y, Sato E, Shiokawa Y, Yazaki H, Hara M, Saito I, *et al.* A combined surgical and endovascular treatment for a case with five vertebro-basilar aneurysms and bilateral internal carotid artery occlusions. *Surg Neurol* 1998;50:363-6.
- Meguro T, Tanabe T, Muraoka K, Terada K, Hirotsune N, Nishino S, *et al.* Endovascular treatment of aneurysmal subarachnoid hemorrhage associated with bilateral common carotid artery occlusion. *Interv Neuroradiol* 2008;14:447-52.
- Arita K, Kurisu K, Ohba S, Shibukawa M, Kiura H, Sakamoto S, *et al.* Endovascular treatment of basilar tip aneurysms associated with moyamoya disease. *Neuroradiology* 2003;45:441-4.
- Bhattacharjee AK, Tamaki N, Minami H, Ehara K. Moyamoya disease associated with basilar tip aneurysm. *J Clin Neurosci* 1999;6:268-71.
- Xu K, Wang H, Luo Q, Li Y, Yu J. Endovascular treatment of bilateral carotid artery occlusion with concurrent basilar apex aneurysm: A case report and literature review. *Int J Med Sci* 2011;8:263-9.