

# The arterialised saphenous venous flow-through flap for managing the radial forearm free flap donor site

Kimberley R. Hughes MBBS<sup>1,2</sup>  | Alisha Fong MBBS<sup>1,2</sup> |  
Warren M. Rozen MBBS, FRACS, MD, PhD<sup>2</sup>  | James C. S. Leong MBBS, FRACS, MS<sup>1,2,3</sup>

<sup>1</sup>Department of Plastic & Reconstructive Surgery, Monash Health, Clayton, Victoria, Australia

<sup>2</sup>Faculty of Medicine, Monash University, Clayton, Victoria, Australia

<sup>3</sup>Department of Surgery, Monash University, Clayton, Victoria, Australia

## Correspondence

Warren M. Rozen, Department of Plastic & Reconstructive Surgery, Monash University, Clayton, Victoria, Australia.

Email: warrenrozen@hotmail.com

## Abstract

**Background:** The radial forearm fasciocutaneous flap (RFFF) is a workhorse flap, however concerns with donor site morbidity include tendon exposure, delayed wound healing, impaired sensitivity, and poor cosmesis, have seen it fall out of favor. We present a method of using an arterialised saphenous flow through flap to reconstruct the RFFF donor site.

**Method:** A cohort study of six patients (five male, one female; mean age 59 [range 19–90]) who had their RFFF donor site reconstructed with an arterialised saphenous flow through flap is presented. The use of multiple peripheral efferent venous anastomoses, flap rotation 180 degrees prior to inset, and the ligation of intra-flap connecting veins were three modifications employed. Primary outcomes include complication rates. Secondary outcomes were patient reported outcome measures via the Michigan Hand Outcomes Questionnaire, and patency and flow through the flap.

**Results:** In all six cases, there was flap survival. RFFF dimensions ranging from lengths of 6–15 cm (mean 11.5 cm) and widths of 4–6 cm (mean 5.3 cm), with an average flap area of 58 cm<sup>2</sup> (range 24–90). There were no total flap losses, one partial superficial flap loss and one minor donor site delayed healing, over a mean follow-up of 6 months (4–24 months). The average overall patient satisfaction was 91 on Michigan Hand Outcomes Questionnaire. Pain was well tolerated with a low average pain score of 15.

**Conclusion:** The modified arterialised saphenous flow through flap is a useful option for reconstructing the soft tissue defect and reconstituting the radial artery after RFFF harvest.

## 1 | INTRODUCTION

The radial forearm fasciocutaneous flap (RFFF) was first described by Yang in 1981 and is traditionally referred to as a “workhorse” flap for head and neck, burn, and lower limb reconstruction. It is a versatile,

thin, pliable, fasciocutaneous flap that has a long vascular pedicle with high caliber vessels, and its consistent anatomy provides ease of harvest (Chang et al., 2010; Pabst et al., 2018).

However, recently the RFFF has fallen out of favor due to its unfavorable donor site morbidity with a complication rate in the

This is an open access article under the terms of the Creative Commons Attribution-NonCommercial-NoDerivs License, which permits use and distribution in any medium, provided the original work is properly cited, the use is non-commercial and no modifications or adaptations are made.

© 2022 The Authors. *Microsurgery* published by Wiley Periodicals LLC.

literature ranging between 6% and 50% (D'arpa et al., 2017; Richardson et al., 1997). Reported donor site complications includes exposure of underlying tendon, delayed wound healing, impaired sensitivity, wrist stiffness, decreased pinch and grip strength, and poor cosmetic scar (Chang et al., 2010; Pabst et al., 2018; Rieger et al., 2016; Zuo et al., 2018). Sacrifice of the radial artery also results in a change in forearm vasculature, and cold intolerance has been reported in up to 30%–40% of patients (Chang et al., 2010). In these studies, revision rates reach 30%, with secondary procedures ranging from scar revision, revision with soft tissue coverage, radial nerve neurolysis, flexor carpi radialis tenolysis or tendon excision.

Various techniques have been described for RFFF donor site closure in both the primary and secondary setting, including split (SSG) or full thickness skin graft (FTSG), primary closure with local flaps, the use of skin substitutes such as acellular dermal matrix, and the use of alternative flaps, including free flaps (Chang et al., 2010; Pabst et al., 2018).

A venous flow through flap has not been described as an option for soft tissue coverage in this setting, despite having attributes suited to the reconstructive dilemmas described above. We have previously described our modification in the design of arterialised saphenous venous flaps and their success in reconstructing traumatic volar forearm soft tissue and segmental arterial defects, and offer this as a useful option (Rozen et al., 2012). We thus postulated that this would be a useful flap in this setting, given its ease of harvest, soft tissue match, good donor site profile, and ability to reconstruct the radial artery.

The current study aims to investigate the utility of this approach to managing the RFFF donor site. We present a series of using the arterialised saphenous venous flow-through flap in this setting, and describe and evaluate our experience using this flap to reconstitute

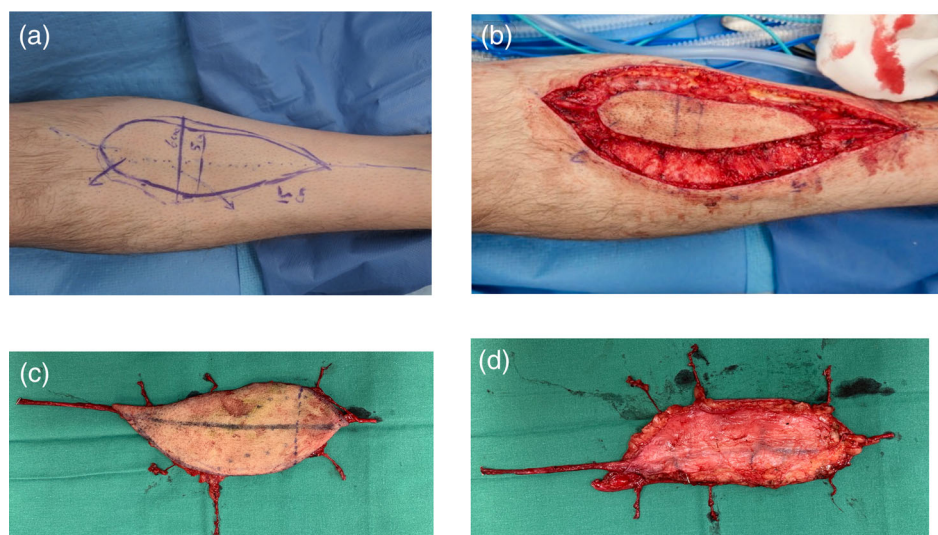
the radial artery and reconstruct the soft tissue defect after RFFF harvest.

## 2 | PATIENTS AND METHODS

A cohort study comprising a case series of patients undergoing RFFF is presented, for which all patients had their donor site reconstructed with a saphenous venous flow-through flap. This was a pilot study, for which six consecutive cases were included in the series, with patients selected for inclusion based on RFFF dimensions that exceeded direct closure or local flap closure of the donor site, and those who had suitable saphenous flap donor sites. The study was approved by institutional ethics committee.

### 2.1 | Surgical technique

Patients were positioned supine with the leg in a frog legged position. The saphenous flap was harvested concurrently with the RFFF harvest utilizing a two-team approach. The course of the long saphenous vein (LSV) and its tributaries were marked out over the posteromedial leg (Figure 1a). The same template used to design the RFFF was utilized for the saphenous flap. The dimensions of the flap were dependent on the defect; however, a maximal width of approximately 6–7 cm was sought to achieve direct closure of the donor site. The flap was incised and raised in sub-fascial plane from distal to proximal (Figure 1b). The length of saphenous vein harvested distally was determined by length of the radial artery defect. The peripheral veins coursing through the fasciocutaneous flap were preserved and



**FIGURE 1** Flap markings and design. (a) Pre-operatively the course of the long saphenous vein is marked from above the medial malleolus to below the knee. The flap is designed centred over the long saphenous vein over the upper posteromedial leg. Smaller veins around the periphery of the flap are also marked. (b) Flap raised, and demonstrated at the leg donor site before transfer. Length of distal saphenous vein harvested depends on the length of radial artery required to reconstitute. (c) Flap harvested with multiple additional peripheral veins. (d) Deep aspect of flap. Saphenous vein runs through the centre of flap, with a second efferent vein harvested in the periphery of the flap

harvested at a good length, as they were required to augment the venous drainage of the flap in the forearm (Figure 1c). Clear and definite connections between these veins and the central saphenous vein were divided and ligated near the central saphenous vein on the under surface to establish a separate venous outflow system (Figure 1d). Extensive dissection to follow and ligate the peripheral veins was not performed to avoid damaging the venous system and these connecting veins were left alone if they were small or the connections were not clearly visible.

The flap was rotated 180 degrees prior to inset in the forearm, to allow unobstructed antegrade flow through the venous valves during arterialisation (Yan et al., 2010). The distal saphenous vein was anastomosed to the proximal radial artery stump, and the proximal saphenous vein anastomosed to the distal stump using 7.0 and 8.0 nylon, sutured in all cases. Care was taken when raising the RFFF to leave a long enough distal stump to facilitate ease of anastomosis and the peripheral veins in the forearm flap harvest were carefully tagged and preserved to facilitate the venous anastomosis for the venous outflow of the transplanted saphenous flap. The peripheral flap veins were anastomosed to suitable sized veins in the volar forearm using 8.0 nylon or a venous coupler device (sutured in one case, couplers in five cases). The majority of microsurgical anastomoses were performed using loupe magnification to facilitate concurrent microsurgery of the RFFF and saphenous flap, to avoid increased operating time.

Postoperatively, the wrist was immobilized for 7 days and then mobilized freely. The lower limb donor site was managed with bedrest for 48 h and then progression through early mobilization.

This case series comprised five male patients and one female patient, with an average age of 59 (19–90 years). There was one active smoker (16.7%). The indication/location for RFFF comprised three head and neck reconstructions (two intra-oral SCCs and one lower lip SCC), two lower limb reconstructions (one calcaneal osteomyelitis and one pretibial wound), and one hand reconstruction (dorsal hand degloving injury). The flap dimensions ranged from lengths of 6 to 15 cm (mean length of 11.5 cm) and widths of 4 to 6 cm (mean width of 5.3 cm). The average flap area was 58 cm<sup>2</sup> (Table 1).

All cases included at least one additional peripheral efferent venous anastomosis, and larger flaps multiple efferent veins were used. The donor site on the posteromedial leg was closed directly in all but one case (83.3%). In that one case, the patient had less redundant soft tissue in the leg and required a small central skin graft. The remainder of the wound was closed directly. The use multiple accessory peripheral efferent venous anastomoses, the flap rotation 180 degrees prior to inset to allow unobstructed antegrade flow through the venous valves during arterialisation, and the ligation of intra-flap connecting veins between the flap periphery and the central saphenous vein, were the three major modifications employed in all cases from traditional venous flow through flaps.

Primary outcomes comprised complication rates including total flap loss, partial flap loss and donor site complication. Secondary outcomes were patient reported outcome measures (PROMs) assessed using the Michigan Hand Outcomes Questionnaire, performed 8 weeks postoperatively; and patency and direction of flow through

**TABLE 1** Patient demographic and operative details; patient reported outcome measure using the Michigan hand outcomes questionnaire

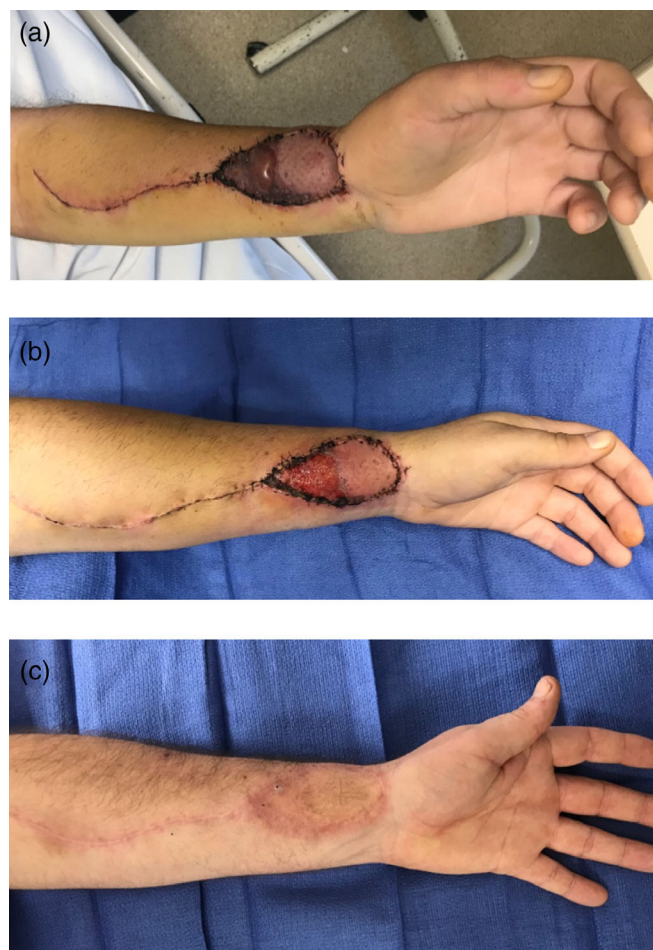
Patient	Gender	Age	Indication	Smoking status	Defect size (length by width in cm)	Donor site closure	Number of efferent veins	Complications	Overall function	Overall ADL	Pain	Work	Aesthetic	Satisfaction
1	M	90	Buccal SCC	No	10 × 6	Small SSG	1	Nil	100	95	0	95	94	100
2	M	34	Calcaneal osteomyelitis	Yes	6 × 4	Direct	1	Superficial distal flap tip necrosis	70	85	60	40	44	67
3	F	72	Oral SCC	No	8 × 5	Direct	1	Nil	85	97	0	100	100	96
4	M	19	Dorsal hand degloving	No	15 × 6	Direct	2	Superficial donor site dehiscence	-	-	-	-	-	-
5	M	63	Pretibial wound	No	15 × 5	Direct	1	Nil	100	100	100	0	100	100
6	M	81	Lower lip SCC	Ex	15 × 6	Direct	3	Nil	-	-	-	-	-	-

the saphenous vein assessed using ultrasound Doppler, performed at 6–8 weeks postoperatively.

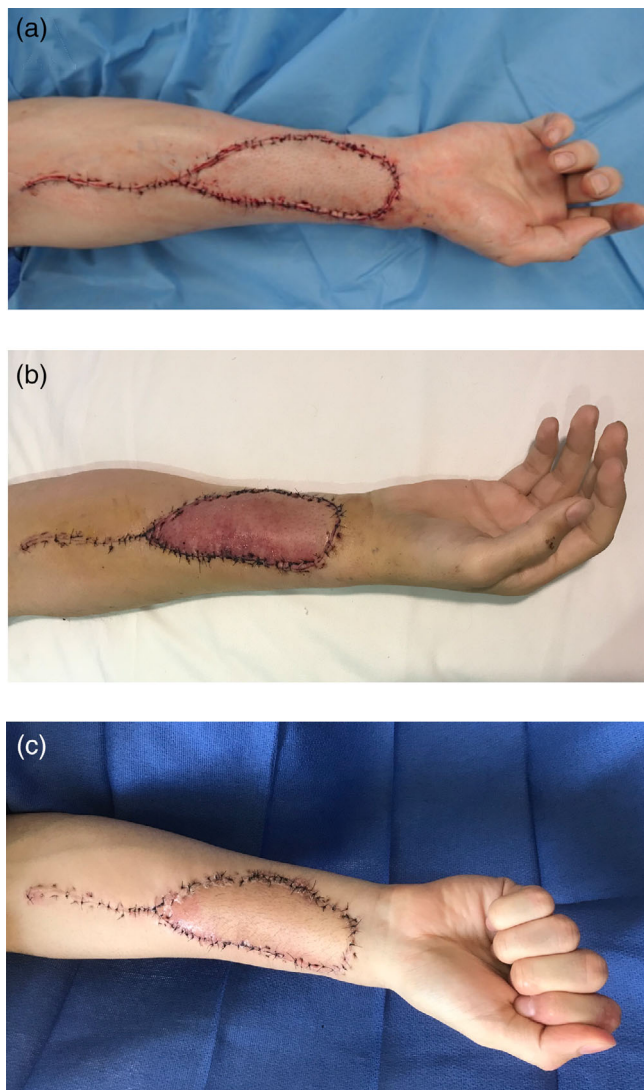
### 3 | RESULTS

In all six cases, there was flap survival and reconstruction of the RFFF donor site was achieved. Over a mean follow-up of 6 months (4–24 months), complications were few. There were no cases of total flap loss. In one case, there was significant early venous congestion of the proximal half of the flap, resulting in blistering and epidermolysis. Healthy dermis remained and the wound was managed with dressings and healed by secondary intention. It is likely that the second efferent vein may have occluded, however it was

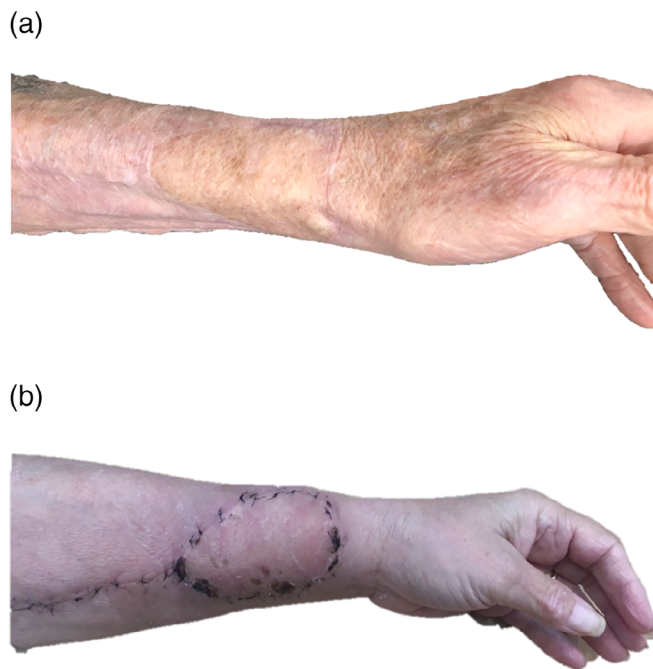
not our practice to take the saphenous flap back to theater for exploration. There was one minor donor site complication of superficial wound dehiscence managed with dressings, this occurred in the patient with the largest flap harvested (90 cm<sup>2</sup>). There were otherwise no donor site complications noted and the remainder healed with an aesthetically acceptable scar. All lower limb donor sites



**FIGURE 2** Case demonstration of a 34-year-old smoker, who underwent debridement of a left heel wound and calcaneal osteomyelitis and eventual reconstruction with RFFF. (a) Post-operative day 4. Significant venous congestion + epidermolysis of proximal half of flap, managed conservatively with elevation. (b) Post-operative day 9. Debridement of blistering revealed healthy dermis, left to heal by secondary intention. (c) Six months post-operative. Completely healed, good soft tissue coverage and contour, with slightly thickened scar proximally where healed by secondary intention. RFFF, radial forearm fasciocutaneous flap



**FIGURE 3** Case demonstration of a 19-year-old male who sustained significant right dorsal hand degloving injury post MVA. Underwent initial debridement and reconstruction with contralateral RFFF. He had a 15 × 6 cm soft tissue defect on the volar forearm and a 18 cm segment of radial artery harvested that was reconstituted with the arterialised saphenous flow through flap. (a) Immediate result on table after reconstituting the radial artery with the saphenous vein and two additional peripheral efferent veins anastomosed to superficial volar forearm veins to augment venous outflow. (b) Post-operative day 4. Characteristic signs of early venous insufficiency. Resting splint is removed at this time and patient has full range of movement of wrist and long flexors. (c) Two weeks post-operative. Healthy flap, completely healed with no signs of venous insufficiency. MVA, motor vehicle accident; RFFF, radial forearm fasciocutaneous flap



**FIGURE 4** (a) Case demonstration of a 90 year old male, shown 2 months post-operatively. Well healed donor site with no scar tissue or tethering over flexor tendons. (b) Case demonstration of a 72 year old female, shown 3.5 weeks post-operatively. Excellent soft tissue coverage, color match, and aesthetic result for RFFF donor site. RFFF, radial forearm fasciocutaneous flap

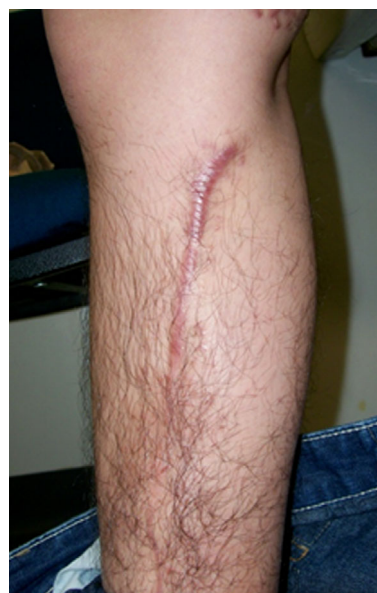healed well, with five cases closed with primary closure, and one requiring a small skin graft. In one case there was minor hypertrophic scarring noted.

The Michigan Hand Questionnaire (MHQ) was used to assess PROMs, with four out of six patients having completed the post-operative survey. The average overall patient satisfaction was 91. Of note, pain was well tolerated with a low average pain score of 15 (Table 1).

In all cases, the post-operative Doppler ultrasound confirmed patient and antegrade flow through the saphenous flap with normal flow velocities. In one case, there was a mild fusiform dilation measuring up to 5.7 mm in diameter around the proximal anastomosis. Radial artery functionality was thus reconstituted.

### 3.1 | Case report

A 19-year-old male sustained a significant right dorsal hand degloving injury post motor vehicle accident. This was patient 4 in the current series. He underwent debridement of the wounds in a first stage procedure, and was ultimately left with a dorsal hand defect with dimensions measuring 15 cm by 6 cm. He progressed to reconstruction with a contralateral RFFF, and a RFFF was designed to match the defect, comprising a 15 × 6 cm soft tissue defect on the volar forearm and an 18 cm segment of radial artery harvested that was reconstituted with



**FIGURE 5** Lower limb donor site for the arterialized saphenous flap. Minor hypertrophic scarring is noted

the arterIALIZED saphenous flow through flap. This was the largest flap of the current series.

The flap was vascularised through reconstitution of the radial artery with the saphenous vein and two additional peripheral efferent veins anastomosed to superficial volar forearm veins to augment venous outflow. Immediately after anastomosis, the flap underwent a phase of early venous congestion before becoming euvascular (Figure 2a). By post-operative day 4, the flap showed characteristic signs of early venous insufficiency (Figure 2b). The resting splint was removed at this time and the patient was confirmed to have a full range of movement of wrist and long flexors, with early mobilization begun. By 2 weeks post-operatively, a healthy flap was demonstrated, which was completely healed with no signs of venous insufficiency (Figure 2c). Ultimately, there was complete flap survival, and good healing. There was a minor donor site complication of superficial wound dehiscence managed with dressings.

The equivalent vascular changes demonstrated in this case report were seen in the other cases of this series, and similar to our previous experience with arterIALIZED saphenous flaps; that is, a phase of early venous congestion before becoming euvascular (Figures 2 and 3). While most flaps healed aesthetically (Figure 4a,b), hypertrophic scarring was noted in one case (Figure 5).

## 4 | DISCUSSION

The current study demonstrates a useful approach to the management of the RFFF donor site. A venous flow through flap has not been described as an option for soft tissue coverage in this setting. The RFFF has traditionally been the “work-horse” flap for complex head and neck, upper, and lower limb defects. Advances in microsurgery

have ensured great success in these reconstructions with less than 5% failure rate (Harris & Bewley, 2016). Recently the RFFF has fallen out of favor for other fasciocutaneous flaps such as the anterolateral thigh (ALT), because of its more favorable donor site. Skin laxity in the thigh permits the harvest of a large fasciocutaneous skin paddle, whilst still allowing direct closure of the donor site in the majority of cases, unlike in the forearm. Despite these advantages, the ALT flap might be too thick and bulky, especially in Western populations, for small defects of the tongue or floor of mouth, where the contour is often uneven requiring folding of the flap (Chang et al., 2010; Lee et al., 2011). Interest has now turned to minimizing the donor site morbidity associated with the RFFF.

The optimal way of reconstructing the forearm to reduce the RFFF donor morbidity remains controversial, with multiple methods described in the literature (Bonaparte et al., 2013; Chang et al., 2010; D'arpa et al., 2017; Hamahata et al., 2016; Hanna et al., 2014; Ho et al., 2006; Lee et al., 2011; Murray et al., 2011; Shaikh et al., 2018). Direct closure of the forearm is the best choice if possible, but its application is restricted to narrow wounds (Loeffelbein et al., 2012). Shaikh et al. (2018) describe utilizing a narrow radial forearm flap (nRFFF), where a long narrow flap is raised and then rolled onto itself to double the width and half the length. This facilitates a wide flap to be raised, but still allow primary closure of the donor site. Tissue expansion is another alternative that can be used to allow direct closure, but only if time permits. They are also associated with a high rate of complications (up to 40%) (Loeffelbein et al., 2012). Various studies have looked at the difference in donor site morbidity with split thickness (STSG) versus full thickness (FTSG) skin grafts. Sidebottom et al. (2000) conducted a randomized control trial comparing the two techniques and found they have comparable short and long-term outcomes. Similarly, other studies have also shown no significant difference in the aesthetic and functional outcomes (Loeffelbein et al., 2012).

A few lower level evidence studies have reported better aesthetic outcomes with FTSG, and reduced morbidity at the secondary donor site which is primarily closed (Loeffelbein et al., 2012). Several local skin flaps have also been described for closure of the donor site. The Z-plasty technique, ulnar transposition flap, V to Y advancement flap, lazy S double opposing rotation flap and bilobed flap based on ulnar artery perforators, all help to reduce the donor site morbidity and avoid skin grafting. However, are only suitable for small to medium sized defects (Hamahata et al., 2016; Loeffelbein et al., 2012). The use of artificial dermal substitutes such as Alloderm, Integra and biodegradable temporizing matrix represent a potential strategy for improving the donor site. A systematic review by Zuo et al. (2018) has shown satisfactory aesthetic and functional outcomes with these substitutes. However, prolonged healing time, two-staged reconstruction with a secondary skin graft, and associated costs do not support their routine use. It is unclear whether the radial forearm donor site morbidity is related to the flap harvest technique or the donor site closure method. Anatomical studies have shown that inclusion of the deep fascia during elevation of the RFFF does not contribute to its perfusion. It has been shown in the clinical setting that supra-fascial flap raise reduces

donor site morbidity, without increasing operative time or compromising flap viability (Schwarzer et al., 2016; Shonka et al., 2017).

The venous flow through flap has key features that may be optimal in this role. A primary and key advantage of the saphenous flap is the ability to reconstitute the radial artery. Detailed studies have shown subtle alterations in the vasculature of the forearm after radial artery harvest (Chang et al., 2010; Richardson et al., 1997). Although these changes do not result in critical ischaemia of the hand, cold intolerance after sacrifice of the radial artery has been reported in up to 30%–40% of patients (Chang et al., 2010; Ho et al., 2006; Richardson et al., 1997). Additionally, reconstituting the radial artery allows the RAFF to be used in patients with an unfavorable Allen's test, in whom previously an alternative reconstructive option would have been sought. Chang et al. (2010) reported using the ALT flap as a flow through to restore the radial artery and reconstruction the RFFF donor site. They report the lack of limitation of movement or contracture of the forearm, and improved appearance of the RFFF donor site. The disadvantages of using the ALT flap compared to the saphenous flap is a longer harvest time with more difficult dissection, and issues with pedicle length, requiring vein grafts to bridge the pedicle of the ALT and the radial artery in 2/12 cases (16.7%). In comparison, the saphenous flap is easy to raise, requires only superficial dissection, and in all of our patients the harvest was faster than the RFFF raise. The length of LSV harvested easily bridges the defect in the radial artery, without need for further vein grafting. This ease of harvest and versatile design are further key attributes in this setting.

Venous flaps are a useful option in the salvage setting, as they enable careful selection of an appropriate vein for reconstruction of a major arterial defect, spare all other free flap donor sites from being expended, and are freely available despite previous free flap use. These flaps have been widely described previously, first described by Nakayama in 1981 (Nakayama et al., 1981), and the arterialised venous flap (AVF) used clinically by Yoshimura et al in 1984 (Inada et al., 1993; Koshima et al., 1991). AVFs have been used in a wide variety of reconstructions for hand, upper limb, lower limb, foot, face, oral cavity, and neck (Pittet et al., 2008). The advantages have been widely reported (Koch et al., 2004; Rozen et al., 2012; Yan et al., 2010), despite higher rates of flap loss, both total and partial (Iglesias et al., 2013; Rozen et al., 2012; Zheng et al., 2016). The use of our technique described aims to optimize the physiological perfusion and survival mechanisms of AVFs: "AV shunting" or retrograde flow from the venous system to the arterial system via paralyzed AC shunts, "reverse flow" or flow from the venules into the capillaries, and "capillary bypass" or flow through the venous system without entrance into the arterial side until neo-vascularisation (Iglesias et al., 2013; Rozen et al., 2012; Yan et al., 2010; Zheng et al., 2016).

Similar to previous descriptions of the AVFs, the majority of flaps in our series underwent an early phase of venous congestion. Signs of venous congestion including oedema, ecchymosis and superficial epidermolysis in the immediate post-operative period, and up to 4 weeks post, are reported frequently in the literature and should be considered a "normal" finding in AVFs (De Lorenzi et al., 2002; Koch et al., 2004; Pittet et al., 2008). This is attributed to the high blood

pressure in venous system of an AVF. The arterial inflow provides high pressure blood flow into the flap, which cannot be regulated by the lack of vasoconstriction in vein (Pittet et al., 2008). Various techniques have been described to reduce the pressure in the venous system, including both chemical and surgical delay, which have been shown to increase the survival of the flap (Pittet et al., 2008; Yan et al., 2010).

We have previously described a modification in the design of the arterialised saphenous venous flap, where a separate source of venous drainage is provided, demonstrating the survival of much larger venous flaps than previously described (Rozen et al., 2012; Rozen & Leong, 2012). In our previous series, we were able to successfully cover defects of up to  $8 \times 20 \text{ cm}^2$ . We attribute our success in covering defects this size to (1) using arterialised flaps only; (2) by reversing the flap such that there is unimpeded flow through the valves during arterialisation; and (3) anastomosing additional side vein to enable dual venous drainage through the system (Rozen et al., 2012). Animal study models also confirm this theory that as the number of draining veins increases, the overall survival of the flap increases (Sang-Hyun et al., 1998; Zheng et al., 2016). We noted venous congestion to be more common early in our series when only one additional side vein was anastomosed. We postulate that the larger the venous flap the more additional side veins that should be anastomosed to avoid post-operative congestion. However, it should be noted that this is contentious in the literature, and studies such as that by Weng et al. (2017), have shown that while venous drainage is vital in the survival of AVFs, venous congestion can only be partially improved by increasing the number of draining veins. As discussed, several major modifications were employed in all cases over traditional venous flow through flaps: the use of multiple accessory peripheral efferent venous anastomoses, a flap rotation 180 degrees prior to inset to allow unobstructed antegrade flow through the venous valves during arterialisation, and the ligation of intra-flap connecting veins between the flap periphery and the central saphenous vein. These specific maneuvers are key pearls to achieving optimal venous drainage, reduce venous congestion and thus flap survival.

Whilst not measured as an objective outcome in our study, subjectively we found that our double flap approach did not add any increased operating time or length of hospital stay. Traditionally our major reconstructive cases are all done with a double team approach, so no extra man-power is not required for the double flap. The RAFF and the saphenous flaps are harvested concurrently using the same defect template. In the majority of our cases, the anastomoses for the saphenous flap were done under loupe magnification, given the larger diameter of the radial artery, or with a second microscope if available. The microsurgery for the main RFFF and the saphenous flap are done concurrently, thus not increasing the operative time. The additional microsurgery in these cases increases the microsurgical exposure and training opportunities for trainees. Post-operatively, saphenous flaps are monitored in a similar fashion to the RFFF so no extra nursing staff support is required. There were no cases of return to theater for the saphenous flap, and no complications that increased the overall length of stay for patients. While haste and versatility were the clear

benefits, the potential for venous compromise can remain a concern. With no detriment to outcomes in this series, we feel that the flap modifications employed are key features to achieving survival.

The current series demonstrates the utility of this flap as a salvage option for the RFFF donor site, however other uses may include primary reconstruction, particularly where a flow through flap may be suitable, and salvage options after harvest of other free flap donor sites. This may warrant the focus of future investigation. Further investigation will also optimally offer a control group to assess the differences in donor site outcomes and in radial artery flow and function.

## 5 | CONCLUSION

The modified arterialised saphenous flow through flap is a useful option for reconstructing the soft tissue defect and reconstituting the radial artery after RFFF harvest. A larger outcome-based study may advocate its use more widely.

## ACKNOWLEDGMENT

Open access publishing facilitated by Monash University, as part of the Wiley – Monash University agreement via the Council of Australian University Librarians.

## CONFLICT OF INTEREST

There are no conflicts of interest for any of the authors or affiliations, and the authors declare no knowledge of any direct interest, particularly a financial interest, in the subject matter or materials discussed. The authors have no employment by an industrial concern, ownership of stock, membership on a standing advisory council or committee, a seat on the board of directors, or being publicly associated with a company or its products that may pose such an interest. The authors have no real or perceived conflict of interest that include receiving honoraria or consulting fees or receiving grants or funds from such corporations or individuals representing such corporations. There was no grant, research scholarship or financial support provided for the study. There is no conflict of interest on preparation of this manuscript.

## DATA AVAILABILITY STATEMENT

The datasets generated during and/or analyzed during the current study are not publicly available due to patient confidentiality but are available from the corresponding author on reasonable request.

## ORCID

Kimberley R. Hughes  <https://orcid.org/0000-0001-5168-4578>

Warren M. Rozen  <https://orcid.org/0000-0002-4092-182X>

## REFERENCES

- Bonaparte, J. P., Corsten, M. J., Odell, M., Gupta, M., Allen, M., & Tse, D. (2013). Management of the radial forearm free flap donor site using a topically applied tissue expansion device. *Oral Surgery, Oral Medicine, Oral Pathology and Oral Radiology*, 116(1), 28–34. <https://doi.org/10.1016/j.oooo.2013.01.007>

- Chang, K.-P., Lai, C.-H., Liang, W.-L., Lai, C.-S., & Lin, S.-D. (2010). Alternative reconstruction of donor defect of free radial forearm flap in head and neck cancer. *Journal of Plastic Surgery and Hand Surgery*, 44(1), 31–36. <https://doi.org/10.3109/02844310903351251>
- D'arpa, S., Cillino, M., Mazzucco, W., Rossi, M., Mazzola, S., Moschella, F., & Cordova, A. (2017). An algorithm to improve outcomes of radial forearm flap donor site. *Acta Chirurgica Belgica*, 1-8, 219–226. <https://doi.org/10.1080/00015458.2017.1411555>
- De Lorenzi, F., van der Hulst, R. R., den Dunnen, W. F., Vranckx, J. J., Vandenhof, B., Francois, C., & Boeckx, W. D. (2002). Arterialized venous free flaps for soft-tissue reconstruction of digits: A 40-case series. *Journal of Reconstructive Microsurgery*, 18(7), 569–574. <https://doi.org/10.1055/s-2002-35093>
- Hamahata, A., Beppu, T., Osada, A., Yamaki, T., & Sakurai, H. (2016). An alternative method of the direct closure for the radial forearm flap donor-site defect: Lazy S double-opposing rotation flaps. *Journal of Reconstructive Microsurgery Open*, 1(1), 63–66. <https://doi.org/10.1055/s-0036-1580607>
- Hanna, T. C., McKenzie, W. S., & Holmes, J. D. (2014). Full-thickness skin graft from the neck for coverage of the radial forearm free flap donor site. *Journal of Oral and Maxillofacial Surgery*, 72(10), 2054–2059. <https://doi.org/10.1016/j.joms.2014.05.015>
- Harris, B. N., & Bewley, A. F. (2016). Minimizing free flap donor-site morbidity. *Current Opinion in Otolaryngology & Head and Neck Surgery*, 24(5), 447–452. <https://doi.org/10.1097/moo.0000000000000286>
- Ho, T., Couch, M., Carson, K., Schimberg, A., Manley, K., & Byrne, P. J. (2006). Radial forearm free flap donor site outcomes comparison by closure methods. *Otolaryngology–Head and Neck Surgery*, 134(2), 309–315. <https://doi.org/10.1016/j.otohns.2005.09.019>
- Iglesias, M., Fonseca-Lazcano, J. A., Moran, M. A. R., Butron, P., & Diaz-Morales, M. (2013). Revascularization of arterialized venous flaps through a Total retrograde reverse blood flow. *Plastic and Reconstructive Surgery—Global Open*, 1(5), e34. <https://doi.org/10.1097/gox.0b013e3182a4bc9d>
- Inada, Y., Fukui, A., Tamai, S., & Mizumoto, S. (1993). The arterialized venous flap: Experimental studies and a clinical case. *British Journal of Plastic Surgery*, 46(1), 61–67. [https://doi.org/10.1016/0007-1226\(93\)90067-1](https://doi.org/10.1016/0007-1226(93)90067-1)
- Koch, H., Scharnagl, E., Schwarzl, F. X., Haas, F. M., Hubner, M., & Moshhammer, H. E. T. (2004). Clinical application of the retrograde arterialized venous flap. *Microsurgery*, 24(2), 118–124. <https://doi.org/10.1002/micr.20011>
- Koshima, I., Soeda, S., Nakayama, Y., Fukuda, H., & Tanaka, J. (1991). An arterialized venous flap using the long saphenous vein. *British Journal of Plastic Surgery*, 44(1), 23–26. [https://doi.org/10.1016/0007-1226\(91\)90171-f](https://doi.org/10.1016/0007-1226(91)90171-f)
- Lee, J.-H., Alrashdan, M. S., Kim, S.-G., Rim, J. S., Jabaiti, S., Kim, M. J., & Kim, S. M. (2011). Functional and esthetic assessment of radial forearm flap donor site repaired with split thickness skin graft. *European Archives of Oto-Rhino-Laryngology*, 268(1), 109–115. <https://doi.org/10.1007/s00405-010-1314-z>
- Loeffelbein, D. J., Al-Benna, S., Steinsträßer, L., Satanovskij, R. M., Rohleder, N. H., Mücke, T., Wolff, K. D., & Kesting, M. R. (2012). Reduction of donor site morbidity of free radial forearm flaps: What level of evidence is available? *Eplasty*, 12, e9.
- Murray, R. C., Gordin, E. A., Saigal, K., Leventhal, D., Krein, H., & Heffelfinger, R. N. (2011). Reconstruction of the radial forearm free flap donor site using integra artificial dermis. *Microsurgery*, 31(2), 104–108. <https://doi.org/10.1002/micr.20833>
- Nakayama, Y., Soeda, S., & Kasai, Y. (1981). Flaps nourished by arterial inflow through the venous system. *Plastic and Reconstructive Surgery*, 67(3), 328–334. <https://doi.org/10.1097/00006534-198103000-00009>
- Pabst, A. M., Werkmeister, R., Steegmann, J., Hölzle, F., & Bartella, A. (2018). Is there an ideal way to close the donor site of radial forearm free flaps? *British Journal of Oral and Maxillofacial Surgery*, 56, 444–452. <https://doi.org/10.1016/j.bjoms.2018.04.016>
- Pittet, B., Quinodoz, P., Alizadeh, N., Schlaudraff, K.-U., & Mahajan, A. L. (2008). Optimizing the arterialized venous flap. *Plastic and Reconstructive Surgery*, 122(6), 1681–1689. <https://doi.org/10.1097/prs.0b013e31818cbef1>
- Richardson, D., Fisher, S. E., Vaughan, D. E., & Brown, J. S. (1997). Radial forearm flap donor-site complications and morbidity: A prospective study. *Plastic and Reconstructive Surgery*, 99(1), 109–115. <https://doi.org/10.1097/00006534-199701000-00017>
- Rieger, U. M., Majenka, P., Wirthmann, A., Sohn, M., Bozkurt, A., & Djedovic, G. (2016). Comparative study of the free microvascular groin flap: Optimizing the donor site after free radial forearm flap Phalloplasty. *Urology*, 95, 192–196. <https://doi.org/10.1016/j.urology.2016.04.007>
- Rozen, W. M., & Leong, J. (2012). Arterialized venous flow-through flaps with dual discontinuous venous drainage. *Plastic and Reconstructive Surgery*, 130(1), 229e–231e. <https://doi.org/10.1097/prs.0b013e3182550260>
- Rozen, W. M., Ting, J. W. C., Gilmour, R. F., & Leong, J. (2012). The arterialized saphenous venous flow-through flap with dual venous drainage. *Microsurgery*, 32(4), 281–288. <https://doi.org/10.1002/micr.21949>
- Sang-Hyun, W., Sung-Eun, K., Tae-Hoon, L., Jae-Ho, J., & Jung-Hyun, S. (1998). Effects of blood flow and venous network on the survival of the arterialized venous flap. *Plastic and Reconstructive Surgery*, 101(5), 1280–1289. <https://doi.org/10.1097/00006534-199804050-00019>
- Schwarzer, C., Mücke, T., Wolff, K.-D., Loeffelbein, D. J., & Rau, A. (2016). Donor site morbidity and flap perfusion of subfascial and suprafascial radial forearm flaps: A randomized prospective clinical comparison trial. *Journal of Cranio-Maxillofacial Surgery*, 44(9), 1299–1304. <https://doi.org/10.1016/j.jcms.2016.06.025>
- Shaikh, S. A., Bawa, A., Shahzad, N., Yousufzai, Z., & Ghani, M. S. (2018). Reducing the donor site morbidity in radial forearm free flaps by utilizing a narrow radial forearm free flap. *Archives of Plastic Surgery*, 45(4), 345–350. <https://doi.org/10.5999/aps.2018.00115>
- Shonka, D. C., Kohli, N. V., Milam, B. M., & Jameson, M. J. (2017). Suprafascial harvest of the radial forearm free flap decreases the risk of postoperative tendon exposure. *Annals of Otology, Rhinology & Laryngology*, 126(3), 224–228. <https://doi.org/10.1177/0003489416685322>
- Sidebottom, A. J., Stevens, L., Moore, M., Magennis, P., Devine, J. C., Brown, J. S., & Vaughan, E. D. (2000). Repair of the radial free flap donor site with full or partial thickness skin grafts. *International Journal of Oral and Maxillofacial Surgery*, 29(3), 194–197. <https://doi.org/10.1034/j.1399-0020.2000.290307.x>
- Weng, W., Zhang, F., Zhao, B., Wu, Z., Gao, W., Li, Z., & Yan, H. (2017). The complicated role of venous drainage on the survival of arterialized venous flaps. *Oncotarget*, 8(10), 16414–16420.
- Yan, H., Brooks, D., Ladner, R., Jackson, W. D., Gao, W., & Angel, M. F. (2010). Arterialized venous flaps: A review of the literature. *Microsurgery*, 30(6), 472–478. <https://doi.org/10.1002/micr.20769>
- Zheng, D.-W., Li, Z.-C., Shi, R.-J., Sun, F., Xu, L., & Shou, K.-S. (2016). Use of giant-sized flow-through venous flap for simultaneous reconstruction of dual or multiple major arteries in salvage therapy for complex upper limb traumatic injury. *INJ*, 47(2), 364–371. <https://doi.org/10.1016/j.injury.2015.11.037>
- Zuo, K. J., Roy, M., Meng, F., Bensoussan, Y., & Hofer, S. O. P. (2018). Aesthetic and functional outcomes of radial forearm flap donor site reconstruction with biosynthetic skin substitutes. *Journal of Plastic, Reconstructive & Aesthetic Surgery*, 71(6), 925–928. <https://doi.org/10.1016/j.bjps.2018.01.038>

**How to cite this article:** Hughes, K. R., Fong, A., Rozen, W. M., & Leong, J. C. S. (2022). The arterialised saphenous venous flow-through flap for managing the radial forearm free flap donor site. *Microsurgery*, 42(4), 333–340. <https://doi.org/10.1002/micr.30883>