

Case Report

Campylobacter Pouchitis Mimicking the Appearance of Crohn's Disease

Greg S. Cohen and Meena Prasad

Department of Medicine, Division of Gastroenterology, Northwestern University, Chicago, IL 60611, USA

Correspondence should be addressed to Greg S. Cohen; gcohenmd@gmail.com

Received 11 May 2016; Accepted 13 July 2016

Academic Editor: Olga I. Giouleme

Copyright © 2016 G. S. Cohen and M. Prasad. This is an open access article distributed under the Creative Commons Attribution License, which permits unrestricted use, distribution, and reproduction in any medium, provided the original work is properly cited.

An unusual case of campylobacter pouchitis resembling the endoscopic appearance of Crohn's disease is reported.

1. Introduction

Proctocolectomy with ileal pouch-anal anastomosis (IPAA) is the preferred treatment for medically refractory ulcerative colitis (UC), UC-associated dysplasia or malignancy, and familial adenomatous polyposis. Postoperative complications of IPAA include pouchitis, Crohn's disease of the pouch, cuffitis, and irritable pouch syndrome [1, 2]. Pouchitis almost exclusively affects those with UC rather than FAP, and it usually responds well to treatment with antibiotics. However, pouchitis remains the most frequent complication of IPAA with a prevalence up to 50% and a significant impact on quality of life [1–3]. The majority of pouchitis cases are idiopathic but up to 20–30% of cases are found to have an identifiable cause including acute infections [4].

2. Case Presentation

A 41-year-old man with ulcerative colitis and a history of total proctocolectomy with subsequent IPAA for toxic megacolon in 1999 presented with fever, right lower quadrant abdominal pain, and diarrhea. Since the IPAA, he had mild recurrent acute pouchitis a few times per year, with symptoms of increased stool frequency and urgency, which would promptly resolve with 2–3 days of ciprofloxacin and metronidazole. His most recent episode of pouchitis was 4 months prior to presentation. Five days prior to presentation, he developed a fever up to 103°F and watery diarrhea every

20–30 minutes. Four days prior to presentation, he developed severe right lower quadrant abdominal pain that became progressively worse. Complete blood count, serum electrolytes, renal function, and liver function tests were normal except for mild acute kidney injury with creatinine 1.37 mg/dL. C-reactive protein was markedly elevated at 27 mg/dL. CT of the abdomen and pelvis with IV and PO contrast showed wall thickening of the distal ileum and pouch with no abscess. Due to his high fever, he was started on piperacillin-tazobactam empirically. *Clostridium difficile* PCR, ova and parasites, giardia stool antigen, and cryptosporidium stool antigen were all negative. He subsequently underwent pouchoscopy, which demonstrated an endoscopic pattern resembling Crohn's disease in the pouch and distal ileum with severe inflammation, marked friability, and deep ulcerations within the pouch and prepouch ileum (Figures 1(a) and 1(b)). However, histologically the small bowel mucosa was acutely inflamed with no evidence of chronic inflammation, architectural distortion, or granulomas. Stains for CMV and HSV were negative.

On hospital day 4, a stool culture was positive for campylobacter and subsequently further characterized as *Campylobacter coli* by matrix assisted laser desorption ionization-time of flight (MALDI-TOF) mass spectrometry. At this point, the patient's stool frequency had improved to 7 bowel movements per day and he had defervesced on piperacillin-tazobactam. He was discharged on Azithromycin 500 mg by mouth daily for a total of 10 days to treat severe *Campylobacter coli* pouchitis. On follow-up 4 months later a pouchoscopy

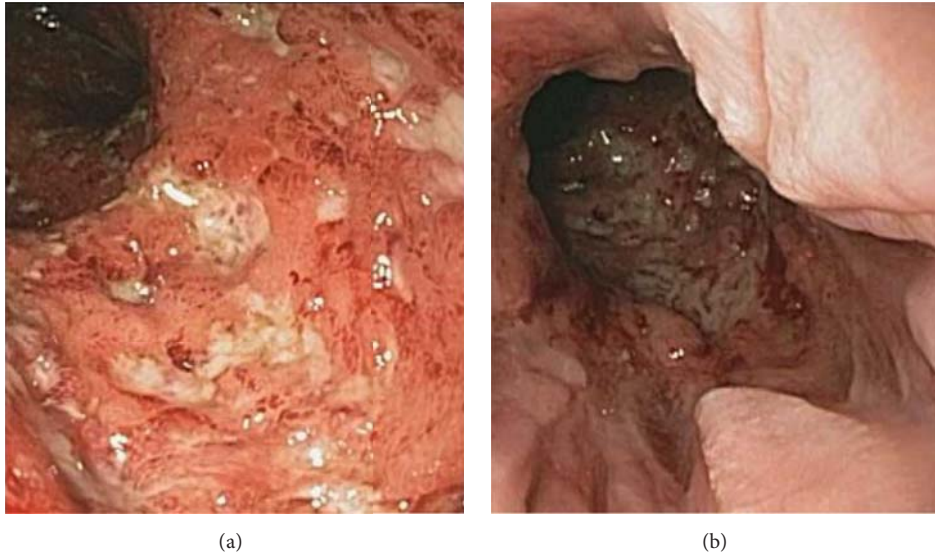


FIGURE 1: (a) Prepouch ileum. (b) Distal pouch.

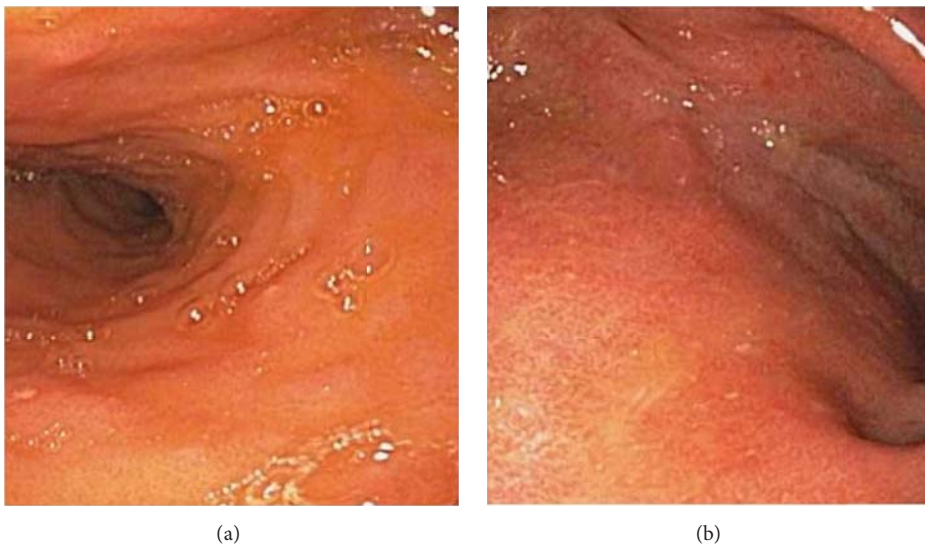


FIGURE 2: (a) Prepouch ileum. (b) Distal pouch.

showed normal mucosa in the pouch and prepouch ileum (Figures 2(a) and 2(b)) and he continues to do well today.

3. Discussion

Campylobacter is an uncommon cause of pouchitis [5], but this case serves as a reminder to check for its presence in severe acute pouchitis. Patients with enteric infections from *Campylobacter* species typically present with symptoms of fever followed by abdominal pain, dehydration, and diarrhea and occasionally display endoscopic features that mimic Crohn's disease. Cases of campylobacter enterocolitis causing transmural inflammation resulting in small intestinal obstruction and toxic megacolon in patients without

inflammatory bowel disease have been described [6, 7]. Two cases have been reported to date describing ulcerative colitis patients with ileal pouches affected by campylobacter-associated infection, both presenting with high fever, dehydration, abdominal pain, and increased bowel frequency [5]. In this case, the lack of histological evidence of chronic inflammation to suggest Crohn's disease would have raised suspicion for acute infectious ileitis even in the absence of a stool culture positive for campylobacter.

Competing Interests

The authors declare that there is no conflict of interests regarding the publication of this paper.

References

- [1] V. W. Fazio, Y. Ziv, J. M. Church et al., "Ileal pouch-anal anastomoses complications and function in 1005 patients," *Annals of Surgery*, vol. 222, no. 2, pp. 120–127, 1995.
- [2] W. J. Sandborn, "Pouchitis following heal pouch-anal anastomosis: definition, pathogenesis, and treatment," *Gastroenterology*, vol. 107, no. 6, pp. 1856–1860, 1994.
- [3] J. C. Coffey, D. C. Winter, P. Neary, A. Murphy, H. P. Redmond, and W. O. Kirwan, "Quality of life after ileal pouch-anal anastomosis: an evaluation of diet and other factors using the cleveland global quality of life instrument," *Diseases of the Colon and Rectum*, vol. 45, no. 1, pp. 30–38, 2002.
- [4] U. Navaneethan and B. Shen, "Secondary pouchitis: those with identifiable etiopathogenetic or triggering factors," *The American Journal of Gastroenterology*, vol. 105, no. 1, pp. 51–64, 2010.
- [5] B. Shen, "Campylobacter infection in patients with ileal pouches," *American Journal of Gastroenterology*, vol. 105, no. 2, pp. 472–473, 2010.
- [6] D. J. Perkins and G. L. Newstead, "Campylobacter jejuni enterocolitis causing peritonitis, ileitis and intestinal obstruction," *The Australian and New Zealand Journal of Surgery*, vol. 64, no. 1, pp. 55–58, 1994.
- [7] L. Larvol, E. Zeitoun, J. Barge, A. Valverde, I. Delaroque, and J. C. Soule, "Toxic megacolon with colonic perforation complicating Campylobacter jejuni ileo-colitis," *Gastroenterologie Clinique et Biologique*, vol. 18, no. 3, pp. 281–284, 1994.