

Effect of interventional embolization treatment for hydrosalpinx on the outcome of in vitro fertilization and embryo transfer

Xin Hong, MD^a, Wen-bin Ding, MD^a, Rui-fan Yuan, MD^a, Jia-yi Ding, MD^b, Jie Jin, MD^{a,*}

Abstract

To explore the effect of interventional embolization treatment for hydrosalpinx on the outcome of in vitro fertilization and embryo transfer (IVF-ET).

During the period from January 2013 to January 2015, a total of 129 patients with unilateral or bilateral hydrosalpinx were treated with IVF-ET and selected for retrospective analysis. Seventy-three patients (intervention group) with unilateral or bilateral hydrosalpinx were treated with fallopian tube embolization, which was followed by IVF-ET. During the same period, 56 patients (control group) with unilateral or bilateral hydrosalpinx directly received IVF-ET without receiving any treatment for hydrosalpinx.

The clinical pregnancy rate of the control group was significantly lower than that of the intervention group ($P < .05$), while the abortion rate and ectopic pregnancy rate of the control group were strikingly higher than that of the intervention group ($P < .05$).

Hydrosalpinx can decrease the clinical pregnancy rate of IVF-ET, and increase the incidence of abortion and ectopic pregnancy. The interventional embolization treatment for hydrosalpinx before IVF-ET can improve the clinical pregnancy rate and reduce adverse pregnancy outcome and which, with the advantages of a high success rate, convenient use, low cost, less pain, no anesthetic risk and no effect on the ovarian function it may further be developed for use in the clinic.

Abbreviations: HSG = hystero-salpingography, IVF-ET = in vitro fertilization and embryo transfer, MR = magnetic resonance, RV = right ventricle.

Keywords: hydrosalpinx, in vitro fertilization and embryo transfer, interventional oviduct embolization, microcoil, pregnancy outcome

1. Introduction

Fallopian tube plays an important role in the reproductive process as the fertilization place of sperm and eggs and the transport channel of fertilized eggs.^[1] Any problems with the fallopian tubes may lead to infertility. According to the survey data, fallopian tube diseases are the main reason for infertility (accounting for 40%), while hydrosalpinx accounts for 10%–30% of various fallopian tube diseases.^[2] Since the success of first in vitro fertilization and embryo transfer (IVF-ET), the technology has brought good news for infertility patients. However, the outcome of IVF-ET is disappointing for patients with hydrosalpinx. Statistical results show that hydrosalpinx can

reduce implantation rate and clinical pregnancy rate of IVF-ET while increasing early abortion rate and ectopic pregnancy rate.^[3] The possible mechanism includes mechanical erosion action,^[4] the toxic effect of embryo and gamete,^[5] and reduced endometrial receptivity.^[6] Therefore, pretreatment for hydrosalpinx before IVF-ET has significant value. Current treatments for hydrosalpinx mainly include ultrasound-guided hydrosalpinx aspiration, fimbria salpingostomy, proximal tubal ligation, and tubectomy.^[7] Hydrosalpinx aspiration and salpingostomy may cause high recurrence rate of hydrosalpinx and high ectopic gestation rate.^[8] As a mature therapy, tubectomy can significantly improve the pregnancy outcome of patients with hydrosalpinx while easily injuring the arteries of fallopian tube-mesovarium which may affect ovarian blood flow and reduce ovarian reserve function and superovulation response.^[9] Recently, with the development of interventional radiology, interventional embolization has been applied in the treatment for hydrosalpinx before IVF-ET and which achieved a certain therapeutic effect. With the advantages of convenient use, low cost, no anesthetic risk, and no effect on ovarian function, it significantly improves pregnancy rate and reduces ectopic gestation rate.^[10]

2. Materials and methods

2.1. General data

During the period from January 2013 to January 2015, a total of 129 patients with hydrosalpinx who were treated with IVF-ET were selected as objects. This study was approved by the Ethics Committee of The Second Affiliated Hospital of Nantong

Editor: Heye Zhang.

XH and W-bD are co-first authors and they contributed equally to the work.

The authors have no conflicts of interest to disclose.

^a Department of Interventional Radiology, The Second Affiliated Hospital of Nantong University, ^b Center for Reproductive Medicine, Nantong Maternal and Child Care Service Centre, Nantong, Jiangsu Province, China.

* Correspondence: Jie Jin, Department of Interventional Radiology, The Second Affiliated Hospital of Nantong University, Nantong, Jiangsu Province, China (e-mail: 15951310500@163.com).

Copyright © 2018 the Author(s). Published by Wolters Kluwer Health, Inc. This is an open access article distributed under the terms of the Creative Commons Attribution-Non Commercial-No Derivatives License 4.0 (CCBY-NC-ND), where it is permissible to download and share the work provided it is properly cited. The work cannot be changed in any way or used commercially without permission from the journal.

Medicine (2018) 97:48(e13143)

Received: 17 July 2018 / Accepted: 14 October 2018

<http://dx.doi.org/10.1097/MD.00000000000013143>

University. Informed consent was obtained from all participants and their guardians.

Enrollment condition:

- (1) regular menstrual cycle (23–32 days) with a period range of ± 3 days;
- (2) no other reasons for infertility except tubal factor (eg, semen abnormality);
- (3) no gynecological endocrinology diseases such as endometriosis, polycystic ovarian syndrome, and pituitary-hypothalamic lesion;
- (4) no fibroid and history of ovarian operation;
- (5) no use of sexual hormones within 3 months before operation;
- (6) normal basal hormone level; and
- (7) no interruption or discontinuity of treatment during assisted reproduction period of IVF-ET. Seventy-three patients in the intervention group (unilateral hydrosalpinx: $n=34$, bilateral hydrosalpinx: $n=39$) were treated with fallopian tube embolization, which was followed by IVF-ET. Fifty-six patients in the control group (unilateral hydrosalpinx: $n=24$, bilateral hydrosalpinx: $n=32$) directly received IVF-ET without receiving any pretreatment for hydrosalpinx.

2.2. Methods

2.2.1. Interventional embolization. Interventional embolization could be completed by the outpatient procedure. Patients with normal parameters received interventional embolization after a routine examination of chlamydia, mycoplasma, and leucorrhea. The patients using the digital subtraction angiography with routine disinfection, draping, and chamber testing in a lithotomy position. Then fluoroscopically-guided 7F oviduct catheter was inserted into cornua uteri of hydrosalpinx across the cervical canal. Under the guidance of 0.018in guidewire, 3F microcatheter was gently inserted into the interstitial section and isthmus of the fallopian tube, after which guidewire was slowly pulled out. According to the length of inserted microcatheter and the thickness of the fallopian tube, proper microcoil was selected and released via a 3F catheter in the drive of the guidewire (trying to locate the near-end of microcoil in the cornua uteri next to interstitial section). Contralateral fallopian tube of patients with bilateral hydrosalpinx was treated with the same method. Finally, hystero-salpingography (HSG) was conducted to verify the effect of embolization. After a month, HSG was performed again to

verify the embolization and patients without therapeutic effect need another embolization (Fig. 1).

2.2.2. Therapeutic evaluation of embolism.

- (1) Significant effect: Microcoil located in fallopian tube with a length of near-end to oviduct aperture <10 mm;
- (2) Effective: The length of near-end to oviduct aperture was 10–30 mm; and
- (3) Invalid: Contrast agent permeated to the far-end cross microcoil; microcoil shifted to the far-end or fallen off to the uterine cavity.

2.2.3. IVF-ET assisted reproduction scheme. Routine long protocol of gonadotrophin releasing hormone agonists in controlled ovarian hyperstimulation was applied, and IVF and observation were conducted with a routine method. ET was performed on the third day of in vitro culture, β -human chorionic gonadotropin (HCG) detection 2 weeks after transplant and b ultrasonic examination 4 weeks after transplant. A fertilized egg and fetal heart beat were determined as clinical pregnancy which was followed by the follow-up to delivery.

2.2.4. Observation index. Age, basal E2 value, basal follicle stimulating hormone (FSH) value, Gn dosage, antral follicle count, follicle count on the day of HCG administration, the E2 value on the day of HCG administration, fertility rate, cleavage rate, clinical pregnancy rate, the rate of abortion and ectopic pregnancy rate.

2.3. Statistical approach

Count data was described as case number or percentage and measurement data as mean \pm SD. *T* test, X^2 test, and rank sum test were applied and a significant difference was considered when $P < .05$. Statistical software: SPSS 13.0 and Microsoft office excel.

3. Results

3.1. The effective rate of interventional embolization and HSG in reexamination a month after surgery

Among 73 patients in the intervention group (unilateral hydrosalpinx: $n=34$, bilateral hydrosalpinx: $n=39$), 111 of 112 fallopian tubes had a successful embolism. HSG reexamination

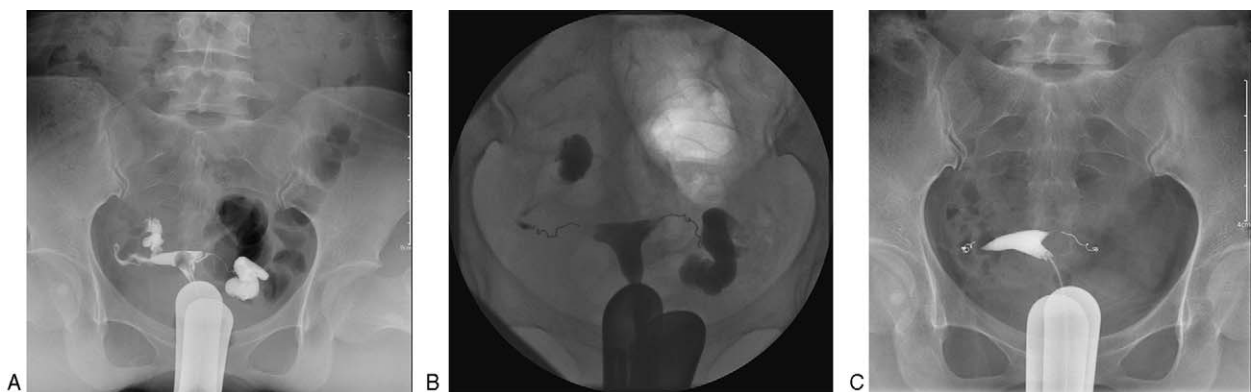


Figure 1. Pretreatment and post-treatment of interventional embolization. A. Bilateral hydrosalpinx examined by HSG before the operation; B. Microcoil locating in the interstitial section of the bilateral fallopian tube after embolism; C. Microcoil crimp in the isthmus of the fallopian tube and no osmosis of contrast agent to the far-end in reexamining. HSG = hystero-salpingography.

Table 1
General conditions between two groups.

	Intervention group n=73	Control group n=56	t value	P value
Age	31.6±3.8	32.4±3.3	1.254	.212
Basal FSH value (U/L)	8.8±1.9	8.5±2.2	0.830	.408
Basal E2 value (pmol/L)	168.2±20.3	173.6±24.6	1.365	.175
Antral follicle count	10.7±3.6	11.5±4.1	1.178	.241

FSH=follicle stimulating hormone

after a month showed that microcoil of one patient shifted to the ampullar region and remedial embolism was successful. Therefore, the total success rate was 100% and 97 fallopian tubes had a significant effect, accounting for 86.6%. During therapeutic process, no serious complications occurred except abdominal pain and colporrhagia in few patients. Twelve patients had severe abdominal pain without special treatment for spontaneous remission.

3.2. Comparison of general conditions in two groups

There was no statistical difference in general conditions such as age, antral follicle count, basal E2 value and basal FSH value between two groups ($P > .05$), shown in Table 1.

3.3. Comparison of IVF-ET index in two groups

There was no statistical difference in Gn dosage, the E2 value on the day of HCG administration, follicle count on the day of HCG administration, retrieved oocyte number, fertility rate, cleavage rate between two groups ($P > .05$), shown in Table 2.

3.4. Comparison of pregnancy outcome index in two groups

The clinical pregnancy rate of the intervention group was significant statistical higher than the control group ($P < .05$). The rate of abortion and the ectopic pregnancy rate was significant statistical higher than the control group ($P < .05$) (Table 3).

Table 2
Comparison of IVF-ET index in two groups.

	Intervention group n=73	Control group n=56	t value	P value
Gn	26.7±4.9	27.3±5.2	0.671	.503
E2 value on the day of HCG administration (pmol/l)	1228.5±225.2	1276.4±251.9	1.137	.258
Follicle count on the day of HCG administration	14.3±4.5	12.9±5.1	1.653	.101
Retrieved oocyte number	11.7±4.6	10.6±4.3	1.385	.169
Fertility rate	72.6±6.5	73.1±7.8	0.397	.692
Cleavage rate	95.4±7.1	94.2±8.6	0.868	.387

HCG=human chorionic gonadotropin, IVF-ET=in vitro fertilization and embryo transfer.

Table 3
Comparison of pregnancy outcome index in two groups.

	Intervention group n=73	Control group n=56	χ ² value	P value
Clinical pregnancy rate	39.7 (29/73)	21.4 (12/56)	0.671	.036
Rate of abortion	6.9 (2/29)	33.3 (4/12)	1.137	.029
Ectopic pregnancy rate	3.4 (1/29)	25.0 (3/12)	1.653	.034

4. Discussion

The previous study showed that due to hydrosalpinx, IVF-ET reduced 50% clinical pregnancy rate, while doubling the spontaneous abortion rate.^[3] The possible mechanism includes:

- (1) Mechanical erosion action generated by the backflow of hydrosalpinx to uterine cavity may affect normal implantation of embryo and cause hydrohystera which blocks the combination of embryo with intima;
- (2) As embryo is sensitive to pH, electrolyte, osmotic pressure and various growth factors in vegetation process, the hydrosalpinx may cause toxic effect on embryo and gamete; and
- (3) Stimulated by the microorganism, fragments of tissue and toxic substance in hydrosalpinx, the uterine cavity will release cytokines, prostaglandin, leukocyte chemokines, and other inflammatory substances, which reduces endometrial receptivity.^[11] Our study shows that interventional embolization therapy followed by IVF-ET can effectively block the effect of hydrosalpinx on embryo and significantly increase the clinical pregnancy rate of IVF-ET while reducing the ectopic pregnancy rate. This is consistent with the clinical results of in vitro fertilization-embryo transfer with the ultrasound-guided aspiration of tubal hydrops that occurs during the controlled ovarian hyperstimulation of Zhou Y et al^[12] And they demonstrated that inhalation of hydrosalpinx during controlled ovarian hyperstimulation can significantly improve the clinical outcome of IVF-ET, but not the previously occurring hydrosalpinx. The effect of interventional embolization before and after controlled ovarian hyperstimulation on IVF-ET remains to be further reported.

Current treatments for hydrosalpinx mainly include ultrasound-guided hydrosalpinx aspiration, fimbria salpingostomy, proximal tubal ligation, and tubectomy before IVF-ET. Simple hydrosalpinx aspiration fails to improve the clinical pregnancy rate, implantation rate and parturition rate of IVF-ET but causes relapsing hydrosalpinx.^[8] Salpingostomy may cause high recurrence rate of hydrosalpinx in short period and high incidence of abortion and ectopic gestation.^[13] Tubectomy and proximal tubal ligation can significantly improve the clinical pregnancy rate and reduce ectopic pregnancy rate. However, they may easily injure mesovarium artery arches, which may affect

ovarian blood flow and reduce ovarian reserve function and superovulation response.^[14] In interventional embolization, microcoil is placed between the interstitial section and the isthmus of the fallopian tube via an interventional operation. Its mechanism of action is described as:

(1) mechanically complete partition of tubular lumina and
 (2) alkaline phosphatase released by mild mechanical necrotic tissue can benefit lymphocytic aggregation and proliferation of vascular tissue, which increases the embolization of tubular lumina.^[15] A mechanical method in interventional embolization of fallopian tube has no effect on ovarian function. Our results show that there are no significant statistical differences in the two groups of the Gn dosage, follicle count, and E2 value on the day of HCG administration (All *P* value < .05), which proves the opinion above.

Reasons for ectopic gestation in patients with hydrosalpinx are unclear, possibly including:

- (1) Fallopian tube thickens due to hydrosalpinx, easily leading to ectopic gestation;
- (2) Mechanical erosion action generated by the backflow of hydrosalpinx to uterine cavity may affect normal implantation;
- (3) Hydrosalpinx reduces endometrial receptivity which influences embryo implantation; and
- (4) Endometrium injury caused by retrograde infection affects endometrial receptivity.^[16] In our study, the ectopic pregnancy rate of the control group is higher than that of intervention group, indicating that pretreatment of interventional embolization for hydrosalpinx before IVF-ET can reduce ectopic pregnancy rate.

HSG reexamination of interventional embolization shows that 29 microcoils have mild shifts to the far-end fallopian tube (range 5–30 mm). Possible reasons are:

- (1) For patients with linearization and thickening symptoms between the interstitial section and isthmus, microcoil before fixation would have a shift under increased abdominal pressure and
- (2) Due to the thick ampullar region of the fallopian tube, the spring coil slides in the tractive force of crimped microcoil. In our study, the patients with significantly effective treatment have no ectopic gestation, while there have 1 patient have ectopic gestation locating between cornua uteri and spring coil after effective treatment. Therefore, the proper microcoil which placed near cornua uteri is necessary for the operation. Besides, counseling after operation should be attached importance.

With the advancement of science and technology, the deep learning method of computers has developed rapidly, especially in the field of medical image recognition. This method can accurately identify specific nuances between a sequence of frames and successive frames. Studies have accurately segmented the right ventricle (RV) through cardiac magnetic resonance (MR) images, which can help doctors to robustly quantify clinical indicators including ejection fraction.^[17–19] Similarly, whether the method can also be applied to the interventional embolization of tubal edema, this method can more accurately know the different degrees of hydrosalpinx and the need for embolization, maximize the success rate of IVF-ET, prevent over-medication and insufficient treatment for the purpose of patients.

5. Conclusion

With advantages of definite therapeutic effect, high success rate, convenient use, no anesthetic risk, low cost, less pain and no effect on ovarian function, interventional embolization can

significantly improve the success rate of IVF-ET and reduce ectopic gestation rate. As a new pretreatment for hydrosalpinx, interventional embolization may further be applied for use in the clinic with potential development prospect.

Author contributions

Conceptualization: Xin Hong, Rui-fan Yuan.

Data curation: Wen-bin Ding.

Formal analysis: Jia-yi Ding.

Funding acquisition: Rui-fan Yuan.

Methodology: Jia-yi Ding.

Resources: Wen-bin Ding.

Software: Wen-bin Ding, Jie Jin.

Supervision: Jie Jin.

Writing – original draft: Xin Hong.

References

- [1] Le J. *Obstetrics and Gynecology*. 2008; People's Medical Publishing House, Beijing:7–25.
- [2] Zhao HC, Zhu L. Effect of hydrosalpinx on assisted reproduction and its treatment. *Chin J Birth Health Hered* 2011;19:9–11.
- [3] Sharma JB, Sneha J, Singh UB, et al. Comparative study of laparoscopic abdominal pelvic and fallopian tube findings before and after antitubercular therapy in female genital tuberculosis with infertility. *J Minim Invasive Gynecol* 2016;23:215–22.
- [4] Sagoskin AW, Lessey BA, Mortla GL, et al. Salpingectomy or proximal tubal occlusion of unilateral hydrosalpinx increases the potential for spontaneous pregnancy. *Hum Reprod* 2003;18:2634–7.
- [5] Chanr LY, Chiu PY, Lau TK. Hydrosalpinx fluid induced embryotoxicity and lipid peroxidation. *Reprod Toxicol* 2004;19:147–8.
- [6] Kirichenko AK, Khorzhevskii VA. Endometrial vasculature in women with hydrosalpinx. *Arkh Patol* 2014;76:59–64.
- [7] D'Arpe S, Franceschetti S, Caccetta J, et al. Management of hydrosalpinx before IVF: a literature review. *J Obstet Gynaecol* 2015;35:547–50.
- [8] Hinckley MD, Milki AA. Rapid reaccumulation of hydrometra after drainage at embryo transfer in patients with hydrosalpinx. *Fertil Steril* 2013;80:1268–71.
- [9] Ye XP, Yang YZ, Sun XX. A retrospective analysis of the effect of salpingectomy on serum anti-Müllerian hormone level and ovarian reserve. *Am J Obstet Gynecol* 2015;212:51–3.
- [10] Li Q, Yang HL. Clinical application of fallopian tube embolization for pretreatment of hydrosalpinx before IVF-ET. *J Int Reprod Health/Fam Plan* 2009;28:298–300.
- [11] Yang J, Wang YQ. Effect evaluation of hydrosalpinx on embryo implantation. *J Reprod Contracept* 2014;34:584–9.
- [12] Zhou Y, Jiang H, Zhang WX, et al. Ultrasound-guided aspiration of hydrosalpinx occurring during controlled ovarian hyperstimulation could improve clinical outcome of in vitro fertilization-embryo transfer. *J Obstet Gynaecol Res* 2016;42:960–5.
- [13] Yang HY. Effect of the management of hydrosalpinx on the clinical outcome of in vitro fertilization and embryo transfer. *J Reprod Med* 2008;17:165–8.
- [14] Qian CX, Chen KM, Song FZ, et al. Effect of embolotherapy treatment of hydrosalpinx on the clinical outcome of in vitro fertilization and embryo transfer. *J Interv Radiol* 2014;23:311–3.
- [15] Wu XM, Li Q. Management of hydrosalpinx before in vitro fertilization and embryo transfer. *Chin J Fam Plan Gynecotokol* 2009;1:65–8.
- [16] Li HM, Jin L. Risk factors for ectopic pregnancy in IVF/ICSI. *Chin J Birth Health Hered* 2010;18:118–20.
- [17] Kong B, Wang X, Li Z, et al. Cancer metastasis detection via spatially structured deep network. *International Conference on Information Processing in Medical Imaging*. 2017; Springer, Cham:236–48.
- [18] Chen J, Zhang H, Zhang W, et al. Correlated regression feature learning for automated right ventricle segmentation. *IEEE J Transl Eng Health Med* 2018;6:1–0.
- [19] Kong B, Zhan Y, Shin M, et al. Recognizing end-diastole and end-systole frames via deep temporal regression network. *International Conference on Medical Image Computing and Computer-Assisted Intervention*. 2016; Springer, Cham:264–72.