

Case report

Spinal cord compression: an unusual presentation of hepatocellular carcinoma

Hileni Taleni Nangolo^{1,&}, Larrea Roberto¹, Innocent Lule Segamwenge¹, Andreas Voigt², Fredrick Kidaaga³

¹Department of Internal Medicine, Intermediate Hospital Oshakati, Oshakati, Namibia, ²Department Orthopedic Surgery, Intermediate Hospital Oshakati, Oshakati, Namibia, ³Namibian Institute of Pathology, Khomas, Namibia

[&]Corresponding author: Innocent Lule Segamwenge, Department of Internal Medicine, Intermediate Hospital Oshakati, Oshakati, Namibia

Key words: Hepatocellular carcinoma, spinal cord compression, spine metastases

Received: 06/04/2014 - Accepted: 25/11/2014 - Published: 09/12/2014

Abstract

Hepatocellular carcinoma is the 5th most common cancer in men and the 2nd common cause of death from cancer worldwide. The tumour commonly metastasizes to the lungs, regional lymph nodes and bone. Spinal cord compression secondary to metastatic disease as a first presentation is uncommon. We describe a patient who presented with paraplegia as a first presentation of hepatocellular carcinoma. 46 year old Namibian man presented with progressive leg weakness that was associated with a dull back ache and inability to pass urine and stool. He had no history of trauma nor did he have chronic cough, night sweats or fevers. He has been treated several times for alcohol dependence. On examination he was wasted, power 0/5 in both lower limbs and a sensory level at T12. He also had a non-tender hepatomegaly with Alpha-fetoprotein of 2000. The Chest X-ray and Chest CT showed nodular opacities indicating metastatic disease and the X-ray and CT of the thoracic spine showed osteolytic lesion with destruction of the pedicle of L1. Liver and spinal biopsy confirmed the hepatocellular carcinoma. The extra hepatic manifestations of HCC are diverse and Spinal cord metastasis is of pertinent clinical importance and should thus be greatly considered.

Pan African Medical Journal. 2014; 19:363 doi:10.11604/pamj.2014.19.363.4323

This article is available online at: <http://www.panafrican-med-journal.com/content/article/19/363/full/>

© Hileni Taleni Nangolo et al. The Pan African Medical Journal - ISSN 1937-8688. This is an Open Access article distributed under the terms of the Creative Commons Attribution License (<http://creativecommons.org/licenses/by/2.0>), which permits unrestricted use, distribution, and reproduction in any medium, provided the original work is properly cited.

Introduction

Hepatocellular carcinoma (HCC) is a common tumour in sub-Saharan Africa and a common cause of death in the continent [1]. This big burden of the tumour is largely driven by the high prevalence of Hepatitis B virus infection (HepB) in Africa. The tumour commonly presents as right upper quadrant abdominal pain with a mass in association with other features of hepatic decompensation. The tumour commonly metastasizes to the lungs, regional lymph nodes and bone [2, 3]. Initial presentation with spinal cord presentation is rare to our knowledge only a few case reports have described such a presentation. We describe a patient who presented with spinal cord compression as the first manifestation of hepatocellular carcinoma.

Patient and observation

A 46 year old Namibian male was referred to our hospital from a district Hospital with complaints of legs weakness for 3 weeks. The patient was in his usual state of health until 3 weeks prior, when he developed progressive leg weakness associated with dull back pain localized to thoracic area. He also noticed inability to pass urine and stool. There was no history of trauma to the back preceding this presentation. There were no complaints related to other body systems except general malaise and weight loss. His past medical history was significant for being on treatment for schizophrenia which was well controlled on haloperidol. In addition he had been treated several times for alcohol dependence. On physical examination we found a middle aged man, sick looking and markedly wasted. He was apyrexial with finger clubbing and below knee bilateral pitting edema. His Vital signs were normal. He had reduced muscle bulk in all limbs reflecting generalized wasting. The tone in the lower limbs was reduced, with power of 0/5 bilaterally and absent knee and ankle reflexes. The Babinski sign was present and he had a sensory level at T12. The upper limbs were normal with power of 5/5. The abdomen was mildly distended, with a firm non tender hepatomegaly 4cm below costal margin. There was no splenomegaly and the kidneys were not palpable. The lungs were clear on auscultation.

The patient liver function tests were consistent alcoholic hepatitis with a ratio of aspartate transaminase (AST) 180 IU/l to alanine transaminase (ALT) 70 IU/l greater than 2:1. The alkaline phosphatase (ALP) and Gamma-glutamyltransferase (GGT) were high 269 IU/l and 223 IU/l respectively. He had hypoalbuminemia of 25g/l and the serology for hepatitis B was consistent with chronic hepatitis B infection and Hepatitis C serology was unreactive. His Alpha-feto protein was elevated 2000 ng/ml and the International normalized ratio (INR) was normal at 0.98. The abdominal ultrasound revealed the liver to be enlarged with multiple hyperechoic masses biggest measuring 4x4 cm in diameter and ascites. The Chest X Ray and Chest Computed Tomography (CT) Scan showed bilateral nodular lesions in keeping with pulmonary metastatic disease. (**Figure 1, Figure 2**). Spinal X Ray and CT scan showed lumbar 1 (L1) osteolytic vertebra body lesions with left pedicle destruction and L4 osteopenia without anterior wedging, kyphosis or destruction of the adjacent intervertebral disk spaces (**Figure 3, Figure 4**).

A liver biopsy was done which showed features of liver cirrhosis and hepatocellular carcinoma. Computed tomography guided biopsy and histology of the paravertebral mass showed features consistent with a metastatic hepatocellular carcinoma and the abnormal cells were

positive to immunostains for Hep par 1 (**Figure 5, Figure 6**). The patient was not offered palliative radiotherapy for his spine metastases because the spinal cord compression had lasted over 3 weeks. He was offered tramadol and was discharged on morphine and lactulose for his pain control and supportive nursing care. He expired after one month hospital stay.

Discussion

Hepatocellular carcinoma is the 5th most common cancer in men and the second most common cause of death from cancer worldwide [4]. It is largely a problem of less developed regions accounting for 83% of new cases of hepatocellular cancer worldwide. This high burden of the cancer is largely driven by the high burden of hepatitis B virus infection in these regions. Other risk factors for HCC include hepatitis C virus infection, aflatoxin, alcoholic liver disease and rarer diseases like Wilson's disease, haemochromatosis and alpha 1 antitrypsin deficiency. Our patient had two major risk factors associated with development of HCC were present; the history of Hepatitis B infection and the alcohol induced liver damage.

Most patients with HCC present with right upper quadrant abdominal pain, solitary or diffuse abdominal mass and hepatomegaly [5]. However, patients may have initial symptoms that are related exclusively to extrahepatic metastases [5]. Extrahepatic metastases are associated with advanced intrahepatic tumours, vessel invasion and reduced 1 year survival. The lungs are the most frequent metastatic site for HCC followed by lymph nodes, bone and adrenal glands [3]. Among patients with bone metastases the vertebrae is the most common site followed by the pelvis, ribs and skull respectively [6]. Our patient did not have any symptoms related to the primary tumor. Rather, he had an extrahepatic presentation; paraplegia as consequence of spinal cord compression secondary to HCC metastases. Metastatic presentation with spinal cord compression is unusual, however there is an expanding body of evidence in the medical literature reporting this type of presentation of HCC metastases [7-10]. Our patient had jaundice, bilateral leg oedema, finger clubbing and hepatomegaly. In addition the abdominal ultrasound showed an enlarged liver with multiple masses and alpha-feto-protein level of greater than 2000. These were suggestive signs to a possibility of a neoplastic process. Metastases were also confirmed in the lungs on plain chest x-ray and computed tomography (**Figure 1, Figure 2**). Biopsy of the liver and vertebrae confirmed metastatic hepatocellular carcinoma as the cause of spinal cord compression.

Spinal cord compression in sub-Saharan Africa is commonly due to Tuberculosis (TB) of the spine and prostate Carcinoma of older men. Our patient presented with a mass at the level of the 10th to 11th thoracic vertebrae, weight loss and paraplegia. Although the patient did not have other constitutional symptoms of fever and night sweats, these features were initially suggestive of a diagnosis of tuberculosis of the spine. The paravertebral mass was similar to a gibbus seen in patients with spinal TB. However, spinal plain X-rays and computed tomography scan of the spine showed osteolytic destructive lesions involving the first lumbar vertebra but affecting posterior vertebral body and left pedicle, sparing intervertebral disk space (**Figure 3**). TB of the spine is more common in children and young adults. In TB of the spine characteristically there is destruction of the intervertebral disk space and the adjacent vertebral bodies, collapse of the spinal elements, and anterior wedging. These changes lead to kyphosis and gibbus formation in the thoracolumbar region of vertebral column most frequently

affecting the mid-thoracic vertebrae. Since both tuberculosis and hepatocellular carcinoma are common in the less developed regions of the world, a broader differential diagnosis is required when evaluating patients with paraplegia in this part of the world.

Conclusion

It is worth stressing that HCC should be included in the differential diagnosis of metastatic extradural spinal cord compression, because it may be the initial manifestation, with or without overt signs of liver disease as occurred in our patient.

Authors' contributions

ILS, RL and HTN conceived the idea and wrote the manuscript with equal participation and input. ILS, RL, HTN and AV investigated and treated the patient. FK confirmed the diagnosis of metastatic disease in the spine and read the histologies. The final manuscript was read and approved by all authors. All authors have read and agreed to the final version of this manuscript and have equally contributed to its content and to the management of the case.

Acknowledgements

We are grateful to our patient for accepting to have this case published (R.I.P). We are also grateful to the administration and staff of Intermediate Hospital Oshakati, the Ministry of Health and Social Services of Namibia and the Namibian Institute of Pathology for the assistance offered in managing the patient.

Figures

- Figure 1:** chest x-ray showing nodular opacities in both lung fields
Figure 2: chest CT Scan of showing lung masses (blue arrows) and multiple nodules consistent with metastatic lung disease from Hepatocellular carcinoma
Figure 3: thoracic spine x-ray showing Osteolytic Left L1 lesion with missing pedicle (blue arrow)
Figure 4: CT scan showing L1 osteolytic vertebra body lesions (black arrow) with a soft tissue swelling and L4 osteopenia sparing intervertebral disk spaces
Figure 5: histological illustration of an AFP positively stained bone mass
Figure 6: H&E Bone mass

References

1. Kew MC. Epidemiology of hepatocellular carcinoma in sub-Saharan Africa. *Ann Hepatol.* 2013 Mar-Apr;12(2):173-82. **PubMed | Google Scholar**
2. Uchino K, Tateishi R, Shiina S, Kanda M, Masuzaki R, Kondo Y, et al. Hepatocellular carcinoma with extrahepatic metastasis: clinical features and prognostic factors. *Cancer.* 2011 Oct 1;117(19):4475-83. **PubMed | Google Scholar**
3. Natsuizaka M, Omura T, Akaike T, Kuwata Y, Yamazaki K, Sato T, et al. Clinical features of hepatocellular carcinoma with extrahepatic metastases. *J Gastroenterol Hepatol.* 2005 Nov;20(11):1781-7. **PubMed | Google Scholar**
4. Globocan. Estimated Incidence, Mortality and Prevalence Worldwide in 2012 http://globocan.iarc.fr/Pages/fact_sheets_cancer.aspx2012 [cited 2013 22/01/2014]. **PubMed | Google Scholar**
5. Trevisani F, D'Intino PE, Caraceni P, Pizzo M, Stefanini GF, Mazziotti A, et al. Etiologic factors and clinical presentation of hepatocellular carcinoma: Differences between cirrhotic and noncirrhotic Italian patient. *Cancer.* 1995;75(9):2220-32. **PubMed | Google Scholar**
6. Fukutomi M, Yokota M, Chuman H, Harada H, Zaitzu Y, Funakoshi A, et al. Increased incidence of bone metastases in hepatocellular carcinoma. *European journal of gastroenterology & hepatology.* 2001 Sep;13(9):1083-8. **PubMed | Google Scholar**
7. Kantharia B, Nizam R, Friedman H, Vardan S. Case report: spinal cord compression due to metastatic hepatocellular carcinoma. *The American journal of the medical sciences.* 1993 Oct;306(4):233-5. **PubMed | Google Scholar**
8. Sherif KA, Frandah W, Graham S, Phy M. Hepatocellular carcinoma as unusual cause for paraplegia. *Journal of clinical oncology : official journal of the American Society of Clinical Oncology.* 2012 Nov 1;30(31):e303-5. **PubMed | Google Scholar**
9. Doval DC, Bhatia K, Vaid AK, Pavithran K, Sharma JB, Hazarika D, et al. Spinal cord compression secondary to bone metastases from hepatocellular carcinoma. *World J Gastroenterol.* 2006 Aug 28;12(32):5247-52. **PubMed | Google Scholar**
10. Vargas J, Gowans M, Vandergrift WA, Hope J, Giglio P. Metastatic hepatocellular carcinoma with associated spinal cord compression. *The American journal of the medical sciences.* 2011 Feb;341(2):148-52. **PubMed | Google Scholar**

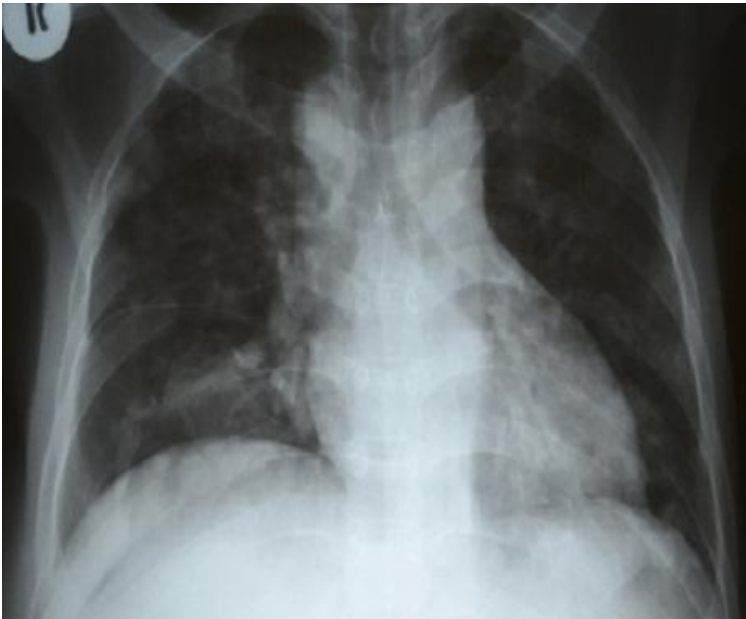


Figure 1: chest x-ray showing nodular opacities in both lung fields

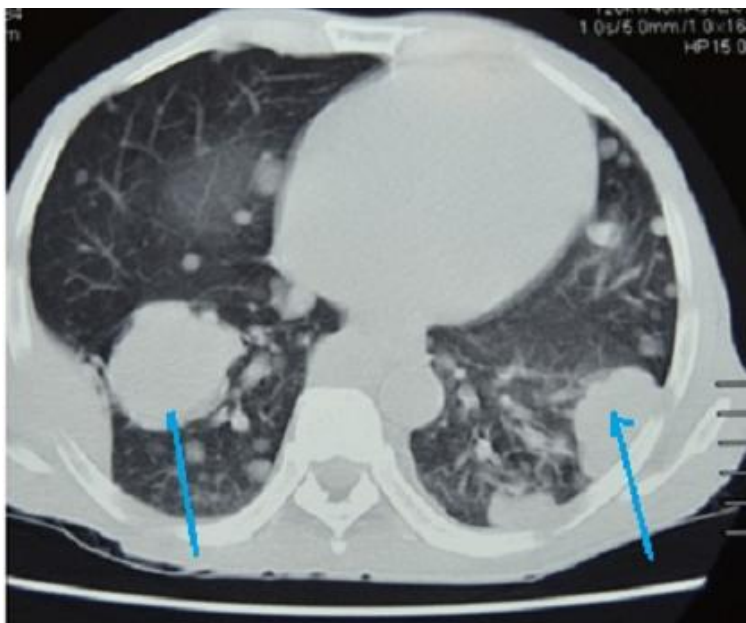


Figure 2: chest CT Scan of showing lung masses (blue arrows) and multiple nodules consistent with metastatic lung disease from Hepatocellular carcinoma

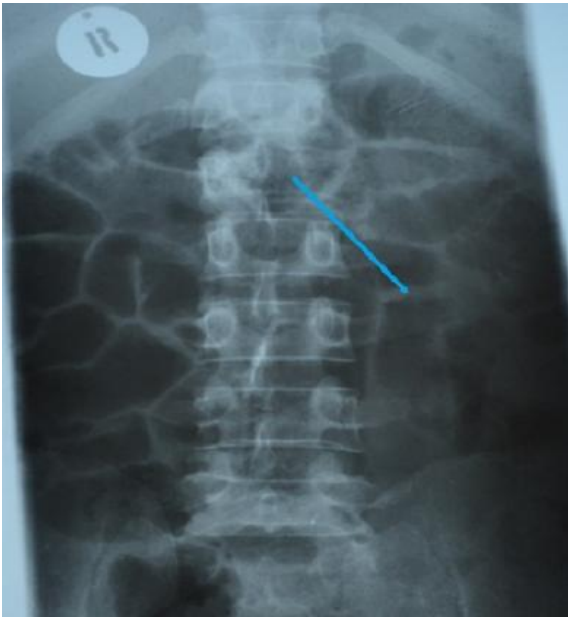

Figure 3: thoracic spine x-ray showing Osteolytic Left L1 lesion with missing pedicle (blue arrow)

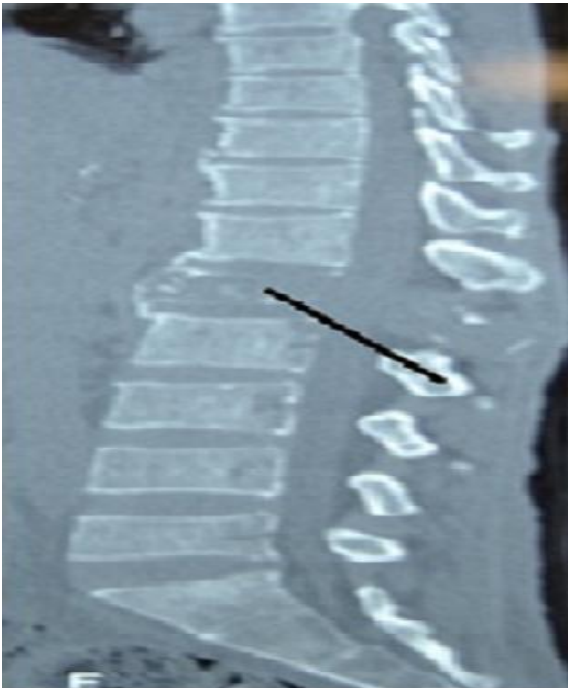

Figure 4: CT scan showing L1 osteolytic vertebra body lesions (black arrow) with a soft tissue swelling and L4 osteopenia sparing intervertebral disk spaces

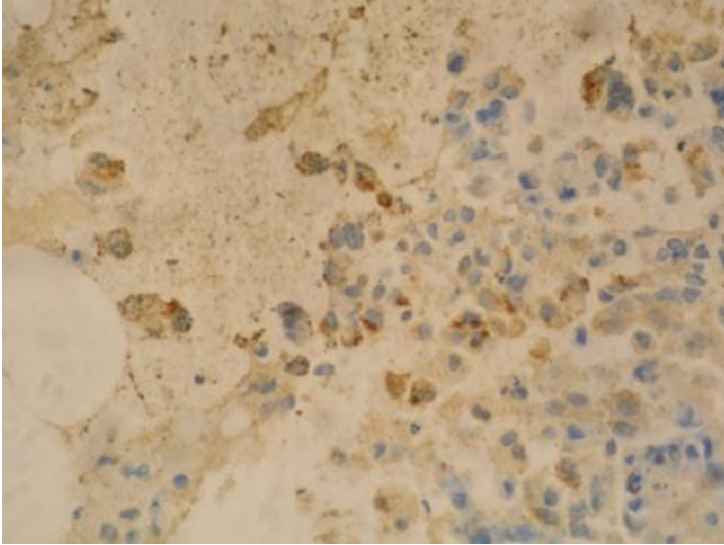


Figure 5: histological illustration of an AFP positively stained bone mass

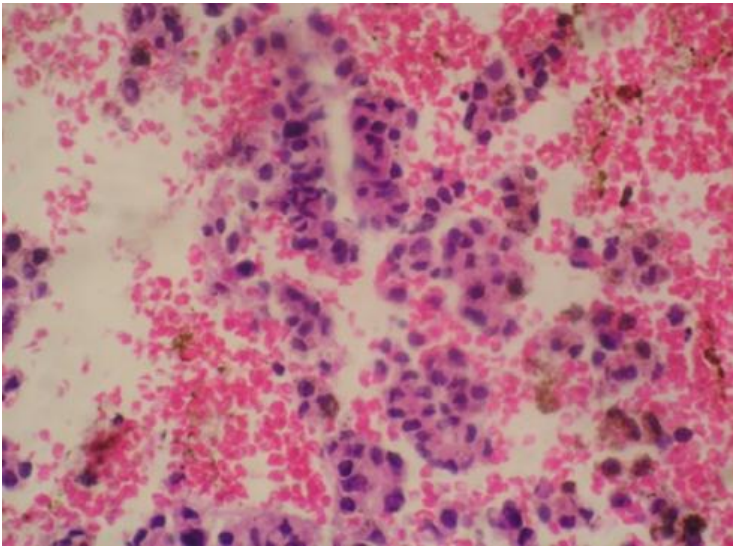


Figure 6: H&E Bone mass