



# Prinzmetal's Angina in a Pregnant Woman: a Case Report

Fariba Almassinokiani, MD<sup>1</sup>, Mahmood Reza Alebouyeh, MD<sup>1</sup>, Farshad Entesari, MD<sup>1</sup>, Seyed Hashem Sezavar Seyedi, MD<sup>1</sup>, Alireza Almasi, MD<sup>2</sup>, Hossein Akbari, MD<sup>3</sup>, Hossein Saidi, MD<sup>1\*</sup>, Homa Homam, MD<sup>4</sup>

<sup>1</sup>Rasool Akram Hospital, Tehran University of Medical Sciences, Tehran, Iran.

<sup>2</sup>Firoozgar Hospital, Tehran University of Medical Sciences, Tehran, Iran.

<sup>3</sup>Hazrat Fatemeh Hospital, Tehran University of Medical Sciences, Tehran, Iran.

<sup>4</sup>Akbarabadi Hospital, Tehran University of Medical Sciences, Tehran, Iran.

Received 04 February 2011; Accepted 09 July 2011

## Abstract

Acute myocardial infarction (MI) during pregnancy is rare and MI due to Prinzmetal's angina is much rarer. We present a 35-year-old, obese, multigravida, and pre-eclamptic woman, who developed acute anterior wall MI at the 30th week of gestation. On coronary angiography, the second obtuse marginal branch was totally occluded and the right coronary artery (RCA) was normal. Three days later, she had chest pain and ST elevation in the inferior leads. On second angiography, there was narrowing in the RCA, while the obtuse marginal branch was patent. We presume that this discrepancy between the first and second electrocardiograms and angiographic findings was due to Prinzmetal's angina.

*J Teh Univ Heart Ctr* 2012;7(2):85-89

**This paper should be cited as:** Almassinokiani F, Alebouyeh MR, Entesari F, Sezavar Seyedi SH, Almasi A, Akbari H, Saidi H, Homam H. Prinzmetal's Angina in a Pregnant Woman: Case Report. *J Teh Univ Heart Ctr* 2012;7(2):85-89.

**Keywords:** Prinzmetal's variant angina • Myocardial infarction • Pregnancy

## Introduction

Ischemic heart disease is rare during pregnancy, occurring in approximately one in 10,000 live births. The risk of myocardial infarction (MI) in pregnancy is reported from one per 37,500 to 6.2 per 100,000 deliveries.<sup>1-3</sup> The diagnosis is by clinical findings, electrocardiogram (ECG), and measurement of the serum level of the cardiac specific contractile protein, Troponin I.<sup>4,5</sup> The most common forms of angina are stable and unstable angina, which are usually due to atherosclerosis. But coronary spasm, coronary dissection, and thrombus have been reported as other causes.<sup>6,7</sup> Prinzmetal's angina (variant angina) is rare and it accounts for only 2 out of every 100 cases of angina.

We report a pregnant woman who presented with signs and symptoms of acute MI and whose ECG findings and Troponin I level were compatible with MI, leading to the final diagnosis of Prinzmetal's angina.

## Case Report

A 35-year-old woman, gravid 3 (with a history of two cesarean section operations), developed acute MI at the 30<sup>th</sup> week of gestation. She was a non-smoker and had no history of drug abuse or systemic disease. She referred to the emergency ward due to a sudden, severe pain in the neck and between the two scapulas that had started during sleep at 5 am,

\*Corresponding Author: Hossein Saidi, Assistant Professor of Emergency Medicine, Tehran University of Medical Sciences, Rasool Akram Hospital, Sattarkhan Street, Niayesh Street, Tehran, Iran. Tel: + 98 21 3100639. Fax: + 98 21 66509283. E-Mail: hsaidi@yahoo.com.

with cold sweat and nausea. Her blood pressure was 200/150 mm Hg; she had a history of increased blood pressure of two weeks' duration. The patient also had tachycardia, rales in the bases of the lungs, signs of anteroseptal MI in the ECG (Figure 1), and increased Troponin 1 blood level.

We performed a cesarean section operation because of severe preeclampsia, repeat cesarean section, and transverse lie. Four days after delivery, the patient's blood pressure was 140/80 mmHg and coronary angiography showed total occlusion of the second obtuse marginal artery (OM2) in addition to diffuse spasm of the left circumflex coronary artery (LCx) (Figure 2). The right coronary artery (RCA) was normal. At the seventh day after delivery in the ward, the patient had chest pain and ST-segment elevation in the inferior leads (Figure 3) as well as signs of pulmonary edema. The ECG changes reversed after intravenous Trinitroglycerin (Figure 4). Based on the ECG, the diagnosis was inferior wall ischemia. We performed angiography for a second time and surprisingly the LCx and OM2 coronary arteries were normal and there was narrowing in the RCA (Figure 5).

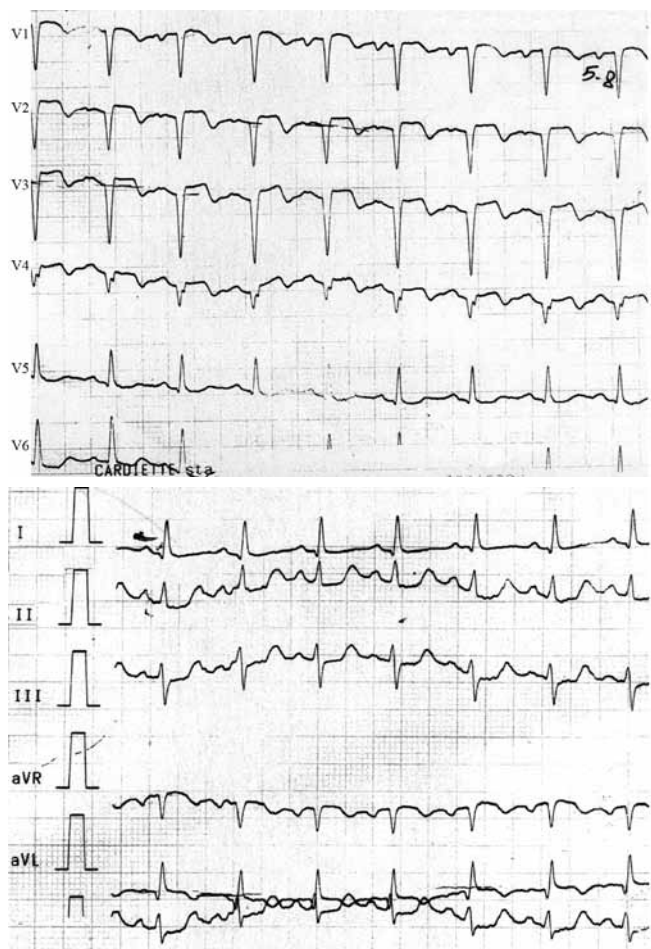
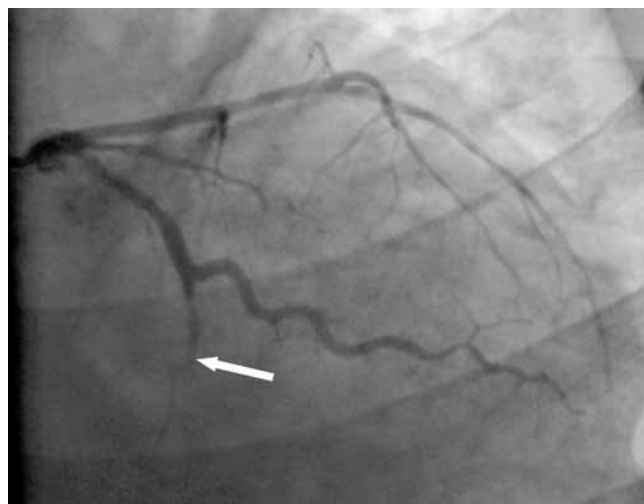
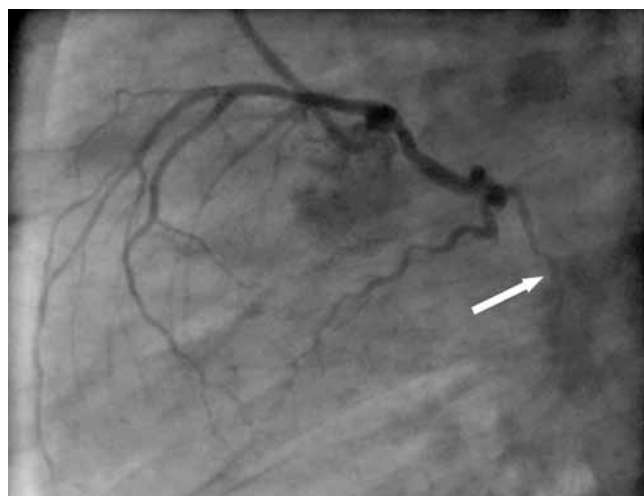


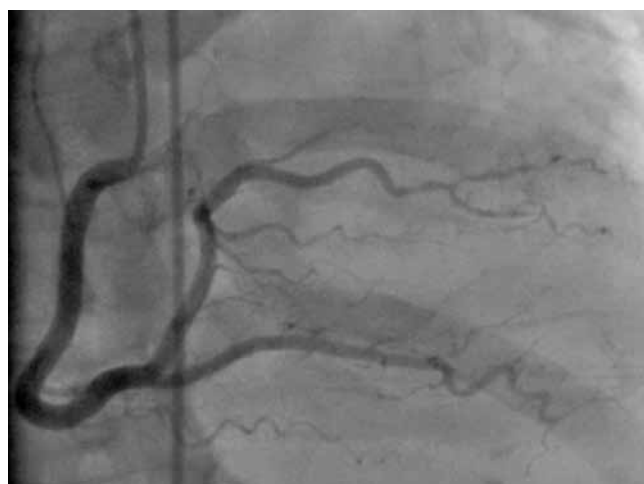
Figure 1. Signs of acute anteroseptal myocardial infarction on admission electrocardiogram



A



B



C

Figure 2. Coronary catheterization in the fourth day of hospitalization. A and B are the right anterior oblique (RAO) caudal and the left anterior oblique (LAO) caudal views of the left coronary, respectively. Diffuse left circumflex artery spasm is visible (arrows) in addition to the absence of the second obtuse marginal artery. C is the left anterior oblique cranial view of the right coronary injection, showing that the right coronary artery and its branches were normal

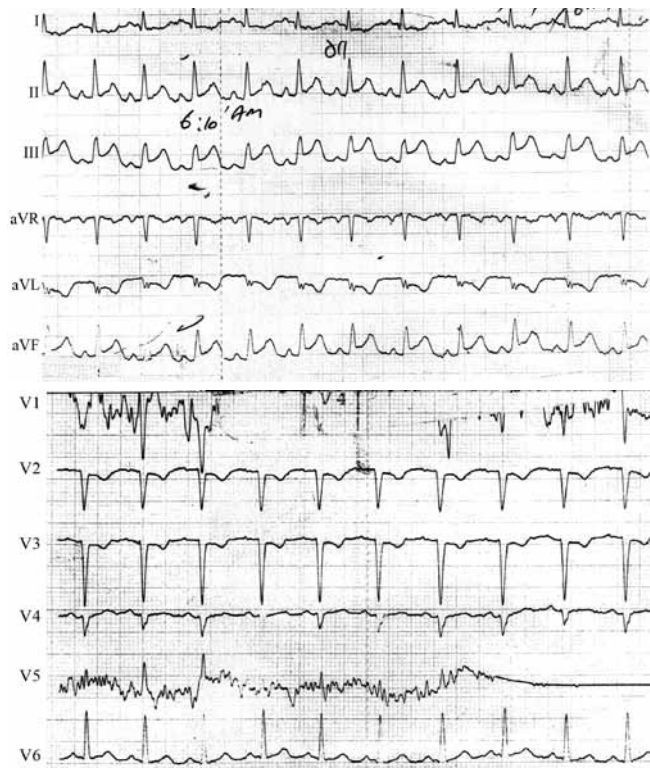
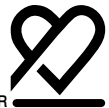

Figure 3. Seventh day after delivery, at 6:00 am, signs of previous anteroseptal myocardial infarction are visible in addition to signs of acute inferior wall ischemia because of Prinzmetal's angina

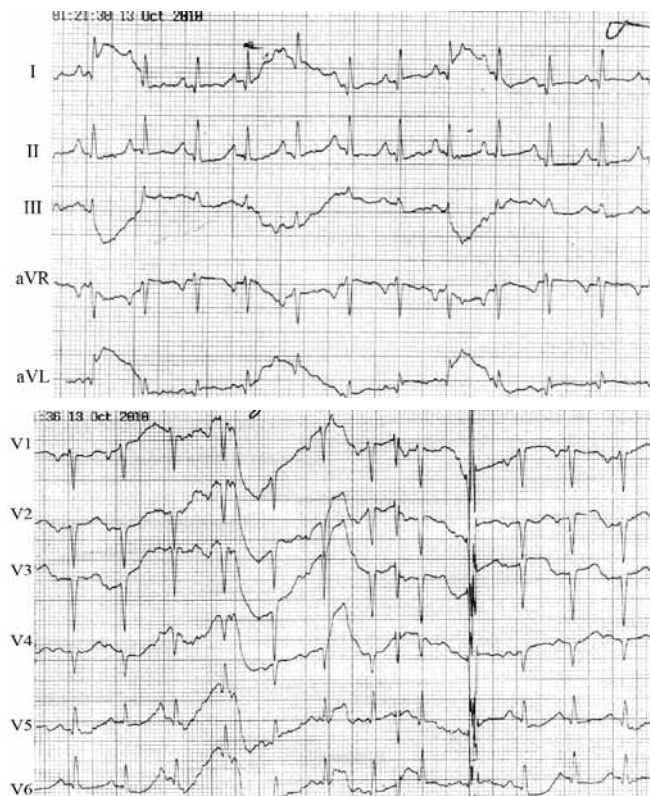
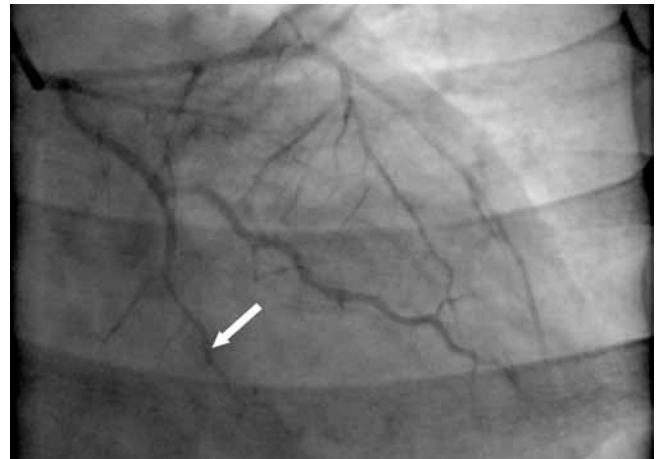
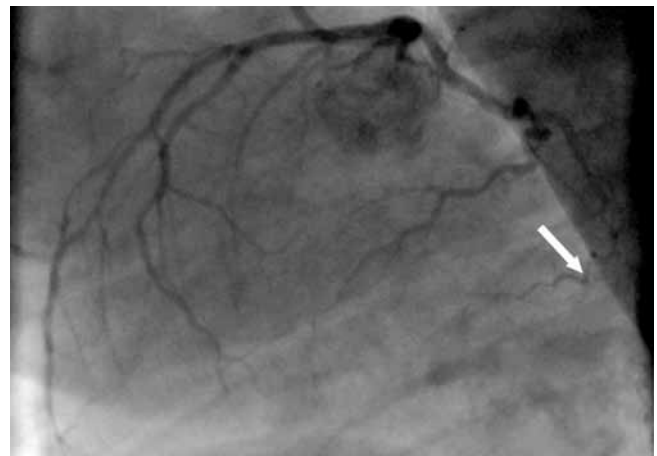


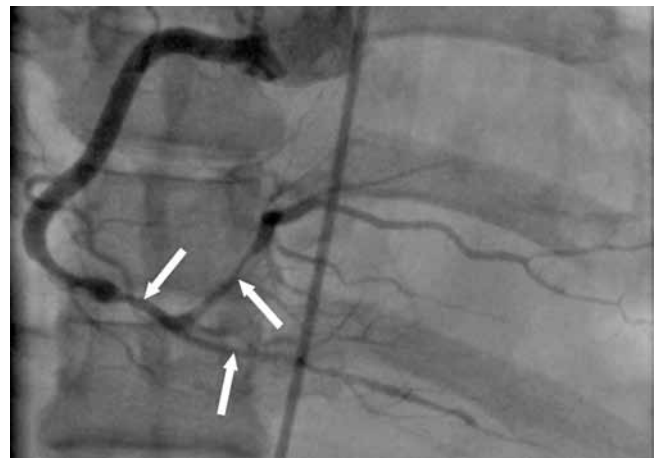Figure 4. Electrocardiogram on the fourth day after delivery at 8:00am, after intravenous Trinitroglycerin (IV TNG) administration, indicated that inferior wall ischemia (due to obtuse marginal artery spasm) had disappeared



A



B



C

Figure 5. Coronary catheterization in the seventh day of hospitalization. A and B are the right anterior oblique (RAO) caudal and the left anterior oblique (LAO) caudal views of the left coronary, respectively. They show relief of the left circumflex artery spasm and visibility of the second obtuse marginal artery (arrows), which was not visible in the previous angiography. C is the left anterior oblique cranial view of the right coronary injection, which shows obvious narrowing of the distal segment of the RCA and its branches (arrows), which were normal in the previous angiogram

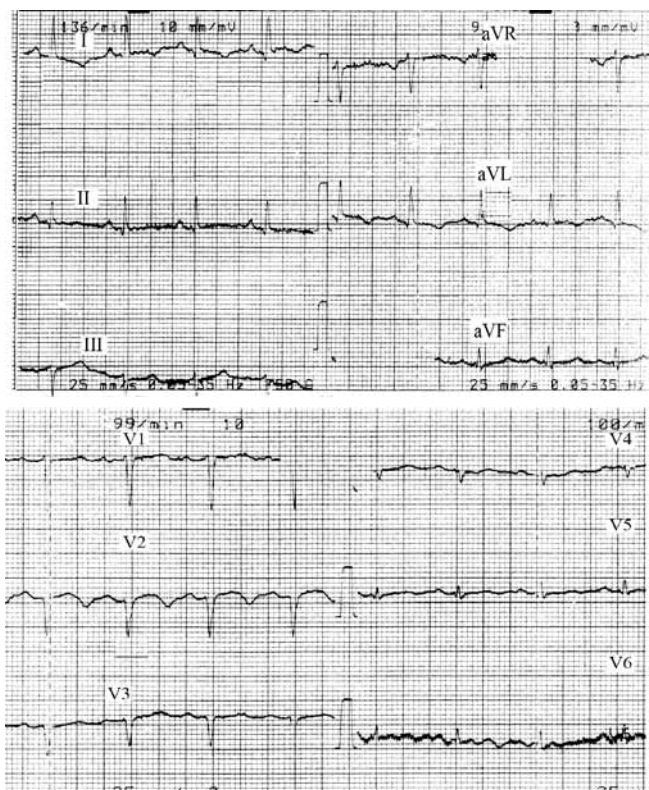


Figure 6. Electrocardiogram at the time of discharge showed that the inferior wall ischemia had disappeared, but signs of anteroseptal MI due to previous probable left anterior descending artery spasm at the time of admission still persisted

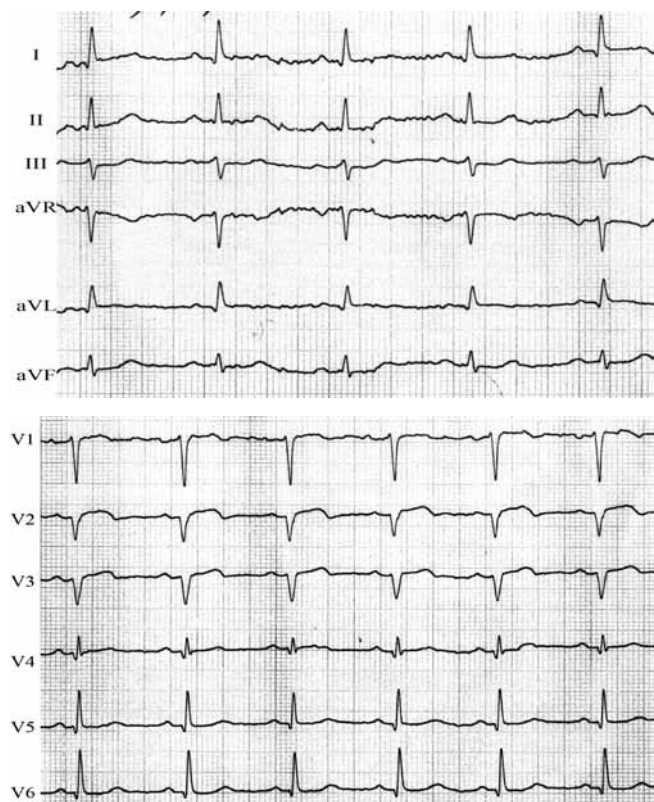


Figure 7. Electrocardiogram about three months after discharge demonstrated signs of anteroseptal myocardial infarction with no visible

inferior wall ischemia

We conclude that this discrepancy between the first and second ECGs and angiographic findings were due to Prinzmetal's angina. A few days later, the patient was discharged (blood pressure = 130/80 mmHg) on Diltiazem, Atorvastatin, Captopril, Nitrocontin, Furosemide, and Clopidogrel while the ECG showed previous anteroseptal MI (Figure 6). An ECG three months after discharge showed the same findings too (Figure 7).

## Discussion

MI in pregnancy is rare but can produce significant maternal and neonatal morbidity. Prompt diagnosis and immediate therapy are necessary to lower the high likelihood of the mortality of mother and fetus. The highest incidence of MI seems to occur in the third trimester and in multigravidas older than 33 years old. Acute MI in pregnancy is commonly located in the anterior wall, and acute maternal death rate is reported to be 19-30%.<sup>1-3, 8</sup> Complications of pregnancy that are significantly associated with acute MI are preeclampsia, postpartum hemorrhage, postpartum infection, and fluid and electrolyte imbalance.<sup>1, 9</sup> Shock from postpartum hemorrhage,<sup>10</sup> ergonovine,<sup>11</sup> and prostaglandin E1 (PGE1)<sup>12</sup> is reported as a risk factors for MI in pregnancy.

Our patient was a 35-year-old, obese, multiparous, pregnant woman with preeclampsia, and her symptoms of MI appeared at rest in the early hours of morning.

Angina pectoris in pregnancy is rare and Prinzmetal's angina is much rarer. It accounts for 2% of all cases of angina. Prinzmetal's angina usually occurs at rest and happens between the midnight and early morning. People with Prinzmetal's angina are often younger than those with the other forms of angina. It is caused by vasospasm but the mechanism of spasm is unknown yet. The gold standard for diagnosis is coronary angiography with injection of provocative agents (like Ergonovine) into the coronary arteries. Exaggerated spasm is diagnostic of Prinzmetal's angina. Also administration of intracoronary nitroglycerin in cases of vasospasm can cause marked diffuse vasodilatation.<sup>13</sup> Treatment with calcium-channel blockers or nitrates eliminates spasm in most of these patients.

## Conclusion

In our patient, the discrepancy between the first and second angiographic findings was the confirmatory evidence that she had Prinzmetal's angina. This conclusion was derived from the fact that the first angiographic examination showed that the LAD coronary artery was normal despite the definite occurrence of an MI in its territory, thus suggesting



transient spasm. Furthermore, a subsequent bout of inferior wall ischemia with confirmation of transient spasm by angiography was another piece of confirmatory evidence. Last but not least, asymptomatic RCA spasm, detected in the last angiography, was another clue to the propensity of the coronary arteries to vasospasm, which is the sine qua non of Prinzmetal's angina.

## References

1. James AH, Jamison MG, Biswas MS, Brancazio LR, Swamy GK, Myers ER. Acute myocardial infarction in pregnancy: a United States population-based study. *Circulation* 2006;113:1564-1571.
2. Ladner HE, Danielsen B, Gilbert WM. Acute myocardial infarction in pregnancy and the puerperium: a population-based study. *Obstet Gynecol* 2005;105:480-484.
3. Macarthur A, Cook L, Pollard JK, Brant R. Peripartum myocardial ischemia: a review of Canadian deliveries from 1970 to 1998. *Am J Obstet Gynecol* 2006;194:1027-1033.
4. Nabatian S, Quinn P, Brookfield L, Lakier J. Acute coronary syndrome and preeclampsia. *Obstet Gynecol* 2005;106:1204-1206.
5. Shade GH, Jr, Ross G, Bever FN, Uddin Z, Devireddy L, Gardin JM. Troponin I in the diagnosis of acute myocardial infarction in pregnancy, labor and postpartum. *Am J Obstet Gynecol* 2002;187:1719-1720.
6. Kealey A. Coronary artery disease and myocardial infarction in pregnancy: a review of epidemiology, diagnosis, and medical and surgical management. *Can J Cardiol* 2010;26:185-189.
7. Iadanza A, Del Pasqua A, Barbati R, Carrera A, Gentilini R, Favilli R, Pierli C. Acute ST elevation myocardial infarction in pregnancy due to coronary vasospasm: a case report and review of literature. *Int J Cardiol* 2007;115:81-85.
8. Roth A, Elkayam U. Acute myocardial infarction associated with pregnancy. *Ann Intern Med* 1996;125:751-762.
9. Poh CL, Lee CH. Acute myocardial infarction in pregnant women. *Ann Acad Med Singapore* 2010;39:247-253.
10. Karpati PC, Rossignol M, Pirot M, Cholley B, Vicaut E, Henry P, Kévorikian JP, Schurando P, Peynet J, Jacob D, Payen D, Mebazaa A. High incidence of myocardial ischemia during postpartum hemorrhage. *Anesthesiology* 2004;100:30-36.
11. Sutaria N, O'Toole L, Northridge D. Postpartum acute MI following routine ergometrine administration treated successfully by primary PTCA. *Heart* 2000;83:97-98.
12. Schulte-Sasse U. Life threatening myocardial ischaemia associated with the use of prostaglandin E1 to induce abortion. *BJOG* 2000;107:700-702.
13. Ornek E, Ornek D, Murat SN, Turfan M. Angiographic documentation of coronary artery spasm induced by anesthesia. *J Anesth* 2010;24:452-455.