

Arthroscopic “Double-Inlay” Eden-Hybinette Procedure with Modified Suture Button Fixation for the Revision of Failed Bristow-Latarjet



Zhenxing Shao, M.D., Ph.D., Xu Cheng, M.D., Hao Luo, M.D., and Guoqing Cui, M.D.

Abstract: Bristow-Latarjet procedure has been widely regarded as a reliable and satisfactory operation for recurrent anterior glenohumeral instability, especially for patients with significant glenoid bone loss or high sports demand. Once failed, however, the subsequent revision surgery could be challenging. Eden-Hybinette procedure is the most common operation for revision of failed Bristow-Latarjet. It can perfectly restore the bone defect of the failed Bristow-Latarjet by harvesting a proper size of iliac bone block. Furthermore, several studies have shown the advantages of using suture button fixation in the revision surgery for failed Bristow-Latarjet procedure. However, the potential inferior biomechanical strength of suture button fixation is still a concern. This Technical Note introduced an arthroscopic “double-inlay” Eden-Hybinette procedure with modified suture button fixation for the revision of failed Bristow-Latarjet. With its “quadruple” reinforcement effect, this procedure can achieve an excellent biomechanical strength of fixation.

Introduction

Bristow-Latarjet procedure has been widely regarded as a reliable and satisfactory operation for recurrent anterior glenohumeral instability, especially for patients with significant glenoid bone loss or high sports demand. Although the incidence of recurrent shoulder dislocation after Bristow-Latarjet procedure is very low, it still can occur because of trauma, nonunion/osteolysis of the bone block, hardware breakage, or a technical error (malposition of the coracoid bone block), etc., with an occurrence ranging from 0% to 8%.¹⁻³ The Eden-Hybinette procedure, which is one of the oldest surgical interventions for the treatment of anterior shoulder instability, has been widely proposed as a most common salvage procedure for failed Bristow-Latarjet.⁴⁻⁸ Currently, screw fixation is still the most common method of fixation of the coracoid for

Bristow-Latarjet. However, the management of broken screws after a failed Bristow-Latarjet will be an additional concern. Reinsertion of screws for fixation of the new bone graft may be difficult. On one hand, leaving broken screws in situ may compromise new hardware trajectory, while on the other hand, attempting to remove broken hardware might cause extra glenoid bone loss.^{2,9,10} Boileau et al. first¹¹ reported a Latarjet procedure with suture button fixation. Midterm results showed that suture button fixation is a reliable alternative to the Latarjet procedure, avoiding hardware-related complications.¹² And then Boileau et al. also applied this fixation method in the Eden-Hybinette procedure for the revision of failed Bristow-Latarjet.⁵ Although several studies have shown the advantages of using suture button fixation in the Bristow-Latarjet or Eden-Hybinette procedure,¹³⁻¹⁵ the potential inferior biomechanical strength of suture button fixation is still in concern.^{16,17}

This Technical Note introduced an arthroscopic “double-inlay” Eden-Hybinette procedure with modified suture button fixation for the revision of failed Bristow-Latarjet. This technique has two “Mortise-Tenon” structures. With its “quadruple” reinforcement effect, this procedure can achieve an excellent biomechanical strength of fixation.

Surgical Technique

Specific Instruments

Several special instruments were designed for this procedure (WEGO, Shandong, China):

Department of Sports Medicine, Peking University Third Hospital, Beijing, China.

Full ICMJE author disclosure forms are available for this article online, as supplementary material.

This study is supported by the National Key Research and Development Program of China (2018YFF0301100).

Received June 24, 2021; accepted August 5, 2021.

Address correspondence to Guoqing Cui, M.D., 49 North Garden Rd., Haidian District, Beijing, P.R. China. E-mail: drcuiguqing1964@126.com

© 2021 by the Arthroscopy Association of North America. Published by Elsevier. This is an open access article under the CC BY-NC-ND license (<http://creativecommons.org/licenses/by-nc-nd/4.0/>).

2212-6287/21952

<https://doi.org/10.1016/j.eats.2021.08.003>

1. The positioner ensures that the center of the first groove is medial to the anterior glenoid rim and up to the bottom of the glenoid with adjustable distance based on the size of the iliac bone and the glenoid (Fig 1, A and A').
2. The glenoid groove drilling bit is to make grooves for the iliac bone, with a diameter of 10 mm and a depth of 4 mm to increase the contact area of the iliac bone and the glenoid (Fig 1, B and B').
3. The iliac bone plug preparation drilling bit is used to produce a plug shape of the iliac bone fit to the grooves on the glenoid (Fig 1, C and C').
4. The positioner with 13-mm offset is to determine the center of the second groove on the glenoid, and the center of the second plug on the iliac bone. The 13-mm offset of this positioner will also ensure that there is 3-mm distance between the two grooves on the glenoid (Fig 1, D and D').

Patient Position and Arthroscopy Portals

The patient is placed in the "beach chair" position, and the patient is given general anesthesia combined with interscalene block. As a revision procedure for Bristow & Latarjet, the former portals of previous surgery are used in this procedure.¹⁵ No extra portals are needed.

Iliac Osteotomy and Preparation

The iliac bone graft is harvested using a standard technique. A tricortical bone graft measuring about

25 mm long and 15 mm deep is harvested using osteotomes. Then the iliac bone graft is trimmed to form two tenon structures on the truncation surface using specific instruments. First, a 2.5-mm-diameter K-wire is used to drill a hole on the truncation surface of the iliac bone graft, in the middle line and about 6 mm to one end longitudinally. Then a second hole is drilled 13 mm above the first hole using the positioner with 13 mm offset by inserting the head plug of the positioner into the first hole (Fig 1D). The two holes are reinserted with 2.5-mm-diameter K-wires. And centered on these two holes, two bone plugs with a diameter of 10-mm and 4-mm height (tenon structure), respectively, are made using the special drill bit (Fig 1C). The distance between the two plugs is 3 mm. Two Mini-TightRopes preloaded with a TigerWire suture (Arthrex, Naples, FL) loop are then pull through the two holes on the graft using Orthocord suture (Depuy, Raynham, Raynham, MA) as traction (Fig 2).

Debridement and Releasing

The debridement and release procedure mainly in scar tissue around the coracoid graft and conjoint tendon should be performed very carefully to avoid harming nerves and vessels, because the previous Bristow and Latarjet procedure has changed the anatomy. And the conjoint tendon should also be protected as long as it still can be identified (Supplemental Fig S1) (see Video 1).

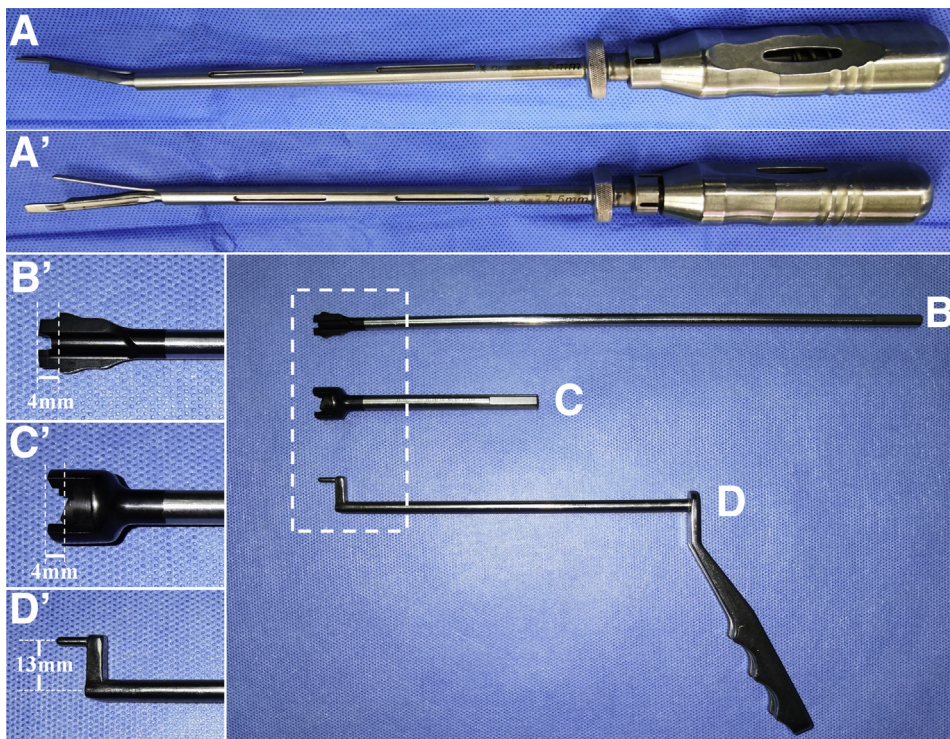
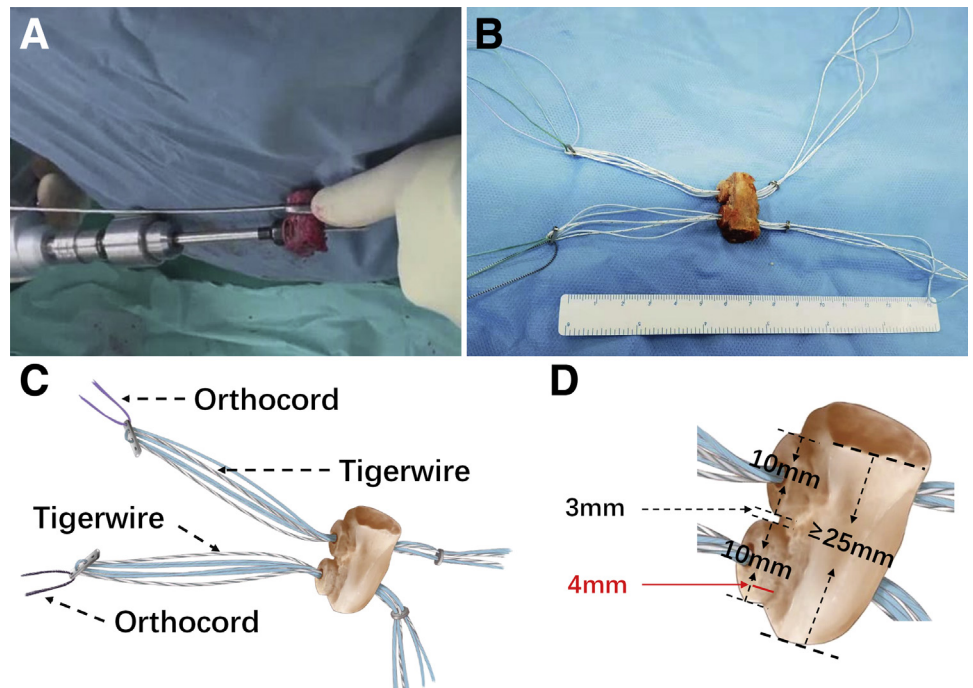


Fig 1. Specific instruments for this technique. (A and A') The positioner for the first hole on the glenoid: folded positioner (A); unfolded positioner (A') (the extra arm can rotate clockwise or counterclockwise to the left or right shoulder. The distance from the center to the both arms is 7.5 mm). (B and B') The drill bit for the grooves with 4-mm depth and 10-mm diameter. (C and C') The drill bit for the bone plug with 4-mm height on the iliac bone graft. (D and D') The positioner with a 13-mm offset for the second hole on the glenoid and iliac bone graft.

Fig 2. Iliac osteotomy and preparation. (A) The plugs are made on the iliac bone graft using the specific drill bit (c). (B) Two Mini-TightRopes preloaded with a TigerWire suture loop are pulled through the prepared iliac bone graft using Orthocord suture. (C) The illustration of the prepared iliac bone graft, with two Mini-TightRopes preloaded with a TigerWire suture loop. (D) The illustration of the size of the prepared iliac bone graft.



Glenoid Repreparation and Drilling

The anterior surface of the glenoid is refreshed. All residual suture threads and implants should be removed as much as possible. A special designed positioner (Fig 1A) is used to drill a hole about 4:30 o'clock on the anterior glenoid and about 7 mm to the glenoid surface (adjusted according to the size of iliac bone

graft) with a 2.5-mm K-wire (Fig 3, A and D). Then the second hole is drilled 13 mm above the first hole in the same method as on the iliac graft (Fig 3, B and D). The two holes are reinserted with 2.5-mm-diameter K-wires. Centered on these two holes, two bone grooves with a diameter of 10-mm and 4-mm depth (mortise structure), respectively, are made using the special drill

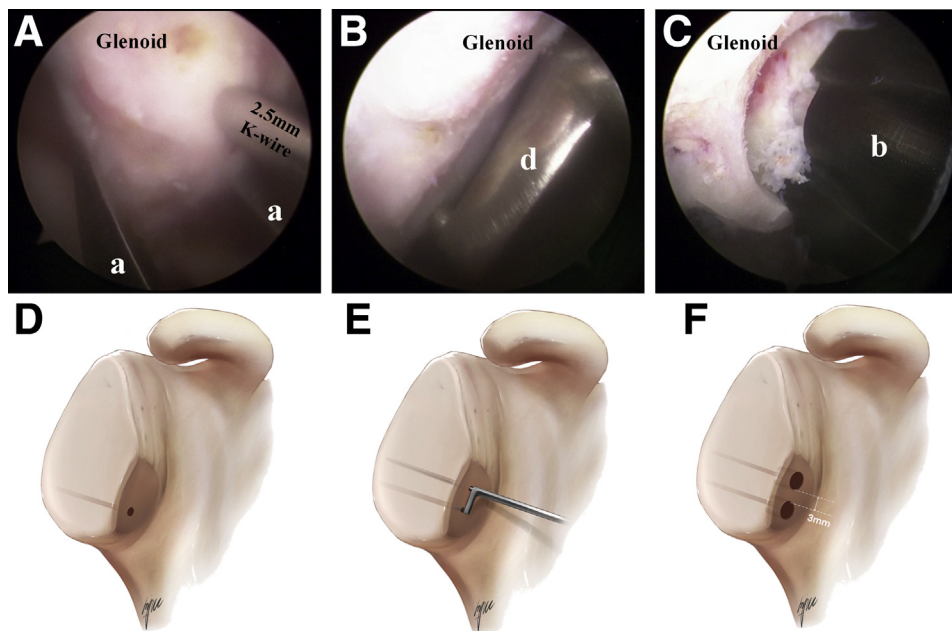


Fig 3. Glenoid repreparation and drilling. (Right shoulder, view from inferolateral portal, which is located in the axillary fold, 2 to 3 finger-widths distal to the coracoid tip; and the working portal located 3 to 4 finger-widths medial to the inferolateral portal through the pectoralis major muscle) (A) The first hole is drilled at about 4:30 o'clock on the anterior glenoid and about 7 mm to the glenoid surface (adjusted according to the size of iliac bone graft) with a 2.5-mm K-wire using the positioner (a). (B) The second hole is drilled 13 mm above the first hole using the positioner (d). (C) The bone groove with 4-mm depth and 10-mm diameter is made on the glenoid centered on the two hole. (D-F) The illustration of A-C.

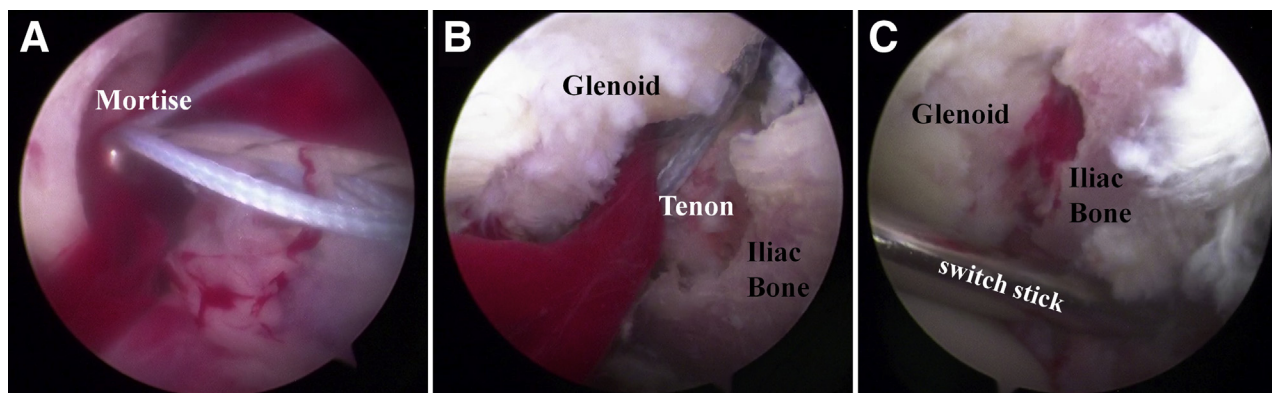


Fig 4. Iliac bone graft transfer. (Right shoulder, view from inferolateral portal, which located in the axillary fold, 2 to 3 finger-widths distal to the coracoid tip; and the working portal located 3 to 4 finger-widths medial to the inferolateral portal through the pectoralis major muscle) (A) The Mini-TightRope loaded on the iliac bone graft is pulled through the glenoid by the Orthocord threads. (B) The tenon structure made on the iliac bone graft perfectly fit into the mortise structure (grooves) made on the glenoid. (C) Confirmation of the perfectly fitting of the mortise-tenon structures.

bit (Fig 1B, Fig 3, C and E). The distance between the two grooves is 3 mm. An Orthocord thread is left in each hole for next step (the color is matched with the Orthocord thread on the Mini-TightRope) (see the Video 1).

Iliac Bone Graft Transferring and Fixation

The two Mini-TightRopes loaded on the iliac bone graft are pulled through the glenoid by the Orthocord threads (Fig 4A). So that the prepared iliac bone graft is pulled onto the anterior glenoid through the previous split on the subscapularis. And the tenon structure made on the iliac bone graft will perfectly fit into the mortise structure (grooves) made on the glenoid (Fig 4B). After confirmation of the fitting of the mortise-tenon structures (Fig 4C), the two TigerWire thread loops were pulled posteriorly, as much as possible, to keep the iliac bone graft tightly onto the glenoid. Meanwhile, the two Mini-TightRopes are tightened anteriorly (Fig 5, A and E). Then the TigerWire thread loops are pulled anteriorly and reopened. At least five tight knots for each TigerWire thread are tied to fix the iliac bone graft (Fig 5, B and F). Finally, each Mini-TightRope is fixed with at least five knots to give a double fixation (Fig 5, C and G) (see Video 1).

Bankart Repair

The stability of the construct is checked with a probe. The remaining capsule and labrum is then reattached to the glenoid rim, and the graft is placed in an extra-articular position. This procedure should not be skipped, owing to the importance of the capsuloligamentous complex in the recurrent shoulder dislocation.¹⁸ Two sockets are drilled onto the surface close to the anterior edge, usually at the 5- and 2-o'clock positions for the 2.9-mm PushLocks (Arthrex, Naples, FL). The remaining threads on the two

Mini-TightRopes (two strands for each) are passed through the labrum and capsule to the joint and then tightened. Each PushLocks took one strand from each Mini-TightRope for fixation. These two PushLocks provide extra fixation of the iliac bone graft by pushing the graft toward the glenoid rim (Fig 5, D and H) (see Video 1).

Rehabilitation Protocol

The rehabilitation protocol was basically the same as a previous study.¹⁵ A brace/sling was maintained for 4 to 6 weeks postoperatively. No resisted elbow flexion or shoulder external rotation was allowed for at least 3 months, to reduce the risk of bone absorption. No active strengthening was allowed until the surgeon judged it appropriate and radiographic healing of the coracoid graft was visualized during follow-up. Return to contact sports, throwing, or heavy labor activities were generally not allowed until 6 months after surgery.

The pearls and pitfalls of this technique are shown in Table 1.

Discussion

Boileau et al. first¹¹ reported a Latarjet procedure with suture button fixation. Midterm results showed that suture button fixation is a reliable alternative to the Latarjet procedure, avoiding hardware-related complications.¹² And then Boileau et al. applied this fixation method in the Eden-Hybinette procedure for the revision of failed Bristow-Latarjet.⁵ Although several studies have shown the advantages of using suture button fixation in the Bristow-Latarjet or Eden-Hybinette procedure,^{13-15,19,20} there are also studies showing that it might have a higher redislocation rate compared to screw fixation.²¹ The main concern about

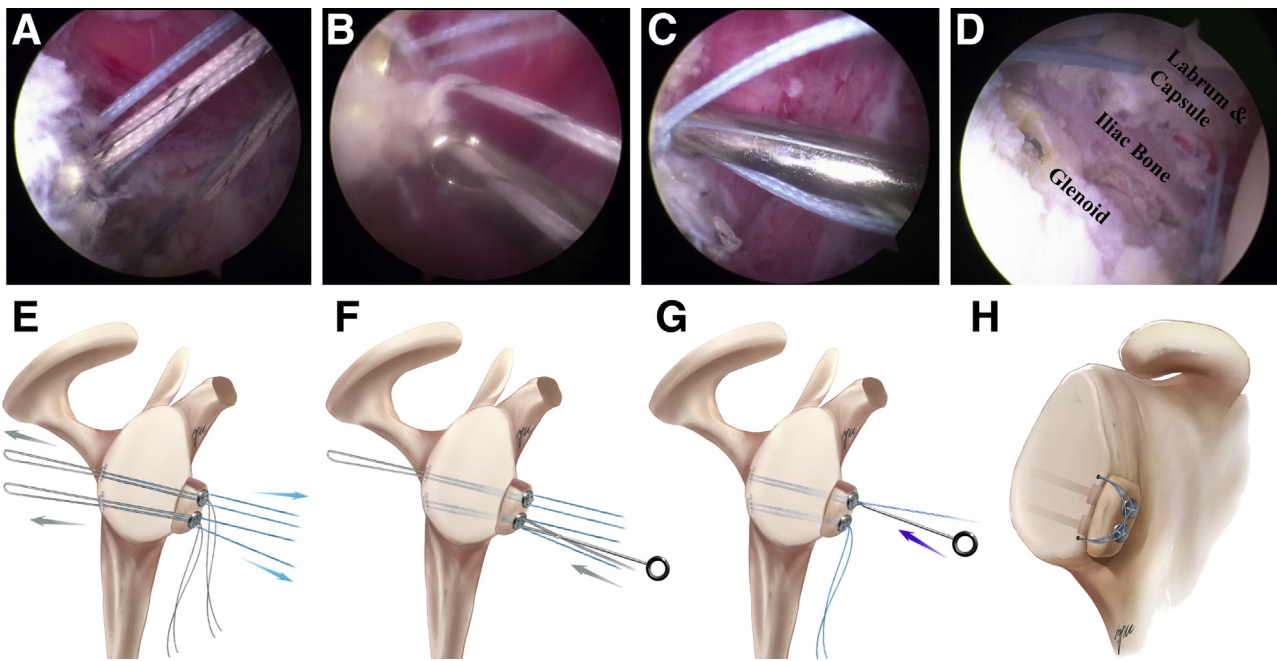


Fig 5. Iliac bone graft fixation and Bankart repair. (Right shoulder, view from superolateral portal, which is located about 1 cm anterolaterally to the anterolateral corner of the acromion; and the working portal uses the inferolateral portal). (A) The two TigerWire thread loops were pulled posterior as much as possible to keep the iliac bone graft tightly onto the glenoid. Meanwhile, the two Mini-TightRopes are tightened anteriorly. (B) The TigerWire thread loops are pulled anteriorly and reopened. At least 5 tight knots for each TigerWire thread are tied to fix the iliac bone graft. (C) Each Mini-TightRope is fixed with at least 5 knots to give a double fixation. (D) The remaining threads on the two Mini-TightRopes (2 strands for each) are passed through the labrum and capsule to the joint and then tightened. Bankart repair is then completed with two 2.9-mm PushLocks at the 5- and 2-o'clock positions of the anterior glenoid. (E-H) The illustration of A-D.

suture button fixation is its inferior biomechanical strength.^{17,22,23} Reeves et al.¹⁷ conducted a cadaveric biomechanics study on the two different fixation methods. The results showed that the screws were significantly more stable than the buttons at 20 N of conjoint tendon loading. Williams et al.²³ reported in their cadaveric study that cortical button fixation did not resist direct loads to the graft as much as traditional

screw fixation. Several techniques have been introduced to improve the fixation strength of suture button fixation, such as using a tensioner for knotting during fixation,^{11,12} adding an extra antirotation thread for the reinforcement or using double-suture buttons for the fixation.²⁴ Following a previous study about a modified Bristow procedure with suture button fixation, a "Mortise-Tenon" structure was created to increase the

Table 1. Pearls and Pitfalls

Pearls	Pitfalls
The tricortical iliac bone graft should be harvested no less than 25 mm long, in order to have enough space for the tenon structure later.	If the length of the iliac bone graft is less than 25 mm, it will not be able to get the "mortise-tenon" structure mentioned in this technique.
The position of the first hole on the glenoid should be adjusted according to the size of harvested iliac bone graft by using the positioner, in order to obtain the best position of the graft.	Do not trust your eyes too much. Using the positioner to get the right position. Malposition of the graft may cause several critical problems.
The Orthocord thread preseated in the glenoid should be in the same color as the one preseated on the Mini-TightRope, to facilitate pulling the iliac bone graft onto the glenoid in a right gesture.	If the threads are not in a good position, are twining together, or are misidentified, it will be very difficult to resolve under the arthroscopy.
Always confirm the fit of the "mortise-tenon" structure before tightening the Mini-TightRopes.	If the iliac bone graft is not inlaid right into the grooves on the glenoid, the final fixation of the graft will be unstable, very easy to get loose.
When knotting on the TigerWire thread, the Mini-TightRopes should be persistently tightening, to obtain a firm fixation of the bone graft.	The Mini-TightRope needs a knotting procedure to get a final fixation. It is hard to keep the Mini-TightRope in the most fastened status during the knotting procedure. The TigerWire helps guarantee and reinforce the fixation.

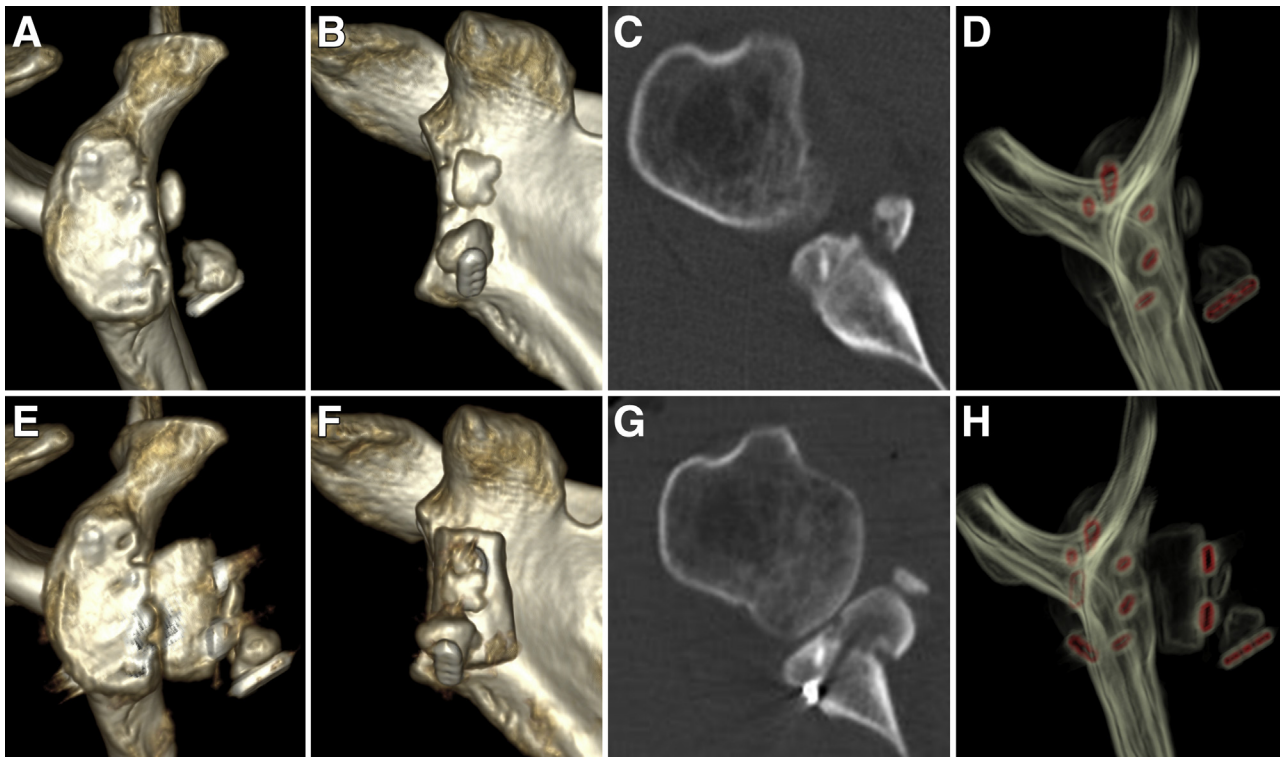


Fig 6. CT scan preoperation and postoperation. (Right shoulder) Pre-operation: en-face view of three-dimensional (3D) computed tomography (CT) (A), anterior view of 3D CT (B), axial view of 2D CT (C), and hardware-enhanced CT view (D). Post-operation: En-face view of 3D CT (E), anterior view of 3D CT (F), axial view of 2D CT (G), and hardware enhanced CT view (H). (A case of failed arthroscopic Latarjet with suture button fixation, revision by arthroscopic “double-inlay” Eden-Hybinette with modified suture button fixation; D and H: red parts show the metal implants).

biomechanical strength.¹⁵ In the present study, we introduced an arthroscopic “double-inlay” Eden-Hybinette procedure with modified suture button fixation for the revision of failed Bristow-Latarjet. We propose that it has a “quadruple” reinforcement effect: 1) “double-inlay” skeletal stabilized structure (dual “Mortise-Tenon” structure), 2) two TigerWire threads fixation, 3) two Mini-TightRopes fixation, and 4) two PushLock anchor fixation. Furthermore, with the positioning system shown in this technique, the bone block can be always placed in a good position (Fig 6). Using suture button fixation can also avoid secondary

harm caused by dealing with the hardware implant (Table 2).

As a salvage surgical procedure for failed Bristow-Latarjet, it should be highly reliable because if it fails again, it may cause catastrophic consequences. And with the “quadruple” reinforcement effect, this arthroscopic “double-inlay” Eden-Hybinette procedure with modified suture button fixation is qualified to be a reliable salvage surgical procedure for failed Bristow-Latarjet. Some of the advantages of this technique, such as the biomechanical superiority, need further investigation.

Table 2. Advantages and Limitations of the Technique

Advantages	Limitations
<p>This technique has “quadruple” reinforcement effect: 1) “double-inlay” skeletal stabilized structure (dual “Mortise-Tenon” structure); 2) two TigerWire threads fixation; 3) two Mini-TightRopes fixation; and 4) two PushLock anchors fixation, to guarantee an excellent fixation of the graft.</p> <p>With the positioning system shown in this technique, the bone block can be always placed in a good position.</p> <p>Using suture button fixation can avoid the second harm caused by dealing with the hardware implant.</p>	<p>Special instruments are needed in this technique, which are still not available in the market. But in the near future, the instruments will be off-the-shelf products.</p> <p>As a salvage surgical procedure for the revision of failed Bristow-Latarjet procedure, the learning curve is relatively long.</p>

References

- Bhatia S, Frank RM, Ghodadra NS, et al. The outcomes and surgical techniques of the Latarjet procedure. *Arthroscopy* 2014;30:227-235.
- Griesser MJ, Harris JD, McCoy BW, et al. Complications and re-operations after Bristow-Latarjet shoulder stabilization: A systematic review. *J Shoulder Elbow Surg* 2013;22:286-292.
- van der Linde JA, van Kampen DA, Terwee CB, et al. Long-term results after arthroscopic shoulder stabilization using suture anchors: an 8- to 10-year follow-up. *Am J Sports Med* 2011;39:2396-2403.
- Villatte G, Spurr S, Broden C, Martins A, Emery R, Reilly P. The Eden-Hybinette procedure is one hundred years old! A historical view of the concept and its evolutions. *Int Orthop* 2018;42:2491-2495.
- Boileau P, Duysens C, Saliken D, Lemmex DB, Bonneville N. All-arthroscopic, guided Eden-Hybinette procedure using suture-button fixation for revision of failed Latarjet. *J Shoulder Elbow Surg* 2019;28:e377-e388.
- Giannakos A, Veziridis PS, Schwartz DG, Jany R, Lafosse L. All-arthroscopic revision Eden-Hybinette procedure for failed instability surgery: Technique and preliminary results. *Arthroscopy* 2017;33:39-48.
- Khan U, Torrance E, Hussain M, Funk L. Failed Latarjet surgery: Why, how, and what next? *JSES Int* 2020;4:68-71.
- Flurin PH, Antoni M, Metais P, Aswad R, SoFec. Revision of failed Latarjet with the Eden-Hybinette surgical technique. *Orthop Traumatol Surg Res* 2020;106:223-227.
- Dimitriou R, Mataliotakis GI, Angoules AG, Kanakaris NK, Giannoudis PV. Complications following autologous bone graft harvesting from the iliac crest and using the RIA: A systematic review. *Injury* 2011;42:S3-S15 (Suppl 2).
- Tytherleigh-Strong GM, Morrissey DI. Failed Latarjet procedure treated with a revision bone block stabilization using a suture-button fixation. *J Shoulder Elbow Surg* 2017;26:e102-e107.
- Boileau P, Gendre P, Baba M, et al. A guided surgical approach and novel fixation method for arthroscopic Latarjet. *J Shoulder Elbow Surg* 2016;25:78-89.
- Boileau P, Saliken D, Gendre P, et al. Arthroscopic Latarjet: Suture-button fixation is a safe and reliable alternative to screw fixation. *Arthroscopy* 2019;35:1050-1061.
- Avramidis G, Kokkineli S, Trellopoulos A, et al. Excellent clinical and radiological midterm outcomes for the management of recurrent anterior shoulder instability by all-arthroscopic modified Eden-Hybinette procedure using iliac crest autograft and double-pair button fixation system: 3-year clinical case series with no loss to follow-up. *Arthroscopy* 2021;37:795-803.
- Xu J, Liu H, Lu W, et al. Modified arthroscopic Latarjet procedure: Suture-button fixation achieves excellent remodeling at 3-year follow-up. *Am J Sports Med* 2020;48:39-47.
- Shao Z, Song Q, Cheng X, et al. An arthroscopic "inlay" Bristow procedure with suture button fixation for the treatment of recurrent anterior glenohumeral instability: 3-Year follow-up. *Am J Sports Med* 2020;48:2638-2649.
- Bonneville N, Girard M, Dalmas Y, Martinel V, Faruch M, Mansat P. Short-term bone fusion with arthroscopic double-button Latarjet versus open-screw Latarjet. *Am J Sports Med* 2021;49:1596-1603.
- Reeves JM, Athwal GS, Johnson JA. Double-screw and quadruple-button fixation for the glenoid: Latarjet versus bone block applications. *JSES Int* 2020;4:780-785.
- Lavoue V, Gendre P, Saliken D, Brassac A, Boileau P. The role of arthroscopic soft tissue reconstruction for failed Bristow-Latarjet procedure. *Arthroscopy* 2019;35:2581-2588.
- John R, Coady CM, Wong I. Arthroscopic revision with autologous iliac crest bone graft for failed anatomic glenoid reconstruction using distal tibia allograft. *Arthrosc Tech* 2019;8:e1333-e1338.
- Milenin O, Sergienko R, Badtieva V. The combined arthroscopic revision technique after the Latarjet procedure. *Arthrosc Tech* 2019;8:e917-e921.
- Hardy A, Sabatier V, Schoch B, Vigan M, Werthel JD, Study I. Latarjet with cortical button fixation is associated with an increase of the risk of recurrent dislocation compared to screw fixation. *Knee Surg Sports Traumatol Arthrosc* 2020;28:2354-2360.
- Provencher MT, Aman ZS, LaPrade CM, et al. Biomechanical comparison of screw fixation versus a cortical button and self-tensioning suture for the Latarjet procedure. *Orthop J Sports Med* 2018;6:2325967118777842.
- Williams RC, Morris RP, El Beaino M, Maassen NH. Cortical suture button fixation vs. bicortical screw fixation in the Latarjet procedure: A biomechanical comparison. *J Shoulder Elbow Surg* 2020;29:1470-1478.
- Valenti P, Maroun C, Wagner E, Werthel JD. Arthroscopic Latarjet procedure combined with Bankart repair: A technique using 2 cortical buttons and specific glenoid and coracoid guides. *Arthrosc Tech* 2018;7:e313-e320.