

Left-Sided Amyand Hernia: Report of Two Cases with Review of Literature

Ali Farooq Al-Mayoof¹ Bilal Hamid Al-Ani¹

¹Department of Paediatric Surgery, Al-Mustansyriah Medical College/ Central Teaching Hospital of Pediatrics, Baghdad, Iraq

Eur J Pediatr Surg Rep 2014;2:63–66.

Address for correspondence Ali Farooq Al-Mayoof, FICMS (Ped Surg), Department of Paediatric Surgery, Al-Mustansyriah Medical College/ Central Teaching Hospital of Pediatrics, Baghdad, Iraq (e-mail: afm19742002@yahoo.com).

Abstract

Keywords

- ▶ Amyand hernia
- ▶ appendectomy
- ▶ herniotomy
- ▶ incidental appendectomy
- ▶ acute appendicitis

The presence of the vermiform appendix in an inguinal hernial sac is called “Amyand” Hernia, which is a rare condition especially in children. The authors are reporting two cases of left-sided Amyand hernia in infants presented with symptoms and signs of obstructed inguinal hernia. Emergency appendectomy and herniotomy were performed. The patients were followed up for 4 to 6 months without complications. The case histories are presented, and the conditions discussed with review of the literature.

Introduction

Amyand hernia (AH) refers to the presence of the vermiform appendix (VA) in the inguinal hernia (IH) sac and is named so as a homage to Claudius Amyand (1681 to 1740)—a sergeant surgeon to King George, who performed the first successful appendectomy in an 11-year-old boy with a perforated appendix in the right IH sac in 1735.¹

Most cases occur on the right side. This is attributed to the normal right side position of the VA in the peritoneal cavity. The finding of the VA in a left-sided IH sac (left-sided AH) is a rare occurrence, and it had been attributed to a mobile cecum, situs inversus, or malrotation.²

Patients with AH usually present with symptoms and signs of complicated IH,^{3,4} that is why it is usually diagnosed intraoperatively.^{5,6} Apart from hernial repair, if the VA is grossly not inflamed, debate continues in the surgical literature regarding the advisability of, or otherwise, incidental appendectomy in the course of the surgical procedure.^{1,7}

In this article, the rare occurrence of AH on the left side in two infants is reported, along with review of the literature about this condition.

Case 1

A 4-month-old infant had been presented with history of excessive crying and frequent attacks of vomiting for the last 2 days.

On examination, the child was found to have an inguinoscrotal swelling which was red, tender, and irreducible. The child had no fever or abdominal distension but was mildly dehydrated. A diagnosis of obstructed IH was made.

Preoperative resuscitation with intravenous fluid and antibiotics were initiated. Exploration revealed an edematous cecum with little adhesions to the hernial sac and a grossly normal VA lying within. After release of adhesions, a trans-hernial appendectomy performed along with reduction of the cecum into the peritoneal cavity followed by herniotomy with high ligation of the sac. A postoperative radiological examination documented a situs inversus with dextrocardia. The histopathological examination revealed an inflamed VA. The patient was discharged and followed up for 6 months without any complications.

received
March 22, 2013
accepted after revision
April 16, 2013
published online
May 9, 2013

DOI <http://dx.doi.org/10.1055/s-0033-1347131>.
ISSN 2194-7619.

© 2014 Georg Thieme Verlag KG
Stuttgart · New York

License terms



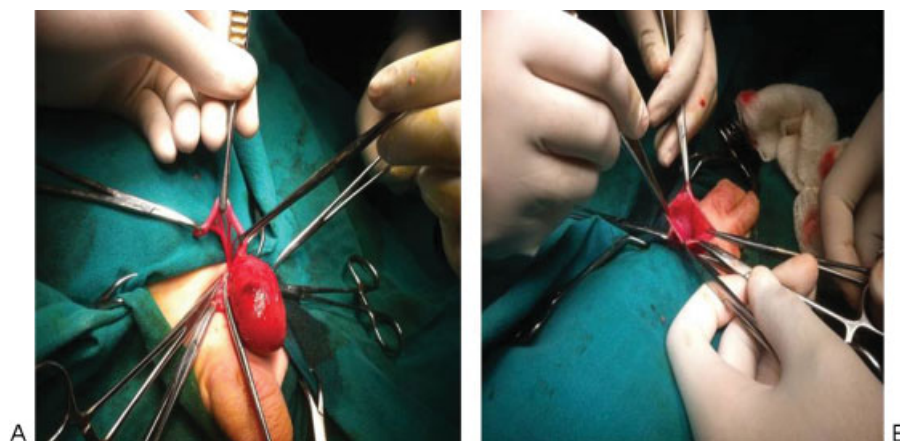


Fig. 1 (A) The edematous cecum with normal appendix in the left hernial sac. (B) After appendectomy and reduction of the cecum through the hernial sac.

Case 2

A 10-month-old infant presented to the ER department with the complaints of excessive crying and frequent attacks of bilious vomiting for the last 36 hours. On examination, there was a red tender hot lump in the left inguinal region with slight erythema of the overlying and surrounding skin. The child was febrile (38°C). An abdominal X-ray documented the clinical suspicion of obstructed IH. After administration of intravenous fluid and antibiotics, exploration was performed. The hernial sac was containing the edematous cecum and a grossly normal VA (→Fig. 1A, B). A trans-hernial appendectomy performed followed by herniotomy with high ligation of the sac. The pathological examination revealed a normal VA. The patient was followed up for 4 months without complications. Because postoperative radiological studies did not prove the presence of malrotation and situs inversus, an excessively mobile cecum was presumed as a possible cause for this finding.

Discussion

AH in pediatric age-group is extremely rare, especially in infants and neonates.⁸ This article is reporting two cases of AH occurring on the left side. In the literature reviewed, the commonest side for AH being reported was the right. However, there were only few reports of the occurrence of AH on the left side. Although a comprehensive review of the literature was conducted, further information was limited by the lack of accomplishment in many reports. Some articles omitted the site, age, sex, management, and pathological condition of the VA (→Table 1).

Most cases occur on the right side. When it occurs on the left side, it had been reported to be caused by situs inversus, intestinal malrotation, or a mobile cecum.² In this article, one of the cases was documented to have situs inversus and dextrocardia, whereas the other case was considered to be caused by a mobile cecum, as malrotation or situs inversus could not be radiologically proved.

The incidence of a grossly noninflamed VA in adult AH is 1%, whereas the incidence of acute appendicitis (AA) is very rare and estimated to be 0.08 to 0.1%.⁹ In infants and children, the incidence was higher (0.42 and 16.6%, respectively).²

Different presentations had been reported in the literature. Majority were with signs of incarcerated, obstructed, or strangulated IH with or without signs and symptoms of AA.^{3,4} However, some cases may present incidentally during an operation for IH, others may present with a scrotal abscess, testicular ischemia, or acute scrotum.^{10–12}

Most cases, be it right or left AH, were diagnosed intraoperatively.^{5,6} In some reported cases, preoperative diagnosis was made by ultrasound or CT scanning.^{13,14} In our cases, the diagnosis was established intraoperatively because the use of ultrasound and/or CT scan is not our routine practice in complicated IH.

The treatment of AH mainly depends on the status of the VA, whether normal, inflamed, or perforated.^{7,15} In cases of inflamed or perforated VA, besides herniotomy, appendectomy was performed, either through the hernial sac or by a separate lower abdominal incision.^{8,9} However, laparoscopic repair of AH had also been reported.¹⁴

In cases of a grossly normal VA, appendectomy may be controversial. Debate continues in the surgical literature about the advisability or otherwise of “incidental” appendectomy during abdominal operations.¹ Although guidelines have been promulgated, the issue is far from being resolved.

Generally, the advocates of “incidental” appendectomy consider decreased future morbidity, mortality, and cost of surgery, with no increase in anesthetic risk, wound infection, or operative time, as reliable justifications.^{1,7} These points had been considered sufficient to justify incidental appendectomy.

Those who oppose suggest that violation of aseptic surgical technique by transection of a fecal-containing organ in an otherwise clean operation may increase morbidity and mortality from septic complications.¹ In addition, it has been proved that the VA plays a role in the immune system of the body especially in children. Furthermore, in the last

Table 1 Summary of published articles 1998–2013

Author	Year	No. of cases	Age	Side	Diagnosis	Treatment
Ryoji et al ¹¹	1998	1	10 d	Lt IH	IO	App (scrotal abscess)
Shyam et al ¹⁰	2004	1	6 y	Rt IH	IO	H + App
S. Gupta et al ⁶	2005	1	9 mo	Lt IH	IO	H
Milburn et al ¹²	2005	1	10 d	Rt IH	IO	H + App
Gurer et al ¹⁸	2005	1	5 mo	Rt IH	IO	H
Sharma et al ¹⁹	2006	1	12 y	Rt IH	IO	NR
N. Gupta et al ³	2007	1	11 mo	Lt IH	IO	H + App (inflamed)
Livaditi et al ⁸	2007	2	32, 35 d	Rt IH	IO	H + App (inflamed and sloughed)
Sunil S Bhide ⁹	2008	1	2 y	Rt IH	IO	H + App
Kaymakci et al ²	2009	30 (2F)	19 d to 8 y	27 Rt IH /3 Lt IH	IO	H ± App
Upadhyaya et al ¹⁵	2009	1	7 mo	Rt IH	IO	H + App
Alessandro et al ¹³	2009	1	4 y	Rt IH	Pre-op	H + App
Park et al ¹⁴	2010	1	33 d	IH	Pre-op	Lap H + App
Sadik et al ²⁰	2010	1	6 y	Rt IH	IO	H + App (perforated by a pin)
Sulu et al ²¹	2010	4	2, 3, 6, 14 y	Rt IH	IO	H ± App
Cankorkmaz et al ²²	2010	12	15 d to 14 mo	Rt IH	(1) Pre-op	H ± App
Ngom et al ⁴	2010	1	14 d	Rt IH	IO	H + App (perforated)
Kulwant et al ⁵	2011	2	1.5 y	Lt IH	IO	H
Oneil et al ²³	2011	1	4 y	Rt IH	IO	H + App (normal)
Khan et al ²⁴	2011	1	1 y	Rt IH	IO	H + App
Claudia et al ²⁵	2013	1	6 wk	Rt IH	IO	H + App
Present article	2013	2	3, 10 mo	Lt IH	IO	H + App

Abbreviations: App, appendectomy; d, day; F, female; H, herniotomy; IH, inguinal hernia; IO, intraoperative; Lap, laparoscopic; Lt, left; mo, months; Rt, right; NR, not recorded, pre-op, preoperative; y, years; wk, week.

decades, the appendix has been used in many pediatric surgical procedures.⁷

In our cases, in addition to herniotomy, we decided to perform appendectomy, whether the VA was grossly normal or inflamed because we adopt the opinion that an abnormal position of the VA necessitates its removal because of a possible future abnormal presentation.¹⁶ In addition, some studies postulated that trauma to the appendix caused by being within the IH sac or because of manipulation could provoke AA thereafter,¹¹ where Ofili reported two patients who developed AA after repair of their AH.¹⁷ He contrasted this result with another 11 patients with AH in whom appendectomy was performed at the time of herniotomy. He did not report any wound infection or hernia recurrences. "Incidental" appendectomy was therefore advocated.

Conclusions

Left-sided AH is a rare condition particularly in infants and usually presents with signs and symptoms of obstructed IH; therefore, it should be considered in the differential diagnosis.

If AH is discovered incidentally during left-sided herniotomy, "incidental" appendectomy is strongly recommended not only because of the possibility of postoperative AA provoked by trauma during hernial obstruction or by intraoperative manipulation, but also to avoid hazards of abnormal presentation in the future.

Conflict of Interest

None

References

- Hutchinson R. Amyand's hernia. *J R Soc Med* 1993;86(2):104–105
- Kaymakci A, Akillioglu I, Akkoyun I, Guven S, Ozdemir A, Gulen S. Amyand's hernia: a series of 30 cases in children. *Hernia* 2009;13(6):609–612
- Gupta N, Vinay Wilkinson TR, Wilkinson A, Akhtar M. Left-sided incarcerated Amyand's hernia. *Indian J Surg* 2007;69:17–18
- Ngom G, Amadou I, Ibrahima KA, Mubake A, Ndour O, Ndoeye M. Amyand's hernia with perforated appendix in a neonate. *BMJ Case Rep* 2010;2010:bcr0320102847

- 5 Singh K, Singh RR, Kaur S. Amyand's hernia. *J Indian Assoc Pediatr Surg* 2011;16(4):171-172
- 6 Gupta S, Sharma R, Kaushik R. Left-sided Amyand's hernia. *Singapore Med J* 2005;46(8):424-425
- 7 Kamil M. Incidental appendisectomy; how far is it justifiable. *Al-Kindy Col Med J* 2004;2(1):22-25
- 8 Livaditi E, Mavridis G, Christopoulos-Geroulanos G. Amyand's hernia in premature neonates: report of two cases. *Hernia* 2007;11(6):547-549
- 9 Bhide SS. Amyand's hernia. *Indian J Pediatr* 2009;76(8):854-855
- 10 Sharma SB, Gupta V. Acute appendicitis presenting as acute hemiscrotum in a boy. *Indian J Gastroenterol* 2004;23(4):150
- 11 Yasumoto R, Kawano M, Kawanishi H, et al. Left acute scrotum associated with appendicitis. *Int J Urol* 1998;5(1):108-110
- 12 Milburn JA, Youngson GG. Amyand's hernia presenting as neonatal testicular ischaemia. *Pediatr Surg Int* 2006;22(4):390-392
- 13 Giannattasio A, Campus R, Muraca M, et al. Amyand's hernia in a child with permanent neonatal diabetes due to pancreatic agenesis. *Pediatr Rep* 2009;1(1):e6
- 14 Park J, Hemani M, Milla SS, Rivera R, Nadler E, Alukal JP. Incarcerated Amyand's hernia in a premature infant associated with circumcision: a case report and literature review. *Hernia* 2010;14(6):639-642
- 15 Upadhyaya VD, Kumar V, Srivastava P, Gangopadhyaya AN. Amyand's hernia in infant: a rare entity. *Kathmandu Univ Med J (KUMJ)* 2009;7(26):143-144 (KUMJ)
- 16 Bakhshi GD, Bhandarwar AH, Govila AA. Acute appendicitis in left scrotum. *Indian J Gastroenterol* 2004;23(5):195
- 17 Ofili OP. Simultaneous appendectomy and inguinal herniorrhaphy could be beneficial. *Ethiop Med J* 1991;29(1):37-38
- 18 Gurer A, Ozdogan M, Ozlem N, Yildirim A, Kulacoglu H, Aydin R. Uncommon content in groin hernia sac. *Hernia* 2006;10(2):152-155
- 19 Sharma H, Gupta A, Shekhawat NS, Memon B, Memon MA. Amyand's hernia: a report of 18 consecutive patients over a 15-year period. *Hernia* 2007;11(1):31-35
- 20 Llullaku SS, Hyseni NSh, Kelmendi BZ, Jashari HJ, Hasani AS. A pin in appendix within Amyand's hernia in a six-years-old boy: case report and review of literature. *World J Emerg Surg* 2010;5:14
- 21 Sulu B, İşler S. [Using the properties of Amyand's hernia in children in the preoperative diagnosis: our experience and review of the literature]. *Ulus Travma Acil Cerrahi Derg* 2010;16(3):253-259
- 22 Cankorkmaz L, Ozer H, Guney C, Atalar MH, Arslan MS, Koyluoglu G. Amyand's hernia in the children: a single center experience. *Surgery* 2010;147(1):140-143
- 23 Machado NO, Machado NN. Unusual contents of inguinal hernial sac. An approach to management. *Surgical Science* 2011;2:322-325
- 24 Khan TS, Wani ML, Bijli AH, et al. Amyand's hernia: a rare occurrence. *Ann Nigerian Med* 2011;5:62-64
- 25 Piedade C, Alves JR. Amyand's hernia in a 6-week-old infant: a delayed diagnosis. *Case Reports Pediatrics* 2013;2013:3 (doi:10.1155/2013/758171)