

Original Article

Comparison of bone regeneration using three demineralized freeze-dried bone allografts: A histological and histomorphometric study in rabbit calvaria

Parichehr Behfarnia¹, Mohammad Shahabooei², Fatemeh Mashhadiabbas³, Elham Fakhari¹

¹Torabinejad Dental Research Center and Department of Periodontics, ²Dental Implant Research Center and Department of Periodontics, School of Dentistry, Isfahan University of Medical Sciences, Isfahan, ³Department of Oral and Maxillofacial Pathology, School of Dentistry, Shahid Beheshti University of Medical Sciences, Tehran, Iran

ABSTRACT

Background: It has been stated that the bone allografts from different tissue banks may lead to various amount of bone induction, so the aim of this study was to evaluate bone regeneration of three demineralized allografts both histologically and histomorphometrically in rabbits calvaria bone defects.

Materials and Methods: In this double-blind randomized experimental animal study, 32 critical size defects (11-mm diameter) in the calvaria of 16 male New Zealand white rabbits were randomly filled with three demineralized freeze-dried bone allografts (DBM, CENOBONE, DEMBONE), while the nongrafted defect was regarded as control group. After 6 and 12 weeks of healing, the experimental animals were euthanized for specimen preparation. After histological evaluation, histomorphometric analysis was performed to quantify new bone formation and remained graft particles. The data were analyzed by one-way ANOVA with Tukey's ad-hoc test and *t*-test. ($P < 0.05$ was considered to be statistically significant).

Results: Mean percentage of bone formation increased between two healing time, but it was not statistically significant in all groups except DBM which the bone formation significantly decreased ($P = 0.04$). There were not statistically significant differences between three allografts in remained particles and bone formation in both healing times and they could not induce significantly more bone formation than control group.

Conclusion: Both test and control groups resulted in successful new bone formation. No difference was noted in bone formation and remained particles between three commercial bone allografts. Further studies in this issue may be needed.

Key Words: Bone regeneration, demineralized freeze-dried bone allografts, osteoinduction, tissue bank

Received: May 2012
Accepted: July 2012

Address for correspondence:
Dr. Elham Fakhari,
Torabinejad Dental Research
Center and Department
of Periodontics, School of
Dentistry, Isfahan University
Of Medical Science, Isfahan,
Iran.
E-mail: fakhari_85@yahoo.
com

INTRODUCTION

Lack of adequate bone is a common complication in periodontally compromised teeth and implant

dentistry.^[1] Autogenous bone is still the gold standard in bone augmentation procedures but its low availability and donor site morbidity necessitates the development of alternative products for it.^[2,3] Many bone substitutes are introduced every day such as allografts, xenografts and synthetically produced ones.^[4] One of the commonly used substitute is allogenic bone graft.^[5] The use of demineralized freeze-dried bone allograft (DFDBA), whether alone or in combination with other bone substitute, showed significant improvements in bone augmentation procedures.^[6]

Access this article online



Website: www.drj.ir

All the bone allografts are osteoconductive, but DFDBA also provide an osteoinductive effect. In fact the presence of bone morphogenic proteins (BMP) in DFDBA facilitates new bone formation by allowing undifferentiated mesenchymal progenitor cells undergo phenotypic conversion to the osteoblasts.^[7,8]

The main advantage of allografts is that they eliminate the need for a donor site Besides it can be used in large quantities if necessary.^[7] But there is a controversy about the effectiveness of bone allografts in bone regeneration between studies. Becker *et al.*^[9] did not find that DFDBA was beneficial for periodontal regeneration, while in the other study the use of DFDBA improve the repair of periodontal lesions.^[10]

There are different batches of allografts commercially available, but they might be different in bone inductive activity (BMP concentration), depends on biological properties of the graft, criteria for selecting donors and methods of allograft processing.^[11] Schwartz and colleagues stated that so many differences exist in bone bank preparations of DFDBA and they can induce bone formation variously.^[12] However, the dental practitioners need to select the most efficient and cost effective ones for the routine dental practice.

In fact the most effective products are those that maintain the porous structure and anatomy of mineralized bone with scrutinized sterilization that adhere to American Association of Tissue Banks (AATB) guidelines.

The aim of this study was to evaluate the ability of three different commercial DFDBA to induce new bone formation in rabbit's calvaria.

MATERIALS AND METHODS

Sixteen New Zealand white male rabbits weighing 2.0-3.0 kg were selected for this study (they were mature skeletally). The rabbits were allowed to acclimatize 14 days before the experimental study. The animals were housed in separate cages under standard laboratory conditions and fed with a standard diet. Animal selection, management, surgical protocol, and preparation were approved by the Institutional Animal Care and Use Committee, Torabinejad Dental Research Center, School of Dentistry, Isfahan University of Medical Sciences, Isfahan, Iran.

Surgical procedure

The animals were anesthetized by intramuscular injection of 50 mg/kg of ketamine hydrochloride

(Ketamine, Alfasan, Woerden, Holland) and 1 mg/kg of Acepromazine (NEUROTRANQ, Alfasan, Woerden, Holland). The surgical sites shaved and then disinfected with alcohol and povidone iodine, followed by local anesthesia with 2% lidocaine HCl with epinephrine (dilution 1:100,000), (Persocaine-E, Darou pakhsh pharmaceutical Mfg.Co, Tehran, Iran). An incision was made along the midsagittal suture from the frontal bone to the occipital bone. A full-thickness flap was elevated to expose the calvaria. One standardized circular and bicortical defect with 11 mm diameter was created using trephine bur under constant cool-saline irrigation on each side of midsagittal suture [Figure 1]. Thirty-two critical size defects were randomly filled with three DFDBA:

DFDBA 1(DBM, Iranian Tissue Bank Research and Preparation Center, Tehran, Iran) particle size: 420-840 μm , DFDBA 2 (CenoBone, Tissue Regeneration Corporation, Kish, Iran) particle size: 500-1000 μm and DFDBA 3(DEMBONE, Pacific Coast Tissue Bank, Los Angeles, USA) particle size: 250-850 μm . In control group, the defects were filled with no bone material. Eight samples were analyzed for each group and four for each healing period. The size of bone particles was nearly similar in three allografts.

The flaps were repositioned and then sutured layer by layer. Periosteum was sutured with a resorbable suture material (4-0 Polyglycolate, HUR-TEB medical devices, ghazvin, Iran) and skin with (silk 3-0 SUPASIL, Supa medical devices, Tehran, Iran).

Postoperative cares included the intramuscular administration of antibiotic Ceftriaxone 5 mg/kg (Ceftrax, Jaberebne Haiian pharmaceutical Mfg Co, Tehran, Iran) and the careful clinical observation of the animals throughout the healing period. Skin sutures were removed 10 days after surgery. The animals were sacrificed 6 and 12 weeks postoperatively using intracardial injection of magnesium sulfate under deep anesthesia.

Specimen preparation

The area of the surgical defects and surrounding tissues were removed *en bloc* after sacrifice. The sections were fixed in 10% buffered formalin solution. The sections were decalcified in 10% formic acid solution for 20 days then dehydrated with graded alcohols and embedded in paraffin. Serial sections (4 μm) were cut from the center of the defects. The most-central sections (the greatest diameter

of the circle) from each block were stained with hematoxylin and eosin (H & E) and examined using light microscopy (Nicon, E400, JAPAN) [Figure 2].

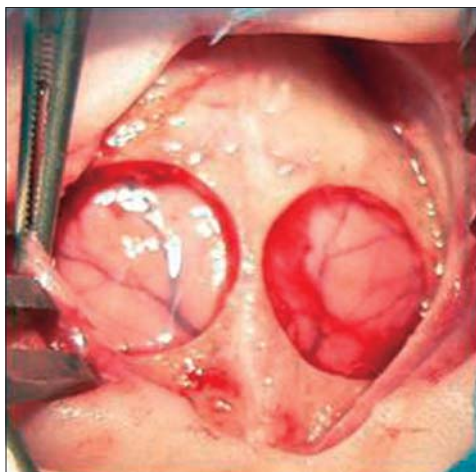


Figure 1: Photograph of two standardized circular defects created with diameter of 11 mm

Histological and histomorphometric analysis

The central sections were chosen for histomorphometric analysis. Photographs were taken with light microscope. Computer-assisted histomorphometric measurements of the newly formed bone were obtained using an automated image analysis software. (IHMMA, Ver. 1, Sbm. Iran). The new bone formation values, which were the percentile ratio of newly formed bone area over the total defect area, remained particles, percentage and type of inflammation, type of bone and connective tissue, were assessed by a blinded pathologist.

Statistical analysis

Statistical analysis was performed using SPSS 11.5 software (SPSS Inc., Chicago, USA). Significant differences among groups were identified by one-way ANOVA with Tukey's ad-hoc test and significant differences among two healing times were determined

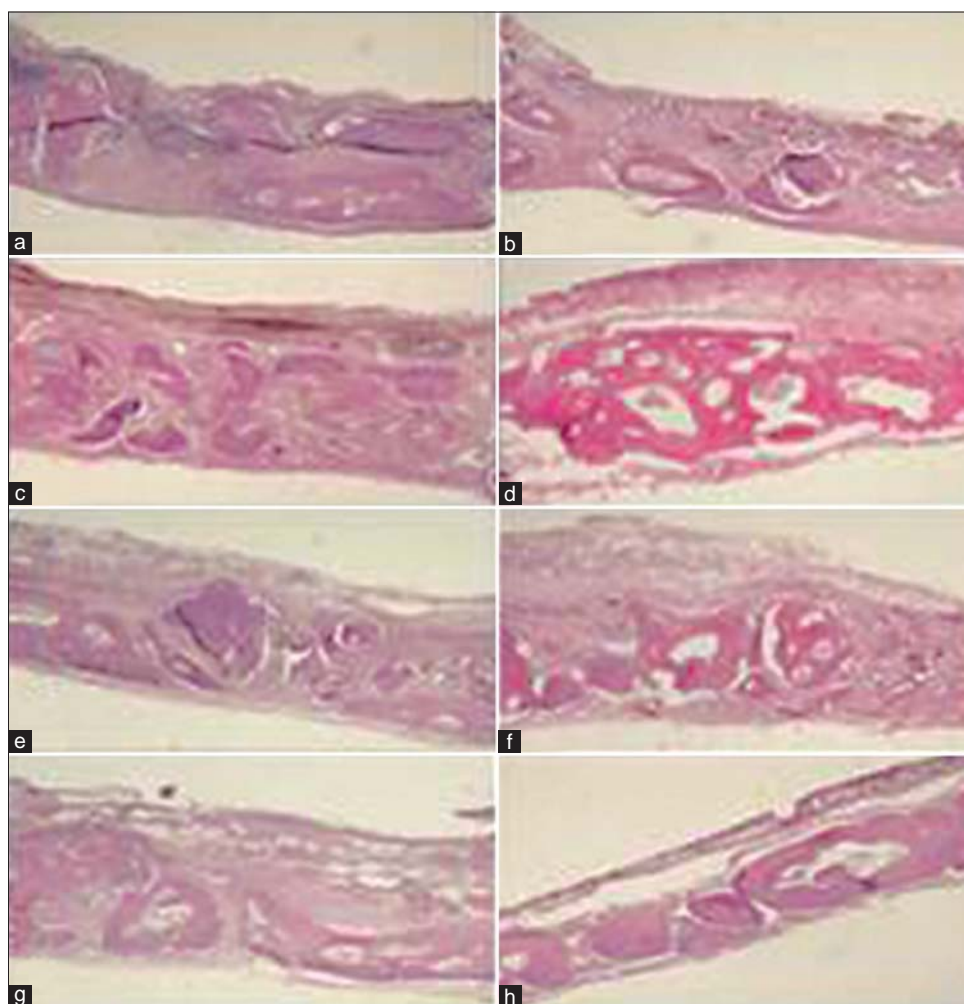


Figure 2: Histological evaluation of all grafted materials and control at 6 and 12 weeks. (magnification $\times 40$). (a) DBM at 6 weeks, (b) DBM at 12 weeks, (c) CENOBONE at 6 weeks, (d) CENOBONE at 12 weeks, (e) DEMBONE at 6 weeks, (f) DEMBONE at 12 weeks, (g) Control at 6 weeks, (h) Control at 12 weeks

by *t*-test ($P < 0.05$ was considered to be statistically significant).

RESULTS

Mean regenerated bone and remained particles in the study samples are mentioned in Table 1.

Histological analysis

In all of the study groups the regenerated bone consisted of woven and lamellar bone was produced after 6 and 12 weeks. Bone formation was seen from margin of the defects with a fibrous connective tissue at the center of the defects in DBM and control groups. There was bone formation in the margin and center of the defect in a fibrous connective tissue background in both healing times in CENOBONE, but only after 12 weeks in DEMBONE allograft. There were foreign body reaction and chronic inflammatory cells in DBM samples in both healing times, but it was diminished in CENOBONE and DEMBONE groups from 6 to 12 weeks and inflammatory aggregations were seen around the remained particles. Chronic inflammatory cell aggregations could be seen around the remained particles in all tested allografts.

Histomorphometric analysis

Mean regenerated bone was increased in DEMBONE ($P = 0.40$), CENOBONE ($P = 0.12$) and control ($P = 0.05$) groups but significantly was decreased in DBM ($P = 0.04$) from 6 to 12 weeks. There was a reduction in mean remained particles after 12 weeks in all allografts, but it was not statistically significant [DBM ($P = 0.53$), CENOBONE ($P = 0.22$), DEMBONE ($P = 0.009$)].

Chronic inflammatory cells significantly was decreased during study period in all groups [CENOBONE ($P = 0.01$), DEMBONE ($P = 0.04$), control ($P = 0.01$)] except DBM which had the

most inflammatory cells after 12 weeks between allografts.

Spearman Rank Correlation Coefficient showed that there was a significant reverse relation between bone formation and remained particles in all groups ($P < 0.001$, $r = 0.624$).

Comparison of mean percentage of bone formation and remained particles between study groups at both healing times are shown in Figures 3 and 4.

After 6 weeks, CENOBONE has the least bone formation, even significantly less than control group ($P = 0.04$) and there were not statistically significant differences between three allografts in remained particles and bone formation.

After 12 weeks, all the bone grafts had more bone formation than 6 weeks except DBM, which demonstrated significantly less bone formation than control group ($P = 0.02$), besides It had the most remained particles between allografts after 3 months. There were not statistically significant differences between three allografts in remained particles and bone formation in this healing time too.

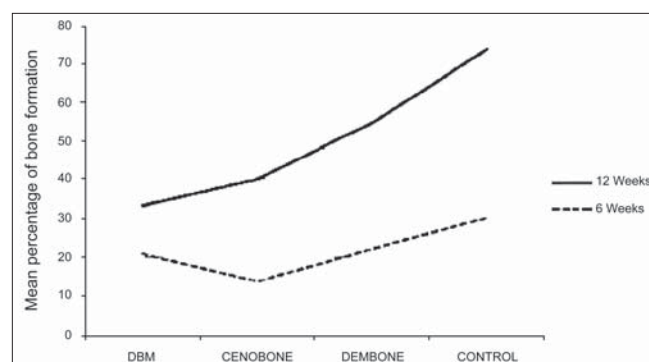


Figure 3: Comparison of bone formation in study groups at two healing times

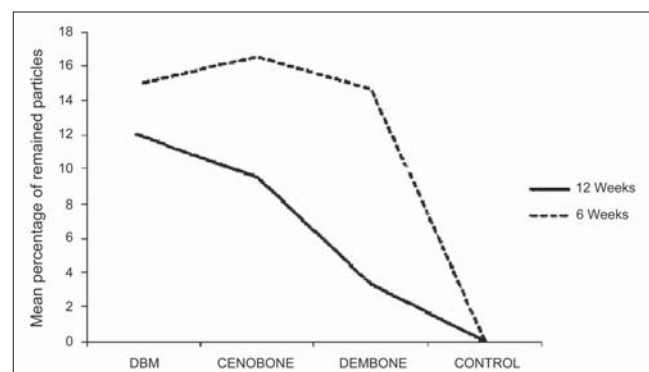


Figure 4: Comparison of remained particles in study groups at two healing times

Table 1: Mean (SDs) percentage of regenerated bone and remaining material in each study sample

Examination	Group	6 weeks		12 weeks	
		Mean	SD	Mean	SD
Percentage of regenerated bone	Dbm	20.88	4.13	12.64	4.98
	Cenobone	13.90	6.32	26.33	12.56
	Dembone	22.14	8.80	32.40	20.91
	Control	30.23	9.50	43.51	5.88
Percentage of remaining graft material	Dbm	15.09	8.56	11.89	4.44
	Cenobone	16.60	4.62	9.54	9.41
	Dembone	14.66	2.54	3.32	5.348
	Control	0.00	0.00	0.00	0.00

DISCUSSION

There are so many choices of grafting materials available to the practitioners. Using enough information about the capacity of bone regeneration of these materials could help to select the most efficient and cost-effective ones.

In this double-blind randomized experimental animal study, the amounts of regenerated bone and remaining graft material, along with the severity of inflammation and foreign body reactions, compared between groups of critical size defects grafted with three common allografts and one group left unfilled and allowed to heal for 6 and 12 weeks.

It is recommended that a healing period of 8 weeks or more and the critical size defects of 11 mm or more should be used for the evaluation of late healing, such as resorption of materials and the amount of bone regeneration, in rabbit's calvaria.^[13]

There were not statistically significant differences between 3 allografts in remained particles and bone formation at two healing times and they could not induce bone formation significantly more than control group. Lee *et al.* found that DFDBA showed higher bone formation than control group after 4, 8 and 12 weeks but the defects were created with trephine 8 in the rat's calvaria, which was different from this study.^[14]

Becker and colleagues^[9] did not find that DFDBA was beneficial for periodontal regeneration and bone regeneration around implants, while Abolfazli and colleagues found the use of DFDBA improve the repair of periodontal lesions in two or three walls alveolar bone defects and reported that it had similar effect like autogenous bone on bone formation.^[10] In some studies DFDBA was enriched with rhBMP-2 and growth factors which made better results.^[15]

Schwartz and colleagues stated that so many differences exist in bone bank preparations of DFDBA and they can induce bone formation variously. In this study DFDBA from two banks caused new bone formation just after 2 months and DFDBA from one of the tissue bank did not induce bone formation at all.^[12]

In our study the defect closure and the new bone area ratio gradually increased with the healing time, but these parameters did not differ significantly between 6 and 12 weeks in all groups except DBM which

the mean percentage of bone formation significantly decreased ($P = 0.04$) between 2 healing times. This may be due to the chronic inflammation presented around the remained particles which was remained more than other allografts after 3 months. As we know the presence of inflammation is mandatory for bone healing but persistence of inflammatory mediators may lead to suboptimal bone formation.^[16]

Chronic inflammation reduced from 6 to 12 weeks in all allografts. Rokn *et al.* stated that the inflammation was reduced during healing time which is in agreement with the result of this study.^[17] DEMBONE had the least inflammation between allografts after 6 weeks and there were not statistically significant differences between it and control group (control group had minute inflammation at both healing times).

Although hydrochloric acid is needed for removal the masking effect of mineralized matrix on BMPs, but putting the allografts for a long time (more than 90 min) in acid bath can affect the BMP concentration reversely. In fact the studies had shown that 2% residual calcium level is necessary for bone induction of allografts, in other words this level of calcium is optimal for osteoclastic resorption and following osteoblastic activity.^[18,19]

Besides Herold *et al.* stated that we can find the highest alkaline phosphatase activity in cultured human periosteal cells with 2% residual calcium which is optimal for bone regeneration.^[20]

The time of acid demineralization may be variant in different tissue banks and this may affect the osteoinductive and osteoconductive properties of them.

Origination of the healing from defect margin is constant and independent of using bone graft as we could see in control group.^[21]

Although CENOBONE had the least bone formation at 6 weeks, but there were bone islets at the centre of the defects which could be seen in defects grafted with DEMBONE after 12 weeks. Presence of bony islets at the center of the defect might present that the particles far from the margin were lined by osteoblasts and actively secret osteoid and this probably point to a more osteoconductive property of these allografts.

In DBM specimens, we could see marginal Bone formation, which means that the graft particles only near the host bone were involved in bone regeneration.

Speed of bone regeneration is important in some treatment modalities such as immediate loading. In this study we could not see any differences in bone formation between allografts at 6 weeks, so no allograft could be faster in bone formation than the other.

The remained particles decreased with increasing bone formation and DEMBONE had the least remained particles after 12 weeks which can be attributed to the nearly smaller size of the graft particles and this could justify the least inflammation of these samples between allografts at 12 weeks.^[22]

According to the study done by Shwartz *et al.*, it was mentioned that the ability of DFDBA to induce bone formation is age dependant^[23] which can affect the ability of bone formation between various tissue banks with different donor selection criteria. In our study the mean cadaver ages were 35 years in all allografts, so there was no difference between them from this aspect.

The graft materials used in this study is considered to be a xenograft, because it was human bone that was used in rabbit's calvaria. One can supposed that this may have had a negative effect on the total bone formation, because studies pointed that allogenic bone grafts may be more effective than xenogenic ones.^[24-26] On the other hand it was stated that there is a homology between BMPs from human, monkey, bovine, rabbit and rat extracellular-bone matrices^[27,28] and in a study by Hollinger, *et al.*, the use of allogenic human bone in primates significantly increase new-bone formation in the CSDs.^[29]

Absence of statistically significant differences between allogenic bone materials can be attributed to the low number of study population, so the author recommended to compare different allografts in studies with the more sample size and in human-controlled trials.

CONCLUSION

Both test and control groups resulted in successful new bone formation. No difference was noted in bone formation and remained particles between three commercial bone allografts.

ACKNOWLEDGEMENTS

This study was partly supported by the Dental Research Center, Isfahan University of Medical Sciences. The

authors would like to thank Dr. M. Manshaei for animal testing and for his contributions to the study.

REFERENCES

1. Pelegrine AA, Sorigi da Costa CE, Sendyk WR, Gromatzky A. The comparative analysis of homologous fresh frozen bone and autogenous bone graft, associated or not with autogenous bone marrow, in rabbit calvaria: A clinical and histomorphometric study. *Cell Tissue Bank* 2011;12:171-84.
2. Williams A, Szabo RM. Bone transplantation. *Orthopaedics* 2004;27:488-95.
3. Kurz LT, Garfin SR, Booth RE Jr. Harvesting autogenous iliac bone grafts: A review of complications and techniques. *Spine (Phila Pa 1976)* 1989;14:1324-31.
4. Marques JM, Viegas C, Dias MI, Zagalo C, Gomes P, Fernandes MH. Modified model of sub-critical size cranial defect in the rabbit. *Int J Morphol* 2010;28:525-8.
5. Moghadam HG, Sándor GK, Holmes HH, Clokie CM. Histomorphometric evaluation of bone regeneration using allogeneic and alloplastic bone substitutes. *J Oral Maxillofac Surg* 2004;62:202-13.
6. Aspriello SD, Ferrante L, Rubini C, Piemontese M. Comparative study of DFDBA in combination with enamel matrix derivative versus DFDBA alone for treatment of periodontal intrabony defects at 12 months post-surgery. *Clin Oral Investig* 2011;15: 25-32.
7. Drosos GI, Kazakos KI, Kouzoumpasis P, Verettas DA. Safety and efficacy of commercially available demineralised bone matrix preparations: A critical review of clinical studies. *Injury* 2007;38 (Suppl 4):S13-21.
8. Lohmann CH, Andreacchio D, Köster G, Carnes DL Jr, Cochran DL, Dean DD, *et al.* Tissue response and osteoinduction of human bone grafts *in vivo*. *Arch Orthop Trauma Surg* 2001;121:583-90.
9. Becker W, Becker BE, Caffesse R. A comparison of demineralized freeze-dried bone and autologous bone to induce bone formation in human extraction sockets. *J Periodontol* 1994;65:1128-33.
10. Abolfazli NI, Saleh Saber F, Lafzi A, Eskandari A, Mehrasbi S. A clinical comparison of cerabone (a decalcified freeze-dried bone allograft) with autogenous bone graft in the treatment of two and three-wall intrabony periodontal defects: A human study with six-month reentry. *J Dent Res Dent Clin Dent Prospects* 2008;2:1-8.
11. Senn N. On the healing of aseptic bone cavities by implantation of antiseptic decalcified bone. *Am J Med Sci* 1889;98:219.
12. Schwartz Z, Mellonig JT, Carnes DL Jr, de la Fontaine J, Cochran DL, Dean DD, *et al.* Ability of commercial demineralized freeze-dried bone allograft to induce new bone formation. *J Periodontol* 1996;67:918-26.
13. Sohn JY, Park JC, Um YJ, Jung UW, Kim CS, Cho KS. Spontaneous healing capacity of rabbit cranial defects of various sizes. *J Periodontal Implant Sci* 2010;40:180-7.
14. Lee DW, Koo KT, Seol YJ, Lee YM, Ku Y, Rhyu IC, *et al.* Bone regeneration effects of human allogeneous bone substitutes: A preliminary study. *J Periodontal Implant Sci* 2010;40:132-8.
15. Sigurdsson TJ, Nygaard L, Tatakis DN, Fu E, Turek TJ, Jin L,

- et al.* Periodontal repair in dogs: Evaluation of rhBMP-2 carriers. *Int J Periodontics Restorative Dent* 1996;16:524-37.
16. Thomas MV, Puleo DA. Infection, inflammation, and bone regeneration: A paradoxical relationship. *J Dent Res* 2011;90:1052-61.
 17. Rokn AR, Khodadoostan MA, Reza Rasouli Ghahroudi AA, Motahhary P, Kharrazi Fard MJ, Bruyn HD, *et al.* Bone formation with two types of grafting materials: A histologic and histomorphometric study. *Open Dent J* 2011;5:96-104.
 18. Turonis JW, McPherson JC 3rd, Cuenin MF, Hokett SD, Peacock ME, Sharawy M. The effect of residual calcium in decalcified freeze-dried bone allograft in a critical-sized defect in the *Rattus norvegicus* calvarium. *J Oral Implantol* 2006;32:55-62.
 19. Pietrzak WS, Ali SN, Chitturi D, Jacob M, Woodell-May JE. BMP depletion occurs during prolonged acid demineralization of bone: Characterization and implications for graft preparation. *Cell Tissue Bank* 2011;12:81-8.
 20. Herold RW, Pashley DH, Cuenin MF, Niagro F, Hokett SD, Peacock ME. The effects of varying degrees of allograft decalcification on cultured porcine osteoclast cells. *J Periodontol* 2002;73:213-9.
 21. Greenwald JA, Mehrara BJ, Spector JA, Chin GS, Steinbrech DS, Saadeh PB, *et al.* Biomolecular mechanisms of calvarial bone induction: Immature versus mature dura mater. *Plast Reconstr Surg* 2000;105:1382-92.
 22. Darby I. Periodontal materials. *Aust Dent J* 2011;56:107-18.
 23. Schwartz Z, Somers A, Mellonig JT, Carnes DL Jr, Dean DD, Cochran DL, *et al.* Ability of commercial demineralized freeze-dried bone allograft to induce new bone formation is dependent on donor age but not gender. *J Periodontol* 1998;69:470-8.
 24. Marinak KW, Mellonig JT, Towle HJ. The osteogenic potential of two human demineralized bone preparations using a xenogeneic model. *J Periodontol* 1989;60:12-8.
 25. Sampath TK, Reddi AH. Homology of bone-inductive proteins from human, monkey, bovine, and rat extracellular matrix. *Proc Natl Acad Sci U S A* 1983;80:6591-5.
 26. Urist MR, Dowell TA. The newly deposited mineral in cartilage and bone matrix. *Clin Orthop Relat Res* 1967;50:291-308.
 27. Thielemann F, Veihelmann D, Schmidt K. The inductin of new bone formation after transplantation [in German]. *Arch Orthop Trauma Surg* 1978;91:3-9.
 28. Thielemann FW, Schmidt K, Koslowski L. Osteoinduction, part 11: Purification of the osteoinductive activities of bone matrix. *Arch Orthop Trauma Surg* 1982;10:73-8.
 29. Hollinger JO, Kleinschmidt JC. The critical size defect as an experimental model to test bone repair materials. *J Craniofac Surg* 1990;1:60-8.

How to cite this article: Behfarnia P, Shahabooui M, Mashhadiabbas F, Fakhari E. Comparison of bone regeneration using three demineralized freeze-dried bone allografts: A histological and histomorphometric study in rabbit calvaria. *Dent Res J* 2012;9:554-60.

Source of Support: This report is based on a thesis which was submitted to the School of Dentistry, Isfahan University of Medical Sciences, Isfahan, Iran, in partial fulfillment of the requirements for the MSc degree in Periodontics (#390418). The study was approved by the Medical Ethics and Research Office at the Isfahan University of Medical Sciences and financially supported by this University. **Conflict of Interest:** None declared.