



Since January 2020 Elsevier has created a COVID-19 resource centre with free information in English and Mandarin on the novel coronavirus COVID-19. The COVID-19 resource centre is hosted on Elsevier Connect, the company's public news and information website.

Elsevier hereby grants permission to make all its COVID-19-related research that is available on the COVID-19 resource centre - including this research content - immediately available in PubMed Central and other publicly funded repositories, such as the WHO COVID database with rights for unrestricted research re-use and analyses in any form or by any means with acknowledgement of the original source. These permissions are granted for free by Elsevier for as long as the COVID-19 resource centre remains active.

Southwestern Internal Medicine Conference: Pneumonias in Adults Due to Mycoplasma, Chlamydiae, and Viruses

BY JAMES P. LUBY, MD

ABSTRACT: Pneumonias in adults due to mycoplasma, chlamydiae, and viruses are a common clinical problem. These microorganisms contribute to the etiologies in 6–35% of all cases of pneumonia and are the sole pathogens in 1–17% of hospitalized cases. Important trends and developments in the field include (1) the emergence of a *Chlamydia psittaci* strain (TWAR) that is passaged from human to human, causes a mycoplasma-like illness, and that is relatively resistant to erythromycin, (2) the recognition of respiratory syncytial virus as a pathogen in nursing home outbreaks and in immunosuppressed adults, (3) the continuing high lethality of fully developed influenza pneumonia, (4) the efficacy of acyclovir and adenine arabinoside in limiting the complications of varicella-zoster virus infections, and (5) the increasing frequency of pneumonia caused by cytomegalovirus and the severity of this disorder in highly immunosuppressed patients. Developments in the rapid diagnosis and therapy of respiratory syncytial virus infections with an aerosolized antiviral drug in children may pave the way for comparable advances in difficult pneumonias in adult patients. **KEY INDEXING TERMS:** Pneumonia; Adults; Mycoplasma; Chlamydia, Influenza A and B; Adenovirus; Varicella; Cytomegalovirus; Respiratory Syncytial; Parainfluenza Viruses. [Am J Med 1987; 294(1):45–64.]

Magnitude and Nature of the Problem of Pneumonias Caused by These Agents

Population-based studies on the incidence of pneumonia have been performed infrequently. In one study, during an 8-year interval from December 1, 1963, through November 30, 1971, Foy and her col-

From the Department of Internal Medicine, The University of Texas Health Science Center at Dallas, Southwestern Medical School, Dallas, Texas.

Reprint requests: James P. Luby, MD, Department of Internal Medicine, 5323 Harry Hines Boulevard, Dallas, TX 75235-9030.

leagues determined the incidence of pneumonia in a prepaid medical health insurance plan comprising more than 100,000 members in Seattle, Washington.¹ They found that total pneumonia rates varied yearly and ranged between 7.2 and 16.8 cases/1,000 population/year. Only 15% of the cases seen by the physicians caring for this group were hospitalized; 85% of the total number of cases were managed as outpatients. In adults, 35% of all cases of pneumonia were associated with cultural and/or serologic evidence of mycoplasma and/or viral infection. Total rates for all cases of pneumonia increased during influenza A2 epidemic years. The highest rates were generally found in the winter quarter, followed by rates occurring during the spring quarter (Figure 1).

The major viral and mycoplasma agents contributing to the etiology of pneumonia in this study were influenza A virus, and *Mycoplasma pneumoniae*, followed by a smaller number of cases due to adenoviruses, influenza B virus, respiratory syncytial virus (RSV), and parainfluenza viruses. Most of the parainfluenza virus infections were caused by Types 2 and 3, but no attempt was made to ascertain the exact contribution of specific agents involved because of antigenic overlap in the complement fixation test. It was recognized that the majority of pneumonias associated with influenza A were related to bacterial suprainfection. Rates for all pneumonia were highest in young children, followed by a peak in pneumonia due to *M. pneumoniae* in the 30–40-year age group. Pneumonia due to influenza A virus increased in incidence above the age of 60 years. Of interest is their finding that sometimes pneumonia was associated with laboratory evidence of infection with more than one respiratory non-bacterial agent. The severity of disease did not appear different between patients with a single infection and those with multiple infections, as measured by duration of illness and hospitalization rates. In individual reports, however, it has been suggested that in certain individuals, multiple infections can sometimes lead to a more severe course than would have been predicted by infection with a single agent.² Overall rates for pneumonia as determined

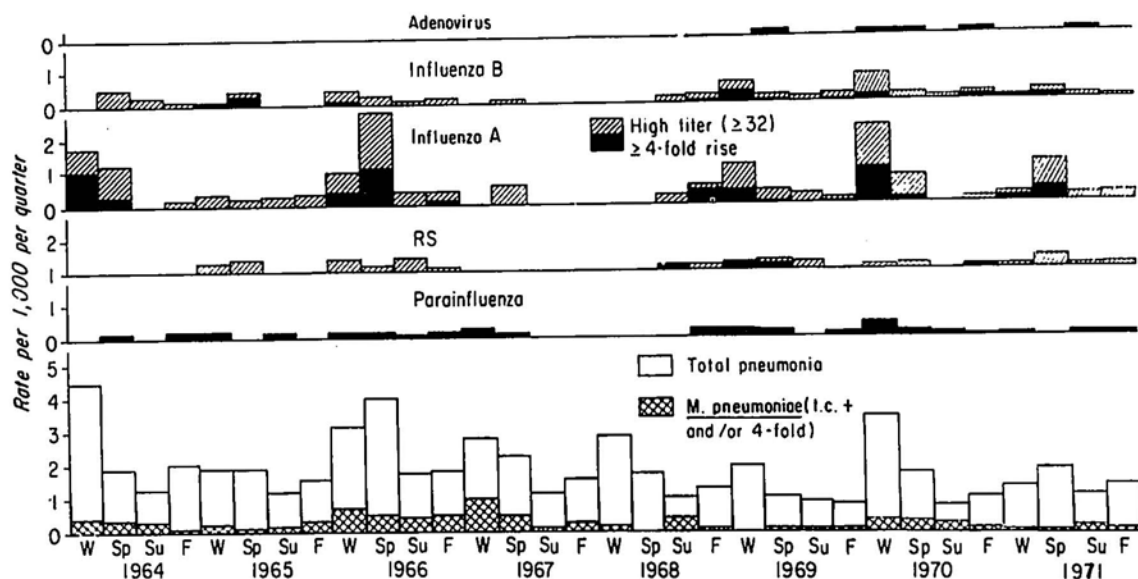


Figure 1. Seasonal rates of pneumonia associated with *Mycoplasma pneumoniae* and various viruses in adults, December 1, 1963, to November 30, 1971. (Reprinted with permission from Foy HM, et al. *Am J Epidemiology* 97:93-102, 1973.)

in this study were similar to those observed in the National Health Survey.

In Houston, Texas, during the years 1975-1978, adult hospitalizations for pneumonia increased sharply during influenza A epidemics but did not change much during influenza B epidemics, a finding that was also seen in the Seattle study (Figure 2).³ Although hospitalizations for pneumonia did not increase in Houston during the 1976-1977 influenza B epidemic, an increased number of patients hospitalized with complications due to influenza B virus infection was seen in Dallas, Texas, at this time.⁴ The etiology of community-acquired pneumonia in 54 adult outpatients in Sweden has been determined.⁵ Using rises in antibody titer between acute and convalescent sera to determine etiology, these investigators found evidence of *Mycoplasma pneumoniae* infection in 37%; *Streptococcus pneumoniae* in 9%; *Haemophilus influenzae* in 12% (6% Type B and 6% nontypeable); influenza A virus in 6%; *Chlamydia psittaci* in 4%; and influenza B virus, parainfluenza 3 virus, respiratory syncytial virus, and adenovirus in 2% each. Multiple infections occurred in several patients and there was no serologic evidence of infection with a particular microorganism in 41%.

The etiologic agents of community-acquired pneumonia in adult patients hospitalized for their disease can be examined (Table 1). Six recent studies were selected for analysis because they had a worldwide authorship and because an attempt had been made to estimate the contribution made by both bacterial and nonbacterial agents.⁶⁻¹¹ Bacterial

etiologies contributed most significantly to the problem of community-acquired pneumonia in adult hospitalized patients. The most frequent microorganisms were *Streptococcus pneumoniae* followed by *Staphylococcus aureus*, *Haemophilus influenzae*, *Legionella pneumophila*, and other gram-negative bacteria. The role of anaerobic bacteria in the etiology of pneumonia was not studied systematically in five of the series. A Nottingham, England, study accentuated the role of *L. pneumophila* in the etiology of pneumonia and showed the propensity of this microorganism to be associated with specific geographic sites. The major nonbacterial agents implicated in these studies included *M. pneumoniae*, influenza A and B viruses, adenoviruses, RSV, parainfluenza viruses, varicella, and *C. psittaci*. All of these latter agents could be seen as single pathogens but influenza A and B viruses, adenoviruses, RSV, parainfluenza viruses, and varicella virus also were associated with bacterial pneumonia. Nonbacterial agents contributed from 6 to 35% to the etiologies of all cases. An indication of the approximate incidence of nonbacterial pneumonia without bacterial superinfection can be ascertained in five of the series and ranged from 1 to 17% of the cases.

The association of influenza A and B viruses, rubeola virus, and varicella virus with bacterial superinfection has been well established. Recently, bacterial superinfection has been shown to occur in adults who have evidence of infection with adenoviruses and RSV. The frequency of bacterial superinfection in association with *M. pneumoniae* infections is difficult to ascertain. It has been considered

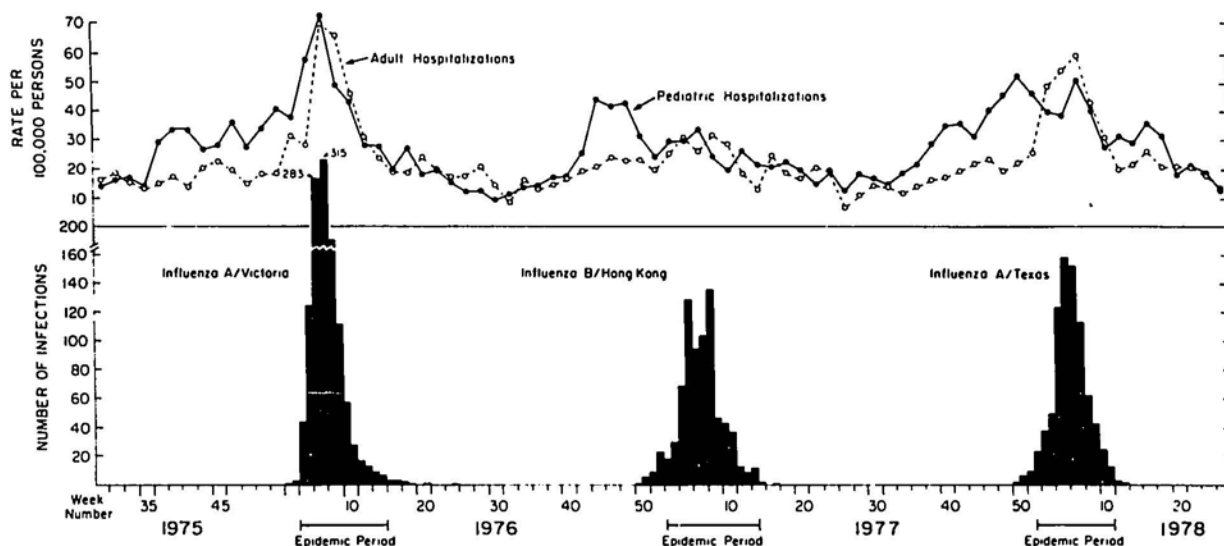


Figure 2. Pediatric (less than 15 years of age) and adult hospitalization rates for acute respiratory disease by 2-week periods estimated for Harris County, Texas (top), and the temporal relation to influenza virus epidemics defined by virologic surveillance at the Influenza Research Center, Houston (bottom), 1975–1978. (Reprinted with permission from Glezen WP. *J Infect Dis* 147:765–770, 1983.)

that bacterial suprainfection of *M. pneumoniae* pneumonia was an infrequent, if not rare, occurrence. Pneumococcal bacteremia, for example, occurring in the course of mycoplasma infections must be extremely uncommon. However, serologic evidence of infection with *S. pneumoniae* and *H. influenzae* has occurred concomitantly with antibody titer rises to *M. pneumoniae*. One case of staphylococcal pneumonia was associated in the Wisconsin series with *M. pneumoniae* seroconversion. Whether *M. pneumoniae* infection predisposes the host to bacterial suprainfection or whether the two events occurred together by chance remains to be determined. A relatively large number of pneumonias have an undetermined etiology and this varies between series of patients. In many instances, these pneumonias appear to respond to penicillin therapy, a phenomenon of interest in suggesting their possible etiologies.

Primary Atypical Pneumonia

The concept of primary atypical pneumonia was set forth in an article by Hobart A. Reimann in 1938.¹² The major bacteria-causing pneumonia were known at that time with the exception of *L. pneumophila*. The clinical entity of psittacosis had been elucidated. Influenza A virus had been grown in ferrets by Laidlaw, Andrews, and Smith. Reimann described eight cases of what he called atypical pneumonia, which he thought was due to a filterable virus. The description of cases allows a view of untreated primary atypical pneumonia. It now seems probable that *M. pneumoniae* was the etiologic agent in most of his cases. The illness often began in-

sidiously with fever, headache, and pharyngitis. With descent of the disease into the respiratory tract, the larynx became involved and hoarseness was present. Finally, laryngotracheobronchitis and pneumonia occurred. A troublesome cough developed in the patient that could not be alleviated and was only slightly productive. In some patients, a pulse-temperature dissociation occurred. During the course of the disease, which often lasted several weeks, patients became dyspneic and cyanotic. Two of the patients became delirious and had central nervous system dysfunction during the course of the infection. On physical examination, the patient was flushed and had evidence of pharyngitis. The physical examination of the chest usually revealed scattered rales without striking evidence of consolidation; in one patient a large pleural effusion was present. The white blood count was only modestly elevated. Chest radiographs revealed mottled or diffuse areas of infiltration. Attempts to isolate pathogenic bacteria and influenza A virus were unsuccessful in establishing an etiology for this syndrome. Reimann considered diagnoses such as typhoid, psittacosis, and epidemic influenza, but the history in none of these cases was consistent and influenza virus could not be recovered. To summarize Reimann's words, "The infection occurred in adults and began as a mild infection of the respiratory tract; this was followed by severe diffuse atypical pneumonia and in two cases by the symptoms of encephalitis. Dyspnea, cyanosis, hoarseness, cough without sputum, drowsiness, and profuse sweating were the chief characteristics. The disease lasted several weeks."

TABLE 1
Etiologic Agents of Community-Acquired Pneumonia in Hospitalized Adult Patients

Etiologic Agent	Number of Patients*					
<i>Streptococcus pneumoniae</i>	79	69	40		96	18
<i>Staphylococcus aureus</i>	11	1	3		3	2
<i>Hemophilus influenzae</i>	4	5	5		4	8
<i>Klebsiella pneumoniae</i>	9					1
<i>Legionella pneumophila</i>		1	1		19	
Other gram negative	5		1		1	2
Anaerobes	3					
Total bacterial	111	75	54	40	122	31
<i>Mycoplasma pneumoniae</i>	7	18			3	7
Influenza A	9	15	4	5	7	
Influenza B		1	1	6		4
Adenovirus				12	1	
Respiratory syncytial virus	1	3			2	
Parainfluenza	3	1		21		3
Varicella		2			1	
<i>Chlamydia psittaci</i>		3			7	
Total nonbacterial	20	45	5	27	21	14
Nonbacterial alone	12	21	1		13	4
Mixed nonbacterial and bacterial	8	24	4	43	8	10
Etiology undetermined	25	27	29		3	37
Total patients studied	148	127	80	110	127	81
Location of study	Wisconsin	Sweden	England	Romania	England	So. Africa
Study Interval	1969-70	not given	1979-82	1984	1980-81	1980
Reference	6	7	8	9	10	11

* The number of patients in each column may not add up to the total patients studied because some had multiple etiologies.

In 1943, Finland found elevated cold agglutinin titers in cases of atypical pneumonia. Eaton later isolated the agent in embryonated eggs, and Chanock and colleagues were able to grow it on defined media and demonstrate it to be a mycoplasma. The entity of primary atypical pneumonia became well known and later was defined as pneumonia that did not clear with penicillin or sulfonamides, or nonbacterial pneumonia, or pneumonia with no sputum or a mucoid sputum without a predominant organism on Gram's stain. We recognize today that the clinical entity of primary atypical pneumonia has multiple etiologies, particularly *M. pneumoniae*, but also *C. psittaci*, the TWAR strain of *C. psittaci*, *Chlamydia trachomatis*, Q-fever, and viruses such as adenoviruses, RSV, influenza viruses, and para-

influenza viruses. *L. pneumophila* infections often are considered in the differential diagnosis.¹³

Early bacterial pneumonia also should be considered when the patient is first seen. In retrospect, persons with this diagnosis are often excluded from series of cases to focus specifically on the nonbacterial nature of the problem. In pertinent geographic areas, acute histoplasmosis and coccidioidomycosis may present like primary atypical pneumonia. Major attempts to identify the etiologic agent on clinical grounds have been made, but the exact diagnosis usually depends on laboratory determination of the offending agent.

In one study of 150 patients of all ages, 50 with viral pneumonia, 50 with mycoplasma pneumonia, and 50 with bacteremic pneumococcal pneumonia

were compared.¹⁴ The best discriminating variables were the C-reactive protein determination, the presence or absence of predisposing disease or previous antibiotic treatment, the erythrocyte sedimentation rate, the presence of lymphocytosis, and the band neutrophile count. Signs of an upper respiratory tract infection and the presence or absence of auscultatory abnormalities also aided significantly in the discrimination. Determinations favoring bacteremic pneumococcal pneumonia included predisposing disease, a short duration of illness before hospitalization, alcoholism, the absence of signs of an upper respiratory tract infection, high C-reactive protein determinations and erythrocyte sedimentation rates, no prior antibiotic treatment, total leukocyte counts exceeding 15,000, relative lymphocyte counts less than 35%, relative band neutrophile counts greater than 20%, abnormal auscultatory findings, and the presence of lobar consolidation on chest radiograph. Differentiation between viral and mycoplasma pneumonia could not be made easily. However, symptoms of mycoplasma pneumonia before hospitalization lasted a longer time and these patients were more likely to have received antibiotic treatment in the interval before hospitalization. Patients with mycoplasma pneumonia were more likely to have lobar consolidation on chest radiograph than those with viral pneumonia, but in this study no distinction could be made between mycoplasma pneumonia and bacteremic pneumococcal pneumonia on the basis of roentgenographic findings alone.

In another study comparing community-acquired pneumonias, mycoplasma pneumonia tended to occur at an earlier age than Legionnaire's disease, pneumococcal pneumonia, or psittacosis.¹⁵ Homogeneous shadowing on chest radiograph was more common in Legionnaire's disease and pneumococcal pneumonia than mycoplasma pneumonia. Pleural effusions were uncommon in all groups but occurred most commonly in bacteremic pneumococcal pneumonia as did multilobe disease on presentation. Hilar lymphadenopathy occurred only in mycoplasma pneumonia. Roentgenographic resolution was fastest in mycoplasma pneumonia, intermediate in psittacosis and nonbacteremic pneumococcal pneumonia, and slowest in Legionnaire's disease and bacteremic pneumococcal pneumonia. Deterioration on chest radiograph after hospital admission characterized Legionnaire's disease and bacteremic pneumococcal pneumonia.

Because the differential diagnosis of primary atypical pneumonia at a clinical level includes pneumonia due to *M. pneumoniae*, chlamydial species, Q fever, adenoviruses, RSV, influenza viruses, parainfluenza viruses, as well as *L. pneumophila* infections and early bacterial pneumonia, therapy should include an antibiotic to which the majority of these

microorganisms are susceptible. Chlamydial species are more susceptible to tetracycline than erythromycin. Tetracycline is effective against rickettsiae but not for *L. pneumophila* infections. Up to 4% of pneumococcal isolates are resistant to tetracycline. A reasonable antibiotic choice is erythromycin at an equivalent dose of 30 mg/kg of erythromycin base per day for 10–14 days. If Legionnaire's disease is diagnosed, a higher dose of erythromycin may be necessary. If a chlamydial or rickettsial etiology is recognized, tetracycline at a dose of 2 gm/day should be given. Occasionally patients with proven *M. pneumoniae* have been treated with erythromycin, failed to respond to therapy, but subsequently responded to a course of tetracycline therapy.¹⁶ Conversely, some patients with *M. pneumoniae* infections have responded to erythromycin after a suboptimal response to tetracycline therapy. Viruses may cause primary atypical pneumonia; however, antibiotic treatment in these instances is useless, does not prevent suprainfection, and may actually change the nature of the bacterial species suprainfecting the patient. Antibiotic therapy seems reasonable in this syndrome, however, because it is usually impossible to differentiate clinically between mycoplasma pneumonia and an entity such as adenovirus pneumonia in the adult. Advances in rapid laboratory diagnosis may be able in the future to influence treatment options but these techniques are still under development, are expensive, and are not widely available.

Pneumonia Due to *Mycoplasma pneumoniae*

Mycoplasmas, the smallest free-living microorganisms, are cell-wall deficient, but have no relationship to cell-wall deficient bacteria with which they were once confused. *M. pneumoniae* attaches to the mucosal epithelium of the respiratory tract through a specific protein that enables the microorganism to adhere to neuraminic acid residues on respiratory epithelial cells. If mycoplasmas cannot attach, there is no damage to the host. Upon adherence, mycoplasmas are able to generate hydrogen peroxide and superoxide anion, resulting in injury to epithelial cells. Because infection occurs commonly in children younger than 5 years of age, although disease is rare at this time of life, mycoplasmas may induce disease primarily by immunopathologic mechanisms.^{17,18} In experimental animals not primed by prior mycoplasma exposure, inflammatory changes occur only after a long interval. With reinfection, inflammatory changes occur more briskly. The extrapulmonic manifestations of mycoplasma infection have never been explained completely, but there are reports demonstrating *M. pneumoniae* in sites such as cerebrospinal fluid and blood.¹⁹ Alternatively, immunopathologic reactions may be the primary mechanism involved. Path-

ologically, the disease in man is characterized by tracheobronchial, bronchiolar and septal lymphoplasmocytic infiltrates, luminal exudates rich in polymorphonuclear leukocytes, bronchiolar and alveolar cell metaplasia, and occasionally diffuse alveolar injury.²⁰ The bronchiole appears to be the major site of attack.

The microorganisms colonize the nasopharynx and transmission of infection occurs only by close contact. Especially conducive to the transmission of *M. pneumoniae* are situations in which persons are housed in closed quarters, such as military platoon barracks or family unit dwellings. In families, there is a high attack rate and cases continue to occur over a 3-4-month interval.^{21,22} The cumulative attack rate of mycoplasma infections in families may approach 90% (Figure 3).²¹ Mycoplasma carriage is not affected by antibiotic therapy, thereby allowing the family epidemic to continue. Mycoplasma disease occurs throughout the year but is particularly frequent during fall and winter. Increased numbers of cases occur with a 3-5-year periodicity.

Although pneumonia may occur soon after infection, the disease is usually manifested as an upper respiratory tract infection progressively descending into the lung. Pharyngitis progresses into laryngitis followed by tracheobronchitis, and, finally, pneumonia. Hoarseness and dysphonia may be present. Middle ear involvement may occur with bullous myringitis, which usually heals without scarring. Occasionally, otitis may lead to tympanic membrane perforation. Sinus involvement is frequent but usually asymptomatic. The cough is often intractable and usually only slightly productive of a mucoid sputum that contains mainly polymorphonuclear leukocytes but no predominant bacterial microorganism on Gram's stain. When pneumonia develops, the patient has an elevated temperature and, occasionally, a temperature-pulse dissociation. Headache, irritation, a flushed facies, myalgias, and arthralgias are common.²³⁻²⁵ On physical examination, the patient is febrile, appears flushed, and usually has physical evidence of pharyngitis. Hemorrhagic bullous myringitis may be present in up to 5% of cases. Physical findings on chest examination usually are limited to scattered rales, wheezes, and rhonchi and are often localized to the lung bases. Evidence of consolidation is not striking, although *M. pneumoniae* infections can cause lobar pneumonia.²⁶ The white count is usually elevated with a shift to the left, but rarely exceeds 15,000 white blood cells/mm³ and the neutrophile band count is usually less than 10%.¹⁴

Chest radiograph reveals peribronchial infiltrates with accentuation of interstitial markings in adjacent lung segments, patchy alveolar infiltrates usually localized to the lower lobes, especially on the left, and occasionally hilar lymphadenopathy.²⁷ More than one lobe may be involved and a confluent

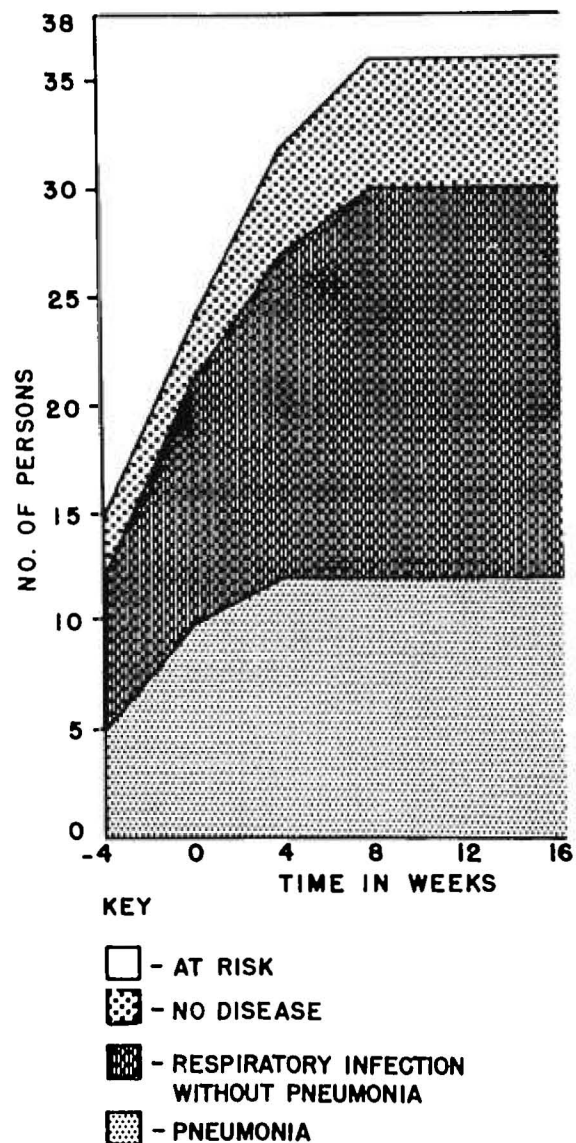


Figure 3. Cumulative incidence of *M. pneumoniae* infection and clinical response in 38 family members exposed. (Reprinted with permission from Balassanian N, et al. *N Engl J Med* 277:719-725, 1967.)

lobar infiltrate may be present in some patients (Figure 4). Less commonly, there is a diffuse interstitial infiltrate and rarely an x-ray picture indistinguishable from the adult respiratory distress syndrome.^{28,29} Without therapy, the disease course usually lasts approximately 3 weeks, but may extend up to 7 weeks.¹² Extrapulmonic manifestations of mycoplasma infection often are a clue to the diagnosis and include bullous myringitis; neurologic disturbances suggesting encephalitis or aseptic meningitis and, rarely, transverse myelitis; arthritis; myopericarditis; hepatic dysfunction; splenomegaly;

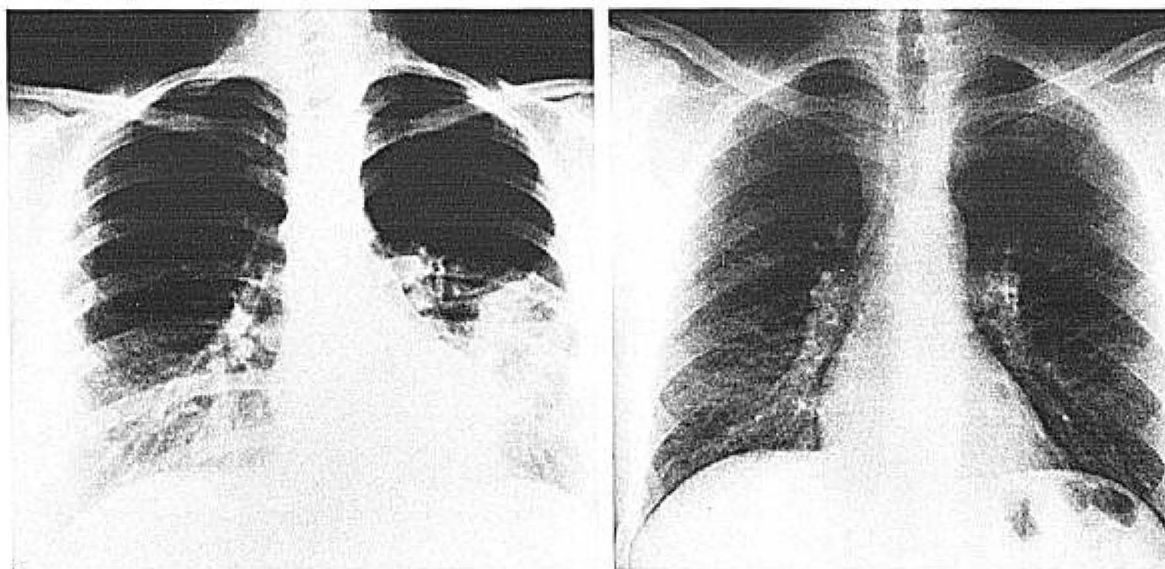


Figure 4. Pneumonia due to *M. pneumoniae*. (Left) Radiograph of an 18-year-old woman showing bilateral, lower lobe (left > right) interstitial, and patchy alveolar infiltrates. (Right) Radiograph of a 43-year-old man with Stevens–Johnson syndrome shows peribronchial and diffuse interstitial infiltrates and hilar adenopathy.

and skin eruptions.³⁰ A Stevens–Johnson syndrome may occur. Japanese workers have described typical cases of pityriasis rosea that followed mycoplasma infection.³² The cerebrospinal fluid (CSF) may be abnormal with an increased number of cells and an elevated protein concentration. Hemolytic anemia may be present resulting from antibody directed against the I antigen on the red-cell membrane.³¹ Almost all patients recover completely after mycoplasma infection but cigarette smokers may have prolonged abnormalities in diffusion capacity.³³ Individual case reports have described pulmonary fibrosis, bronchiolitis obliterans, and bronchiectasis following *M. pneumoniae*.^{34–36} Glomerulonephritis with continuing renal dysfunction also has been reported.^{37,38}

The diagnosis is established by culture of the microorganism or the demonstration of a fourfold rise in antibody by complement fixation or other serologic test. A single high complement fixation test antibody titer ($\geq 1:128$) may be used as presumptive evidence of infection. Cold agglutinin antibody titers at low level are nonspecific but very high values ($\geq 1:128$) also can be used to support the diagnosis.

Treatment consists of the administration of either erythromycin or tetracycline as outlined in the therapy of primary atypical pneumonia. The patient usually responds, but it should be remembered that there are reports of inadequate resolution of the disease and the necessity to switch to the alternate drug to achieve more rapid clinical improvement.

Antibiotic therapy does not eliminate the carrier state. Immunity is relatively short-lasting and documented episodes of repeated mycoplasma infection have been reported. A vaccine against *M. pneumoniae*, given present priorities, appears only a hopeful future development.

Case Report

***Mycoplasma pneumoniae*.** An 18-year-old man was well until 8 days before admission into the hospital, at which time he developed fever, a sore throat, and a nonproductive cough. His oral temperature reached 40° C. A “pounding” headache developed. The cough persisted and became productive of a mucoid sputum. Oral penicillin was prescribed but did not alleviate his symptoms. Physical examination on admission into the hospital revealed a young man who was confused about time and uncertain about recent events. The oral temperature was 38.8° C and the pulse rate was 100. The pharynx was described as normal. Chest examination revealed harsh breath sounds with bilateral inspiratory rales, especially on the right, anteriorly and inferiorly. There was no egophony or decreased fremitus. Rhonchi were present more on the right than left. Hepatosplenomegaly was present. Laboratory examination revealed 12,200 white blood cells with 70% polymorphonuclear cells, 28% lymphocytes, one monocyte, and one eosinophile. The serum aspartate aminotransferase was 140 (normal <40). Arterial blood gases on room air showed a pH of 7.55, pCO₂ of 29, and pO₂ of 45. A lumbar puncture was performed that showed 31 white blood cells, 95% of which were mononuclear cells. The CSF glucose was 69 mg/dL and the simultaneous plasma glucose 155 mg/dL. The patient was treated initially with intravenous penicillin for presumed pneumococcal pneumonia and partially treated bacterial meningitis. His condition deteriorated but finally he was placed on erythromycin therapy at the advice of a consultant. Mycoplasma complement fixation test titers rose from less than 1:8 to 1:64.

Comment. Encephalitis, hepatosplenomegaly, and mild hepatic dysfunction were the extrapulmonic manifestations of

mycoplasma disease. Typical of mycoplasma pneumoniae were the long duration of illness before admission into the hospital, prior antibiotic administration, presence of a sore throat, physical examination of the chest, and characteristics of the sputum.

Pneumonia Due to Chlamydiae

Psittacosis was first described by Ritter in Switzerland in 1879 as a disease of the lungs in patients in contact with sick psittacine birds. Later, in 1929–1930, a pandemic of psittacosis occurred involving psittacine birds exported from South America. The clinical manifestations were described fully and the epidemiology was established, leading to control measures that have kept psittacosis or the better, more inclusive term, ornithosis, at a low level of occurrence. Occasionally migrant birds can carry *C. psittaci*, and persons dealing with them may develop ornithosis. More importantly now, ornithosis is an occupational hazard to the farmer who manages poultry such as ducks and turkeys.^{17,18,40,41} Clinically, patients with ornithosis have headache, fever, pulse-temperature dissociation, pneumonia, hepatic function abnormalities, and hepatosplenomegaly. Intra-alveolar inflammatory changes predominate in ornithosis with interstitial changes being secondary and less prominent. The chest radiograph reflects this and lobar consolidation may be seen. When lung involvement is minor, the disease can be diagnostically confusing, and present as a fever of undetermined origin. Granuloma formation can be found in both the liver and the bone marrow and may be a diagnostic clue. Ornithosis can be diagnosed by serologic tests with a chlamydial common group antigen by either complement fixation or the enzyme-linked immunoabsorbent assay (EIA). Treatment is with tetracycline for 10–14 days.

Chlamydia trachomatis can cause an afebrile pneumonia-like syndrome in young infants beginning at the age of 1–3 months, and is characterized by an afebrile state, failure to gain weight, and a staccato-like cough. On examination, there are rales, expiratory wheezing, and evidence of hyperaeration of the lungs. Chest radiograph usually reveals diffuse interstitial pneumonia and hyperaerated lung fields. Laboratory determinations show a modest eosinophilia and hyperglobulinemia. Upon this identification, the infants can be treated with oral erythromycin syrup for 3 weeks with benefit. Recently, *C. trachomatis* has been isolated from the lower respiratory tract of immunosuppressed patients with pneumonia, although four of the six patients reported and the only ones tested did not show a serologic response to that microorganism.⁴² Cases of community-acquired pneumonia in normal adults also have been reported with serologic evidence of infection with *C. trachomatis*.⁴³ Fifty-two patients were studied and seven were found to have definite or suggestive serologic evidence of infection.

The seven ranged in age from 22 to 77. The chest radiographs of these patients have been analyzed and the infiltrates were found to be patchy and characteristically streaky with areas of plate atelectasis. There was no particular localization to a single lobe and three patients had radiographic evidence of multilobar involvement.⁴⁴ Further studies need to be done to corroborate these reports and determine the frequency with which lung involvement occurs.

In Finland, an epidemic of mild pneumonia has been related to a newly described strain of *C. psittaci*, capable of being passaged from human to human. This epidemic occurred in adolescents and young adults and had a point prevalence of pneumonia of 15–19 cases/1,000 students at the time of x-ray survey.⁴⁵ The contribution of this particular strain of *C. psittaci*, designated the TWAR strain from TW-183 and AR-39, the first two isolates, has been examined best during a 2.5-year study at the University of Washington. Infected students usually presented with a mild pneumonia that simulated mycoplasma infection and was often associated with pharyngitis and laryngitis.⁴⁶ In this study, the TWAR strain of *C. psittaci* caused 12% of the pneumonias in the student population. The TWAR strain of *C. psittaci* was isolated from the students, and serial sera showed conversion to the common chlamydial group antigen by complement fixation tests. Microimmunofluorescence tests revealed specific reactions to the TWAR strain of *C. psittaci*. The microorganisms isolated from the students formed typical inclusion bodies in tissue culture, were not stained by iodine, and were considered typical of *C. psittaci*. The clustering of cases had an epidemiology that suggested human-to-human transmission. Bird-to-human transmission could not be demonstrated in any of the cases. Treatment with tetracycline shortened the course, but, occasionally, patients did not respond to 1 gm of erythromycin given for 5–10 days.

This new strain of *C. psittaci* was isolated from the patients and serologic reactions to specific antigens were demonstrated. The evidence linking *C. trachomatis* to lung disease has either been by isolation alone or just by serologic testing. Further studies similar to the one in Seattle need to be performed to link *C. trachomatis* to lung disease. It is clear, however, that a new strain of *C. psittaci* exists and can cause disease commonly. The disease due to this microorganism can be diagnosed by complement fixation or EIA tests using chlamydial group antigen. Specialized laboratories can isolate the organism and also perform microimmunofluorescence tests. A major new development in the evaluation of patients with primary atypical pneumonia is the emergence of this *C. psittaci* strain that is capable of being passaged from human to human, and that may not have the desired response to erythromycin treatment.

Adenovirus Pneumonia

Adenoviruses are ubiquitous nonenveloped DNA viruses that colonize the human nasopharynx and are transmitted to other persons by close contact. Types 4 and 7 are recognized for their capacity to produce epidemics in military recruit populations. Because the transmission of this group of viruses is dependent upon close human contact, disease is often produced in the home or the military recruit barracks. Pathogenetically, lung infection usually follows pharyngitis and a movement of the disease process down the respiratory tract. Although most cases of pneumonia are not severe, cases coming to autopsy show that the tracheobronchial mucosa is denuded of the normal epithelial structures down to the basal layer. Squamous metaplasia occurs along with interstitial space thickening due to the presence of chronic inflammatory cells. Alveolar edema and mononuclear cell infiltrates are present. As with *M. pneumoniae* infections, infiltrates are often peribronchial or peribronchiolar in distribution. Nuclear inclusion bodies or nuclei with a smudged appearance may be found in epithelial cells.

Clinically, the disease often begins with pharyngitis associated with fever and anterior cervical lymphadenopathy with or without conjunctivitis, then involves the tracheobronchial tree, and, finally, the parenchyma of the lung. Pneumonia is most common in infants, young children, and military recruits. In military recruit populations, mycoplasma and adenovirus pneumonia have been found to be indistinguishable clinically except for an increased

frequency of exudative pharyngitis with adenovirus infection. Physical examination reveals pharyngitis and rhinitis and scattered rales and rhonchi.⁴⁷ Evidence of consolidation is infrequent but occasionally lobar consolidation can occur, as can a pleural effusion⁴⁸ (Figure 5). Virus rarely has been isolated from pleural fluid.² Fatal cases of adenovirus pneumonia can occur in infants, immunosuppressed patients, and rarely in normal persons.⁴⁹⁻⁵³ In these cases, the pneumonia is progressive with the development of diffuse bilateral alveolar infiltrates and hypoxemia requiring ventilator assistance for its correction. As the infiltrates progress, leukopenia ensues with marked lymphocytopenia. Rhabdomyolysis occurs along with evidence of disseminated intravascular coagulation and renal failure. Terminally, the patient becomes obtunded.

Bacterial suprainfection can be associated with adenovirus pneumonia. Suprainfecting species of bacteria include *S. pneumoniae*, Group A streptococci, *H. influenzae*, *S. aureus*, and Group Y *Neisseria meningitidis*.⁵⁴ In military recruits, an increased frequency of Group Y meningococcal suprainfection has been observed because these microorganisms commonly colonize the nasopharynx in this population. Administration of antibiotics during the course of the adenovirus pneumonia does not prevent bacterial suprainfection. Although most persons recover uneventfully from adenovirus pneumonia, occasional patients have residual abnormalities such as restrictive lung disease, bronchiectasis, or bronchiolitis obliterans.^{55,56} Extrapulmonic mani-

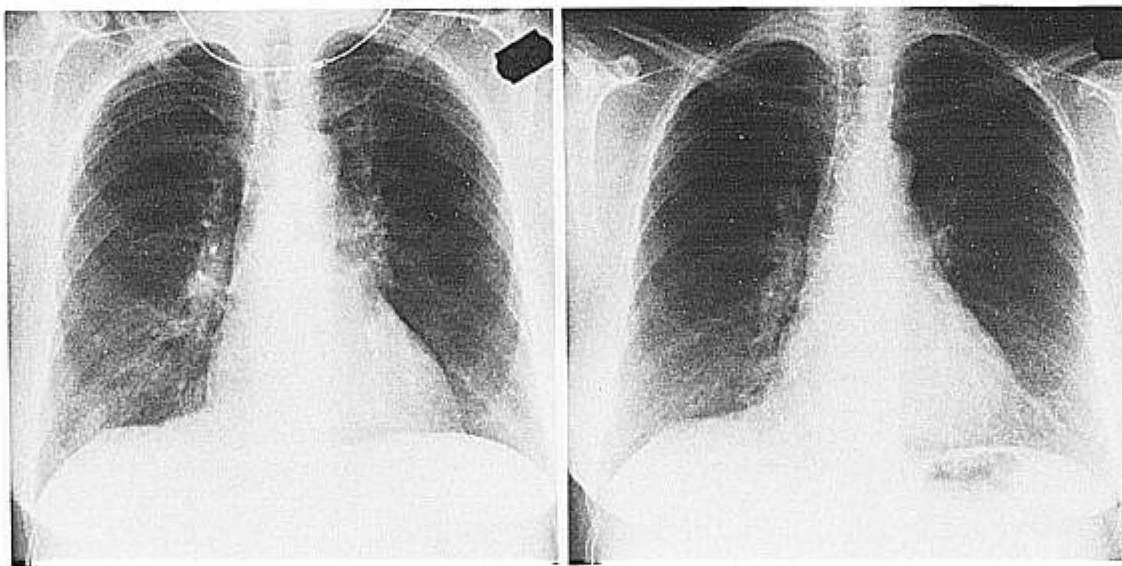


Figure 5. Adenoviral pneumonia. (Left) Radiograph of a 54-year-old woman with bilateral interstitial and alveolar infiltrates and hilar adenopathy. (Right) Resolution of the process during convalescence.

festations of adenovirus infection include pharyngitis, conjunctivitis, pericarditis, arthritis, skin rashes, and hepatic dysfunction. Reye's syndrome has been described during the course of adenovirus pneumonia.⁵⁷ The occurrence of one or more of these manifestations during the course of pneumonia can lead the physician to order appropriate diagnostic tests to make a specific etiologic diagnosis. Virus can be isolated from the nasopharynx, sputum, or endotracheal secretions. Antigen can be detected by immunofluorescence tests, EIA, or DNA hybridization within epithelial cells derived from the respiratory tract.⁵⁸ These latter tests are specific but at the present time less sensitive than viral culture. There is no specific therapy for the infection. Oral live attenuated vaccines are available against Types 4 and 7 adenoviruses, and these are used now in the military to prevent epidemic disease.

Case Report

Fatal Adenovirus Pneumonia. A 32-year-old man with an unremarkable past history except for hypertension was controlled on medication. Two weeks before admission he developed a nonproductive, hacking cough and began to have dyspnea, which increased to the time of admission. On physical examination he appeared in moderate respiratory distress. Oral temperature was 38.1° C, pulse rate was 100/min, blood pressure was 170/106, and respiratory rate was 30/min. The oropharynx was described as normal. Scattered rhonchi and rales were heard diffusely through the lungs. A summation gallop was heard at the cardiac apex. Laboratory examination revealed a white blood count of 5,100 with 82% polymorphonuclear cells, 11% band forms, 3% lymphocytes, and 4% monocytes. Arterial blood gases on room air showed a pH of 7.44, pCO₂ of 31, and pO₂ of 56. EKG showed left ventricular hypertrophy. Chest radiograph revealed an enlarged cardiac silhouette with patchy alveolar infiltrates of the entire right lung and left lower lobe.

The patient was started on erythromycin 500 mg every 6 hours intravenously. He continued to spike temperatures to 40° C. Cefamandole and tobramycin were added to his antibiotic therapy. Two days after admission, the creatine phosphokinase value rose to 16,420 and the next day was 37,576. His creatinine rose to 4.8 mg/dL. His heart was enlarged on radiograph and the pulmonary infiltrates continued to increase. His mental status gradually deteriorated and he was transferred to the intensive care unit. The white blood count was 3,700 with 12% lymphocytes. He developed evidence of disseminated intravascular coagulation and died on the eighth hospital day of respiratory insufficiency.

Postmortem examination revealed changes of viral pneumonia, with some epithelial cells showing intranuclear inclusions and the appearance of "smudged" nuclei, an enlarged heart due to idiopathic myocardial disease, only minimal pathologic evidence of hypertension, and findings of disseminated intravascular coagulation. Electron microscopy of lung sections revealed adenovirus. The adenovirus complement fixation test titer rose from less than 1:8 to 1:64.

Comment. The patient had a 2-week febrile period before admission, and pulmonary infiltrates progressed on antibiotic therapy. He developed leukopenia, lymphocytopenia, rhabdomyolysis, disseminated intravascular coagulation, and acute renal failure. His illness occurred in the setting of idiopathic myocardial disease, and it is possible that mild, chronic, left ventricular failure might have predisposed him to severe adenoviral pneumonia similar to the manner in which cardiac failure augments influenza pneumonia.

Pneumonia Due to Respiratory Syncytial Virus, Parainfluenza, and Other Viruses

Respiratory syncytial virus is the predominant respiratory tract viral pathogen of infancy and young childhood. Infection in adults usually results in no symptoms or a mild upper respiratory tract illness such as the common cold. It is now recognized that immunosuppressed patients and elderly persons can develop pneumonia because of RSV and that it can be severe and complicated by bacterial superinfection.⁵⁹⁻⁶¹ Furthermore, since immunosuppressed and elderly persons may aggregate in hospitals and nursing homes, these institutions are often sites of acquisition of infection. An epidemic of pneumonia and febrile respiratory illness took place in Los Angeles in February-March, 1979.⁶² Forty of 101 residents were affected, 22 having pneumonia. Eight persons died for a case-fatality rate of 20%. Other such outbreaks have been recorded. Nosocomial acquisition of RSV is very difficult to prevent. Hospital personnel become colonized and may have no or mild respiratory tract symptoms. Transfer of virus can occur by patient to personnel to patient transmission or directly from the personnel themselves. Hands and fomites become contaminated by respiratory secretions and virus is spread to patients by direct contact with these sources. The pathology of pneumonia due to RSV is similar to that of other viral pneumonias; however, epithelial cells with intracytoplasmic inclusion bodies can be seen. The x-ray appearance of the pneumonia can be that of a diffuse interstitial process or have interstitial and patchy alveolar infiltrates in the lower lobes, or have an appearance indistinguishable from the adult respiratory distress syndrome.

Pneumonia due to RSV in immunosuppressed and elderly persons is a newly described phenomenon, but one that may be of increasing importance. It is also important because RSV infections can be diagnosed early by antigen detection techniques (immunofluorescence or EIA) and because effective therapy has been developed recently. Antigen detection tests for RSV now equal or exceed the efficacy of viral cultures for diagnosis of infection. Respiratory syncytial virus infections in infancy now have been treated successfully with aerosolized ribavirin.^{63,64} This therapy is indicated for infants and children with lower respiratory tract involvement with RSV who are exceptionally ill or who may have congenital heart disease or bronchopulmonary dysplasia. With aerosol delivery by oxygen tent, hood, or mask, concentrations of ribavirin are quite high in the upper and lower respiratory tract and exceed the minimum inhibitory concentration necessary to inhibit the growth of the virus in tissue culture.

To achieve this concentration by oral administration of the drug, unacceptable toxicity would be en-

countered. This toxicity would include bone marrow depression and particularly anemia related both to maturation arrest and, to a lesser extent, hemolysis. This latter event occurs because ribavirin triphosphate can accumulate in erythrocytes, having a half-life greater than 40 days, and interferes with the formation of guanosine triphosphate. Aerosolized ribavirin therapy is expensive, but is presently approved by the Food and Drug Administration for the therapy of complicated RSV infections in infants and young children. It represents the first example of an effective drug for treating a significant lower respiratory tract viral infection. It is conceivable that this technology could be applied to influenza infections.

Influenza and rubeola will be covered in detail but it is now recognized that other RNA viruses can cause lower respiratory tract involvement in adults. These viruses include the parainfluenza viruses, respiratory enteroviruses such as Coxsackie B viruses and Coxsackie virus A21, rhinoviruses, and coronaviruses.⁶⁵ The magnitude of the problem, however, appears to be limited. Documented instances of severe lower respiratory tract infection due to parainfluenza II and III viruses have occurred, however. There is presently no accepted therapy for these latter infections, although aerosolized ribavirin has been used successfully to control persisting parainfluenza virus infections of the lower respiratory tract in immunodeficient children.

Influenza Pneumonia

Influenza A virus is the cause of pandemics and epidemics that occur every or every other year. All influenza A viruses possess a common group complement fixation test antigen, the nucleoprotein antigen. Influenza A viruses differ in the antigenic character of the hemagglutinin and neuraminidase. The H1N1 strain of influenza A circulated in the world from 1918–1919 through 1957, when Asian influenza strains (H2N2) became predominant. These strains circulated until 1968–1969, when Hong Kong influenza (H3N2) appeared; strains of this virus continue to be transmitted. H1N1 strains again began to circulate during 1976 and they continue to do so. Influenza B strains have the same common complement fixation test antigen, and this differs from that of influenza A virus. The hemagglutinin and neuraminidase of influenza B virus are less prone to change; pandemic disease due to this virus does not occur and the interepidemic interval is longer than that of influenza A, namely, every 3–4 years. Serious morbidity due to influenza A virus occurs because of host factors such as age, underlying disease, and immunosuppression; because immunity wanes with time; and because influenza A viruses are constantly changing their antigenic character. In pandemic years, when both the hemagglutinin and neuraminidase change concomitantly,

there is a tendency for more serious disease to occur than if just one of the surface proteins changes. This is well illustrated by the 1918–1919 and 1957 pandemics. Influenza A viruses may, on certain occasions, be more virulent. In the 1918–1919 epidemic the pneumonia rate in persons from the ages of 25 to 40 years was approximately 10% of those who had influenza.⁶⁶ This and other facts have been cited to indicate the virulence and striking pneumotropism of the virus that led to 20 million deaths occurring throughout the world during the pandemic. Influenza B viruses are more likely to cause disease in younger persons and only occasionally do epidemics occur in which there is excess mortality.

Pathogenetically, influenza virus attaches to cells of the respiratory epithelium and enters by a process termed "receptor-mediated endocytosis." The virion is uncoated in the endosome by fusion with the membrane of this structure, a process requiring an acidic pH. The particle then undergoes a cytoplasmic and a nuclear stage of replication. Virion RNA is capped and polymethylated in the nucleus so that the RNA message now can be recognized by the cell and translated at the ribosome.⁶⁷ In the process of replication, the virus rapidly destroys respiratory tract epithelial structures in order to compromise natural defense mechanisms of the lung, such as mucous production and ciliary activity. In cases of severe pneumonia the epithelium of the trachea and bronchi are destroyed down to the basal layer and then metaplasia occurs, leaving the respiratory tract coated with a layer of squamous cells. There is involvement of bronchiolar structures and an intense peribronchiolar inflammatory process. In uncomplicated influenza, small airways are commonly affected, producing diffuse dysfunction in these structures, mild hypoxemia, and a compensated respiratory alkalosis.^{68,69} In severe influenza pneumonia, there is alveolar cell destruction and disruption of the alveolar–capillary membrane resulting in hemorrhage into the alveoli along with edema, a mononuclear cell infiltrate, and the presence of hyaline membranes. Thickening of the interstitium occurs with a chronic inflammatory cell infiltrate. The process can be fulminant, occurring coincident with the onset of illness, or it can be more protracted, leading to the occurrence of progressive infiltrates over 5–7 days. When an adult respiratory distress syndrome-like picture is produced, influenza pneumonia has a high case-fatality rate, which may approximate 75%.^{70,71} Not all influenza A pneumonia is this severe, however, and there are cases in which only an interstitial or bronchopneumonic process is apparent and the disease simulates *M. pneumoniae*, except that in influenza the leukocyte count tends to be normal or decreased.^{72,73}

Influenza pneumonia can coexist with bacterial suprainfection or bacterial suprainfection can occur

alone. The offending bacterial pathogens may vary between pandemics; in 1889–1890, *H. influenzae* evidently was a major pathogen. In the 1918–1919 pandemic, the Group A streptococcus was considered a major pathogen; more recently, *S. pneumoniae* has been the most common offending agent followed by *S. aureus* and *H. influenzae*.

Occasionally, other gram-negative bacteria may be involved. Influenza B virus can cause a similar spectrum of pulmonary disease, but the number of patients involved is fewer. The hospitalization rate for lower respiratory tract disease nearly always increases during influenza A epidemics. This rate tends not to increase during influenza B epidemics, although total hospitalizations may be increased during this period; like influenza A virus, influenza B virus can cause a variety of disease processes outside the lung. These include myopericarditis, rhabdomyolysis, disseminated intravascular coagulation, nervous system disturbances such as encephalitis, Reye's syndrome, the Landry–Guillain–Barré syndrome, the Stevens–Johnson syndrome, and others.^{4,74}

Clinically, the patient with influenza virus pneumonia has the sudden onset of fever, prostration, and myalgias followed shortly by dyspnea. Blood-tinged sputum may be produced. The dyspnea progresses until hospitalization and ventilatory support are required. The illness can also assume a more protracted course leading to progressive interstitial and alveolar infiltrates over a week (Figure 6). Some pa-

tients simply have viral pneumonia with pulmonary dysfunction but do not need ventilator assistance. Complicating bacterial suprainfection may coexist with viral pneumonia or more commonly presents after an afebrile interval, during which the patient appears to be recovering from the primary infection. Morbidity and mortality are greatest in elderly persons, in those with chronic disease states such as chronic obstructive pulmonary disease, chronic congestive heart failure or diabetes mellitus, and in immunosuppressed patients.

Morbidity due to influenza A and B viruses is not limited to these groups, however. Women in the third trimester of pregnancy also may have an increased rate of developing influenza pneumonia and death due to this disease process.⁷⁵ In renal transplant recipients who contract influenza A, illnesses are often prolonged, with the development of viral pneumonia, bacterial suprainfection, and myopericarditis. There may be loss of the renal allograft due to the combination of these disease processes.⁷⁶ Influenza A and B virus infections are diagnosed by serial titer rises in a suitable serologic test such as the complement fixation or the hemagglutination inhibition test. A single complement fixation test titer $\geq 1:128$ has been shown to correlate highly with recent influenza B infections.⁴ Virus can be grown from the nasopharynx or endotracheal secretions by inoculation of the specimen into Rhesus monkey kidney or Madin–Darby canine kidney tissue culture. Embryonated eggs sometimes need to be used for

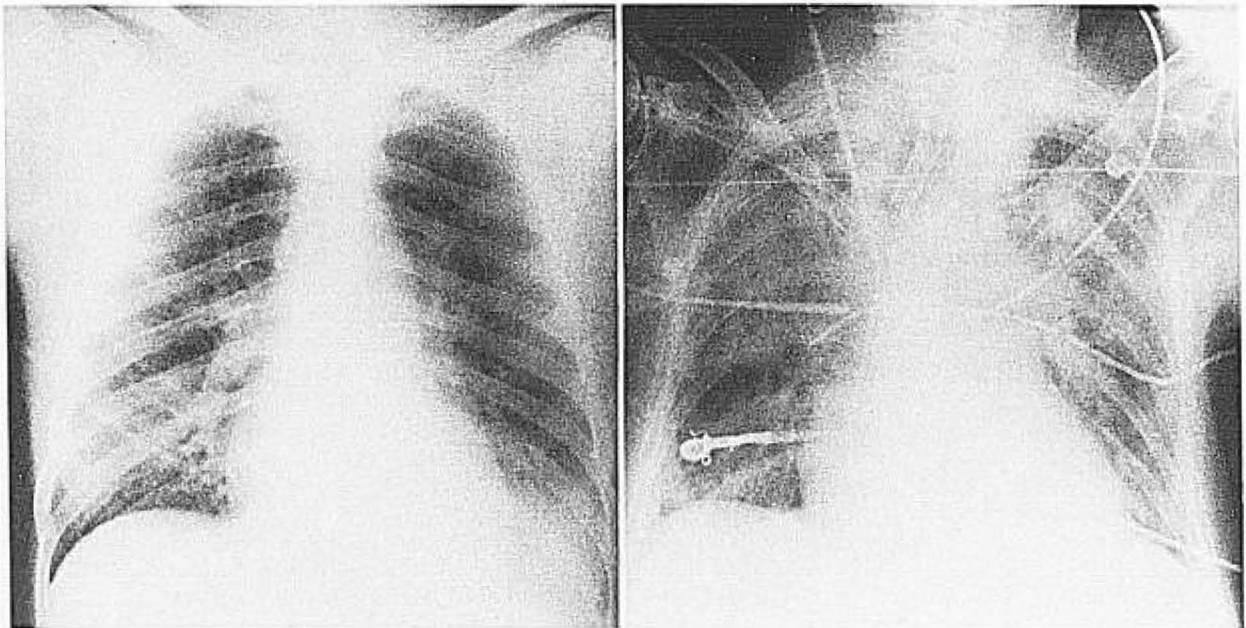


Figure 6. Influenza pneumonia. The radiograph on the left shows combined influenza pneumonia with left lower lobe consolidation indicating bacterial suprainfection. The radiograph on the right shows diffuse alveolar infiltrates in the course of serologically documented influenza A infection. Bacterial cultures from endotracheal secretions consistently showed no growth.

optimal recovery of virus. Virus may be able to be identified within 72 hours by using immunofluorescence. Direct detection of antigen by immunofluorescence or EIA can be applied to appropriate secretions, but these tests are not yet as sensitive as viral culture.⁷⁷

Amantadine and rimantadine are two compounds that have both prophylactic and therapeutic efficacy against influenza A but not influenza B virus. They act by preventing uncoating of influenza A virus, perhaps by preventing the development of an acidic pH so that the envelope of the virion cannot fuse with the endosomal membrane. At the dosage given, 100 mg twice a day, amantadine has more central nervous system side effects and the dose has to be adjusted with renal failure.⁷⁸ The dose of rimantadine does not have to be adjusted with renal dysfunction because the compound is metabolized in the body.

A study sponsored by the National Institutes of Health is underway evaluating whether rimantadine can be used effectively in the therapy of hospitalized patients with influenza A, and would include patients with influenza A virus pneumonia. Ribavirin has in vitro efficacy against both influenza A and B viruses. It has multiple sites of action including interference with the formation of guanosine triphosphate and deoxyguanosine triphosphate and prevents placement of the polymethylated cap structure on the influenza A viral RNA message. With the aerosolization of ribavirin, high concentrations of the drug can be produced within the respiratory tract but serum levels are low.^{79,80} Attempts most likely will be made in the future to treat influenza A virus pneumonia with aerosolized ribavirin or a combination of ribavirin and rimantadine. Influenza B virus pneumonia may be able to be treated with aerosolized ribavirin. Vaccines exist for both influenza A and B viruses, and standard medical care necessitates yearly immunization of elderly patients or those with underlying medical conditions. A recent emphasis of the Public Health Service is to have medical personnel also immunized yearly, since they are exposed to persons with influenza, may develop that illness themselves, and may then transmit the infection to sick patients within the hospital.

Case Report

Nosocomial influenza pneumonia. A 55-year-old alcoholic man was admitted to the hospital on January 30 with alcoholic liver disease, macrocytic anemia, and symptoms of bladder neck obstruction. He was a heavy smoker and had evidence of chronic obstructive pulmonary disease. Twelve days after admission into the hospital, he developed fever to 39.2° C while awaiting a urologic procedure. He "felt terrible" with myalgias and developed a cough, mild diarrhea, and dyspnea. Chest examination revealed diffuse rales and rhonchi. Chest radiograph showed new interstitial infiltrates, more prominent on the right. The sputum was mucoid. The diagnosis of pneumonia was made and the diag-

nosis of congestive heart failure with pulmonary edema considered. However, his heart examination revealed no gallop sounds and his neck veins were not distended. He was placed on ampicillin, became afebrile after 5 days, and his dyspnea improved with low flow oxygen by face mask. Influenza A complement fixation test titer on a single convalescent serum specimen was $\geq 1:256$.

Comment. Influenza virus pneumonia occurred during hospitalization. The pneumonia cleared with symptomatic therapy. The Public Health Service now recommends widespread immunization of medical personnel in an attempt to prevent nosocomial acquisition of influenza.

Measles Pneumonia

Although predictions were made that rubeola would be eradicated in this country during the early 1980s, this has not been achieved. In Dallas, Texas, during 1986 more than 150 cases of rubeola occurred. This marked a resurgence of cases after a relatively disease-free interval after 1971, when a large epidemic occurred in Dallas, causing more than 1,000 cases, including three deaths. As a consequence of this and other epidemics, in 1971 Texas adopted a law requiring the compulsory immunization of children against measles, mumps, rubella, poliomyelitis, diphtheria, and tetanus.

Present rubeola vaccines are at least 95% effective, but universal immunization of the preschool child is not practiced, particularly in lower socioeconomic class population groups. Furthermore, rubeola virus has been found to violate the concept of herd immunity, a major principle on which eradication was based, because outbreaks occur in high schools and colleges in which a large percentage of the population has been immunized. An inactivated vaccine was available from 1962 through 1965. Children who received the inactivated vaccine may have developed atypical measles on exposure to rubeola virus. Following this, an attenuated, live strain of measles virus was used as vaccine but the high side-reaction frequency necessitated the concomitant administration of γ -globulin. It is now recognized that the concurrent use of γ -globulin sometimes rendered immunization ineffective. Many children were immunized before the age of 12 months; for effective immunization to occur, vaccine must be given after the age of 15 months. As a consequence of the lack of universal preschool immunization and difficulties related to the vaccine, there now exist two population groups who may be nonimmune with respect to rubeola, ie, preschool children, and adolescents and young adults. A few years ago rubeola epidemics were common in military recruits. Following the occurrence of these outbreaks, recruits now routinely undergo serologic testing, and if antibody to rubeola virus is not detected by either hemagglutination inhibition or indirect immunofluorescence tests, live attenuated vaccine is given. This practice essentially has stopped the occurrence of these outbreaks in the military.

Persons who received the inactivated vaccine can develop atypical measles. The first cases of this new syndrome were misdiagnosed as Rocky Mountain Spotted Fever. They were confused with this disease because the rash began on the extremities and spread inward to involve the trunk. The rash could be maculopapular, vesicular, or petechial. In atypical measles, pulmonary involvement consists of nodular infiltrates, lobar consolidation, and the occurrence of pleural effusions. Hilar lymphadenopathy may also be present in these patients.^{81,82} They have an anamnestic response in antibody production with the infection. Mild eosinophilia may also be present and the virus cannot be recovered from the nasopharynx.

In young adults with typical measles, approximately 5% develop clinical evidence of pneumonia. Radiographic evidence of pneumonia, however, may be seen in up to 50% of the patients. The pneumonia is usually characterized by diffuse bilateral interstitial or fine reticulonodular infiltrates, particularly affecting the lower lobes. Bacterial superinfection occurs in as many as 30% of cases of recognized viral pneumonia. The types of bacteria causing infection may be determined by the circumstances in which disease occurs, such as military recruit populations. Recognized pathogens include *H. influenzae*, *S. pneumoniae*, Group A streptococci, Group Y meningococci, and *S. aureus*. Bacterial superinfection generally occurs between the fifth and tenth days after the rash and is heralded by clinical worsening, new or different lung infiltrates, or changes in sputum characteristics or the white blood count. Antibiotic treatment of viral pneumonia does not prevent bacterial superinfection.

In immunodeficient children, measles pneumonia occurred without a rash and pathologically was called giant-cell pneumonia. It is now recognized that these children lacked cell-mediated immunity and had depressed and delayed antibody production.⁸³ Intact cell-mediated immunity is essential for rash production. In fatal rubeola pneumonia, the entire tracheobronchial tree may be denuded of cells down to the basal layer; squamous metaplasia of the cells occurs; there is widening of the interstitial space with edema and inflammatory cells; and alveoli are filled with edema, hyaline membranes, and mononuclear cells. In addition, giant cells containing multiple nuclei are found within the tracheobronchial epithelium. Extrapulmonic manifestations of measles occur and include otitis media, sinusitis, encephalitis, and the common presence of hepatic dysfunction in young adults, mostly consisting of mild elevations of the serum aspartate aminotransferase and lactic dehydrogenase. There presently is no specific therapy. Some public health authorities now think that reimmunization with measles, mumps, and rubella vaccines should be

given before or when the child enters high school. Medical personnel not sure of their rubeola immunity should have that status assessed by determination of specific antibody.

Pneumonia Due to Varicella-Zoster Virus

Varicella-zoster virus can produce pneumonia during the course of varicella or disseminated herpes zoster and can be a severe disease that can lead to mortality. Varicella in childhood is not usually associated with viral pneumonia, but bacterial superinfection can occur, necessitating appropriate antibiotic treatment. In immunosuppressed children, however, pure viral pneumonia can occur in association with varicella. In adults, there is a tendency for the virus to affect the lung relatively commonly during varicella. Fifteen to twenty percent of all adults with varicella may have x-ray evidence of pneumonia but only about 5% require hospitalization. Most frequently in adults, varicella pneumonia is not complicated by bacterial superinfection; however, this can occur, particularly when patients require intubation. The virus reaches the lung both by passage down the respiratory tract and by hematogenous seeding because the rash is occurring at the same time as the pneumonia. Initially, the pneumonic process appears as nodular infiltrates, 1-4 mm in diameter associated with an interstitial inflammatory infiltrate.⁸⁴ The lesions are more dense toward the hilum and are the counterpart in the lung of the pox occurring on the skin (Figure 7). Peribronchial inflammatory infiltrates, hilar adenopathy, and pleural effusions may occur.

The reticulonodular interstitial infiltrate can progress to widespread alveolar damage and diffuse pulmonary parenchymal infiltrates. Pathologically, the pneumonia resembles influenza pneumonia except that areas of coagulative necrosis can be seen. Although these necrotic areas generally clear during the course of clinical disease, they can become calcified, and the radiograph shows a picture of miliary calcifications. It has been shown that this area of coagulative necrosis can become surrounded by an inflammatory infiltrate and resemble a granuloma.⁸⁵ Fibrous tissue envelops the necrotic granulomatous process and the lesion eventually calcifies.

Another process occurring in varicella pneumonia is destruction of the epithelium of the trachea and bronchi. In cases in which the illness is protracted, the development of a thick, fibrinopurulent crust may occur over the lower pharynx, larynx, and upper trachea. This thick crust can cause respiratory embarrassment and can pose a problem for intubation. Disseminated herpes zoster can cause the same processes in the lung. Most normal adults recover from varicella pneumonia without difficulty, but there can be substantial respiratory morbidity and mor-

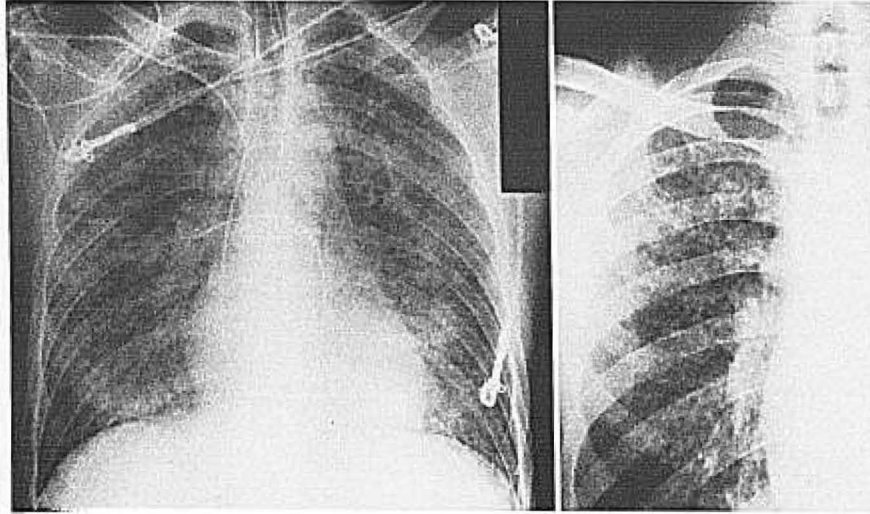


Figure 7. Varicella pneumonia. The chest radiograph on the left is from the case report described in the protocol. The close-up film on the right in another patient shows peribronchovascular infiltrates and multiple 1–4-mm rounded opacities in the right lung field.

tality in immunosuppressed patients or in women during the third trimester of pregnancy.⁸⁶

Clinically, the patient with varicella–zoster virus pneumonia presents with a rash followed by cough and dyspnea. The sputum is initially white and modest in amount, but can become hemorrhagic. The process can be complicated by the development of chest pain and pleural effusions, which are often blood tinged and related to the presence of pox on the pleural surface. Extrapulmonic manifestations of varicella occur and consist of the characteristic skin rash, otitis media with bacterial suprainfection, myopericarditis, hepatic dysfunction, and encephalitis.

Reye's syndrome can complicate the course of varicella. There can be an associated glomerulonephritis and varicella virus can occasionally induce frank arthritis. In caring for patients with varicella–zoster virus pneumonia, it is important to realize that the external appearance of the patient or his apparent well-being may disguise underlying hypoxemia. If efforts are not made to diagnose and correct the hypoxemia, the patient may become confused, perform inappropriate activity, and become more hypoxemic. Ventilator support may become necessary. Deaths in varicella pneumonia occur because of respiratory insufficiency, the development of tension pneumothoraces, bacterial suprainfection, or progressive pulmonary fibrosis.

Two antiviral compounds, adenine arabinoside (Ara-A) and acyclovir (ACV), have been proven to be efficient in the treatment of significant, complicated varicella–zoster virus infections. Adenine arabinoside inhibits viral DNA polymerase and is given at a dosage of 10 mg/kg over a 12-hour period for at least 5 days. The dosage could be increased to 15 mg/kg

but the majority of experience with varicella–zoster virus infections is with 10 mg/kg/day. The drug is sparingly soluble so that 2 mL of vehicle are required for each milligram of drug administered to the patient. At a dose of 10 mg/kg, bone marrow suppression does not usually occur.

If the dose is not decreased in the setting of hepatic and renal dysfunction, central nervous system disturbances, which consist of insomnia, hallucinations and tremulousness, may occur. These central nervous system manifestations usually fade with stopping the drug and rarely lead to death, but can persist for a protracted period after the drug has been discontinued. Acyclovir also has been used to treat varicella–zoster virus infections. It inhibits viral DNA polymerase and also acts as a chain terminator. Its dosage is 500 mg/M² every 8 hours for at least 7 days. The only significant problem with the administration with acyclovir in this setting is the production of an obstructive nephropathy, due to salting out of the drug in the collecting tubules of the kidney. This is usually easily managed by administration of a fluid bolus, a diuretic, or mannitol.

A comparison of the two drugs in complicated varicella–zoster virus infection has been made.^{87,88} One group found that acyclovir was more efficacious; the other study determined that Ara-A was equally as effective. Because the administration of Ara-A requires an increased volume of fluid and can be associated with central nervous system side effects, some authorities now consider acyclovir the drug of choice in the treatment of complicated infections due to varicella–zoster virus. Oral acyclovir is absorbed poorly by the gastrointestinal tract and its efficacy in uncomplicated herpes zoster is apparent only

when 800 mg are given 5 times a day for at least a 5-day period. There has been no experience with oral ACV in treating varicella pneumonia. Future modes of therapy may include combining Ara-A with ACV or administering one or other of the drugs with an interferon preparation. Alpha-interferon also has been shown to be effective as therapy in complicated varicella-zoster virus infections but its use has been superseded by ACV and Ara-A.

Case Report

Varicella Pneumonia. A 39-year-old man was exposed to his two children with chicken pox. Two days before admission he developed a rash, then dyspnea. On physical examination, a typical varicella rash was present. He was in severe respiratory distress. Rales were present diffusely over both lung fields. The chest radiograph revealed bilateral extensive alveolar infiltrates. Arterial blood gases showed a pH of 7.42, pCO₂ of 32, and a pO₂ of 24. He was intubated and begun on positive end-expiratory pressure (PEEP) with a FIO₂ of 70%. He was started on intravenous acyclovir 500 mg/M² every 8 hours. He improved and was able to be extubated after 5 days.

Comment. Severe varicella pneumonia responded to intravenous acyclovir while his oxygenation was maintained on PEEP with a high FIO₂.

Pneumonia Due to Herpes Simplex Virus and Epstein-Barr Virus

Herpes simplex virus can cause a necrotizing bronchopneumonia in neonatal infections and can also cause pneumonia in severely immunosuppressed adult patients. The largest series of patients with herpes simplex virus pneumonia was reported from Seattle in bone-marrow transplant recipients and consisted of 20 patients with either a focal pneumonia (12 patients) or a diffuse interstitial pneumonia (eight patients).⁸⁹ The focal pneumonia was found associated with herpetic esophagitis and tracheitis and probably resulted from contiguous spread of herpes virus to the lung parenchyma. Diffuse interstitial pneumonia most probably resulted from hematogenous dissemination of virus to lung. Pathologically, the process can be one of a necrotizing bronchopneumonia or of a widening of the interstitial space in the lung associated with diffuse alveolar injury. In these highly immunosuppressed patients, both bacterial and fungal suprainfection occurred and it was difficult to sort out which process was responsible for what proportion of lung damage. Acyclovir has been shown to be an effective treatment of complicated herpes simplex virus infections in immunosuppressed patients. Its dose in the usual patient is 250 mg/M² every 8 hours for at least 7 days, but if the process has been ascertained to be a rapidly progressive herpetic pneumonia, the dose could be increased to 10 mg/kg every 8 hours until a therapeutic response had been obtained. With the development of potent antiviral chemotherapy, there is a need to consider and diagnose herpetic pneumonia. Specific diagnosis can only be accomplished readily by lung biopsy.

Although involvement of the lung in infectious mononucleosis due to Epstein-Barr virus must be considered a rare occurrence, recent studies and case reports demonstrate that it probably can happen.^{90,91} Careful attention should be given to possible coexisting mycoplasma and other viral infections, particularly since the former can be treated. Radiographic abnormalities may consist of hilar adenopathy, strand-like parenchymal infiltrates, diffuse bilateral pneumonia, and a picture consistent with primary atypical pneumonia. Although Epstein-Barr virus is susceptible to acyclovir, there are no reports treating lung involvement with this drug.

Cytomegalovirus Pneumonia

Cytomegalovirus (CMV) rarely causes pneumonia in normal adults as part of the CMV mononucleosis syndrome.⁹² However, it is more common for CMV to induce pneumonia in normal hosts than Epstein-Barr virus. Of 443 patients with community-acquired pneumonia, 18 had virologic,² pathologic,² or serologic¹⁴ evidence of CMV infection.⁹³ Ten of these 18 patients were not immunosuppressed. In five of the ten, CMV was the only pathogen. The remaining five patients had one or more coexisting infections; *C. trachomatis* in two, *M. pneumoniae* in one, Epstein-Barr virus in one, and bacteria in three, both aerobic and anaerobic.

Cytomegalovirus more commonly causes pneumonia in immunosuppressed patients. It occurs particularly in renal, heart, liver, and bone-marrow transplant recipients. It is now becoming an increasing problem in patients with AIDS. In the transplant recipient experiencing a primary CMV infection, the virus most probably reaches the lung parenchyma through the hematogenous route, and the first finding is that of a reticulonodular infiltrate and the presence of 1–4 mm opacities (Figure 8). Pathologically, these focal areas usually consist of necrotic tissue, hemorrhage and alveolar damage with edema, a mononuclear infiltrate, and typical cytomegalic cells. The process can extend leading to diffuse interstitial and alveolar infiltrates.

An attempt has been made to separate the foregoing process from that of an insidiously developing interstitial pneumonia that occurs more commonly in reactivated infections and has a better prognosis.⁹⁴ In bone marrow transplant recipients, diffuse interstitial pneumonitis due to CMV is much more common in patients receiving allogeneic transplants, and the case-fatality rate approximates 90%.⁹⁵ In some renal transplant recipients, the pneumonic process can be focal and does not have to be exceptionally severe.⁹⁶ Small pleural effusions can occur occasionally. In other renal transplant recipients, however, CMV pneumonia can progress rapidly and lead to death as part of a widely disseminated infectious process.⁹⁷ In cardiac transplant recipients a

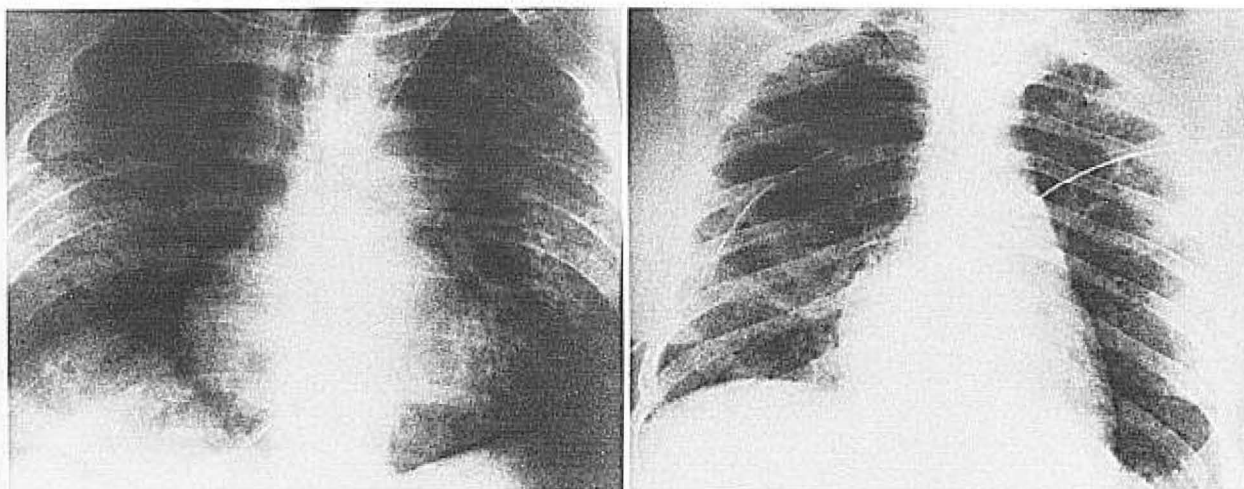


Figure 8. Cytomegalovirus pneumonia. The chest radiograph on the left is from the case report described in the protocol and shows diffuse alveolar infiltrates. The radiograph on the right shows diffuse reticulonodular infiltrates in a woman with systemic lupus erythematosus treated with steroids and cyclophosphamide.

variety of pulmonary opportunistic suprainfections has been well documented to occur in the course of CMV pneumonia.⁹⁸ Typical microorganisms causing suprainfections include *P. carinii* and nocardia species. In patients with AIDS, there may be co-existing infection with pneumocystis. Cure of the pneumocystis can be effected by drugs, leaving CMV as the major pulmonary pathogen. In patients with AIDS, rapid development of CMV pneumonia can occur and lead to the death of the patient. Extrapulmonic manifestations of CMV in the renal transplant recipient include fever, malaise, hepatic dysfunction, splenomegaly, leukopenia, and an increase in serum creatinine.⁹⁶

With extensive CMV dissemination in heavily immunosuppressed patients, including those with AIDS, extrapulmonic manifestations include gastrointestinal ulceration with bleeding and perforation, hepatic dysfunction, adrenal cortical involvement, and central nervous system dysfunction. Cytomegalovirus can be thought of as an immunosuppressive viral agent, and infection with this microorganism may lead to further immunosuppression with consequent bacterial, fungal, and parasitic suprainfection.

Clinically, patients with CMV pneumonia complain of dyspnea with a nonproductive cough. There can be an associated pleurisy. The process can be transient or can extend to respiratory insufficiency necessitating ventilatory support. Therapy of fully developed CMV pneumonia has been shown not to be effective and this includes the use of the adenine arabinoside, acyclovir, ganciclovir (DHPG), and combinations of interferon with all the above. Ganciclovir has been successful in achieving an antiviral effect in the lung, yet has not improved outcome in

bone marrow transplant recipients with CMV pneumonia.⁹⁹ In an occasional renal transplant recipient who has the potential of a good immune response to the virus, the CMV illness that can include localized pneumonia might be benefited by the judicious use of ganciclovir. Attempts at preventing CMV pneumonia have included donor selection, avoidance of white blood cell transfusions, and prophylactic administration of alpha-interferon or γ -globulin preparations given before and through the first 60 days after transplantation. Alpha-interferon does prevent CMV viremia in the renal transplant recipient; γ -globulin protects partially against CMV pneumonia if white blood cell transfusions have not been given. Studies are in progress trying to make this latter effect more consistent, and consist of determining whether total antibody content is the necessary component or whether the effect necessitates the presence of large quantities of neutralizing antibody. On a priority basis, live, attenuated CMV vaccine development has been curtailed for the immediate future.

Case Report

A 40-year-old homosexual man presented to the hospital with fever, cough, and an erythematous rash. He had been followed in clinic with AIDS-related complex with lymphadenopathy, thrush, lymphopenia, anergy, diarrhea, and a positive antibody test to human immunodeficiency virus. At the time of his acute terminal illness he had a temperature of 38.5° C and had a diffuse, erythematous pruritic rash over the trunk and upper legs. The admission chest radiograph was interpreted as normal. On the second hospital day, the patient became delirious, had a worsening cough, and developed severe dyspnea. Arterial blood gases on room air revealed a pH of 7.50, pCO₂ of 30, and a pO₂ of 44. Chest radiograph now revealed bilateral diffuse reticulonodular infiltrates. He was started on sulfatrimethoprim but

had a respiratory arrest and died. Postmortem examination revealed CMV pneumonia without evidence of pneumocystis. Lung viral cultures rapidly grew CMV, with the cytopathic effect being present the second day.

Comment. Explosive illness in a patient with ARC revealed only CMV at autopsy and on viral culture of the lung.

References

1. Foy HM, Cooney MK, McMahan R, Grayston JT: Viral and mycoplasmal pneumonia in a prepaid medical care group during an eight-year period. *Am J Epidemiol* 97:93-102, 1973.
2. Aiello LF, Luby JP: Primary atypical pneumonia in a family due to concomitant *Mycoplasma pneumoniae* and adenovirus type 7 infection. *Am J Dis Child* 128:874-877, 1974.
3. Glezen WP: Viral pneumonia as a cause and result of hospitalization. *J Infect Dis* 147:765-770, 1983.
4. Baine WB, Luby JP, Martin SM: Severe illness with influenza B. *Am J Med* 68:181-189, 1980.
5. Berntsson E, Lagergard T, Strannegard O, Trollfors B: Etiology of community-acquired pneumonia in out-patients. *Eur J Clin Microbiol* 5:446-447, 1986.
6. Dorff GJ, Rytel MW, Farmer SG, Scanlon G: Etiologies and characteristic features of pneumonias in a municipal hospital. *Am J Med Sci* 266:349-358, 1973.
7. Berntsson E, Blomberg J, Lagergard T, Trollfors B: Etiology of community-acquired pneumonia in patients requiring hospitalization. *Eur J Clin Microbiol* 4:268-272, 1985.
8. McNabb WR, Williams TDM, Shanson DC, Lant AF: Adult community-acquired pneumonia in central London. *J R Soc Med* 77:550-555, 1984.
9. Paun L, Antipa C, Barnaure F, Parvu C, Iacobescu V, Baltien A, Erscouiu S, Ceausu E, Popescu E, Dumitrescu I, Duiculescu D, Stoiian N, Peulescu P: Virological investigations in adults with acute pneumonia. *Rev Roum Med Virol* 37:23-28, 1986.
10. Macfarlane JT, Ward MJ, Finch RG, Macrae AD: Hospital study of adult community-acquired pneumonia. *Lancet* 2:255-258, 1982.
11. Prout S, Potgieter PD, Forder AA, Moodie JW, Matthews J: Acute community-acquired pneumonias. *S Afr Med J* 64:443-446, 1983.
12. Reimann HA: An acute infection of the respiratory tract with atypical pneumonia. A disease entity probably caused by a filtrable virus. *JAMA* 251:936-944, 1984.
13. Marrie TJ, Haldane EV, Noble MA, Faulkner RS, Martin RS, Lee SHS: Causes of atypical pneumonia: Results of a 1-year prospective study. *Can Med Assoc J* 125:1118-1123, 1981.
14. Ponka A, Sarna S: Differential diagnosis of viral, mycoplasmal and bacteraemic pneumococcal pneumonias on admission to hospital. *Eur J Respir Dis* 64:360-368, 1983.
15. Macfarlane JT, Miller AC, Smith WHR, Morris AH, Rose DH: Comparative radiographic features of community acquired Legionnaires' disease, pneumococcal pneumonia, mycoplasma pneumonia, and psittacosis. *Thorax* 39:28-33, 1984.
16. Ford MJ, Brunton WAT, Millar J, Stewart C, Critchley JAJH: Mycoplasma pneumonia: Failure of erythromycin therapy. *Scott Med J* 25:126-128, 1980.
17. Fraser RG, Pare JAP: Lung infections caused by viruses, *Mycoplasma pneumoniae*, and rickettsiae. in Fraser RG, Pare JAP (eds): *Diagnosis of Diseases of the Chest*. Philadelphia, W.B. Saunders, 1978 Second Edition. pp 814-852.
18. Spencer H: Pneumonias due to rickettsiae, chlamydiae, viruses and mycoplasma. in *Pathology of the Lung*. Oxford, Pergamon Press, 1985 Fourth Edition. pp 213-259.
19. Bayer AS, Galpin JE, Theofilopoulos AN, Guze LB: Neurologic disease associated with *Mycoplasma pneumoniae* pneumonitis. Demonstration of viable *Mycoplasma pneumoniae* in cerebrospinal fluid and blood by radioisotopic and immunofluorescent tissue culture techniques. *Ann Intern Med* 94:15-20, 1981.
20. Rollins S, Colby T, Clayton F: Open lung biopsy in *Mycoplasma pneumoniae* pneumonia. *Arch Pathol Lab Med* 110:34-41, 1986.
21. Balassanian N, Robbins FC: *Mycoplasma pneumoniae* infection in families. *N Engl J Med* 277:719-725, 1967.
22. Hanukoglu A, Hebroni S, Fried D: Pulmonary involvement in *Mycoplasma pneumoniae* infection in families. *Infection* 14:1-6, 1986.
23. Ali NJ, Sillis M, Andrews BE, Jenkins PF, Harrison BDW: The clinical spectrum and diagnosis of *Mycoplasma pneumoniae* infection. *Q J Med* 58:241-251, 1986.
24. Izumikawa K, Hara K: Clinical features of Mycoplasmal pneumonia in adults. *Yale J Biol Med* 56:505-510, 1983.
25. Dean NL: Mycoplasmal pneumonias in the community hospital. The "unusual" manifestations become common. *Clin Chest Med* 2:121-131, 1981.
26. Cockcroft DW, Stilwell GA: Lobar pneumonia caused by *Mycoplasma pneumoniae*. *Can Med Assoc J* 124:1463-1468, 1981.
27. Finnegan OC, Fowles SJ, White RJ: Radiographic appearances of mycoplasma pneumonia. *Thorax* 36:469-472, 1981.
28. Dixon C: Mycoplasmal pneumonia and adult respiratory distress syndrome: A complication to be recognized. *J Natl Med Assoc* 73:549-552, 1981.
29. Sutherland GE, Schlichtig R: Acute respiratory failure due to atypical pneumonia. *Mo Med* 80:144-145, 1983.
30. Murray HW, Masur H, Senterfit LB, Roberts RB: The protean manifestations of *Mycoplasma pneumoniae* infection in adults. *Am J Med* 58:229-242, 1975.
31. Weekly clinicopathological exercises: Case 39-1983. *N Eng J Med* 309:782-789, 1983.
32. Ishibashi A, Ueda I, Fujita K: Pityriasis rosea gibert and *Mycoplasma pneumoniae* infection. *J Dermatol* 12:97-100, 1985.
33. Macfarlane JT, Morris MJ: Abnormalities in lung function following clinical recovery from *Mycoplasma pneumoniae* pneumonia. *Eur J Respir Dis* 63:337-341, 1982.
34. Kaufman JM, Cuvelier CA, Van Der Straeten M: Mycoplasma pneumonia with fulminant evolution into diffuse interstitial fibrosis. *Thorax* 35:140-144, 1980.
35. Coultas DB, Samet JM, Butler C: Bronchiolitis obliterans due to *Mycoplasma pneumoniae*. *West J Med* 144:471-474, 1986.
36. Goudie BM, Kerr MR, Johnson RN: Mycoplasma pneumonia complicated by bronchiectasis. *J Infect* 7:151-152, 1983.
37. Von Bonsdorff M, Ponka A, Tornroth T: Mycoplasmal pneumonia associated with mesangiocapillary glomerulonephritis Type II (Dense Deposit Disease). *Acta Med Scand* 216:427-429, 1984.
38. Kanayama Y, Shiota K, Kotumi K, Ikuno Y, Yasumoto R, Ishii M, Inoue T: *Mycoplasma pneumoniae* pneumonia associated with IgA nephropathy. *Scand J Infect Dis* 14:231-233, 1982.
39. Granato PA, Poe L, Weiner LB: New York City medium for enhanced recovery of *Mycoplasma pneumoniae* from clinical specimens. *J Clin Microbiol* 17:1077-1080, 1983.
40. Schaffner W: Chlamydia psittaci (psittacosis), in Mandell GL, Douglas RG Jr, Bennett JE (eds): *Principles and Practice of Infectious Diseases*. New York, John Wiley and Sons, 1985 Second Edition. pp 1061-1063.
41. Kuritsky JN, Shmid GP, Potter ME, Anderson DC, Kaufmann AF: Psittacosis. A diagnostic challenge. *J Occup Med* 26:731-733, 1984.
42. Tack KJ, Peterson PK, Rasp FL, O'Leary M, Hanto D, Simmons RL, Sabath LD: Isolation of *Chlamydia trachomatis* from the lower respiratory tract of adults. *Lancet* 1:116-120, 1980.
43. Komaroff AL, Aronson MD, Schachter J: *Chlamydia trachomatis* infection in adults with community-acquired pneumonia. *JAMA* 245:1319-1322, 1981.
44. Edelman RR, Hann LE, Simon M: *Chlamydia trachomatis* pneumonia in adults: radiographic appearance. *Radiology* 152:279-282, 1984.

45. Saikku P, Wang SP, Kleemola M, Brander E, Rusanen E, Grayston JT: An epidemic of mild pneumonia due to an unusual strain of *Chlamydia psittaci*. *J Infect Dis* 151:832-839, 1985.
46. Grayston JT, Kuo C-C, Wang S-P, Altman J: A new *Chlamydia psittaci* strain, TWAR, isolated in acute respiratory tract infections. *N Engl J Med* 315:161-168, 1986.
47. Bryant RE, Rhoades ER: Clinical features of adenoviral pneumonia in Air Force recruits. *Am Rev Respir Dis* 96:717-723, 1967.
48. Leers W-D, Sarin MK, Kasupski GJ: Lobar pneumonia associated with adenovirus type 7. *Can Med Assoc J* 125:1003-1004, 1981.
49. Dudding BA, Wagner SC, Zeller JA, Gmelich JT, French GR, Top FH Jr: Fatal pneumonia associated with adenovirus type 7 in three military trainees. *N Engl J Med* 286:1289-1292, 1972.
50. Loker EF Jr, Hodges GR, Kelly DJ: Fatal adenovirus pneumonia in a young adult associated with ADV-7 vaccine administered 15 days earlier. *Chest* 66:197-199, 1974.
51. Myerowitz RL, Stalder H, Oxman MN, Levin MJ, Moore M, Leith JD, Gantz NM, Pellegrini J, Hierholzer JC: Fatal disseminated adenovirus infection in a renal transplant recipient. *Am J Med* 59:591-598, 1975.
52. Shields AF, Hackman RC, Fife KH, Corey L, Meyers JD: Adenovirus infections in patients undergoing bone-marrow transplantation. *N Engl J Med* 312:529-533, 1985.
53. Siegal FP, Dikman SH, Arayata RB, Bottone EJ: Fatal disseminated adenovirus 11 pneumonia in an agammaglobulinemic patient. *Am J Med* 71:1062-1067, 1981.
54. Ellenbogen C, Graybill JR, Silva J, Homme PJ: Bacterial pneumonia complicating adenoviral pneumonia. *Am J Med* 56:169-177, 1974.
55. Lang WR, Howden CW, Laws J, Burton JF: Bronchopneumonia with serious sequelae in children with evidence of adenovirus type 21 infection. *Br Med J* 1:73-79, 1969.
56. Pearson RD, Hall WJ, Menegus MA, Douglas RG Jr: Diffuse pneumonitis due to adenovirus type 21 in a civilian. *Chest* 78:107-109, 1980.
57. Morgan PN, Moses EB, Fody EP, Barron AL: Association of adenovirus type 16 with Reye's-syndrome-like illness and pneumonia. *South Med J* 77:827-830, 1984.
58. Lehtomaki K, Julkunen I, Sandelin K, Salonen J, Virtanen M, Ranki M, Hovi T: Rapid diagnosis of respiratory adenovirus infections in young adult men. *J Clin Microbiol* 24:108-111, 1986.
59. Carfrae DC, Bell EJ, Grist NR: Fatal haemorrhagic pneumonia in an adult due to respiratory syncytial virus and *Staphylococcus aureus*. *J Infect* 4:79-80, 1982.
60. Spelman DW, Stanley PA: Respiratory syncytial virus pneumonitis in adults. *Med J Aust* 1:430-431, 1983.
61. Kasupski GJ, Leers W-D: Case report: Presumed respiratory syncytial virus pneumonia in three immunocompromised adults. *Am J Med Sci* 285:28-33, 1983.
62. Sorvillo FJ, Huie SF, Strassburg MA, Butsumyo A, Shandera WX, Fannin SL: An outbreak of respiratory syncytial virus pneumonia in a nursing home for the elderly. *J Infect* 9:252-256, 1984.
63. Hall CB, McBride JT, Gala CL, Hildreth SW, Schnabel KC: Ribavirin treatment of respiratory syncytial viral infection in infants with underlying cardiopulmonary disease. *JAMA* 254:3047-3051, 1985.
64. Taber LH, Knight V, Gilbert BE, McClung HW, Wilson SZ, Norton HJ, Thurson JM, Gordon WH, Atmar RL, Schlaudt WR: Ribavirin aerosol treatment of bronchiolitis due to respiratory syncytial virus infection in infants. *Pediatrics* 72:613-618, 1983.
65. Riski H, Hovi T: Coronavirus infections of man associated with diseases other than the common cold. *J Med Virol* 6:259-265, 1980.
66. Francis T Jr: Influenza: the new acquaintance. *Ann Intern Med*; 39:203-221, 1953.
67. Kingsbury DW: Orthomyxo- and paramyxoviruses and their replication, in Fields BN (ed): *Virology*. New York, Raven Press, 1985 First Edition. p 1157.
68. Johanson WG Jr, Pierce AK, Sanford JP: Pulmonary function in uncomplicated influenza. *Am Rev Respir Dis* 100:141-146, 1969.
69. Hall WJ, Douglas RG Jr, Hyde RW, Roth FK, Cross AS, Speers DM: Pulmonary mechanics after uncomplicated influenza A infection. *Am Rev Respir Dis* 113:141-147, 1976.
70. Luria DB, Blumenfeld HL, Ellis JT, Kilbourne ED, Rogers DE: Studies on influenza in the pandemic of 1957-1958. II. Pulmonary complications of influenza. *J Clin Invest* 38:214-265, 1959.
71. Burk RF, Schaffner W, Koenig MG: Severe influenza virus pneumonia in the pandemic of 1968-1969. *Arch Intern Med* 127:1122-1128, 1971.
72. Riski H, Alanko K: Mycoplasma and influenza pneumonia in a series of 214 adults. *Scand J Resp Dis* (suppl) 89:235-245, 1974.
73. Douglas RG Jr, Alford RH, Cate TR, Couch RB: The leukocyte response during viral respiratory illness in man. *Ann Intern Med* 64:521-530, 1966.
74. Finland M, Parker F Jr, Barnes MW, Joliffe LS: Acute myocarditis in influenza A infections. Two cases of non-bacterial myocarditis, with isolation of virus from the lungs. *Am J Med Sci* 209:455-468, 1945.
75. Kort BA, Cefalo RC, Baker VV: Fatal influenza A pneumonia in pregnancy. *Am J Perinatol* 3:179-182, 1986.
76. Keane WR, Helderman JH, Luby J, Gailiunas P, Hull A, Kokko JP: Epidemic renal transplant rejection associated with influenza A Victoria. *Proc Dial Transplant Forum* 8:232-236, 1978.
77. Bogart DB, Liu C, Ruth WE, Kerby GR, Williams CH: Rapid diagnosis of primary influenza pneumonia. *Chest* 68:513-517, 1975.
78. Horadam VW, Sharp JG, Smilack JD, McAnalley BH, Garriott JC, Stephens MK, Prati RC, Brater DC: Pharmacokinetics of amantadine hydrochloride in subjects with normal and impaired renal function. *Ann Intern Med* 94:454-458, 1981.
79. Knight V, McClung HW, Wilson SZ, Waters BK, Quarles JM, Cameron RW, Greggs SE, Zerwas JM, Couch RB: Ribavirin small-particle aerosol treatment of influenza. *Lancet* 2:945-949, 1981.
80. Gilbert BE, Wilson SZ, Knight V, Couch RB, Quarles JM, Dure L, Hayes N, Willis G: Ribavirin small-particle aerosol treatment of infections caused by influenza virus strains A/Victoria/7/83 (H1N1) and B/Texas/1/84. *Antimicrob Agents Chemother* 27:309-313, 1985.
81. Olson RW, Hodges GR: Measles pneumonia. Bacterial superinfection as a complicating factor. *JAMA* 232:363-365, 1975.
82. Gremillion DH, Crawford GE: Measles pneumonia in young adults. An analysis of 106 cases. *Am J Med* 71:539-542, 1981.
83. Enders JF, McCarthy K, Mitus A, Cheatham WJ: Isolation of measles virus at autopsy in cases of giant-cell pneumonia without rash. *N Engl J Med* 261:875-881, 1959.
84. Triebwasser JH, Harris RE, Bryant RE, Rhoades ER: Varicella pneumonia in adults. Report of seven cases and a review of literature. *Medicine* 46:409-423, 1967.
85. Meyer B, Stalder H, Wegmann W: Persistent pulmonary granulomas after recovery from varicella pneumonia. *Chest* 89:457-459, 1986.
86. Harris RE, Rhoades ER: Varicella pneumonia complicating pregnancy. Report of a case and review of literature. *Obstet Gynecol* 25:734-740, 1965.
87. Shepp DH, Dandliker PS, Meyers JD: Treatment of varicella-zoster virus infection in severely immunocompromised patients. *N Engl J Med* 314:208-212, 1986.
88. Vilde JL, Bricaire F, Lepout C, Renaudie M, Brun-Vezinet F:

- Comparative trial of acyclovir and vidarabine in disseminated varicella-zoster infections in immunocompromised patients. *J Med Virol* 20:127-134, 1986.
89. Ramsey PG, Fife KH, Hackman RC, Meyers JD, Corey L: Herpes simplex virus pneumonia. Clinical, virologic, and pathologic features in 20 patients. *Ann Intern Med* 97:813-820, 1982.
90. O'Donohue WJ Jr, Polly SM, Angelillo VA: Diffuse pneumonia and acute respiratory failure due to infectious mononucleosis. *Nebr Med J* 66:245-247, 1981.
91. Andiman WA, McCarthy P, Markowitz RI, Cormier D, Horstmann DM: Clinical, virologic, and serologic evidence of Epstein-Barr virus infection in association with childhood pneumonia. *J Pediatr* 99:880-886, 1981.
92. Idell S, Johnson M, Beauregard L, Learner N: Pneumonia associated with rising cytomegalovirus antibody titres in a healthy adult. *Thorax* 38:957-958, 1983.
93. Marrie TJ, Janigan DT, Haldane EV, Faulkner RS, Kwan C, Durant H: Does cytomegalovirus play a role in community-acquired pneumonia? *Clin Invest Med* 8:286-295, 1985.
94. Beschorner WE, Hutchins GM, Burns WH, Saral R, Tutschka PJ, Santos GW: Cytomegalovirus pneumonia in bone marrow transplant recipients: miliary and diffuse patterns. *Am Rev Respir Dis* 122:107-114, 1980.
95. Appelbaum FR, Meyers JD, Fefer A, Flournoy N, Cheever MA, Greenberg PD, Hackman R, Thomas ED: Nonbacterial nonfungal pneumonia following marrow transplantation in 100 identical twins. *Transplantation* 33:265-268, 1982.
96. Luby JP, Ware AJ, Hull AR, Helderman JH, Gailunas P, Butler S, Atkins C: Disease due to cytomegalovirus and its long-term consequences in renal transplant recipients. Correlation of allograft survival with disease due to cytomegalovirus and rubella antibody level. *Arch Intern Med* 143:1126-1129, 1983.
97. Simmons RL, Matas AJ, Rattazzi LC, Balfour HH Jr, Howard RJ, Najarian JS: Clinical characteristics of the lethal cytomegalovirus infection following renal transplantation. *Surgery* 82:537-546, 1977.
98. Abdallah PS, Mark JBD, Merigan TC: Diagnosis of cytomegalovirus pneumonia in compromised hosts. *Am J Med* 61:326-332, 1976.
99. Shepp DH, Dandliker PS, de Miranda P, Burnette TC, Cederberg DM, Kirk LE, Meyers JD: Activity of 9-[2-Hydroxy-1-(hydroxymethyl)-ethoxymethyl]guanine in the treatment of cytomegalovirus pneumonia. *Ann Intern Med* 103:368-373, 1985.