

Kounis syndrome leading to triple-vessel coronary artery ischaemia due to simultaneous coronary spasm, plaque erosion, and multiple stent thrombosis: a case report

Hiroyuki Yamamoto ^{1,2}, Hiromasa Otake ^{1*}, Kosuke Tanimura¹, and Ken-ichi Hirata¹

¹Division of Cardiovascular Medicine, Department of Internal Medicine, Kobe University Graduate School of Medicine, 7-5-1 Kusunoki-cho, Chuo-ku, Kobe 6500017, Japan; and ²Division of Cardiovascular Medicine, Hyogo Brain and Heart Center, Himeji 670-0981, Japan

Received 11 October 2021; first decision 30 November 2021; accepted 20 April 2022

Background

Kounis syndrome (KS) is an acute coronary syndrome (ACS) induced by allergic reactions. Currently, there are three variants of KS based on the mechanism and onset of ACS. We report a rare case of KS, wherein ACS was caused by all KS variants.

Case summary

A 68-year-old man with a history of percutaneous coronary intervention (PCI) for ST-segment elevation myocardial infarction of the left anterior descending artery 16 days ago underwent a staged PCI for the mid-left circumflex artery (LCx) stenosis under optical coherence tomography (OCT) guidance using low-molecular-weight dextran (LMWD). During OCT examination, the LMWD induced an anaphylactic reaction. The patient was immediately administered medications to manage the anaphylaxis; however, he complained of chest discomfort. Coronary angiography and subsequent intravascular ultrasound revealed a newly developed coronary thrombus in the proximal LCx. Furthermore, coronary spasm or multiple stent thromboses occurred sequentially in all coronary arteries, resulting in triple-vessel coronary artery ischaemia. Balloon angioplasty was performed under intra-aortic balloon pumping, which could rescue the patient. The patient was discharged without any complications 11 days post-KS, under a 7-day anti-histamine regimen. No further cardiovascular events had occurred by 1-year follow-up.

Discussion

This case documented the clinical course of KS caused by LMWD, wherein all KS variants occurred sequentially. Early recognition of KS and appropriate management with anaphylaxis medication and balloon angioplasty under mechanical circulatory support effectively prevent vascular morbidity. Interventionalists should be aware of this rare and serious complication of PCI.

Keywords

Case report • Kounis syndrome • Coronary spasm • Plaque erosion • Stent thrombosis • Low-molecular-weight dextran • Percutaneous coronary intervention

ESC Curriculum

2.1 Imaging modalities • 3.1 Coronary artery disease • 3.2 Acute coronary syndrome • 7.1 Haemodynamic instability

* Corresponding author: Tel: +81 78 382 5111, Fax: +81 78 382 5859, Email: hotake@med.kobe-u.ac.jp

For the podcast associated with this article, please visit <https://academic.oup.com/ehjcr/pages/podcast>

Handling Editor: Farshad Farouzanmehr

Peer-reviewers: Andreas Mitsis and Sherif Mohammad Abd ElSamad

Compliance Editor: Rayhan Noah Saiani

Supplementary Material Editor: Ayse Djahit

© The Author(s) 2022. Published by Oxford University Press on behalf of the European Society of Cardiology.

This is an Open Access article distributed under the terms of the Creative Commons Attribution-NonCommercial License (<https://creativecommons.org/licenses/by-nc/4.0/>), which permits non-commercial re-use, distribution, and reproduction in any medium, provided the original work is properly cited. For commercial re-use, please contact journals.permissions@oup.com

Learning points

- Low-molecular-weight dextran use during optical coherence tomography may induce anaphylaxis and concomitant fulminant Kounis syndrome.
- Direct exposure to allergic insults can lead to coronary thrombus formation in the treated vessel, and subsequent systemic reactions might lead to coronary spasm and/or in-stent thrombosis in all coronary arteries, which could potentially lead to triple-vessel coronary ischaemia.

Introduction

Kounis syndrome (KS) is a rare but significant cause of acute coronary syndrome (ACS) that results from allergic reactions to various triggers. The consequent release of inflammatory mediators and platelet hyperactivity are integral to its development.^{1,2} Currently, KS is classified into three variants based on the mechanism and onset of ACS. Type-1 represents ACS due to coronary spasm in a non-atherogenic coronary artery, Type-2 represents ACS due to plaque rupture or erosion in patients with pre-existing coronary atheroma, while Type-3 represents ACS due to stent thrombosis.^{2,3} We describe a rare case of KS wherein all variants occurred sequentially during a staged percutaneous coronary intervention (PCI), 16 days after the treatment of ST-segment elevation myocardial infarction (STEMI).

Timeline

Sixteen days before	Primary percutaneous coronary intervention (PCI) for acute ST-segment elevation myocardial infarction of the proximal left ascending artery (LAD) was performed.
0:00, a staged-PCI started	A staged PCI of the mid-left circumflex artery (LCx) was performed. Coronary angiogram (CAG) prior to PCI showed no abnormal findings in the LAD stents.
0:37, Type-2 KS	Optical coherence tomography using low-molecular-weight dextran was first performed.
0:38, allergic reaction	Erythematous rash with generalised pruritus was confirmed, and his blood pressure dropped to 70 mmHg.
0:44, chest pain	The patient complained of chest discomfort, and CAG revealed newly developed luminal narrowing of the proximal LCx.
1:02, Type-1 KS	CAG showed a totally occluded non-atherosclerotic right coronary artery (RCA). Multiple nitrate injections into the RCA improved its coronary flow.
1:22, Type-3 KS	CAG and intravascular ultrasound showed acute in-stent thrombus occlusion both in the LCx and diagonal branch. Balloon angioplasty under intra-aortic balloon pumping (IABP) support improved the coronary artery flow.
3:00, final CAG	Final CAG confirmed optimal coronary flow in all coronary arteries.
Day 1	IABP was removed.
Day 11	The patient was discharged without any disabilities.
One year later	No further cardiovascular events had occurred.

Case summary

A 68-year-old East Asian male smoker with a medical history of hypertension, dyslipidaemia, and chronic kidney disease presented with persistent chest discomfort for 2 hours. The patient was haemodynamically stable with a blood pressure of 110/70 mmHg and a heart rate of 75 beats/min. Physical examination findings revealed no abnormality. Electrocardiogram showed ST-segment elevation in the anterior leads (*Figure 1A*). Emergent coronary angiogram (CAG) through the right femoral artery (FA) showed double-vessel coronary artery disease with acute occlusion of the proximal left anterior descending artery (LAD). Consequently, primary PCI was performed for the culprit lesion. After reperfusion, remarkable stenosis of the diagonal branch was observed. Because the diagonal coronary flow was not sufficiently maintained after the single-stent strategy for the proximal LAD, culotte stenting was conducted as a bailout method, using two everolimus-eluting stents (EESs) for the proximal LAD (EES: 3.0/33 mm) and diagonal branch (EES: 2.5/23 mm). This approach achieved optimal results (*Figure 1B–1D*). The total contrast amount used during the procedure was 105 mL, and the patient's serum creatinine level (1.35 mg/dL) (reference range, 0.52–1.02 mg/dL) and estimated glomerular filtration rate (eGFR) (41.8 mL/min/1.73 m²) (reference range, >60 mL/min/1.73 m²) remained unchanged after the primary PCI. The maximal creatinine kinase (CK) and CK-myocardial band (CK-MB) levels were 2465 IU/L (reference range, 56–244 IU/L) and 300 IU/L (reference range, <5 IU/L) respectively. The patient was treated with dual-antiplatelet therapy consisting of aspirin (loading dose, 200 mg; maintenance dose, 100 mg/day) and prasugrel (loading dose, 20 mg; maintenance dose, 3.75 mg/day) as per Japanese guidelines.⁴ The patient was generally well, and no signs of any allergic reaction were noted.

Sixteen days later, a staged PCI through the right radial artery was performed to treat the mid-left circumflex artery (LCx) stenosis under optical coherence tomography (OCT) guidance (*Figure 2A*). After implanting an EES (2.5/28 mm) in the culprit lesion, the first OCT examination was performed using low-molecular-weight dextran (LMWD) to reduce the amount of contrast used (*Figure 2B and 2C*). Shortly after that, the patient developed an erythematous rash with generalized pruritus, and his systolic blood pressure dropped to 70 mmHg. An anaphylactic reaction to LMWD was suspected; therefore, intravenous fluid therapy and concomitant intravenous antihistamines (chlorpheniramine 5 mg and famotidine 20 mg) and corticosteroids (hydrocortisone 100 mg) were administered immediately. However, he complained of chest discomfort, and subsequent CAG revealed a newly developed luminal narrowing of the proximal LCx (*Figure 2D*). Angioplasty of the proximal LCx with a 2.0 mm compliant balloon improved the coronary flow.

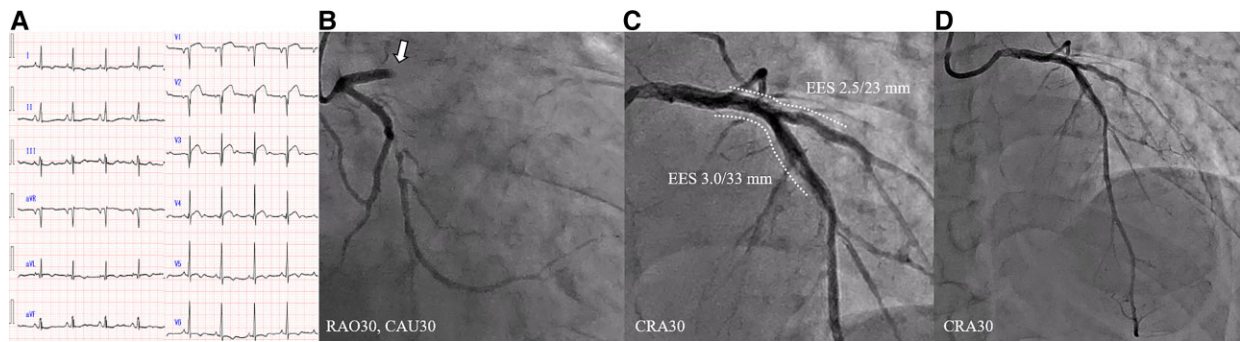


Figure 1 (A) Electrocardiogram showing ST-segment elevation in the anterior leads. Coronary angiograms: (B) initial, (a white arrow indicates the culprit lesion), (C) post-stenting using two everolimus-eluting stents (EESs), (D) final.

Intravenous ultrasound (IVUS) confirmed a newly developed intracoronary thrombus due to plaque erosion in the proximal LCx. This suggested KS Type-2 (Figure 2E and F). Despite a significant improvement in the LCx flow, his electrocardiogram showed ST-segment elevation in the inferior leads. Coronary angiogram through the right FA confirmed a totally occluded non-atherosclerotic right coronary artery (RCA). Multiple nitrate

injections to the RCA improved coronary flow. This suggested KS Type-1 (Figure 3). After 20 min, his electrocardiogram showed ST-segment elevation in the lateral leads. Coronary angiogram revealed acute in-stent occlusion of the LCx and diagonal branch, as well as a hazy appearance in the LAD stent, for which additional IVUS-guided PCI was performed (Figure 4A–4D). Intravenous ultrasound confirmed multiple thrombi formation inside the stents,

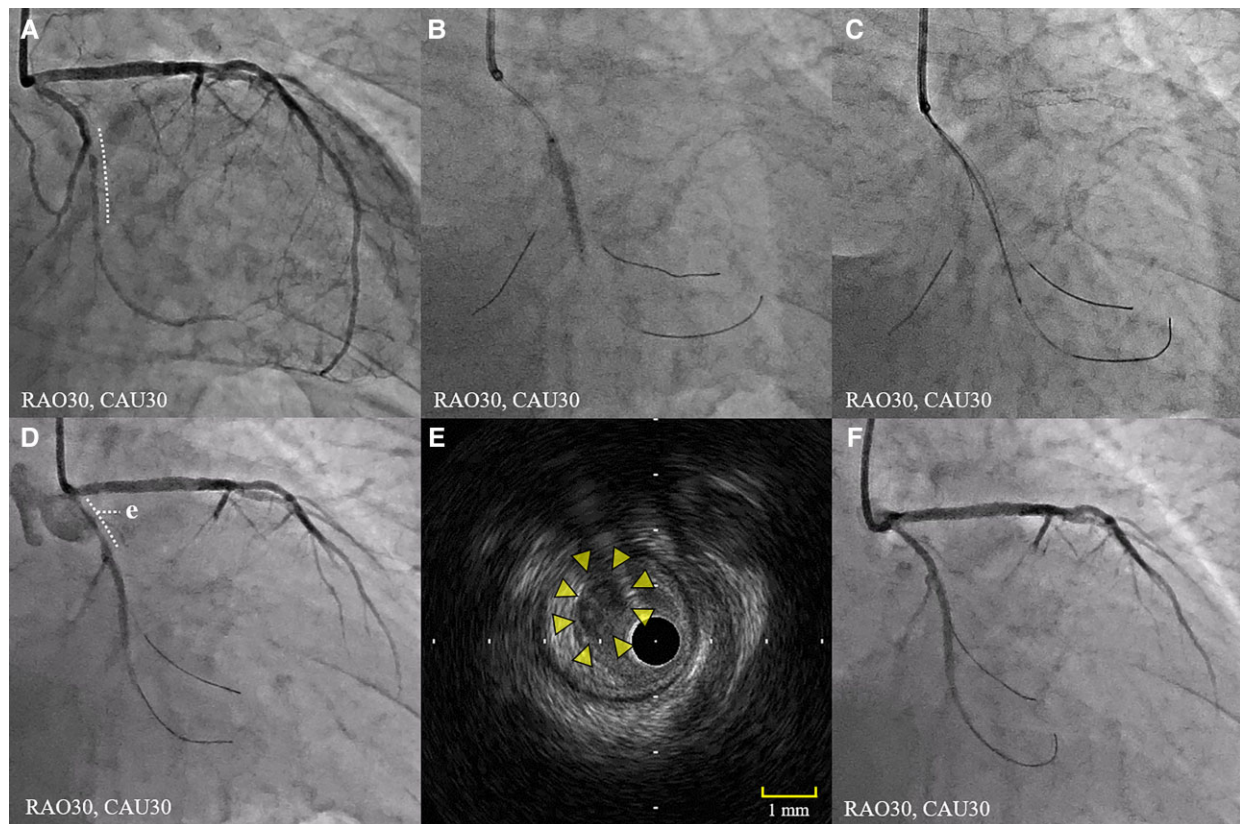


Figure 2 Coronary angiogram: (A) pre-percutaneous coronary intervention for the mid-left circumflex artery (LCx) stenosis (dotted line), (B) stent implantation, (C) optical coherence tomography using low-molecular-weight dextran, (D) newly developed luminal narrowing of the proximal LCx. (E) Intravascular ultrasounds suggesting coronary thrombus without plaque rupture (arrowheads). (F) Coronary angiogram post-improved LCx flow.

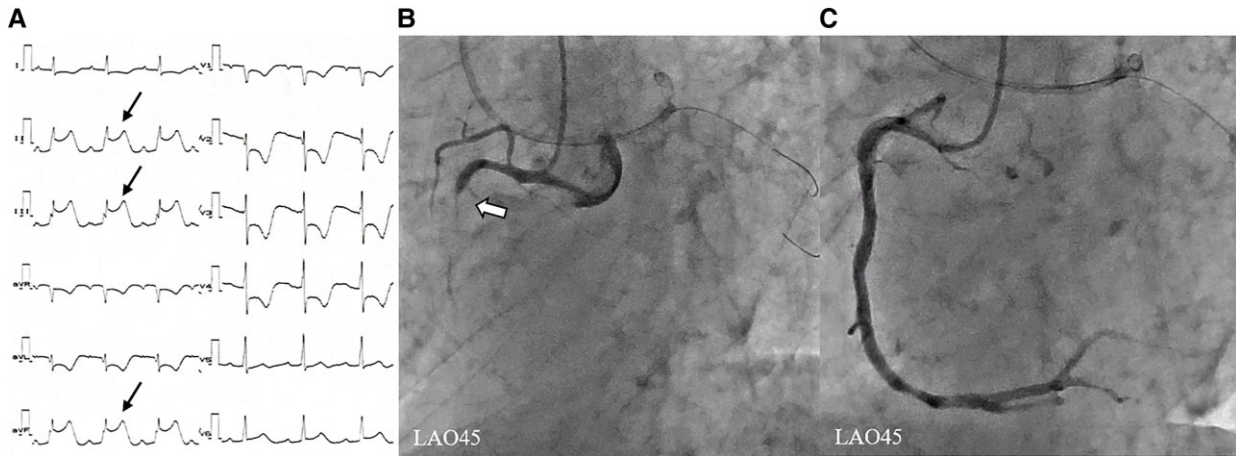


Figure 3 (A) Electrocardiogram showing ST-segment elevation in the inferior leads (arrows). Coronary angiogram: (B) a totally occluded right coronary artery (RCA) (a white arrow), (C) post-improved RCA flow after multiple nitrate infusions.

suggestive of KS Type-3. (Figure 4E). Intra-aortic balloon pumping (IABP) was immediately initiated to stabilize the haemodynamics and improve the coronary flow. Despite the adequately controlled activated clotting time (>250 s), the in-stent thrombi progressed over time. Considering the possibility of heparin-induced thrombocytopenia (HIT), the anticoagulant agent used during PCI was switched from unfractionated heparin to argatroban (a direct thrombin inhibitor) as per Japanese guidelines (whereas bivalirudin or other anticoagulants such as glycoprotein IIB-IIIa inhibitors should be used

in Europe).^{4,5} Following thromboaspiration performed using an aspiration device (Thrombuster III GR; Kaneka, Osaka, Japan) and balloon angioplasty with perfusion balloons (Ryusei; Kaneka, Osaka, Japan), the coronary flow had adequately improved (Figure 4F–4H). Laboratory blood test results after the KS event reflected myocardial damage (maximal CK/CK-MB levels were 1843 IU/L and 217 IU/L, respectively), notable inflammation [maximal C-reactive protein level was 15.1 mg/dL (reference range, <0.3 mg/dL) and white blood cell counts increased to 32 200/ μ L (reference range, 4000–9000/ μ L),

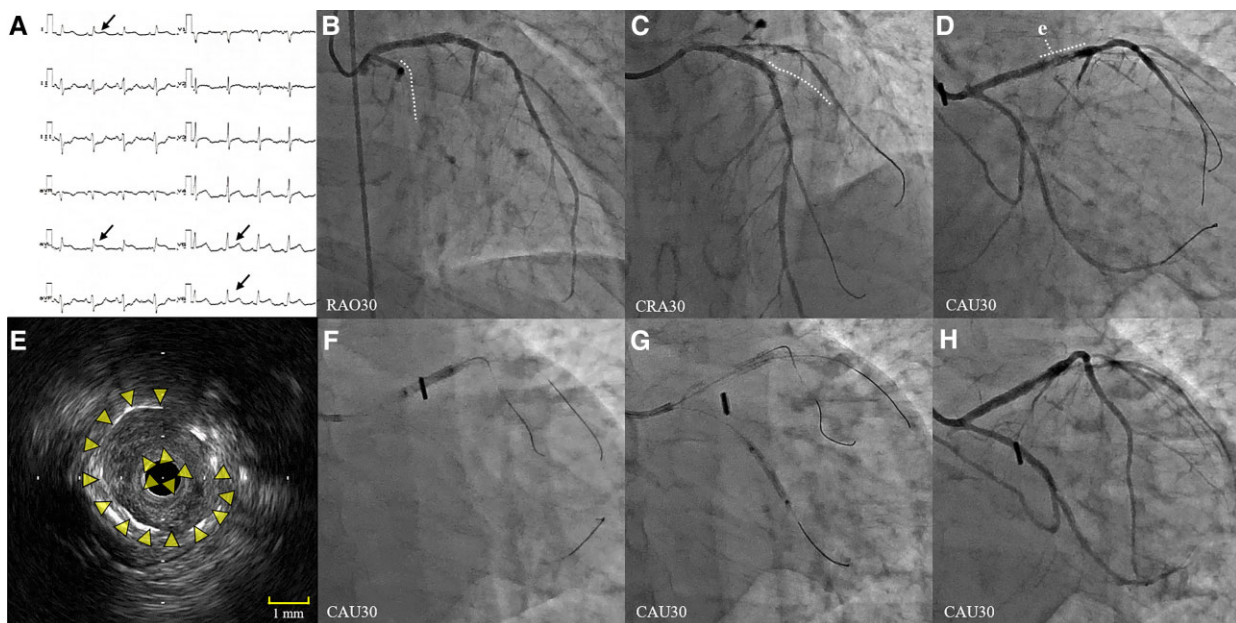


Figure 4 (A) Electrocardiogram showing ST-segment elevation in the lateral leads (arrows). Coronary angiogram: (B) acute in-stent occlusion (dotted line), (C) subacute in-stent occlusion (dotted line), (D) a hazy appearance of the left anterior descending artery (LAD) stent. (E) Intravascular ultrasound shows a stent thrombus in the LAD (arrowheads). (F, G) Angioplasty with perfusion balloons. (H) Final coronary angiogram.

with eosinophils at 1545/ μL (reference range, $<500/\mu\text{L}$), monocytes at 2898/ μL (reference range, $<800/\mu\text{L}$), and basophils at 966/ μL (reference range, $<300/\mu\text{L}$), and thrombocytosis [platelet count increased to $40.8 \times 10^4/\mu\text{L}$ from $28.3 \times 10^4/\mu\text{L}$ (reference range, $15\text{--}35 \times 10^4/\mu\text{L}$)]. The P2Y12 reaction units (PRUs) measured by the VerifyNow assay during the KS event had a low value of 199 (therapeutic range <220). Additional blood examinations ruled out coagulation disorders, including HIT. The drug-induced lymphocyte stimulation test did not reveal the precise allergic cause. The IABP was successfully removed the following day. Although the total contrast amount used in the staged PCI and KS event was 90 mL, his renal function did not worsen (creatinine level of 1.21 mg/dL, and eGFR of 47.1 mL/min/1.73 m²). The patient was discharged without any complications 11 days post-KS, under a 7-day anti-histamine regimen. No further cardiovascular events had occurred by 1-year follow-up.

Discussion

Kounis syndrome is an allergy-related ACS, caused by mast cell degranulation and release of inflammatory mediators.^{1,6} Although multiple KS variants can theoretically occur simultaneously, such a phenomenon has not been reported. This case is the first to document the clinical course of KS wherein all variants occurred sequentially within a short interval during PCI. Most KS cases reportedly occur within an hour of allergen exposure.⁴ Based on this characteristic, the LMWD was the most likely trigger of KS in this case. Low-molecular-weight dextran has been used in OCT-guided PCI as an alternate contrast agent for removing blood during OCT.⁷ The incidence of dextran-induced anaphylactoid reactions is reportedly low (0.6%), and KS ensuing during OCT while using LMWD is extremely rare.^{8–10} In this case, multiple KS variants occurred within 45 min of anaphylaxis. First, the immediate local reaction caused by direct exposure to LMWD led to coronary spasm and thrombus formation in the target artery. Subsequently, remarkable inflammation and thrombocytosis after the KS were observed, which suggested that the systemic reaction due to inflammation and platelet hyperactivity might be associated with coronary spasm or stent thrombus in all coronary arteries.⁶ Low-molecular-weight dextran-related KS rarely occurs; however, interventionalists should be cognizant of the fact that direct infusion of allergens into the coronary artery can result in the development of multiple KS variants.

The haemodynamic instability in KS is hypothesized to be due to anaphylactic shock with extensive peripheral vasodilation and resulting redistribution. Furthermore, myocardial hypoperfusion with or without myocardial suppression may ensue, potentially leading to cardiogenic shock.^{11,12} Therefore, the therapeutic goals for KS are both to suppress anaphylaxis and to improve coronary flow. In all KS variants, the management of anaphylaxis should be performed immediately. H1/H2-antihistaminic drugs and corticosteroids can effectively suppress histamine-related allergic reactions and inflammation due to mast cells, respectively.⁶ Rapid administration of intravenous fluid therapy and careful usage of intramuscular or intravenous epinephrine are recommended to stabilize the haemodynamic status. Although PCI is effective against both Type-2 and Type-3 KS variants, additional thrombi-related complications due

to activated platelet aggregation should be avoided. In our case, acute and subacute stent thrombosis were successfully treated with balloon angioplasty under IABP support. Furthermore, Type-3 KS was reportedly associated with late stent thrombosis in older stents with uncovered struts or evaginations.¹³ Thus, KS-induced platelet aggregation can cause stent thrombosis in both newly implanted stents and old stents with poor healing. Additional stent implantation needs to be avoided in such settings, and immediate mechanical circulatory support can be effective to stabilize the haemodynamics in KS-related thrombi. Low-dose prasugrel (3.75 mg/day) was used as a component of dual-antiplatelet therapy in this case. Recent studies suggested that low-dose prasugrel might not be sufficiently effective for thrombogenic complications compared with standard-dose clopidogrel (75 mg/day) even in East Asian populations.^{14,15} Although PRU in this case showed adequate suppression of platelet aggregation, low-dose prasugrel might not prevent KS-related thrombogenic events. We should keep in mind that KS can lead to serious coronary events, especially in cases wherein multiple stents are implanted, and early recognition and appropriate management of KS during PCI are needed to avoid further vascular morbidity.

Lead author biography



Dr. Hiroyuki Yamamoto received his license to practice medicine at Kobe University in 2010 and completed a Ph.D. in the Kobe University Graduate School of Medicine in 2019. He currently works as a physician in the field of interventional cardiology at the Hyogo Brain and Heart Center in Japan. His main areas of research are intravascular coronary imaging and interventional cardiology, including coronary artery disease and structural heart disease.

Acknowledgements

The authors thank all staff involved in this case for the excellent treatment.

Consent: In line with the COPE guidelines, written informed consent was obtained from the patient for the submission and publication of this case report.

Conflict of interest: None declared.

Funding: None declared.

References

1. Kounis NG, Zavras GM. Histamine-induced coronary artery spasm: the concept of allergic angina. *Br J Clin Pract* 1991;**45**:121–128.
2. Kounis NG. Kounis syndrome: an update on epidemiology, pathogenesis, diagnosis and therapeutic management. *Clin Chem Lab Med* 2016;**54**:1545–1549.
3. Tsigkas G, Chouchoulis K, Theodoropoulos K, Kounis NG, Alexopoulos D. Allergic reaction reveals a non-lethal late stent thrombosis. A new subtype of Kounis syndrome? *Int J Cardiol* 2011;**149**:281–282.
4. Kimura K, Kimura T, Ishihara M, Nakagawa Y, Nakao K, Miyauchi K, Sakamoto T, Tsujita Ki, Hagiwara Na, Miyazaki Si, Aki J, Arai H, Ishii H, Origuchi H, Shimizu W, Takemura H, Tahara Y, Morino Y, Iino K, Itoh T, Iwanaga Y, Uchida K, Endo H,

- Kongoji K, Sakamoto K, Shiomi H, Shimohama T, Suzuki A, Takahashi J, Takeuchi I, Tanaka A, Tamura T, Nakashima T, Noguchi T, Fukamachi D, Mizuno T, Yamaguchi J, Yodogawa K, Kosuge M, Kohsaka S, Yoshino H, Yasuda S, Shimokawa H, Hirayama A, Akasaka T, Haze K, Ogawa H, Tsutsui H, Yamazaki T. JCS 2018 Guideline on diagnosis and treatment of acute coronary syndrome. *Circ J* 2019;**83**:1085–1196.
5. Salter BS, Weiner MM, Trinh MA, Heller J, Evans AS, Adams DH, Fischer GW. Heparin-induced thrombocytopenia: a comprehensive clinical review. *J Am Coll Cardiol* 2016;**67**:2519–2532.
 6. Abdelghany M, Subedi R, Shah S, Kozman H. Kounis syndrome: a review article on epidemiology, diagnostic findings, management and complications of allergic acute coronary syndrome. *Int J Cardiol* 2017;**232**:1–4.
 7. Kurogi K, Ishii M, Sakamoto K, Kusaka H, Yamamoto N, Takashio S, Arima Yo, Yamamoto E, Kaikita K, Tsujita K. Minimum-contrast percutaneous coronary intervention guided by optical coherence tomography using low-molecular weight dextran. *JACC Cardiovasc Interv* 2020;**13**:1270–1272.
 8. Brown RI, Aldridge HE, Schwartz L, Henderson M, Brooks E, Coutanche M. The use of dextran-40 during percutaneous transluminal coronary angioplasty: a report of three cases of anaphylactoid reactions—one near fatal. *Cathet Cardiovasc Diagn* 1985;**11**:591–595.
 9. Akita T, Kawata M, Sakaguchi A, Kato Y, Suehiro H, Takada H, Matsuura T, Kamemura K, Hirayama Y, Adachi K, Matsuura A, Sakamoto S. Successful treatment of prolonged cardiopulmonary arrest of Kounis syndrome during coronary angioplasty. *J Cardiol Cases* 2015;**13**:47–51.
 10. Kurogi K, Ishii M, Sakamoto K, Komaki S, Kusaka H, Yamamoto N, Takashio S, Arima Y, Yamamoto E, Kaikita K, Tsujita K. Optical coherence tomography-guided percutaneous coronary intervention with low-molecular-weight dextran- effect on renal function. *Circ J* 2020;**84**:917–925.
 11. Mitsis A, Christodoulou E, Georgiou P. Coronary spasm secondary to cefuroxime injection, complicated with cardiogenic shock—a manifestation of Kounis syndrome: case report and literature review. *Eur Heart J Acute Cardiovasc Care* 2018;**7**:624–630.
 12. Kounis NG, Cervellin G, Koniari I, Bonfanti L, Dousdampanis P, Charokopos N, Assimakopoulos SF, Kakkos SK, Ntouvias IG, Soufras GD, Tsolakis I. Anaphylactic cardiovascular collapse and Kounis syndrome: systemic vasodilation or coronary vasoconstriction? *Ann Transl Med* 2018;**6**:332.
 13. Fujisaki T, Higa T, Uechi Y, Maehira N. A case report of Kounis syndrome presenting with a rash, very late stent thrombosis and coronary evaginations. *Eur Heart J Case Rep* 2020;**4**:1–5.
 14. Akita K, Inohara T, Yamaji K, Kohsaka S, Numasawa Y, Ishii H, Amano T, Kadota K, Nakamura M, Maekawa Y. Impact of reduced-dose prasugrel vs. standard-dose clopidogrel on in-hospital outcomes of percutaneous coronary intervention in 62737 patients with acute coronary syndromes: a nationwide registry study in Japan. *Eur Heart J Cardiovasc Pharmacother* 2020;**6**:231–238.
 15. Wongsalap Y, Ungsriwong S, Kumtep W, Saokaew S, Senthong V, Kengkla K. Efficacy and safety of low-dose prasugrel versus clopidogrel in patients with acute coronary syndrome undergoing percutaneous coronary intervention: a systematic review and meta-analysis. *Cardiovasc Drugs Ther* 2021. doi:10.1007/s10557-021-07202-1