

# Intracranial hypotension after syringopleural shunting in posttraumatic syringomyelia: Case report and review of the literature

Johanne C. Summers<sup>3</sup>, Yagnesh Vellore<sup>1</sup>, Patrick C. H. Chan<sup>1,2</sup>, Jeffrey V. Rosenfeld<sup>1,2</sup>

<sup>1</sup>Department of Neurosurgery, The Alfred Hospital, <sup>2</sup>Department of Surgery, Monash University, <sup>3</sup>Department of Neurosurgery, Monash Medical Centre, Victoria, Australia

## ABSTRACT

We report a case of a 45-year-old male with a syringopleural shunt who developed intracranial hypotension. The patient presented with 2 weeks history of worsening headache and back pain, on a background of having had a syringopleural shunt inserted for a thoracic posttraumatic syrinx. Computerized tomography imaging of the brain revealed bilateral subdural fluid collections. Magnetic resonance imaging appearances of spinal and intracranial pachymeningeal enhancement confirmed intracranial hypotension. We present a rare case of intracranial hypotension secondary to syringopleural shunting in a patient with posttraumatic syringomyelia.

**Key words:** Intracranial hypotension, subdural collection, syringomyelia, syringopleural shunt

## Case Report

A 45-year-old male presented with a 9-month history of worsening thoracic back pain, after a fall onto his back. The patient also complained of dysesthetic pain and numbness in his right leg, as well as pain involving his buttocks, thighs and calves bilaterally. No reported lower limb weakness or disturbance of bowel or bladder function. The patient's medical history included hypertension, hypercholesterolemia, type 2 diabetes, chronic obstructive airways disease and depression. T2-weighted magnetic resonance imaging (MRI) of the thoracic spine showed evidence of cord signal abnormality with a relatively well-defined linear hyperintensity at T1–T2, no abnormal contrast enhancement or cord expansion. The patient was initially treated conservatively.

Twenty months later at out-patient clinic review, the patient

reported progression of neurological symptoms, with worsening numbness and weakness in the right leg. Clinical examination was significant for right lower limb globally reduced sensation and power Medical Research Council (MRC) grade 4/5 in all myotomes, with generalized hyper-reflexia. T2-weighted sagittal MRI of the spine revealed a central spinal cord intramedullary hyperintensity at the level of C7–T2 measuring 7 mm by 28 mm with mild cord expansion [Figure 1]. The radiological appearances were consistent with an intramedullary syrinx cavity at C7–T2. Surgery was performed, T1 laminectomy and insertion of syringopleural shunt. After the operation the patient had reduction in pain symptoms and improvement in right leg sensory and motor function.

Six months later the patient experienced neurological deterioration, with gait disturbance, left arm paraesthesia, left leg generalized numbness and more severe pain. Clinical examination was significant for reduced sensation to light touch left upper limb C7/C8 dermatomes and left sided T4 hemi-sensory level, exacerbated with coughing and valsalva maneuver. T2-weighted sagittal MRI of the spine showed partial re-accumulation of the syrinx cavity at C7–T2, with the shunt tube *in situ* at this level. The patient was admitted for revision of the syringopleural shunt. Postoperatively the patient reported improvement in left leg numbness and pain.

Three months later the patient represented with 2 weeks of worsening headache, orthostatic in nature, and back pain. Clinical examination was significant for left lower limb global reduction in sensation to light touch and reduced power MRC grade 4<sup>+</sup>/5, with generalized hyper-reflexia. Computed tomography (CT) imaging of the brain demonstrated bilateral

Access this article online	
Quick Response Code:	Website: www.asianjns.org
	DOI: 10.4103/1793-5482.152113

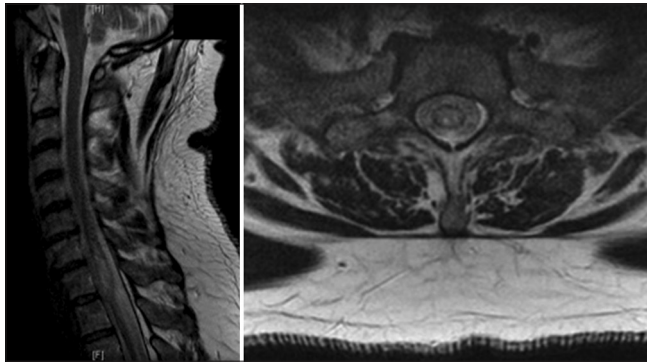
### Address for correspondence:

Dr. Johanne C. Summers  
Department of Neurosurgery, Monash Medical Centre, 246 Clayton Road Clayton, Victoria 3168, Australia. E-mail: johannesummers@gmail.com

low attenuation subdural fluid collections over the cerebral convexities, maximal depth near the cerebral vertex measuring 6 mm on the right and 7 mm on the left, with adjacent sulcal and ventricular effacement, and some mass effect on the lateral ventricles [Figure 2]. T2-weighted MRI demonstrated decreased size of the syrinx cavity at C7–T2, with the shunt drain tube *in situ* at this level [Figure 3]. T1-weighted gadolinium-enhanced images revealed new marked diffuse spinal and intracranial pachymeningeal enhancement [Figure 4], with increased prominence of the left transverse sinus and a small right pleural effusion. The appearances were consistent with intracranial hypotension, potentially due to a connection between the syrinx cavity and the subarachnoid space resulting in excess drainage via the syringopleural shunt. Surgery was performed for insertion of a programmable (Medtronic strata II) valve into the syringopleural shunt, with the intention of trying to reduce the rate of cerebrospinal fluid (CSF) drainage. In the postoperative period the valve pressure setting was gradually increased, and the patient's headaches resolved. Postoperative CT imaging of the brain showed reduction of bilateral subdural fluid collections and increase in size of the ventricles and basal cisterns. At 6 weeks follow-up the patient remained stable, with no recurrence of headaches, and CT imaging of the brain demonstrated resolution of bilateral subdural collections.

## Discussion

It is proposed that posttraumatic syringomyelia develops as a result of arachnoid scarring and CSF flow obstruction.<sup>[1]</sup>

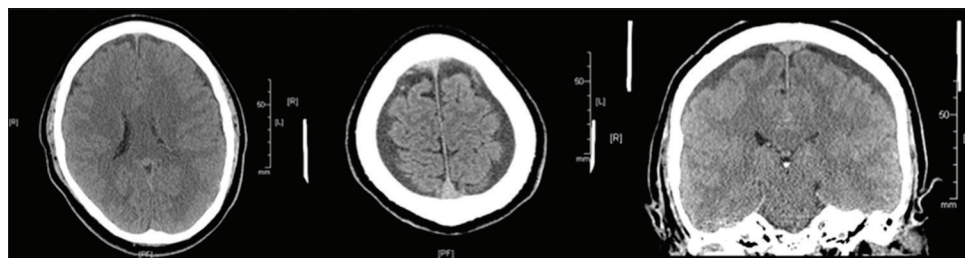


**Figure 1:** Magnetic resonance T2-weighted sagittal and axial images. Syrinx cavity C7–T2, spinal cord intramedullary hyperintensity

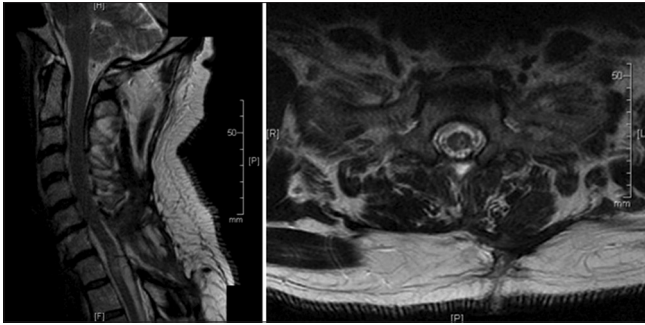
Research studies report on the effect of arachnoid scarring causing a rise in the subarachnoid space pressure proximal to the obstruction.<sup>[2,3]</sup> CSF flow obstruction is said to result in changes in the spinal cord distribution of extra-cellular fluid.<sup>[3-5]</sup> Other hypotheses include increased flow in the perivascular spaces,<sup>[3,5-8]</sup> and spinal cord tethering<sup>[1]</sup> playing a role in the development of posttraumatic syringomyelia. The literature reports a variable time interval after trauma to clinical symptom presentation.<sup>[1,2,4,9-13]</sup> The condition generally manifests as a progressive neurological deficit above the level of previous spinal cord injury. Clinical symptoms can include a heterogeneous presentation of sensory changes, autonomic dysfunction, pain, motor weakness, spasticity, or gait disturbance.<sup>[1,9-11,14-16]</sup>

The literature reports use of different shunt systems for the management of syringomyelia, including syringosubarachnoid, syringoperitoneal and syringopleural shunts. Shunt systems are used to direct fluid away from the syrinx, with the aim of reduction of the cystic cavity and improvement in the neurological symptoms. Syringopleural shunting for syringomyelia has satisfactory short-term results,<sup>[12,17-24]</sup> but limited information is available on long-term complications and outcomes.<sup>[12,17,21,24]</sup> A variety of complications after syringopleural shunt placement have been reported, including shunt obstruction, failure or migration, spinal cord tethering by the shunt, a low CSF pressure state, and pulmonary problems such as pleural effusion, irritation and pneumothorax.<sup>[17,20,23,25,26]</sup> A number of studies report a low pressure CSF state or low-pressure headaches as a complication of shunting procedures for syringomyelia, but little detail is given.<sup>[17,25-28]</sup> The low pressure CSF state is proposed to result from communication between the syrinx cavity and the subarachnoid space, resulting in the shunt draining the syrinx and CSF from the spinal subarachnoid space.<sup>[17]</sup>

In the case that we have presented, postgadolinium MRI showed spinal and intracranial pachymeningeal enhancement associated with intracranial hypotension, as described by Hochman *et al.*<sup>[29]</sup> Intracranial hypotension associated with subdural hematoma,<sup>[28,30-32]</sup> and subdural hematoma secondary to subarachnoid shunting,<sup>[28]</sup> have been reported in the literature. We report a case of syringopleural shunting complicated by intracranial hypotension associated with bilateral subdural fluid collections. This



**Figure 2:** Computed tomography brain coronal and axial images. Bilateral low-attenuation cerebral convexity subdural collections, sulcal effacement and mass effect on the lateral ventricles



**Figure 3:** Magnetic resonance T2-weighted sagittal and axial images. Syrinx cavity C7–T2 with shunt drain tube

complication has not previously been reported as the result of syringopleural shunting for posttraumatic syringomyelia. A subdural fluid collection, or subdural effusion, refers to an effusion, usually CSF, in the subdural space.<sup>[33]</sup> In our case, the pathogenesis of the bilateral subdural fluid collections was secondary to intracranial hypotension. The low-pressure state resulted in opening up of the subdural space due to the brain sagging away from the calvarium, causing fluid transudation into the subdural space from the intravascular compartment, due to stretching on the vessels traversing the subdural space.<sup>[34]</sup> The subdural fluid collections were small, did not require surgical intervention and showed spontaneous resolution with management of the intracranial hypotension.

In the case that we have reported, intracranial hypotension was potentially due to communication between the syrinx cavity and the subarachnoid space,<sup>[23]</sup> resulting in excess drainage via the syringopleural shunt. This may have resulted from a number of proposed mechanisms:

### Communicating syrinx

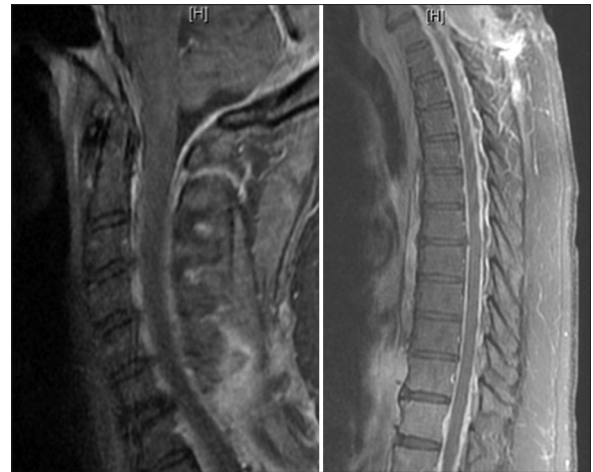Imaging did not identify a communication between the syrinx and the subarachnoid space, and during the surgical procedure excess fluid from the syrinx shunt tubing was not evident to indicate that a communication was present.

### Shunt system tubing

Silastic “T” shunt tubing with side holes was used, placed within the syrinx, designed to drain the syrinx cavity only. MRI demonstrated functional shunt tubing positioned within the reduced syrinx cavity.

### Incomplete or failure of myelotomy closure, or pia-arachnoid membrane rupture

This could result in a communication between the syrinx and the subarachnoid space,<sup>[23,35]</sup> with flow of spinal CSF into the syrinx, resulting in draining of the syrinx fluid and CSF via the shunt. In our case, secure myelotomy closure was performed, and there was not a profuse flow of fluid from the end of the shunt tubing to indicate insufficient closure.<sup>[23]</sup> A pia-arachnoid membrane defect was not detected, however there may have been a small defect causing a slow CSF leak.



**Figure 4:** Magnetic resonance sagittal gadolinium-enhanced T1-weighted images. Diffuse spinal and intracranial pachymeningeal enhancement

### Incomplete or failure of dural closure, or dural rupture

This could cause leakage of spinal CSF through a dural fistula,<sup>[30,36]</sup> or tracking of spinal CSF along the shunt tubing into the pleural cavity.<sup>[23]</sup> In our case, secure dural closure was achieved with sutures, DuraForm and DuraSeal, and MRI did not demonstrate a subcutaneous collection of CSF.

### Intraoperative intracranial hypotension

During the revision of the syringopleural shunt, vigorous CSF outflow and transient intra-operative intracranial hypotension due to abnormal pressure gradient from the intracranial to the intraspinal canal space,<sup>[28]</sup> could have resulted in the formation of bilateral subdural fluid collections. This is not likely to be the cause as our patient developed symptomatic orthostatic headaches secondary to intracranial hypotension 2.5 months after the surgical procedure.

We report a rare case of intracranial hypotension in a patient with a syringopleural shunt for the management of posttraumatic syringomyelia. Further research on the pathophysiology and treatment strategies is required in order to optimize the management of patients with syringomyelia.

### References

1. Williams B. Surgical management of non-hindbrain-related and post-traumatic syringomyelia. In: Schmidek HH, Sweet WH, editors. *Operative Techniques in Neurosurgery*. Philadelphia: Saunders; 1995.
2. Bilston LE, Fletcher DF, Stoodley MA. Focal spinal arachnoiditis increases subarachnoid space pressure: A computational study. *Clin Biomech (Bristol, Avon)* 2006;21:579-84.
3. Klekamp J, Völkel K, Bartels CJ, Samii M. Disturbances of cerebrospinal fluid flow attributable to arachnoid scarring cause interstitial edema of the cat spinal cord. *Neurosurgery* 2001;48:174-85.
4. Greitz D. Unraveling the riddle of syringomyelia. *Neurosurg Rev* 2006;29:251-63.
5. Klekamp J. The pathophysiology of syringomyelia-historical overview and current concept. *Acta Neurochir (Wien)* 2002;144:649-64.

6. Brodbelt AR, Stoodley MA, Watling AM, Tu J, Burke S, Jones NR. Altered subarachnoid space compliance and fluid flow in an animal model of posttraumatic syringomyelia. *Spine (Phila Pa 1976)* 2003;28:E413-9.
7. Stoodley MA, Gutschmidt B, Jones NR. Cerebrospinal fluid flow in an animal model of noncommunicating syringomyelia. *Neurosurgery* 1999;44:1065-75.
8. Stoodley MA, Jones NR, Yang L, Brown CJ. Mechanisms underlying the formation and enlargement of noncommunicating syringomyelia: Experimental studies. *Neurosurg Focus* 2000;8:E2.
9. Aghakhani N, Baussart B, David P, Lacroix C, Benoudiba F, Tadie M, *et al.* Surgical treatment of posttraumatic syringomyelia. *Neurosurgery* 2010;66:1120-7.
10. Kramer KM, Levine AM. Posttraumatic syringomyelia: A review of 21 cases. *Clin Orthop Relat Res* 1997;190-9.
11. Schurch B, Wichmann W, Rossier AB. Post-traumatic syringomyelia (cystic myelopathy): A prospective study of 449 patients with spinal cord injury. *J Neurol Neurosurg Psychiatry* 1996;60:61-7.
12. Sgouros S, Williams B. Management and outcome of posttraumatic syringomyelia. *J Neurosurg* 1996;85:197-205.
13. Ushewokunze SO, Gan YC, Phillips K, Thacker K, Flint G. Surgical treatment of post-traumatic syringomyelia. *Spinal Cord* 2010;48:710-3.
14. Biyani A, el Masry WS. Post-traumatic syringomyelia: A review of the literature. *Paraplegia* 1994;32:723-31.
15. Edgar R, Quail P. Progressive post-traumatic cystic and non-cystic myelopathy. *Br J Neurosurg* 1994;8:7-22.
16. Falci SP, Indeck C, Lammertse DP. Posttraumatic spinal cord tethering and syringomyelia: Surgical treatment and long-term outcome. *J Neurosurg Spine* 2009;11:445-60.
17. Batzdorf U, Klekamp J, Johnson JP. A critical appraisal of syrinx cavity shunting procedures. *J Neurosurg* 1998;89:382-8.
18. Cacciola F, Capozza M, Perrini P, Benedetto N, Di Lorenzo N. Syringopleural shunt as a rescue procedure in patients with syringomyelia refractory to restoration of cerebrospinal fluid flow. *Neurosurgery* 2009;65:471-6.
19. Kahler RJ, Knuckey NW, Davis S. Arachnoiditis ossificans and syringomyelia: A unique case report. *J Clin Neurosci* 2000;7:66-8.
20. Ram Z, Findler G, Tadmor R, Sahar A, Shacked I. Syringopleural shunt for the treatment of syringomyelia. Technical note. *Spine (Phila Pa 1976)* 1990;15:231-3.
21. Vernet O, Farmer JP, Montes JL. Comparison of syringopleural and syringosubarachnoid shunting in the treatment of syringomyelia in children. *J Neurosurg* 1996;84:624-8.
22. Wiedemayer H, Nau HE, Rauhut F, Grote W, Gerhard L. Operative treatment and prognosis of syringomyelia. *Neurosurg Rev* 1994;17:37-41.
23. Williams B, Page N. Surgical treatment of syringomyelia with syringopleural shunting. *Br J Neurosurg* 1987;1:63-80.
24. Williams B, Sgouros S, Nenji E. Cerebrospinal fluid drainage for syringomyelia. *Eur J Pediatr Surg* 1995;5 Suppl 1:27-30.
25. Barbaro NM, Wilson CB, Gutin PH, Edwards MS. Surgical treatment of syringomyelia. Favorable results with syringoperitoneal shunting. *J Neurosurg* 1984;61:531-8.
26. Sgouros S, Williams B. A critical appraisal of drainage in syringomyelia. *J Neurosurg* 1995;82:1-10.
27. Isik N, Elmaci I, Isik N, Cerci SA, Basaran R, Gura M, *et al.* Long-term results and complications of the syringopleural shunting for treatment of syringomyelia: A clinical study. *Br J Neurosurg* 2013;27:91-9.
28. Yamazaki T, Yanaka K, Uemura K, Tsukada A. Subdural hematoma caused by intracranial hypotension after syringosubarachnoid shunting – case report. *Neurol Med Chir (Tokyo)* 2004;44:475-8.
29. Hochman MS, Naidich TP, Kobetz SA, Fernandez-Maitin A. Spontaneous intracranial hypotension with pachymeningeal enhancement on MRI. *Neurology* 1992;42:1628-30.
30. Burkhard PR, Duff JM. Bilateral subdural hematomas following routine lumbar discectomy. *Headache* 2000;40:480-2.
31. Nakajima H, Sakai T, Aoki N, Takakura K. Bilateral chronic subdural hematomas associated with intracranial hypotension – case report. *Neurol Med Chir (Tokyo)* 1996;36:647-9.
32. Sipe JC, Zyroff J, Waltz TA. Primary intracranial hypotension and bilateral isodense subdural hematomas. *Neurology* 1981;31:334-7.
33. Yilmaz N, Kiyamaz N, Yilmaz C, Bay A, Yuca SA, Mumcu C, *et al.* Surgical treatment outcome of subdural empyema: A clinical study. *Pediatr Neurosurg* 2006;42:293-8.
34. Mitra S, Ghosh D, Pathak A, Kumar L. Bilateral subdural effusion and subcutaneous swelling with normally functioning csf shunt. *Neurol India* 2001;49:178-81.
35. Milhorat TH, Capocelli AL Jr, Anzil AP, Kotzen RM, Milhorat RH. Pathological basis of spinal cord cavitation in syringomyelia: Analysis of 105 autopsy cases. *J Neurosurg* 1995;82:802-12.
36. Acharya R, Chhabra SS, Ratra M, Sehgal AD. Cranial subdural haematoma after spinal anaesthesia. *Br J Anaesth* 2001;86:893-5.

**How to cite this article:** Summers JC, Vellore Y, Chan PC, Rosenfeld JV. Intracranial hypotension after syringopleural shunting in posttraumatic syringomyelia: Case report and review of the literature. *Asian J Neurosurg* 2015;10:158-61.

**Source of Support:** Nil, **Conflict of Interest:** None declared.