

## Cystoid macular edema after bone marrow transplantation

Vikas Khetan, S P Chaudhary,  
Lingam Gopal

We report a case of cystoid macular edema in a patient who underwent bone marrow transplant for aplastic anemia. After having ruled out all the other causes of cystoid macular edema, we concluded that it was secondary to the bone marrow transplant. The patient had mild visual impairment and did not recover the lost vision. In this case report, we describe in detail the clinical presentation, follow-up, and course of medication that this patient had. It is an illustrated case report of cystoid macular edema after bone marrow transplant with mild visual impairment and no recovery.

**Key words:** Bone marrow transplantation retinopathy, cyclosporine, cystoid macular edema

*Indian J Ophthalmol*: 2009;57:55-7

Bone marrow transplantation (BMT) retinopathy is a type of occlusive microvascular retinopathy first described in 1983.<sup>[1]</sup> BMT is an important treatment option for both malignant and nonmalignant disorders of bone marrow including aplastic anemia, leukemia, and lymphoma.<sup>[2]</sup> Posterior segment complications after BMT have been reported to be 12.8% in literature.<sup>[3]</sup>

Reported clinical manifestations were usually bilaterally symmetrical and included multiple microaneurysms, telangiectasis, cotton wool spots, hard exudates, retinal hemorrhages, and macular edema.

In this report, we describe a patient with isolated cystoid macular edema after BMT for aplastic anemia with mild visual impairment and no recovery.

### Case History

A 13-year-old boy presented in September 2005 with gradual decrease of vision of 9 months duration. The patient had been previously diagnosed to have aplastic anemia, for which he had undergone BMT in January 2004. He was also diagnosed to have hypothyroidism, mesangiopathic nephritis, and cushingoid habitus for the last 1 year. There was no history of drug allergy.

The patient received tablet cyclosporine 80 mg twice a day for 3 months before BMT and continued to receive tablet

cyclosporine 150 mg twice a day after BMT, which was tapered over 6 months. Subsequently, because of increased creatinine levels, he was administered with high-dose oral steroids, one month before presentation to us. He was also on folic acid (2.5 mg/day), anticoagulants (Tab Acitrom 1.5 mg/day), calcium supplements (Tab Shelcal 500 mg twice/day), and thyroxin tablets (Tab Eltroxin 25 mg/day).

On ocular examination, the best-corrected visual acuity was 20/50, N6 in right eye and 20/60, N6 in the left eye. Anterior segment was within normal limits. Applanation intraocular pressure was 14 mmHg in both eyes. Fundus examination showed cystoid macular edema in both eyes and retinal pigment epithelium (RPE) changes along the inferotemporal arcade. There were no microaneurysms or cotton wool spots. Fundus fluorescein angiography showed window defects in the macular area, suggestive of atrophy, and did not reveal areas of capillary nonperfusion [Fig. 1 A, B]. Optical coherence tomography confirmed the presence of cystoid macular edema [Fig. 2 A, B].

One year later, the visual acuity was stable (right eye 20/50, N6; left eye 20/60, N6). Anterior segment was within normal limits except for early posterior polar cataract. Fundus examination and OCT showed persistent cystoid macular edema and RPE changes in both eyes. The full-field electroretinogram (ERG) showed normal scotopic and photopic responses. However, multifocal ERG showed gross reduction of central and paracentral amplitudes.

### Discussion

The incidence of posterior segment complications after BMT has been reported to be 12.8% and includes intraretinal hemorrhage, vitreous hemorrhage, cotton wool spots, optic disc edema, ocular infections, ocular lymphoma, and serous retina detachment.<sup>[3]</sup> Lopez *et al.* have reported eight patients who underwent allogenic and autologous BMT and subsequently developed nonproliferative (six patients) and proliferative retinopathy (two patients) with macular edema.<sup>[4]</sup> They have reported the incidence of clinically significant macular edema to be 80%.

The exact etiology of BMT retinopathy is uncertain. Causes of this entity are likely to be multifactorial, resulting from the combined effects of cyclosporine, total body radiation, high-dose chemotherapy, and recurrent malignancies.<sup>[3]</sup> Cyclosporine is a potent immunosuppressive agent for suppressing graft-versus-host immune response. It has been shown to cause endothelial cell injury. Because of neurotoxic side effects, it has been implicated as a cause of BMT retinopathy.<sup>[5]</sup> Total body irradiation has also been implicated as the causal agent of BMT retinopathy. Radiation damages the retinal microvasculature and may lead to ischemic vasculopathy. It usually occurs within 6 months of BMT. However, it has been reported as early as 3 months to as late as 62 months.<sup>[1,4]</sup>

BMT retinopathy has been reported to have a generally good prognosis. The retinopathy typically resolves within 2–4 months after the cessation or lowering of cyclosporine with or without use of systemic prednisone.<sup>[3]</sup> However, in our patient, cystoid macular edema developed 12 months after allogenic BMT and 6 months after stopping oral cyclosporine.

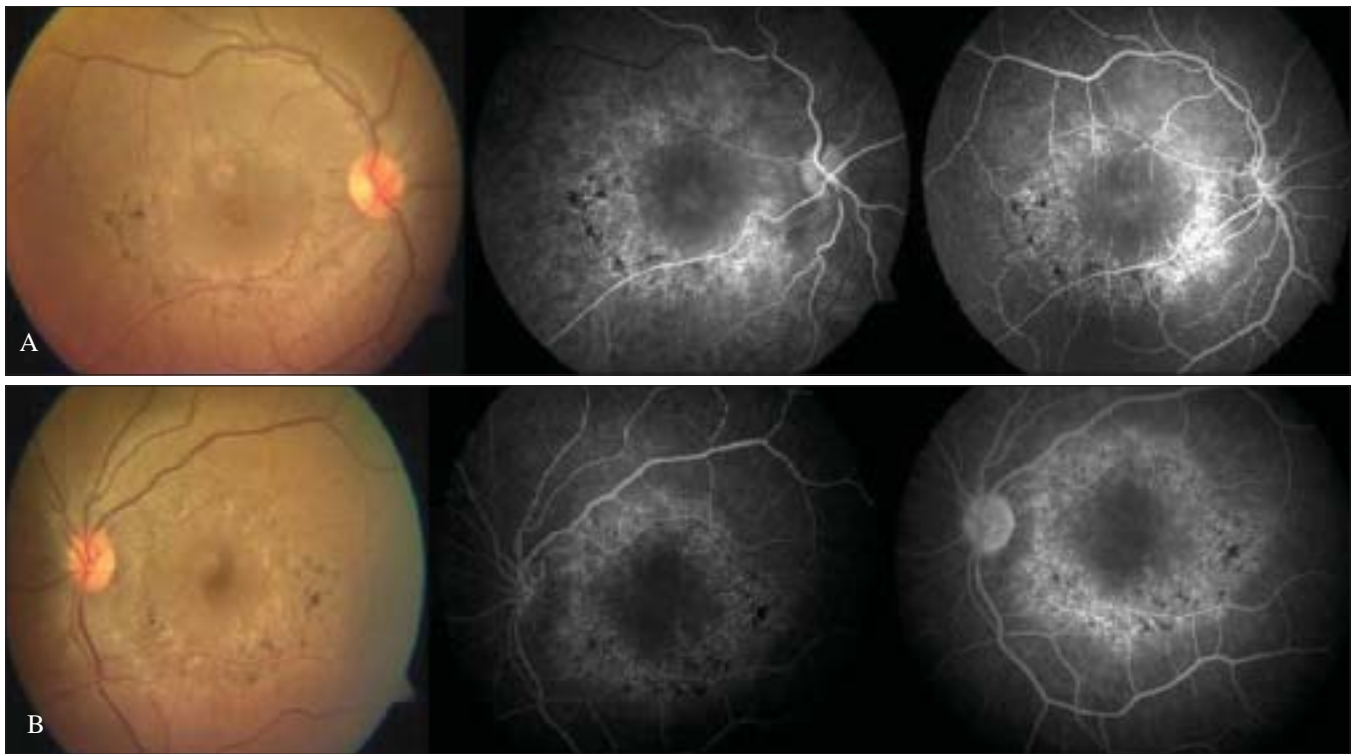
Fundus lesions in our case were restricted to isolated cystoid macular edema with no other signs of microangiopathic vascular

---

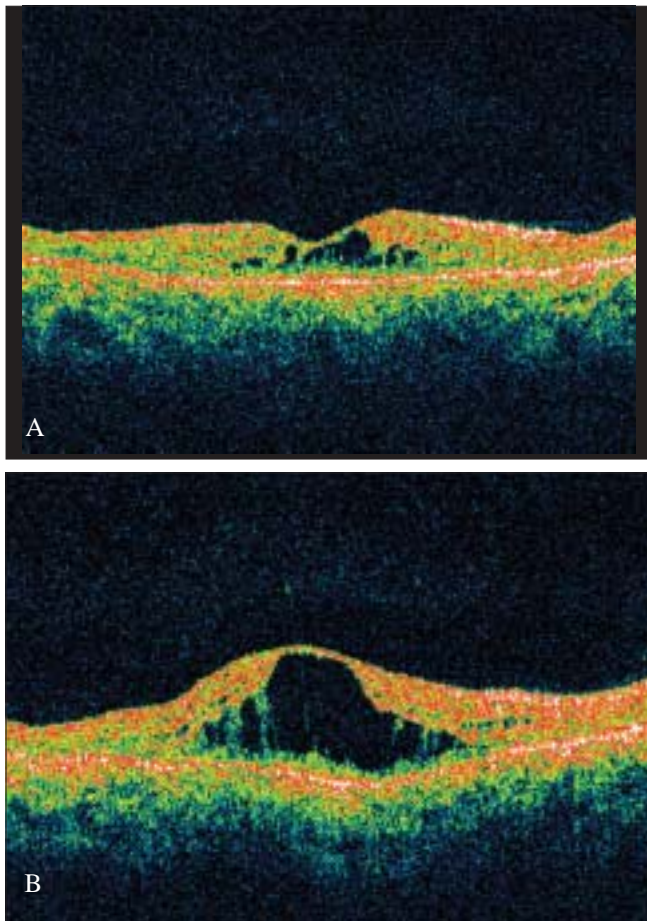
Bhagwan Mahavir Vitreoretinal Services, Vision and Medical Research Foundation, Sankara Nethralaya, 18, College Road, Nungambakkam, Chennai - 600 006, India

Correspondence to Dr. Lingam Gopal, Bhagwan Mahavir Vitreoretinal Services, Vision and Medical Research Foundation, Sankara Nethralaya, 18, College Road, Nungambakkam, Chennai - 600 006, India. E-mail: drlg@snmail.org

Manuscript received: 16.07.07; Revision accepted: 17.03.08



**Figure 1:** Color photo and fundus fluorescein angiogram: Bone marrow transplantation cystoid macular edema, (A) right eye (B) left Eye



**Figure 2:** Optical coherence tomography, (A) right eye(B) left eye

retinopathy such as retinal hemorrhages, microaneurysms, or cotton wool spots as described in literature.<sup>[1-4,6]</sup> Such isolated cystoid macular edema after BMT has not been described and is unique to our case.

The other condition to be kept in mind is the steroid-induced serous pigment epithelium detachment. However, in our case, OCT clearly demonstrated cystoid macular edema, and the condition occurred even before oral steroids were initiated.

Macular edema is an important cause of visual impairment in BMT retinopathy. Perifoveal microaneurysms have been described as an infrequent source of diffuse macular edema, and the prophylactic use of cyclosporine has been associated with the development of microvascular retinopathy in cases of BMT.<sup>[4]</sup>

Because of the relatively favorable prognosis and nonprogressive nature of the BMT retinopathy, aggressive treatment is not necessary. Use of acetazolamide, corticosteroids, and grid photocoagulation has been advised in literature in cases of significant macular edema. In our case, acetazolamide could not be used because of mesangiopathic nephritis, and the child was already on systemic steroids as immunosuppressive agent. Lopez *et al.* have recommended grid photocoagulation for visually significant macular edema.<sup>[4]</sup>

In summary, BMT as a cause of isolated cystoid macular edema has not been reported before. The possible causes could be the use of cyclosporine or even steroids; however, steroids are known to cause multifocal central serous retinopathy-like picture.

## References

1. Hirst LW, Jabs DA, Tutschka PJ, Green WR, Santos GW. The eye in

- 
- bone marrow transplantation: I, Clinical study. *Arch Ophthalmol* 1983;101:580-4.
2. Armitage JO. Bone marrow transplantation. *N Engl J Med* 1994;330:827-38.
  3. Coskuncan NM, Jabs DA, Dunn JP, Haller JA, Green WR, Vogelsang GB, *et al.* The eye in bone marrow transplantation: VI, Retinal complication. *Arch Ophthalmol* 1994;112:372-9.
  4. Lopez PF, Sternberg P Jr, Dabbs CK, Vogler WR, Crocker I, Kalin NS. Bone marrow transplantation retinopathy. *Am J Ophthalmol* 1991;112:635-46.
  5. Avery R, Jabs DA, Wingard JR, Vogelsang G, Saral R, Santos G. Optic disc edema after bone marrow transplantation: Possible role of cyclosporine toxicity. *Ophthalmology* 1991;98:1294-301.
  6. Moon SJ, Mieler WF. Retinal complications of bone marrow and solid organ transplantation. *Curr Opin Ophthalmol* 2003;14:433-42.
-