


# A Pediatric Case of Antibiotic-Associated Hemorrhagic Colitis Caused by *Klebsiella Oxytoca*

Global Pediatric Health  
January-December 2014: 1–3  
© The Author(s) 2014  
DOI: 10.1177/2333794X14550525  
gph.sagepub.com  


Mamiko Yamada, MD<sup>1</sup>, Kazuki Yamazawa, MD<sup>1</sup>, Shinichiro Sekiguchi, MD<sup>1</sup>, Masayoshi Shinjoh, MD<sup>1</sup>, Kentaro Tomita, MD<sup>1</sup>, Toshiki Takenouchi, MD<sup>1</sup>, and Takao Takahashi, MD<sup>1</sup>

*Klebsiella oxytoca* is a gram-negative member of the human fecal microbiota, which is detected in the intestine of about 1.6% to 9% of healthy subjects and thus considered to be a commensal member of the enteric microflora.<sup>1</sup> Recently, *K. oxytoca* has been recognized as the causative organism of antibiotic-associated hemorrhagic colitis (AAHC) after the use of antibiotics, whereas some studies have shown that *K. oxytoca* is not associated with nonhemorrhagic antibiotic-associated diarrhea.<sup>2,3</sup> The characteristics of AAHC are sudden onset of bloody diarrhea and abdominal cramps after penicillin therapy that is considered to be critical for triggering dysbiosis as *K. oxytoca* exhibits a natural resistance to penicillins.<sup>4</sup>

Here we describe a pediatric case of AAHC who initially presented with acute abdominal pain and bloody diarrhea after taking an antibiotic for traumatic dental injury. In addition, we conduct a literature review of previously reported cases of AAHC to clarify the characteristics from a clinical point of view.

## Case Report

A previously healthy 14-year-old Japanese girl was admitted to our hospital with acute severe abdominal pain and frequent bloody diarrhea. She had been treated with 0.75 g oral amoxicillin (AMPC) daily without probiotics since she accidentally lost her teeth 3 days before the admission. She remained afebrile, and the positive findings on physical examination were limited to the abdomen: severe tenderness in the umbilical region without rebound and absent bowel sound. Laboratory examination was normal except for slightly elevated values of white blood cell count (12 400/ $\mu$ L) and C-reactive protein (0.95 mg/dL). An X-ray of the abdomen revealed distension of the small intestine, and ultrasound study demonstrated thickening of the colon walls. Based on the physical examination, laboratory findings, and imaging studies, acute infectious enteritis was initially suspected. The fact that she did not have high fever

and that white blood cell count and C-reactive protein level were not highly elevated suggested that severe bacterial infection was less likely, so symptomatic treatment including fluid and diet therapy was administered with discontinuation of AMPC. On the third day of hospitalization, the results of stool bacterial analysis collected on admission were established: *Clostridium difficile* toxin A and B were not detected by the cytotoxin assay, nor was *C. difficile* itself isolated from the anaerobic stool culture. None of the intestinal pathogens such as *Salmonella*, *Shigella*, *Vibrio*, *Campylobacter*, *Yersinia*, and pathogenic *Escherichia Coli* were isolated either, but pure growth of *K. oxytoca* was yielded from the aerobic stool culture (Figure 1). The diagnosis of AAHC caused by *K. oxytoca* was made on the basis of the history of AMPC medication and the result of stool culture. Her condition gradually improved with the resolution of bloody diarrhea and abdominal cramps. She was discharged on the fifth day of hospitalization, and no recurrence of symptoms was observed thereafter.

## Discussion

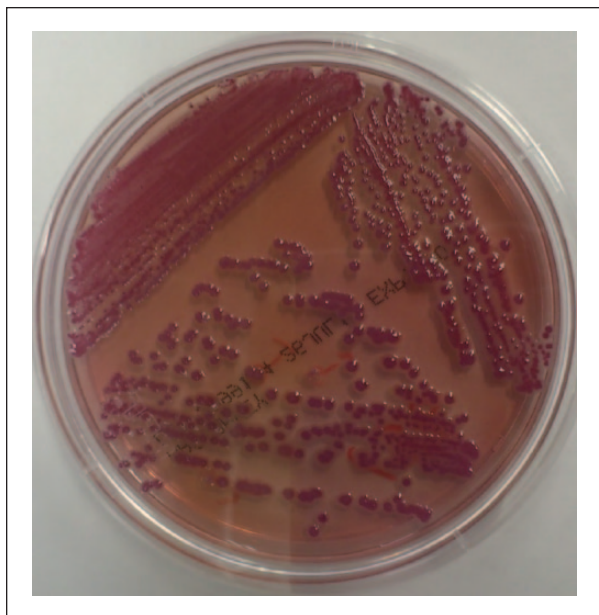
We presented a pediatric case of AAHC caused by *K. oxytoca* who initially had acute abdominal pain and bloody diarrhea after taking AMPC, which then resolved spontaneously after cessation of AMPC. For the sake of comparison, we summarized the previously reported cases of AAHC (Table 1).<sup>2,3,5-9</sup> Of note, all cases of AAHC described to date suddenly developed bloody diarrhea and severe abdominal cramps approximately 4 to 10 days after taking penicillin derivatives. Symptoms resolved within 3 days after cessation of antibiotic therapy. It is also noteworthy that, in addition to adults,

<sup>1</sup>Keio University School of Medicine, Tokyo, Japan

### Corresponding Author:

Kazuki Yamazawa, Department of Pediatrics, Keio University School of Medicine, 35 Shinanomachi, Shinjuku-ku, Tokyo 160-8582, Japan.  
Email: kyamazawa@z5.keio.jp





**Figure 1.** Stool culture yielded pure growth of *Klebsiella oxytoca* on MacConkey agar plate.

school-age children and adolescents have been affected with AAHC. In this context, narrow-spectrum antibiotics are widely prescribed for the treatment of common pediatric conditions such as upper respiratory tract infections or acute otitis media in the pediatric outpatient clinic, despite the fact that such conditions are often self-limiting viral infections and thus not benefiting from antibiotic therapy. Therefore, it is reasonably assumed that pediatric patients predominantly develop AAHC following administration of narrow-spectrum antibiotics. In fact, there have been a limited number of reports of AAHC by *K. oxytoca* probably because the symptoms are rather common and nonspecific, leading to underdiagnosis or misdiagnosis. Thus, it is speculated that the prevalence of AAHC would be underestimated and that there would be much more unreported pediatric and adult cases. Given that only withdrawal of the causative antibiotic treatment can usually result in the improvement of the symptoms and that more invasive management such as endoscopy is not the requisite for the diagnosis, it is important to keep this disease in mind as a possible differential diagnosis of acute bloody diarrhea. In this regard, taking a history of antibiotics medication would be beneficial for the diagnosis.

Preventive measures for AAHC remain to be investigated. The cytotoxin-producing *K. oxytoca* strains present at least temporarily in the colon of healthy individuals are the causative organism of AAHC. Following therapy with penicillin derivatives, toxigenic *K. oxytoca* can selectively overgrow as microbial substitution,

**Table 1.** Clinical Features of Previously Reported AAHC Cases.

	This Case	Pediatric Cases (n = 6)	Adult Cases (n = 20)
Age (years)	14	6-14 (median = 11.5)	22-74 (median = 40)
Gender	Female	Females = 3, males = 3	Females = 10, males = 10
Antibiotics triggering AAHC (no. of cases)	AMPC	AMPC (4)	SBT/ABPC (10)
		AMPC/CVA (1) ABPC (1)	AMPC (4) AMPC/CVA (4) AMPC + CAM (1) AMPC + MNZ (1)
Indication of antibiotics	Dental procedure	Upper respiratory tract infection Urinary tract infection Epididymitis	Sinusitis Bronchitis Tonsillitis Dental procedure
Time to onset (days)	4	3-12 (median = 6.5)	1-14 (median = 4.2)
Symptoms	Hemorrhagic diarrhea Severe abdominal pain	Hemorrhagic diarrhea Severe abdominal pain	Hemorrhagic diarrhea Severe abdominal pain
Time to recovery (days)	3	2-5 (median = 3.3)	2-7 (median = 2.8)
References		Refs 3-5	Refs 2, 6-8

Abbreviations: AAHC, antibiotic-associated hemorrhagic colitis; AMPC, amoxicillin; ABPC, ampicillin; SBT/ABPC, sulbactam/ampicillin; AMPC/CVA, amoxicillin/clavulanate; CAM, clarithromycin; MNZ, metronidazole.

because *Klebsiella* is usually resistant to penicillins due to production of  $\beta$ -lactamase.<sup>2</sup> Based on the above-mentioned notion, taking probiotics is thought to be a good candidate for prevention. Although no reports have examined the prophylactic effect of probiotics against AAHC thus far, some trials in children receiving antibiotics have been performed to assess the efficacy of probiotics used for the prevention of antibiotic-associated diarrhea, demonstrating a dose-dependent benefit from probiotics.<sup>10,11</sup> Further investigations are needed to precisely evaluate the effect of probiotics against AAHC; nonetheless, taking probiotics such as live antibiotic-resistant *Lactobacilli* when using penicillin derivatives would be worth consideration even at this time point.

In summary, we present a 14-year-old girl with AAHC caused by *K. oxytoca*. AAHC is possibly misdiagnosed due to its nonspecific symptoms. Pediatricians should keep this disease in mind when seeing patients with bloody diarrhea and abdominal cramp after starting penicillin treatment.

## Declaration of Conflicting Interests

The author(s) declared no potential conflicts of interest with respect to the research, authorship, and/or publication of this article.

## Funding

The author(s) received no financial support for the research, authorship, and/or publication of this article.

## References

1. Beaugerie L, Metz M, Barbut F, et al. *Klebsiella oxytoca* as an agent of antibiotic-associated hemorrhagic colitis. *Clin Gastroenterol Hepatol*. 2003;1:370-376.
2. Högenauer C, Langner C, Beubler E, et al. *Klebsiella oxytoca* as a causative organism of antibiotic-associated hemorrhagic colitis. *N Engl J Med*. 2006;355:2418-2426.
3. Hoffmann KM, Deutschmann A, Weitzer C, et al. Antibiotic-associated hemorrhagic colitis caused by cytotoxin-producing *Klebsiella oxytoca*. *Pediatrics*. 2010;125:e960-e963.
4. Herzog KAT, Schneditz G, Leitner E, et al. Genotypes of *Klebsiella oxytoca* isolates in nosocomial pneumonia are distinct from antibiotic-associated hemorrhagic colitis isolates. *J Clin Microbiol*. 2014;52:1607-1616.
5. Shinjoh M, Iwata S, Takahashi T. *Klebsiella oxytoca*-positive, penicillin-associated hemorrhagic enterocolitis in children. *Pediatr Int*. 2010;52:132-133.
6. Kato S, Ebina K, Ozawa A, Naganuma H, Nakagawa H. Antibiotic-associated hemorrhagic colitis without *Clostridium difficile* toxin in children. *J Pediatr*. 1995;126:1008-1010.
7. Philbrick AM, Ernst ME. Amoxicillin-associated hemorrhagic colitis in the presence of *Klebsiella oxytoca*. *Pharmacotherapy*. 2007;27:1603-1607.
8. Moulis H, Vender RJ. Antibiotic-associated hemorrhagic colitis. *J Clin Gastroenterol*. 1994;18:227-231.
9. Yilmaz M, Bilir YA, Aygun G, Erzin Y, Ozturk R, Celik AF. Prospective observational study on antibiotic-associated bloody diarrhea: report of 21 cases with a long-term follow-up from Turkey. *Eur J Gastroenterol Hepatol*. 2012;24:688-694.
10. Pattani R, Palda VA, Hwang SW, Shah PS. Probiotics for the prevention of antibiotic-associated diarrhea and *Clostridium difficile* infection among hospitalized patients: systematic review and meta-analysis. *Open Med*. 2013;7:e56-e67.
11. Szajewska H, Ruszczynski M, Radzikowski A. Probiotics in the prevention of antibiotic-associated diarrhea in children: a meta-analysis of randomized controlled trials. *J Pediatr*. 2006;149:367-372.