

# 38-year-old woman with nasal congestion

## A rare case of septum-originated benign fibrous histiocytoma

Zhixian Xiao, MS<sup>a</sup>, Li Zhou, MD<sup>b,\*</sup>, Lian Xu, MD<sup>c,d</sup>, Fangqi Liang, MS<sup>b</sup>, Li Tian, BS<sup>b</sup>, Luyun Jiang, MS<sup>b</sup>, Guowei Ren, MS<sup>a</sup>, Jianhong Deng, MS<sup>b</sup>

### Abstract

**Introduction:** Benign fibrous histiocytoma (BFH) is a mesenchymal tumor composed of fibroblasts and histiocytes, which normally occurs in the bone tissue and/or the skin of the limbs. BFH of the nasal septum is rare worldwide.

**Patient concerns:** A 38-year-old female patient attended our clinic with congestion in her right nasal cavity.

**Diagnoses:** Endoscopic examination revealed a mass within the right nasal passage. Immunohistochemical staining demonstrated cells labeled with VIM (+), CD68PGM1 (+), CD34 (-), Actin (-), PCK (-), EMA (-), Desmin (-), SMA (-), S-100 (-), P63 (-), ALK-1 (-), beta-catenin (+), and KI67 (+). Clinical and histopathological examinations showed that the mass was a septum-originated BFH.

**Interventions:** For the treatment of BFH of the nasal septum, the mass was removed endoscopically using a transnasal approach.

**Outcomes:** No recurrence was observed over 30 months of follow-up.

**Conclusion:** To prevent the recurrence wide local resection with histological clear margin and long-term follow-up with an endoscope are necessary.

**Abbreviations:** BFH = benign fibrous histiocytoma, FH = fibrous histiocytoma.

**Keywords:** benign fibrous histiocytoma, case report, nasal septum

## 1. Introduction

Benign fibrous histiocytoma (BFH) is a mesenchymal tumor composed of fibroblasts and histiocytes.<sup>[1]</sup> Approximately 11% of the BFH patients suffer from its recurrence after local excision, and 1% of them have a risk of malignant

transformation and peripheral metastasis.<sup>[2]</sup> BFH can occur in all parts of the body, especially in the bone tissue, skin, mucous membranes, and deep soft tissue. Septum-originated BFH is extremely rare.<sup>[3]</sup>

## 2. Case presentation

We report a case of a BFH in a 38-year-old woman who presented with a 2-week history of right nasal congestion. The female patient had no history of sinusitis and trauma. Endoscopic examination revealed a mass within the right nasal passage (Fig. 1). On physical examination, the clinician noted an isolated 10 × 10 mm, reddish brown smooth mass was located in the right nasal septum. Incisional biopsy of the mass was performed for pathological examination. Clinical and histopathological examinations showed that the mass was a septum-originated BFH (Fig. 2). Septorhinoplasty was performed by video-assisted endoscopic surgery on September 2, 2016. During surgery, the mass of the septum was widely excised, including septum mucosa, perichondrium, and cartilage. Postoperative pathological examination confirmed ulcer formation on the mucosa surface. Meanwhile, underneath the mucosa, plenty of proliferating spindle cells were found, as well as a few scattered multinucleated giant cells occasionally occurring at the division of the cell nucleus and abundant blood vessels. Immunohistochemical staining demonstrated cells labeled with VIM (+), CD68PGM1 (+), CD34 (-), Actin (-), PCK (-), EMA (-), Desmin (-), SMA (-), S-100 (-), P63 (-), ALK-1 (-), beta-catenin (+), and KI67 (+). Clinical and histopathological examinations showed that the mass was a septum-originated BFH (Figs. 3–5). No recurrence was observed over 30 months of follow-up.

Editor: N/A.

Consent for publication: Informed written consent was obtained from the patient for publication of this case report and accompanying images.

Ethical approval: All procedures performed in studies involving human participants were in accordance with the ethical standards of the institutional and/or national research committee and with the 1964 Helsinki declaration and its later amendments or comparable ethical standards.

The authors declare that they have no conflict of interest.

<sup>a</sup> Department of Otolaryngology, Chengdu University of Traditional Chinese Medicine, <sup>b</sup> Department of Otolaryngology, Hospital of Chengdu University of Traditional Chinese Medicine, <sup>c</sup> Department of Pathology, West China Second University Hospital, Sichuan University, <sup>d</sup> Key Laboratory of Birth Defects and Related Diseases of Women and Children (Sichuan University), Ministry of Education, Chengdu, China.

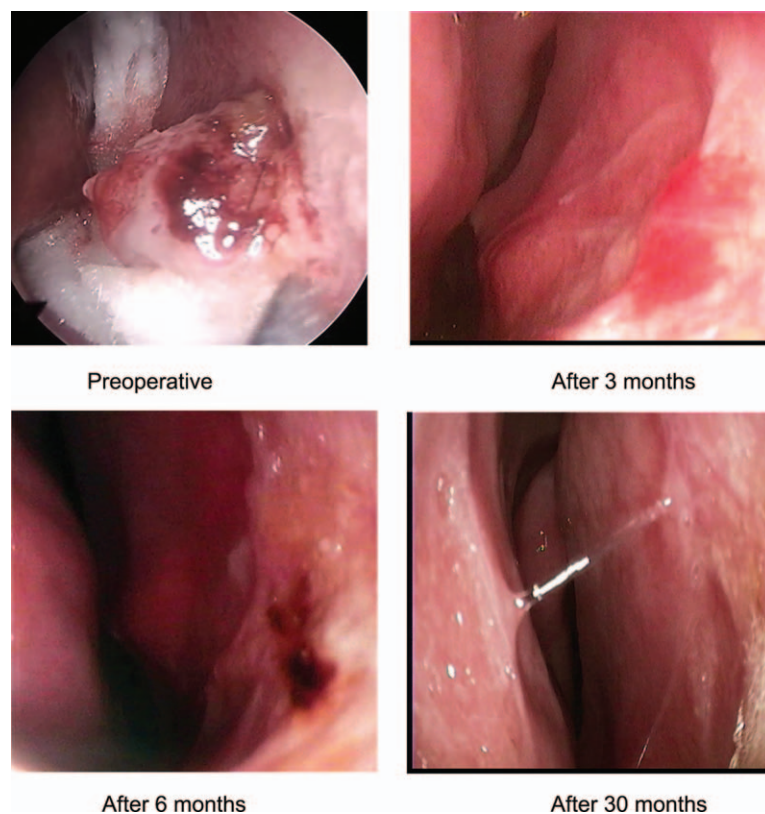
\* Correspondence: Li Zhou, Department of Otolaryngology, Hospital of Chengdu University of Traditional Chinese Medicine, Chengdu, China (e-mail: zhoulj\_1\_2000@126.com).

Copyright © 2019 the Author(s). Published by Wolters Kluwer Health, Inc. This is an open access article distributed under the terms of the Creative Commons Attribution-Non Commercial-No Derivatives License 4.0 (CCBY-NC-ND), where it is permissible to download and share the work provided it is properly cited. The work cannot be changed in any way or used commercially without permission from the journal.

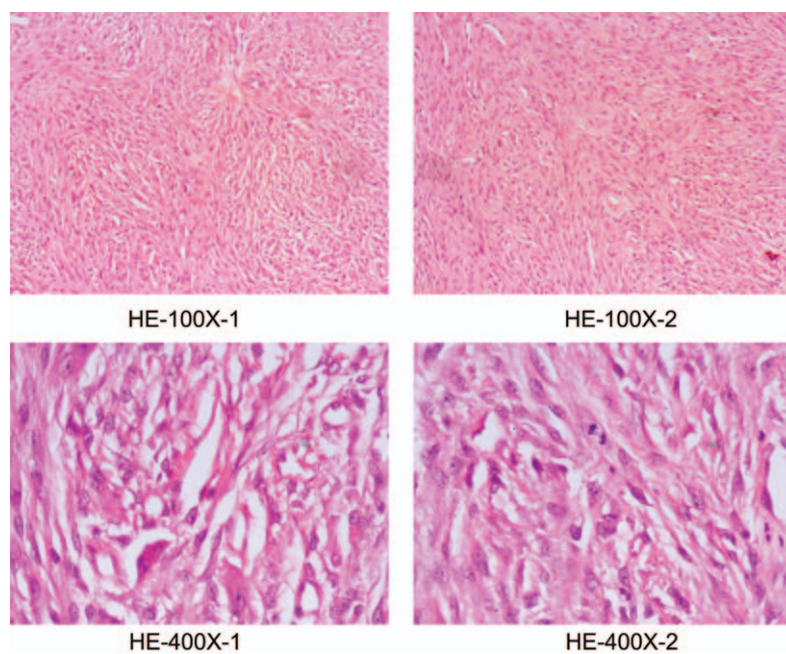
Medicine (2019) 98:23(e15815)

Received: 2 December 2018 / Received in final form: 16 April 2019 / Accepted: 29 April 2019

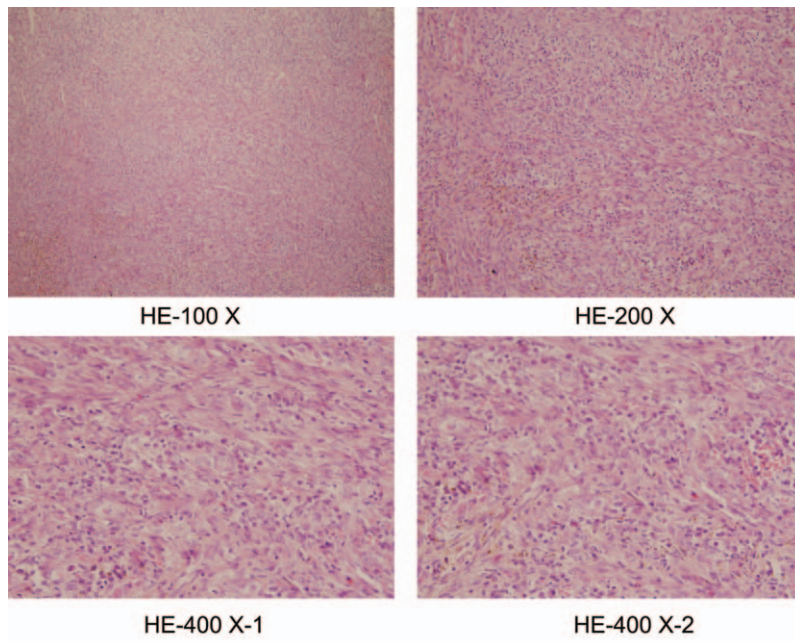
<http://dx.doi.org/10.1097/MD.00000000000015815>



**Figure 1.** Endoscopic examination revealed an isolated 10 × 10 mm, reddish brown smooth mass was located in the right nasal septum. Follow-up was observed at 3rd, 6th, and 30th month.



**Figure 2.** Preoperative pathological examination revealed tumor spindle cells, in which multinucleated giant cells were found. The tumor cells were observed under a high-magnification microscope and found to be arranged in a sheet-like shape, with oval-like shaped nuclei with basically similar pattern of the karyotype, in which a few divisions cell nucleus were observed.

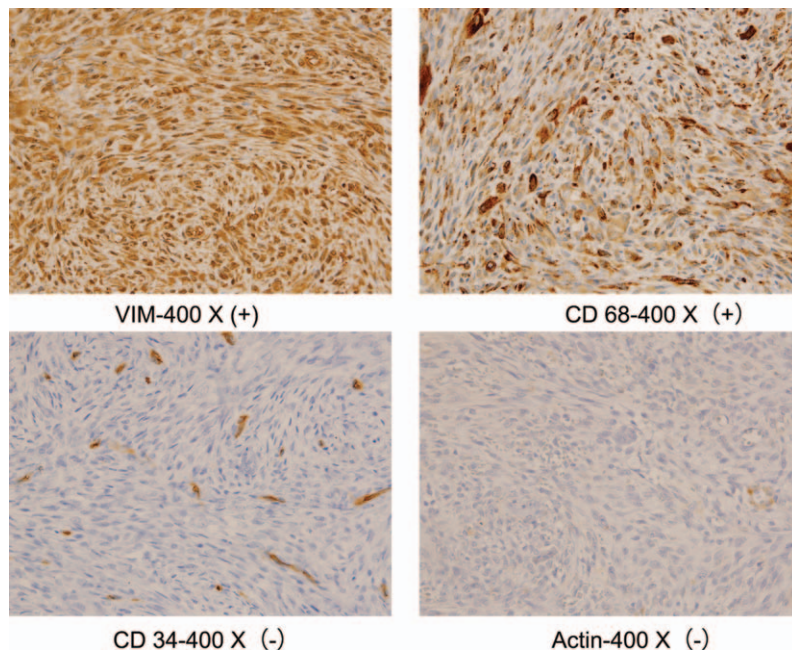


**Figure 3.** Postoperative pathological examination revealed that there were ulcers on the surface of the mucosa, and spindle cells were intermixed with scattered multinucleated giant cells. Among them, there were few in division phases of cell nucleus but abundant blood vessels.

**3. Discussion**

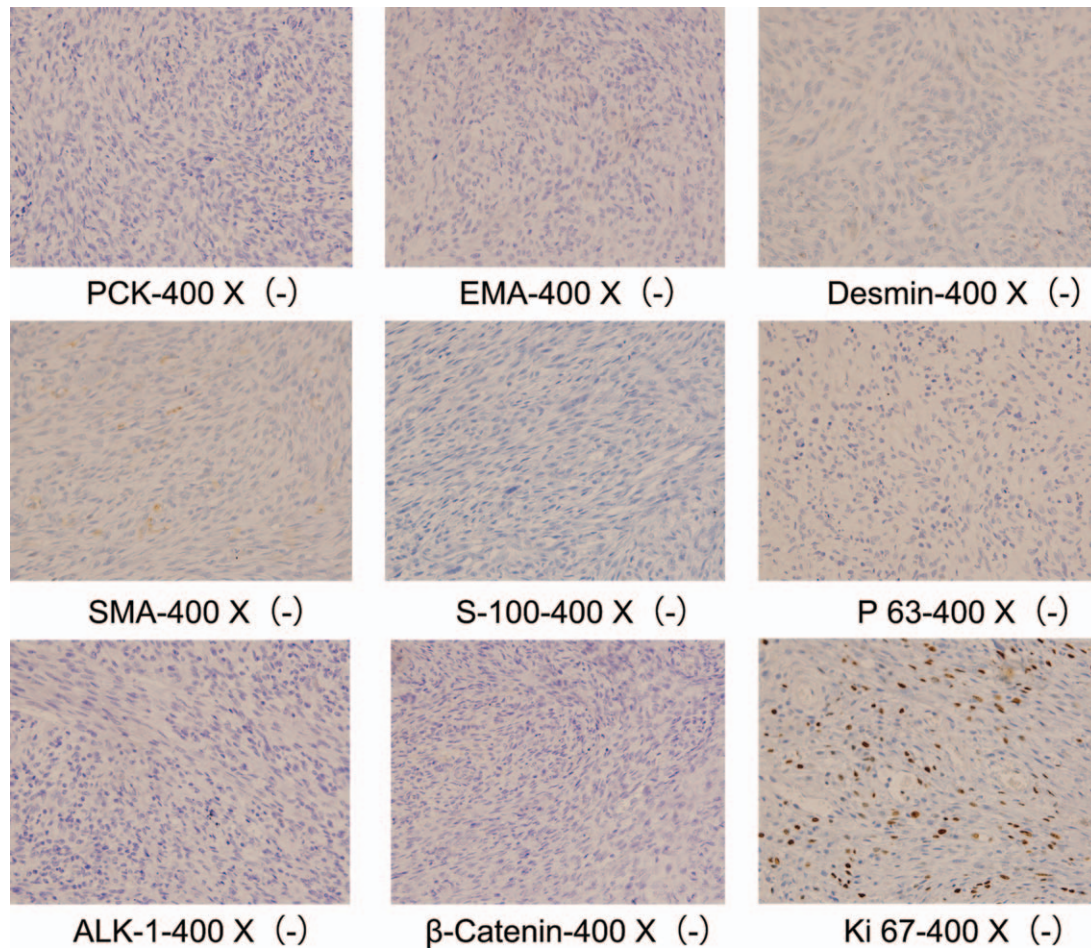
BFH normally occurs in the bone tissue, skin, mucosa, and deep soft tissue. There is no sex difference for BFH which is diagnosed mainly among young and middle-aged people, and is characterized by potential local recurrence, malignant transformation, and metastasis. The etiology remains unknown, possibly induced by trauma and/or chronic infection.<sup>[4]</sup> Intranasal BFH is extreme

rare.<sup>[2]</sup> The variety of clinical manifestations was primarily determined by various locations, mainly due to tumor-enlargement mediated obstruction and compression, for instance, inspiratory dyspnea caused by bronchial BFH, overflowing tears caused by BFH of the lacrimal sac, reflex pain secondary to obstruction and compression of vessels, and/or nerves and etc. Notably, the diagnosis of BFH requires mutual confirmation by



**Figure 4.** Immunohistochemical staining demonstrated cells labeled with VIM (+), CD68PGM1 (+), CD34 (-), and Actin (-).





**Figure 5.** Immunohistochemical staining demonstrated the cells labeled with PCK (-), EMA (-), Desmin (-), SMA (-), S-100 (-), P63 (-), ALK-1 (-), beta-catenin (+), and Ki67 (+).

HE staining and immunohistochemical staining.<sup>[5]</sup> Under the microscope, BFH was observed to be typically composed of fibroblasts and histiocytes. The spindle cells were well arranged either in a swirling-like or grass mat-like patterns. Normally, there was nuclear pleomorphism and divisions of the cell nucleus in those spindle cells, which were mixed with lipid-filled, foam, and multinucleated giant cells. Immunohistochemical staining revealed that vimentin was expressed in all cells in the BFH sample, whereas most of them were CD68-, and some of them were CD34-expressing. In contrast, none of them expressed S-100 or GFAP.<sup>[6]</sup> The differential diagnosis for benign and malignant fibrous histiocytoma (FH) were mainly focused on the presence of high mitotic activity, atypical/heterocystic/pleomorphic cells, and necrosis in malignant FH.<sup>[7]</sup> Furthermore, most biomarkers of malignant FH were primarily designated against heterocysts. Based on the results of a number of empirical studies on pathological examination in clinical practice, a well-defined expression profile of AACT-, CD68-, lysozyme-, vimentin-, PCNA-positive, while Cy-tokeratin-, EMA-, S100-, and myoglobin-negative,<sup>[8]</sup> are highly sensitive and specific for the diagnosis of malignant FH and other malignant tumors. Clinically, it is challenging to distinguish nasal BFH from other benign lesions, such as papilloma, nerve sheath tumor, and pleomorphic adenoma because the clinical manifestations of BFH are not entirely unique. However, there were a few detectable and

differential properties. The exophytic papilloma of the nasal septum was mushroom-like, verrucous, and papillary carcinoma. It often has a broad base, pink or slightly gray color, hard, and rough texture with sometimes granulated surface and lobulated shape. Patients with exophytic papilloma are prone to nose bleeding, which can be caused by soft contact. The nerve sheath tumor of the nasal septum has a gray-white color, round or lobulated shape, well-defined boundary, smooth surface but various texture. Epistaxis is seldom found in these patients.<sup>[9]</sup> Accordingly, the pleomorphic adenoma of nasal septum is normally pink color, mulberry-like shape, visible vascular stria, brittle, and lightly elastic texture.

If the lesion is completely removed, BFH is not likely to recur. Excision with integrated perichondrium may effectively reduce relapses.<sup>[10]</sup> Rare metastasis and good prognosis have been previously reported.<sup>[11]</sup> Wide local resection with histological clear margin is generally agreed as the treatment of choice for BFH.<sup>[12]</sup> In this case radical local excision was achieved by excising the mass together with septum mucosa, ipsilateral and contralateral perichondrium, and cartilage.

#### 4. Conclusions

In summary, BFH of the nasal septum is a mesenchymal tumor composed of fibroblasts and histiocytes and it may be

misdiagnosed at the early stage. Definitive diagnosis relies on histopathological and immunohistochemical features. To prevent the recurrence wide local resection with histological clear margin and long-term follow-up are necessary.

### Author contributions

**Conceptualization:** Zhixian Xiao, Li Zhou.

**Data curation:** Zhixian Xiao.

**Formal analysis:** Li Zhou, Lian Xu, Fangqi Liang, Luyun Jiang, Guowei Ren, Jianhong Deng.

**Methodology:** Zhixian Xiao, Lian Xu, Li Tian.

**Resources:** Zhixian Xiao, Guowei Ren, Li Zhou.

**Software:** Fangqi Liang.

**Supervision:** Zhixian Xiao, Lian Xu, Li Tian.

**Validation:** Li Tian, Luyun Jiang, Li Zhou.

**Visualization:** Fangqi Liang, Jianhong Deng.

**Writing – original draft:** Zhixian Xiao, Li Zhou.

**Writing – review & editing:** Zhixian Xiao, Li Zhou.

### References

- [1] Knapp AN, Samara WA, Shields CL, et al. Conjunctival fibrous histiocytoma in an 8-year-old boy. *J AAPOS* 2016;20:368–70.
- [2] Tanaka T, Kobayashi T, Iino M. Transformation of BFH into malignant fibrous histiocytoma in the mandible: case report. *J Oral Maxillofac Surg* 2011;69:e285–90.
- [3] Basak S, Mutlu C, Erkus M, et al. BFH of the nasal septum. *Rhinology* 1998;36:133–5.
- [4] Skoulakis CE, Papadakis CE, Datsaris GE, et al. Subcutaneous BFH of the cheek. Case report and review of the literature. *Acta Otorhinolaryngol Ital* 2007;27:90–3.
- [5] Ding YF, Hao SP. BFH of the cheek. *Am J Otolaryngol* 2013;34:154–7.
- [6] Volpicelli ER, Fletcher CD. Desmin and CD34 positivity in cellular fibrous histiocytoma: an immunohistochemical analysis of 100 cases. *J Cutan Pathol* 2012;39:747–52.
- [7] Demiralp B, Kose O, Oguz E, et al. BFH of the lumbar vertebrae. *Skeletal Radiol* 2009;38:187–91.
- [8] Sawai H, Okada Y, Funahashi H. Clinicopathological and immunohistochemical analysis of malignant fibrous histiocytoma of the maxillary sinus and nasal cavity. *J Pract Med* 1999;15:547–8.
- [9] Pauna HF, Carvalho GM, Guimaraes AC, et al. Schwannoma of the nasal septum: evaluation of unilateral nasal mass. *Braz J Otorhinolaryngol* 2013;79:403.
- [10] Yu XW, Liu L, XW. Pleomorphic adenoma of nasal septum: 5 cases reports and the literature review. *J Otolaryngol Eye Shand Univ* 2013;27:90–1.
- [11] Gleason BC, Fletcher CD. Deep “benign” fibrous histiocytoma: clinicopathologic analysis of 69 cases of a rare tumor indicating occasional metastatic potential. *Am J Surg Pathol* 2008;32:354–62.
- [12] Soon AK, Brownstein S, O’Connor M, et al. Fibrous histiocytoma of the conjunctiva. *Ophthalmic Plast Reconstr Surg* 2017;33:e133.