

[CASE REPORT]

Pseudolipomatosis of the Colon and Cecum Followed by Pneumatosis Intestinalis

Masaya Iwamuro¹, Takehiro Tanaka², Tomoko Kawabata³, Yuusaku Sugihara^{1,4},
Keita Harada¹, Sakiko Hiraoka¹ and Hiroyuki Okada¹

Abstract:

A 74-year-old Japanese woman was diagnosed with pseudolipomatosis of the cecum and ascending colon. Colonoscopy was performed, which revealed the presence of slightly elevated white lesions, while a magnifying observation showed microbubbles within the mucosa. A month after colonoscopy, the patient was diagnosed with pneumatosis intestinalis. Although the exact pathogenesis is unclear, pneumatosis intestinalis may arise secondary to pseudolipomatosis. This case also indicates that a magnifying observation during colonoscopy may aid in the diagnosis of pseudolipomatosis of the large intestine, since it shows microbubbles within the mucosa, which may be a distinctive feature reflecting the pathology of this disease.

Key words: pseudolipomatosis, pneumatosis intestinalis, colonoscopy, giant cell arteritis

(Intern Med 57: 2501-2504, 2018)

(DOI: 10.2169/internalmedicine.0730-17)

Introduction

Pseudolipomatosis of the large intestine is a rare and benign condition. Endoscopically, colonic lesions appear as slightly elevated whitish or yellowish plaques, often multiple, and sometimes confluent (1, 2). Pseudolipomatosis is histopathologically characterized by the presence of variable-sized cystic spaces within the lamina propria (3, 4). Although pseudolipomatosis of the large intestine is a distinct entity, these pathological features are sometimes associated with pneumatosis intestinalis (5).

We herein report a case of pseudolipomatosis of the large intestine identified during the treatment of giant cell arteritis. It was noteworthy that a magnifying endoscopic observation revealed microbubbles within the cecal and colonic mucosa. The endoscopic findings in this patient carry important implications that a magnifying observation provides diagnostic clues for pseudolipomatosis. Another unique feature of this case was that pneumatosis intestinalis occurred one month after the diagnosis of pseudolipomatosis of the large intestine.

tine.

Case Report

A 74-year-old Japanese woman underwent computed tomography (CT) and magnetic resonance imaging of the head for the investigation of a fever, fatigue, headache at the bilateral temples, and bilateral jaw pain during mastication. However, radiological studies revealed no abnormalities. She was referred to our hospital for a further investigation because of anemia, elevated levels of C-reactive protein, and increased white blood cell count. On a physical examination, there was no focal tenderness or nodularity upon direct palpation of the superficial temporal arteries; her visual fields were intact, and no bruits or murmur were noted on auscultation of the carotid artery and heart. Myalgia was absent, and no abdominal abnormalities were noted. Laboratory findings revealed increased white blood cell and platelet counts of 9,340/ μ L and 596,000/ μ L, respectively, and an elevated erythrocyte sedimentation rate of >140 mm/h, an elevated C-reactive protein level of 8.61 mg/dL, and an ele-

¹Department of Gastroenterology and Hepatology, Okayama University Graduate School of Medicine, Dentistry, and Pharmaceutical Sciences, Japan, ²Department of Pathology, Okayama University Hospital, Japan, ³Department of Rheumatology, Okayama University Graduate School of Medicine, Dentistry, and Pharmaceutical Sciences, Japan and ⁴Department of General Medicine, Okayama University Graduate School of Medicine, Dentistry, and Pharmaceutical Sciences, Japan

Received: December 26, 2017; Accepted: February 1, 2018; Advance Publication by J-STAGE: April 27, 2018

Correspondence to Dr. Masaya Iwamuro, iwamuro.masaya@yahoo.co.jp

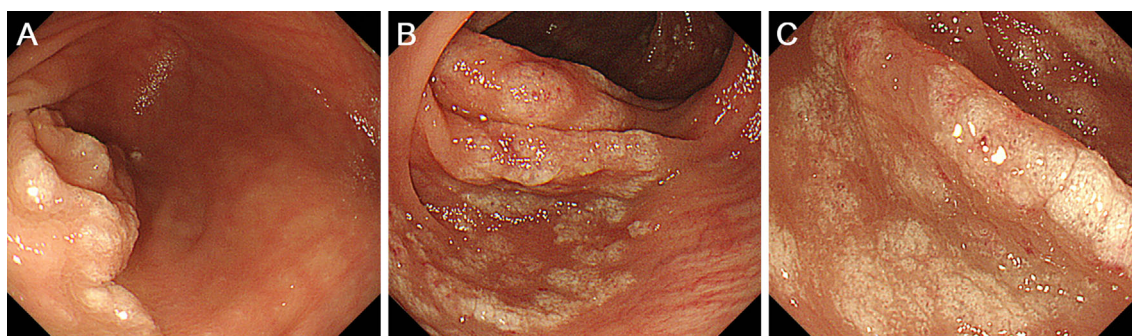


Figure 1. Colonoscopic images. Slightly elevated white lesions are observed in the cecum (A) and ascending colon (B, C).

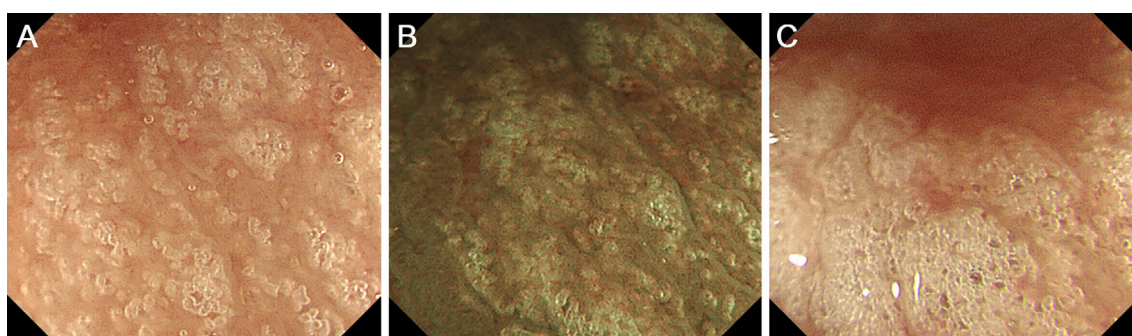


Figure 2. Magnifying observation images during colonoscopy. A magnifying observation (A) and narrow-band imaging (B) show microbubbles within the mucosa in the white lesions. In another part of the white lesions, the denser accumulation of microbubbles is observed (C).

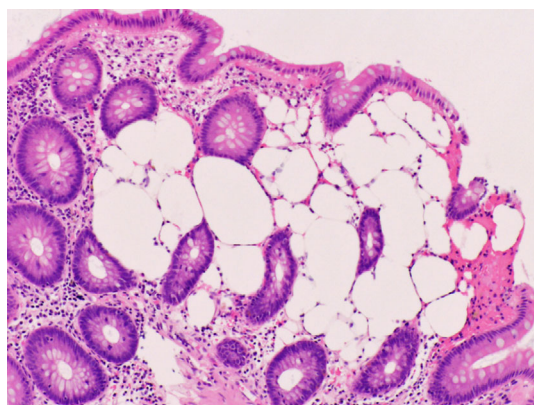


Figure 3. Pathology images. In the biopsy specimens from the white lesions of the large intestine, optically empty coalescent vacuoles are seen within the lamina propria, leading to the diagnosis of pseudolipomatosis.

vated ferritin level of 582.4 ng/mL. 18F-fluorodeoxyglucose positron emission tomography revealed the uptake of the tracer in the aorta and carotid, subclavian, and leg arteries. Ultrasonography revealed a perivascular halo sign in the superficial temporal artery. We performed a biopsy of the superficial temporal artery and confirmed the diagnosis of giant cell arteritis.

The treatment was initiated with 45 mg of oral prednisolone, voglibose, esomeprazole, and alfacalcidol. A week

later, the patient underwent screening colonoscopy. She had no abdominal symptoms at that time. Colonoscopy revealed the presence of slightly elevated white lesions in the cecum (Fig. 1A) and ascending colon (Fig. 1B and C). A magnifying observation (Fig. 2A) and narrow-band imaging (Fig. 2B) showed that there were microbubbles within the mucosa of the white lesions. The dense accumulation of microbubbles was seen in another part (Fig. 2C). Biopsy specimens from the white lesions revealed optically empty coalescent vacuoles within the lamina propria (Fig. 3). Consequently, the white lesions were identified as pseudolipomatosis. Esophagogastroduodenoscopy showed reflux esophagitis and erosive gastritis. There were no whitish or emphysematous lesions in the upper gastrointestinal tract. No specific treatment was initiated for the pseudolipomatosis of the colon.

One month after the colonoscopic examination, the patient presented with abdominal distension. On a physical examination, a snowball crepitation was noted on her chest. There were no peritoneal irritation signs in her abdomen. CT revealed pneumatosis intestinalis (Fig. 4A). Subcutaneous and mediastinal emphysema and pneumoperitoneum were noted in association with pneumatosis intestinalis (Fig. 4B). The patient's condition improved following oxygen administration at 3 L/min for 1 week and maintenance of a "nothing by mouth" status. Improvement in her pneumatosis intestinalis, pneumoperitoneum, and mediastinal emphysema was

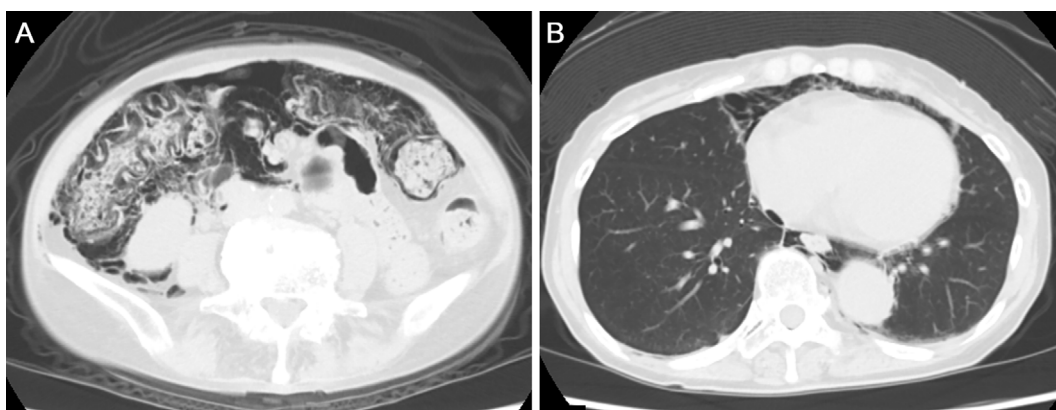


Figure 4. CT images. CT performed one month after the colonoscopic examination shows the presence of gas in the wall of the large intestine and pneumoperitoneum (A). Mediastinal emphysema is also noted (B).

confirmed by CT.

Discussion

Pseudolipomatosis of the large intestine is a rare disease. Kim et al. identified 12 cases with colonic pseudolipomatosis among 1,276 colonoscopies (0.94%) (2). The reported frequency ranges from 0.02% to 1.7% among all colonoscopies performed (2, 3, 6-9). Several mechanisms, such as chemical injury by a disinfectant, particularly hydrogen peroxide, and mechanical injury during an endoscopic procedure, have been hypothesized for the pathogenesis of colonic pseudolipomatosis (2, 10, 11). In addition, the epidemic occurrence of this disease has been reported when using colonoscopes sterilized with hydrogen peroxide and peracetic acid (2, 12). Cammarota et al. noted that colonic pseudolipomatosis appeared when the water button was depressed (12). They speculated that insufflation of air and/or water injection was responsible for releasing residual hydrogen peroxide in the endoscope, resulting in the subsequent appearance of mucosal pseudolipomatosis (1, 12). Experimental production of colonic pseudolipomatosis after exposure to hydrogen peroxide has also been reported in pig and rat models (10, 13). Consequently, residual hydrogen peroxide in the endoscope after rinsing is a possible cause for this disease in some patients.

Another possible cause is injury of the colonic mucosa caused by stretching, abrasive trauma, overinflation, and biopsies of the colon during endoscopy (2, 10, 11). These mechanical mucosal injuries may lead to the penetration of the luminal gas to the bowel wall. At our institution, hydrogen peroxide is not used for the sterilization of endoscopes. Therefore, its involvement is unlikely in the present patient. Instead, steroid use may have played a role in the induction of pseudolipomatosis, since the excess administration of glucocorticoids results in impaired wound healing and friable connective tissue (14).

As described previously, pseudolipomatosis of the large intestine appears as slightly elevated whitish or yellow

plaques (1, 2, 7). These lesions are often multiple, as shown in the present patient. Since the prevalence of this disease is low, the lesions are unfamiliar to endoscopists and may be confused for pseudomembranous colitis, colonic lipomatosis, or malakoplakia (2, 4, 15). In the present patient, a magnifying observation revealed microbubbles within the mucosa, which are a distinct pathological feature of this disease, presenting as optically empty coalescent vacuoles within the lamina propria. Therefore, a magnifying observation and identification of these microbubbles within the whitish to yellow lesions will provide clues that aid in the prompt diagnosis of pseudolipomatosis of the large intestine. To our knowledge, this report is the first to describe the magnifying endoscopic features of this disease.

Pseudolipomatosis of the large intestine is pathologically characterized by unlined spaces in the colorectal lamina propria (3). Although such cavities within the mucosa were initially considered to be adipocytes, Snover et al. revealed that these were not adipocytes, based on histochemical and ultrastructural analyses, and instead termed the lesions “pseudolipomatosis” (3). The endoscopic and histological lesions generally spontaneously disappear in 3 to 20 months (1, 7, 11, 12, 16). Thus, conservative management is acceptable for pseudolipomatosis of the large intestine (17).

Pneumatosis intestinalis is another distinct disease entity that is characterized by gas in the bowel wall and is often identified on abdominal radiography or CT. The typical pathological features of pneumatosis intestinalis are the presence of submucosal or subserosal empty spaces lined by histiocytes and giant cells (5). Of note, pseudolipomatosis is sometimes accompanied by pneumatosis intestinalis on a pathological analysis. Koreishi et al. retrospectively investigated the pathological features of 7 cases of pneumatosis intestinalis and found pseudolipomatosis in 4 of them (57.1%) (5). However, to our knowledge, there have been no previous reports describing the sequential progression from pseudolipomatosis of the large intestine to pneumatosis intestinalis or the simultaneous occurrence of both diseases diagnosed endoscopically and/or radiologically. In the present

patient, pneumatosis intestinalis emerged one month after the diagnosis of pseudolipomatosis. Small vacuoles within the lamina propria (i.e. pseudolipomatosis) may have grown, thereby leading to larger empty spaces in the submucosal and proper muscle layers (i.e. pneumatosis intestinalis) (18). We also speculate that pneumatosis intestinalis was already present when pseudolipomatosis was identified during the colonoscopic examination. Pneumatosis intestinalis subsequently worsened, leading to subcutaneous and mediastinal emphysema. Although further investigations are required to determine the causal association between these two entities, the present patient may be a proof-of-concept case showing a close relationship between pseudolipomatosis of the large intestine and pneumatosis intestinalis.

Pneumatosis intestinalis occurs in association with a wide range of underlying disorders such as inflammatory, autoimmune, collagen vascular, infectious, and pulmonary diseases. Traumatic, mechanical, and drug-induced damages or alterations of the colonic mucosa have also been suspected of being etiologies (5, 19-21). In the present patient, pneumatosis intestinalis might have arisen secondary to pseudolipomatosis, as described above. A biopsy and/or mechanical damage occurring during and caused by the colonoscopic procedure itself can trigger the emergence of pneumatosis intestinalis. However, the direct association between pneumatosis intestinalis and pseudolipomatosis, biopsies, and colonoscopic procedures is uncertain, as pneumatosis intestinalis was diagnosed one month after colonoscopy in our patient. Alternatively, pneumatosis intestinalis may have occurred independently in our patient because she received prednisolone and voglibose, both of which are known to cause pneumatosis intestinalis (22). Vasculitis of the mesenteric arteries as part of giant cell arteritis is a potential causal factor in the present patient as well.

In conclusion, in our patient, a magnifying observation showed microbubbles within the mucosa, which may be a distinctive feature reflecting the pathology of this disease. Furthermore, our patient showed pneumatosis intestinalis one month after colonoscopy. Although the exact pathogenesis is uncertain, pneumatosis intestinalis might arise secondary to pseudolipomatosis.

The authors state that they have no Conflict of Interest (COI).

References

- Jonas G, Mahoney A, Murray J, Gertler S. Chemical colitis due to endoscope cleaning solutions: a mimic of pseudomembranous colitis. *Gastroenterology* **95**: 1403-1408, 1988.
- Kim SJ, Baek IH. Colonic mucosal pseudolipomatosis: disinfectant colitis? *Gastroenterol Nurs* **35**: 208-213, 2012.
- Snover DC, Sandstad J, Hutton S. Mucosal pseudolipomatosis of the colon. *Am J Clin Pathol* **84**: 575-580, 1985.
- Kaassis M, Croue A, Carpentier S, Burtin P, Boyer J. A case of colonic pseudolipomatosis: a rare complication of colonoscopy? *Endoscopy* **29**: 325-327, 1997.
- Koreishi A, Lauwers GY, Misdragi J. Pneumatosis intestinalis: a challenging biopsy diagnosis. *Am J Surg Pathol* **31**: 1469-1475, 2007.
- Prignet JM, Carlot E, Kunkel D. Pseudolipomatose muqueuse rectosigmoïdienne révélée par une diarrhée chronique Discussion physiopathologique à propos d'un cas et revue de la littérature. *Acta Endoscopica* **25**: 175-178, 1995 (in French, Abstract in English).
- Brevet M, Chatelain D, Bartoli E, et al. Colonic pseudolipomatosis: clinical, endoscopic and pathological features in nine cases. *Gastroenterol Clin Biol* **30**: 9-13, 2006.
- Costa MN, Martins M, Barbosa J. Colonic pseudolipomatosis. *Gastrointest Endosc* **82**: 580, 2015.
- Ersoz F, Toros AB, Cakar E, et al. Colonic mucosal pseudolipomatosis: Are we aware of it? *Ulus Cerrahi Derg* **32**: 90-92, 2015.
- Sheehan JF, Brynjolfsson G. Ulcerative colitis following hydrogen peroxide enema: case report and experimental production with transient emphysema of colonic wall and gas embolism. *Lab Invest* **9**: 150-168, 1960.
- Waring JP, Manne RK, Wadas DD, Sanowski RA. Mucosal pseudolipomatosis: an air pressure-related colonoscopy complication. *Gastrointest Endosc* **35**: 93-94, 1989.
- Camarota G, Cesaro P, Cazzato A, et al. Hydrogen peroxide-related colitis (previously known as "pseudolipomatosis"): a series of cases occurring in an epidemic pattern. *Endoscopy* **39**: 916-919, 2007.
- Ryan CK, Potter GD. Disinfectant colitis. Rinse as well as you wash. *J Clin Gastroenterol* **21**: 6-9, 1995.
- Leibovich SJ, Ross R. The role of the macrophage in wound repair. A study with hydrocortisone and antimacrophage serum. *Am J Pathol* **78**: 71-100, 1975.
- Cipolletta L, Bianco MA, Fumo F, Orabona P, Piccinino F. Malakoplakia of the colon. *Gastrointest Endosc* **41**: 255-258, 1995.
- Ben Rejeb A, Khedhiri F. Mucosal pseudo-lipomatosis of the colon: apropos of a case with a review of the literature. *Arch Anat Cytol Pathol* **37**: 254-257, 1989.
- Magalhães MJ, Coelho A, Salgado M, Pedroto I. A rare case of colonic pseudolipomatosis. *Ann Gastroenterol* **28**: 146, 2015.
- Alper M, Akcan Y, Belenli OK, Cukur S, Aksoy KA, Suna M. Gastric pseudolipomatosis, usual or unusual? Re-evaluation of 909 endoscopic gastric biopsies. *World J Gastroenterol* **9**: 2846-2848, 2003.
- Heng Y, Schuffler MD, Haggitt RC, Rohrmann CA. Pneumatosis intestinalis: a review. *Am J Gastroenterol* **90**: 1747-1758, 1995.
- Pear BL. Pneumatosis intestinalis: a review. *Radiology* **207**: 13-19, 1998.
- St Peter SD, Abbas MA, Kelly KA. The spectrum of pneumatosis intestinalis. *Arch Surg* **138**: 68-75, 2003.
- Tsujimoto T, Shioyama E, Moriya K, et al. Pneumatosis cystoides intestinalis following alpha-glucosidase inhibitor treatment: a case report and review of the literature. *World J Gastroenterol* **14**: 6087-6092, 2008.

The Internal Medicine is an Open Access article distributed under the Creative Commons Attribution-NonCommercial-NoDerivatives 4.0 International License. To view the details of this license, please visit (<https://creativecommons.org/licenses/by-nc-nd/4.0/>).