

➤ **Original Article** ➤

# Cryopreserved Human Allografts for the Reconstruction of Aortic and Peripheral Prosthetic Graft Infection

Matteo Bossi, MD, Matteo Tozzi, MD, Marco Franchin, MD, Stefania Ferraro, MD, Nicola Rivolta, MD, Massimo Ferrario, MD, Chiara Guttadauro, MD, Patrizio Castelli, MD, and Gabriele Piffaretti, MD, PhD

**Background:** This study aimed to present cases with cryopreserved human allografts (CHAs) for vascular reconstruction in both aortic and peripheral infected prosthetic grafts. **Materials and Methods:** This is a single center, observational descriptive study with retrospective analysis. In all cases, the infected prosthetic graft material was completely removed. At discharge, patients were administered anticoagulants. Follow-up examinations included clinical visits, echo-color-Doppler ultrasounds, or computed tomography angiography within 30 days and at 3, 6, and 12 months after the treatment, and then twice per year.

**Results:** We treated 21 patients (90% men, n=19) with the mean age of 71±12 years and mean interval between the initial operation and replacement with CHA of 30 months [range, 1–216; interquartile range (IQR), 2–36]. In-hospital mortality was 14% (n=3); no CHA-related complication led to death. Limb salvage was 100%. No patient was lost at the median follow-up of 14 months (range, 2–61; IQR, 6–39). No rupture, aneurysmal degeneration, or re-infection occurred. Estimated freedom from CHA-related adverse events (95% confidence interval, 43–63) was 95% at 3 years.

**Conclusion:** In our experience, CHAs are a viable option for prosthetic graft infections and provide satisfactory clinical results and favorable stability because of a very low rate of CHA-related adverse events during follow-up.

**Keywords:** cryopreserved human allograft, prosthetic graft infection

*Vascular Surgery, Department of Medicine and Surgery, Circolo University Teaching Hospital, University of Insubria School of Medicine, Varese, Italy*

Received: June 26, 2017; Accepted: August 6, 2017  
Corresponding author: Gabriele Piffaretti, MD, PhD. Vascular Surgery, Department of Medicine and Surgery, Circolo University Teaching Hospital, University of Insubria School of Medicine, Via Guicciardini 9, 21100 Varese, Italy  
Tel: +39-332-393-259, Fax: +39-332-278-581  
E-mail: gabriele.piffaretti@uninsubria.it

## Introduction

Native prosthetic graft infection is undoubtedly one of the most dreaded vascular complications with overall mortality rate ranging from 9% to 28% and limb loss ranging from 10% to 20% of the cases.<sup>1–3</sup> In this setting, prosthetic graft excision plays a decisive role for the eradication of infection; nonetheless, vascular reconstruction remains a mainstay of surgical treatment to obtain better outcomes.<sup>4</sup> The restoration of in-line flow should be performed in an expedient manner using a readily available conduit that is resistant to re-infection and thrombosis and free from late structural degeneration.<sup>5</sup> Autologous veins are still ideal grafts to accomplish this type of reconstruction, but their use is frequently limited because of unavailability/unsuitability or because of the physiological impact of demanding operations, which should be performed in patients who are typically sick or harmed.<sup>6</sup> Both silver and antibiotic-bonded grafts are accepted alternatives but have been prone to poorer performances, especially for peripheral arterial reconstructions.<sup>7</sup>

Cryopreserved human allografts (CHAs) are proven to be suitable alternative conduits; they can offer the possibility of an anatomical reconstruction and ensure better infection resistance compared to prosthetic grafts.<sup>8</sup> However, the limited availability of suitable CHA segments have contributed to reports of contradictory results in terms of patency rate or allograft-related adverse events.<sup>9,10</sup>

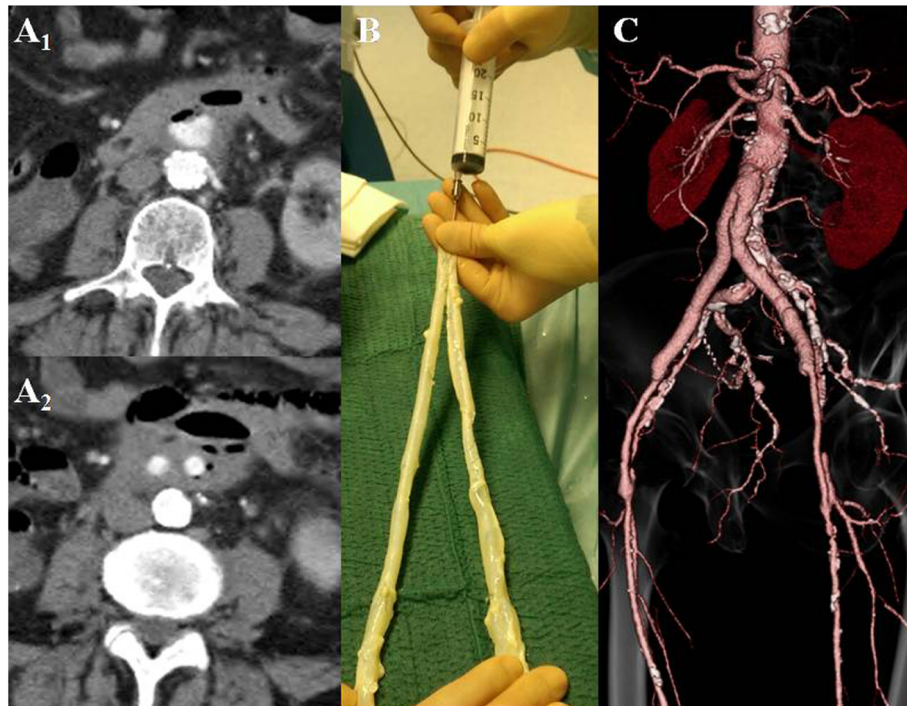
This study aimed to present cases with CHAs for vascular reconstruction in both aortic and peripheral infected prosthetic grafts.

## Materials and Methods

### Type of study

This is a single center, observational descriptive study with retrospective analysis of all patients treated with CHAs since January 2010; for the final analysis, the end of study was considered as March 31, 2016. All clinical and pro-





**Fig. 1** A case of infected aorto-bifemoral bypass: preoperative computed tomography angiography (**A<sub>1,2</sub>**) shows air bubbles surrounding the split flow and the limbs of the dacron prosthetic graft. At the bench (**B**), two segments of common/superficial femoral veins were anastomized to establish a “neo-aorto-iliac system.” (**C**) Postoperative computed tomography-angiography shows the result of allograft reconstruction.

cedural data were prospectively collected and recorded into a computerized database registry that remained consistent over the study period. Data entry was managed by physicians involved in patient care. Information about demographics, comorbidities, medical and surgical history, operative details, and postoperative events during the hospital stay and follow-up were all registered. Authors have full access to the database and take full responsibility for the integrity of the data. Informed consent was signed by each patient; the retrospective analysis of the anonymized data did not require approval from the Institutional Review Board.

### Clinical assessment and bacteriology

All patients clinically suspected with prosthetic graft infection were evaluated with full panel blood tests, including those for inflammatory markers and bloodstream and urinary tract cultures, and with radiological work-up, including computed tomography angiography (Fig. 1A<sub>1,2</sub>) and, in those suspected with aorto-enteric fistula, esophagogastroduodenoscopy. Upon admission, all patients were administered broad-spectrum antibiotics using a combination of glycopeptide (Vancotex<sup>®</sup>, Pharmatex, Milano, Italy) and penicillin/beta-lactamase inhibitors (Textazo<sup>®</sup>, Pharmatex, Milano, Italy). Thereafter, they were eventually replaced by other selective antibiotics based on the

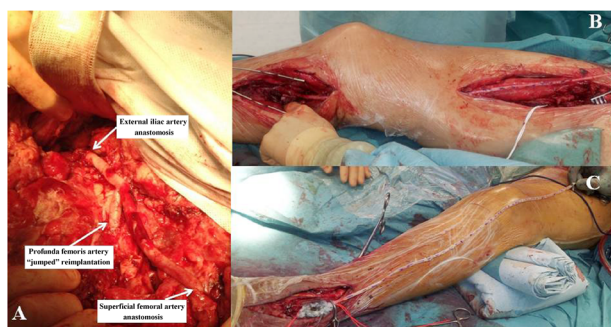
microbiological findings. A physician specializing in infectious diseases evaluated each patient upon admission and regularly during hospitalization to optimize the type, dosage, and duration of the antibiotic therapy.

### Operative technique and follow-up

When CHAs were available, we used them for elective repair in patients lacking autologous veins or who were unsuitable for a specific vascular reconstruction. CHAs used were harvested from brain-dead donors as part of a program to retrieve multiorgan transplant tissues. Bacteriology and virology tests were routinely performed in donors. We received CHAs by the Tissue Bank of the Centro Cardiologico Monzino (Milan, Italy), within 12–24 h of our request. Attempts were made to match donor and recipient blood types when possible, and CHAs were chosen to best match the recipient’s anatomic measurements.

Briefly, to save time, all vascular segments were prepared and tailored on another table while operating surgeons were operating the patient on the main table (Fig. 1B). Concurrently, another surgical equipe prepared the operative field. At the bench, we followed recognized principles for CHA preparation<sup>8)</sup>:

- Collateral branches of the CHA were ligated or sutured using a through-and-through polypropylene suture (Sur-gipro II<sup>™</sup>, Covidien Medtronic Inc., Santa Rosa, CA,



**Fig. 2** Cryopreserved human allografts for peripheral reconstruction: (A) a complete reconstitution of the iliac–femoral vessels using the superficial femoral vein from the external iliac artery to the superficial femoral artery, and reimplantation of the profunda femoris with a short interposition segment of the cryopreserved graft. Below-the-knee femoro-popliteal (B) bypass, and common femoral-to-pedideal artery (C) bypass, using the cryopreserved great saphenous vein.

USA).

- The length and anastomosis was optimized appropriately without the slightest tension; in case of inadequate dimensions, CHAs were obtained by performing anastomoses of the arterial segments.

For aorto-iliac graft infection, a median laparotomy was routinely performed; infrarenal aortic clamping was performed whenever possible. In all cases, native vessels that were macroscopically infected were excised, and the prosthetic graft material was removed completely. Periprosthetic tissues were aggressively debrided to obtain macroscopically normal tissues. All the specimens were cultured to test for aerobic and anaerobic bacteria and fungi. In case of aortic graft reconstruction, CHA was implanted “in situ” (Fig. 1C); extracavitary iliac–femoral (Fig. 2A) and femoro-distal bypasses were tunneled subcutaneously (Fig. 2B) and positioned “ex situ” (Fig. 2C). The latter technical aspects aimed to avoid contaminated tissues and to assess CHA easily using echo-color-Doppler ultrasound in order to detect any minimal intraluminal defect. Drains were routinely positioned. Generally, the infected field was covered with pedicled omentum in the abdomen and with the sartorius muscle flap in the groin. Postoperatively, all patients were admitted to the intensive care unit (ICU), received low-molecular-weight heparin twice per day for 1 week. Upon discharge, they were administered the anticoagulant warfarin sodium (Coumadin<sup>®</sup>, Bristol-Myers Squibb, Rome, Italy) to reach a therapeutic international normalized ratio of 2.0–3.0. No immunosuppressive agents were used. Follow-up examinations included clinical visit, echo-color-Doppler ultrasound, or computed tomography angiography within 30 days and at 3, 6, and 12 months after the treatment, and then twice per year.

## Definitions

A primary technical success was defined as the successful explants of the native vessel/prosthetic graft in the absence of death  $\leq 24$  h. Infected wounds were classified according to the depth of infection and degree of graft involvement, whereas graft infection extension at the time of graft replacement with CHA was classified based on the modified Bunt classification.<sup>11)</sup> Based on the time of appearance after prosthetic graft implantation, infection was defined early when it occurred  $< 4$  months and late when it was detected  $> 4$  months after the intervention.<sup>11)</sup> Follow-up index (FUI) is described as completed follow-up at the given end date of the study, computed as the ratio between the investigated and potential follow-up period.<sup>12)</sup> Major end-points were in-hospital mortality, CHA-related mortality, and freedom from CHA-related adverse events (thrombosis, aneurysmal degeneration, pseudoaneurysm, and/or infection).

## Statistical analysis

Clinical data were prospectively recorded and tabulated in Microsoft Excel (Microsoft Corp, Redmond, WA, USA) database: statistical analysis was performed with SPSS, version 23.0 for Windows (IBM SPSS Inc., Chicago, IL, USA). Categorical variables were presented using frequencies and percentages, and continuous variables were presented as mean  $\pm$  standard deviation (SD) and interquartile range (IQR); otherwise, medians with range were applied. Significant statistical difference was considered for  $P < 0.05$ . Survival and freedom from CHA-related adverse events were estimated using the Kaplan–Meier method and presented as percentage with 95% confidence interval (CI).

## Results

### Study cohort

We treated 21 patients (90% men;  $n = 19$ ) with the mean age of  $71 \pm 12$  years (range, 43–83; IQR, 66–80). Comorbidities and risk factors are summarized in Table 1, and patient characteristics with regard to previous procedure and CHA used are presented in Table 2. In 11 (52%) cases, the indexed intervention was performed on an urgent basis, and 13 (62%) cases had complicated course of wound infection (grade I,  $n = 9$ ; grade II,  $n = 4$ ) postoperatively.

### Characteristics of the graft infection

Regarding the time of appearance, 14 (67%) graft infections were late events: the mean interval between the initial operation and replacement with CHA was 30 months (range, 1–216; IQR, 2–36). Graft infection extension was as follows: Bunt’s  $P_0$  in 8 (38%),  $P_1$  in 8 (38%),  $P_2$  in 2

**Table 1** Clinical characteristics of the cohort

	CHAs (n=21)
Demographic data	
Male:female	19:2
Age (mean±SD)	71±12 (IQR, 66–80)
Comorbidities (%)	
Hypertension	18 (86)
CAD	12 (57)
Dyslipidemia	12 (57)
CRI	7 (33)
Diabetes	7 (33)
COPD	6 (28)
Risk factors	
Septic shock	4 (19)
Hemodialysis	2 (10)
Rupture	1 (5)
Immunosuppression Tx	1 (5)

CHAs: cryopreserved human allografts; SD: standard deviation; IQR: interquartile range; CAD: coronary artery disease; CRI: chronic renal insufficiency; COPD: chronic obstructive pulmonary disease; Tx: treatment

(9.5%), and P<sub>3</sub> in 3 (14%) cases. Clinical presentation included fever and leukocytosis in all patients: anastomotic abscess was also present in 13 (62%) cases, pseudoaneurysm in 7 (33%) cases, and active bleeding in 1 (5%) case.

### Operative details

We used 29 vascular segments as follows: great saphenous vein (n=7, 33%), superficial femoral vein (n=6, 28%), superficial femoral artery (n=5, 24%), external iliac artery (n=2, 9.5%), and inferior vena cava (n=1, 4.5%). In 14 (67%) cases, one CHA segment was needed to perform the vascular reconstruction, in 6 (28%) cases, two segments, and in 1 (5%) case, three segments (aorto-iliac reconstruction). Aorto-iliac, iliac–femoral, and femoro-femoral reconstructions were performed in situ at the same anatomic level; all but one (n=7) femoro-popliteal infected grafts required a tibial vessel reconstruction. The mean operation time was 4±1 h (range, 2–6; IQR, 3–5) with the mean blood loss of 1257±627 mL (range, 500–2300; IQR, 750–1900).

### Bacteriology

Microorganisms were identified in all but 1 (95%) case: in 18 (86%) cases, ≥2 microorganisms were isolated. Among

**Table 2** Patients' characteristics

Patient (n)	Year	Gender, age	Index intervention	CHA (type of graft)	Vascular reconstruction (anatomic extent)
1	2016	F, 81	"bk" FP bypass	SFV	FTp bypass
2	2016	M, 77	IF bypass	SFV	IF bypass
3	2016	M, 82	AbF bypass	SFV	AbF bypass
4	2016	M, 79	Femoral TEA+patch	SFV	IF bypass
5	2015	M, 80	"ak" FP bypass	GSV	FTp bypass
6	2015	M, 46	AbF bypass	EIA	AbF bypass
7	2015	M, 71	AbF bypass	SFV	AbF bypass
8	2015	M, 81	IF bypass	SFV	IF bypass
9	2015	M, 43	IF bypass	GSV	IF bypass
10	2015	F, 76	Femoral TEA+patch	SFA	IF bypass
11	2014	M, 78	"bk" FP bypass	SFA	FTPt bypass
12	2013	M, 80	"bk" FP bypass	GSV	FTp bypass
13	2013	M, 66	AbF bypass	IVC	IF bypass
14	2013	M, 63	FF bypass	SFA	FF bypass
15	2013	M, 78	FF bypass	SFA	FF bypass
16	2012	M, 83	"bk" FP bypass	GSV	FTp bypass
17	2011	M, 79	"bk" FP bypass	GSV	FTp bypass
18	2010	M, 53	FF bypass	SFA	IF bypass
19	2010	M, 69	Femoral TEA+patch	GSV	FF bypass
20	2010	M, 69	"bk" FP bypass	GSV	"bk" FP bypass
21	2010	M, 52	"ak" FP bypass	EIA	FTp bypass

n: number; M: male; F: female; CHA: cryopreserved human allograft; "bk": below-the-knee; FP: femoro-popliteal; IF: iliac–femoral; AbF: aorto-bifemoral; "ak": above-the-knee; TEA: thromboendarterectomy; FF: femorofemoral; SFV: superficial femoral vein; GSV: great saphenous vein; EIA: external iliac artery; SFA: superficial femoral artery; IVC: inferior vena cava; FTp: femoro-tibial posterior; FTPT: femoro-tibio-peroneal trunk

**Table 3** Postoperative complications and relative treatments

Complication <sup>§</sup>	n (%)	Treatment
Mild		
Wound dehiscence	2	Conservative
Severe		
Anastomotic bleeding	1	Re-exploration
Acute limb ischemia	1	Thromboembolectomy
Acute lung injury	1	C-PAP

§: Society for Vascular Surgery grading score; n: number; C-PAP: continuous positive air pressure

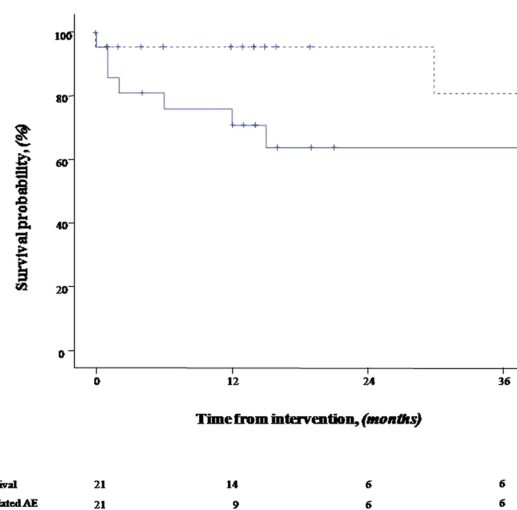
the microorganisms, methicillin-resistant *Staphylococcus aureus* was isolated in 15 (71%) cases, followed by *Escherichia coli* in 12 (57%) cases, and *Pseudomonas aeruginosa* in 6 (28%) cases; fungus (*Candida albicans*) was isolated in only 1 (5%) case. In the presence of systemic sepsis, the microorganisms isolated from graft culture and blood cultures were exactly the same.

### Early results

The primary technical success was 100%. In-hospital mortality was 14% (n=3): overwhelming sepsis was the cause of death in all cases. No CHA-related complication led to death. Major complications were observed in 5 (24%) cases (Table 3). Median ICU stay was 3 days (range, 1–34; IQR, 1–10); hospitalization was 32±18 days (range, 7–62; IQR, 18–41). Limb salvage was 100%: all survived patients had patent CHAs with no signs of structural degeneration.

### Late outcomes

No patient was lost at the median follow-up of 14 months (range, 2–61; IQR, 6–39); the FUI was 1. No patients received antibiotic therapy ad infinitum. The median survival was 41 months (95%CI, 29–53): 4 (22%) patients died at a mean of 11 (range, 6–15) months after the CHA replacement. Causes of death were unrelated to CHA failure or complications: major stroke (n=1, ischemic), chronic left heart failure (n=1), end-stage liver disease (n=1), and cancer (n=1). Estimated survival was 64% at 3 years (Fig. 3, whole line), whereas CHA-related mortality was never observed. When we compared patients who died to those who survived, significant differences were not detected in terms of the demographic data, comorbidities, time of onset of infection, procedural data, or bacteriological findings. The only CHA thrombosis occurred 30 months after the prosthetic graft replacement: reintervention was not indicated because of a mild claudication. Overall primary patency and limb salvage were 94% and 100%, respectively. No rupture, degenerated aneurysm, or re-infection occurred; the estimated freedom from CHA-related adverse events (95%CI, 43–63) was 95% at 3 years (Fig. 3, dashed line).



**Fig. 3** Kaplan–Meier estimate of overall survival and freedom from CHA-related adverse events (FF CHA-related AE).

### Discussion

Prosthetic graft infection is one of the most feared threats in vascular surgery. In a recent extensive series, Kieffer et al.<sup>13)</sup> reported a 30-day and long-term mortality of 20.1% and 25.9%, respectively. This series reported only on aortic reconstructions and included fresh allografts that were outscored, and then widely established, by CHAs in terms of clinical and technical outcomes. Our in-hospital and follow-up mortality rates of 13% and 22% are comparable to the reports of other major series, which included all types of CHAs in both aortic and peripheral CHAs. Brown et al.<sup>9)</sup> reported an overall mortality, for both aortic and peripheral reconstructions, of 5.1% and 11%, respectively. These data confirm how graft infection is still truly harmful at different levels, either aortic or peripheral.

A controversy still existed on the optimal surgical intervention for infected vascular grafts. The treatment modality have been tailored based on the clinical scenario, patient's condition, and type of intervention.<sup>6,14)</sup> However, the ideal conduit should be readily available and must ensure resistance to re-infections, thrombosis, or aneurysmal degeneration in different vascular segments. Silver-bonded dacron grafts eliminate the long time periods lost for preparing the autologous veins, but have a dismal primary patency, especially for below-the-knee revascularizations.<sup>9)</sup> In contrast, the great saphenous vein represents the best conduit for long-term patency and re-infection resistance, but may have inadequate diameter or characteristics in up to 30% of patients and time-consuming preparations.<sup>15)</sup> CHAs may represent a valid alternative graft conduit when autologous veins are not present or unsuitable. Although they are not always readily available,

CHA is our first-line alternative conduit, regardless of the type of graft because they mimic the structural and hemodynamic characteristics of autologous vessels while avoiding the demanding operations for their harvesting.<sup>16–18)</sup>

Considering graft patency, some reports have suggested that CHAs are prone to thrombosis because of a host response against the graft.<sup>19)</sup> Patency rates reported by many investigators with venous CHAs were low. In the most extensive series so far, Farber et al.<sup>20)</sup> performed 240 infrainguinal revascularizations for limb salvage and achieved a primary patency rate of 30% at 1 year and 18% at 2 years. Other series reported similar results.<sup>21)</sup> However, most of these interventions were distal revascularization for limb salvage, which represents the worst setting for any type of vascular conduit. It is impossible to draw definitive conclusions regarding the reasons for our good results, especially because we needed to target a more distal vessel in almost all cases of infected peripheral bypass; further, we did not have long-term follow-up, and the cohort mixed aortic and peripheral reconstructions. However, we believe that the meticulous preparation of both arterial and venous grafts and the postoperative anticoagulation that has not been routinely used in other experiences may have helped emphasize the hemodynamic characteristic of this biological graft.

Structural degenerations, meaning anastomotic rupture or aneurysmal enlargement of the whole graft, were related to complications of CHA reconstructions.<sup>22,23)</sup> However, it has been already recognized that CHA durability has become excellent since the advent of cryopreservation; the basic collagenous network of arteries is preserved, giving a mechanical stability similar to native arteries.<sup>14)</sup> Similarly to our results, Brown et al.<sup>9)</sup> reported no cases of aneurysmal degeneration during the follow-up. Some adjunctive variables may have played a key role for these satisfactory outcomes. Indeed, the small cohort can be intuitive; however, the overall results reflect a growing experience, which has ameliorated the quality of both selection and preparation of CHAs, the refinements of surgical technique with the adjunct of graft coverage, and the meticulous graft surveillance with potential positive contributors.

Persistent or recurrent infections have been reported ranging from 5% to 10% post CHA reconstructions mainly because of infections extending to the adjacent tissues.<sup>7–10,13,15–21,24)</sup> To minimize this potential complication, we used a multimodal approach: complete original graft removal, extra-anatomical CHA positioning (peripheral cases) to avoid an extensively contaminated bed, aggressive peri-prosthetic debridement of contaminated tissues, coverage of the CHA with a pediculated omentum flap (abdominal cases) or a sartorius myoplasty (peripheral cases), close follow-up, and prolonged multiple anti-microbial therapy.<sup>8,9)</sup> In our opinion, this aggressive manage-

ment has been effective. In the early postoperative period, none of our patients died because of persistent/recurrent infection, even though all of them presented multiple signs of systemic sepsis upon admission. Moreover, although long-term follow-up period would have been a concern for recurrent infections, the freedom from infective complications at a mean follow-up period of 20 months has been satisfactory.

### Limitation

The present study has the following limitations: the cohort is small and heterogeneous, which does not allow drawing definitive conclusions on the use of CHAs in an arterial infection setting. Second, it is a retrospective study. Despite these limitations and considering the heterogeneity of the etiopathogenesis that led to several series of mixed cohort lesions, our technical strategy has been homogeneously standardized and follow-up was consistently performed in all patients.

### Conclusion

In our experience, vascular reconstruction with CHAs is a viable surgical option in patients with prosthetic graft infections because it is safe with satisfactory clinical results and favorable stability of the allograft owing to a very low rate of CHA-related adverse events during follow-up.

### Acknowledgments

None.

### Funding

No funding was received for this work.

### Disclosure Statement

None.

### Author Contributions

Study conception: MB, MT, GP

Data collection: MB, CG, GP

Analysis: MB, CG, GP

Investigation: MB, MT, MF, SF, NR, MF, CG, PC

Writing: MB, GP

Funding acquisition: this work was unsupported; no funding was received.

Critical review and revision: all authors

Final approval of the article: all authors

Accountability for all aspects of the work: all authors

## References

- 1) Mertens RA, O'Hara PJ, Hertzner NR, et al. Surgical management of infrainguinal arterial prosthetic graft infections: review of a thirty-five-year experience. *J Vasc Surg* 1995; **21**: 782-90; discussion, 782-91.
- 2) Calligaro KD, Veith FJ, Dougherty MJ, et al. Management and outcome of infrapopliteal arterial graft infections with distal graft involvement. *Am J Surg* 1996; **172**: 178-80.
- 3) O'Connor S, Andrew P, Batt M, et al. A systematic review and meta-analysis of treatments for aortic graft infection. *J Vasc Surg* 2006; **44**: 38-45.
- 4) Oderich GS, Bower TC, Cherry KJ Jr, et al. Evolution from axillofemoral to in situ prosthetic reconstruction for the treatment of aortic graft infections at a single center. *J Vasc Surg* 2006; **43**: 1166-74.
- 5) Vardanian AJ, Chau A, Quinones-Baldrich W, et al. Arterial allograft allows in-line reconstruction of prosthetic graft infection with low recurrence rate and mortality. *Am Surg* 2009; **75**: 1000-3.
- 6) De Donato G, Setacci F, Galzerano G, et al. Prosthesis infection: prevention and treatment. *J Cardiovasc Surg (Torino)* 2014; **55**: 779-92.
- 7) Bisdas T, Wilhelm M, Haverich A, et al. Cryopreserved arterial homografts vs silver-coated Dacron grafts for abdominal aortic infections with intraoperative evidence of microorganisms. *J Vasc Surg* 2011; **53**: 1274-81.
- 8) Vogt PR, Brunner-LaRocca HP, Lachat M, et al. Technical details with the use of cryopreserved arterial allografts for aortic infection: influence on early and midterm mortality. *J Vasc Surg* 2002; **35**: 80-6.
- 9) Brown KE, Heyer K, Rodriguez H, et al. Arterial reconstruction with cryopreserved human allografts in the setting of infection: a single-center experience with midterm follow-up. *J Vasc Surg* 2009; **49**: 660-6.
- 10) Minga Lowampa E, Holemans C, Stiennon L, et al. Late fate of cryopreserved arterial allografts. *Eur J Vasc Endovasc Surg* 2016; **52**: 696-702.
- 11) Back MR. Local complications: graft infection. In: Rutherford's Vascular Surgery, 7th edition, Philadelphia: Saunders Elsevier, 2006: 643-61.
- 12) von Allmen RS, Weiss S, Tevaearai HT, et al. Completeness of follow-up determines validity of study findings: results of a prospective repeated measures cohort study. *PLoS ONE* 2015; **10**: e0140817.
- 13) Kieffer E, Gomes D, Chiche L, et al. Allograft replacement for infrarenal aortic graft infection: early and late results in 179 patients. *J Vasc Surg* 2004; **39**: 1009-17.
- 14) Vogt PR. Arterial allografts in treating aortic graft infections: something old, something new. *Semin Vasc Surg* 2011; **24**: 227-33.
- 15) Touma J, Cochenne F, Parisot J, et al. In situ reconstruction in native and prosthetic aortic infections using cryopreserved arterial allografts. *Eur J Vasc Endovasc Surg* 2014; **48**: 292-9.
- 16) Gabriel M, Pukacki F, Dzieciuchowicz Ł, et al. Cryopreserved arterial allografts in the treatment of prosthetic graft infections. *Eur J Vasc Endovasc Surg* 2004; **27**: 590-6.
- 17) Castier Y, Francis F, Cerceau P, et al. Cryopreserved arterial allograft reconstruction for peripheral graft infection. *J Vasc Surg* 2005; **41**: 30-7.
- 18) Aavik A, Lieberg J, Kals J, et al. Ten years experience of treating aorto-femoral bypass graft infection with venous allografts. *Eur J Vasc Endovasc Surg* 2008; **36**: 432-7.
- 19) Randon C, Jacobs B, De Ryck F, et al. Fifteen years of infrapopliteal arterial reconstructions with cryopreserved venous allografts for limb salvage. *J Vasc Surg* 2010; **51**: 869-77.
- 20) Farber A, Major K, Wagner WH, et al. Cryopreserved saphenous vein allografts in infrainguinal revascularization: analysis of 240 grafts. *J Vasc Surg* 2003; **38**: 15-21.
- 21) Albertini JN, Barral X, Branchereau A, et al. Long-term results of arterial allograft below-knee bypass grafts for limb salvage: a retrospective multicenter study. *J Vasc Surg* 2000; **31**: 426-35.
- 22) Lehalle B, Geschier C, Fiévé G, et al. Early rupture and degeneration of cryopreserved arterial allografts. *J Vasc Surg* 1997; **25**: 751-2.
- 23) Chiesa R, Astore D, Piccolo G, et al. Fresh and cryopreserved arterial homografts in the treatment of prosthetic graft infections: experience of the Italian Collaborative Vascular Homograft Group. *Ann Vasc Surg* 1998; **12**: 457-62.
- 24) Harlander-Locke MP, Harmon LK, Lawrence PF, et al.; Vascular Low-Frequency Disease Consortium. The use of cryopreserved aortoiliac allograft for aortic reconstruction in the United States. *J Vasc Surg* 2014; **59**: 669-74.