

## Case Report

## Posterior longitudinal ligament and its implications in intradural cervical disc herniation: Case report and review of the literature

Christian Brogna<sup>1,2</sup>, José Pedro Lavrador<sup>1</sup>, Sabina Patel<sup>1</sup>, Francesco Vergani<sup>1</sup>, Sanjeev Bassi<sup>1</sup>, Gordan Grahovac<sup>1</sup>, Ranjeev Bhangoo<sup>1</sup>, Keyoumars Ashkan<sup>1</sup>

<sup>1</sup>Neurosurgical Department, King's College Hospital Foundation Trust, <sup>2</sup>Institute of Psychiatry, Psychology and Neuroscience, King's College London, London, United Kingdom

E-mail: \*Christian Brogna - [Christian.brogna@nhs.net](mailto:Christian.brogna@nhs.net); Jose Pedro Lavrador - [josepedro.lavrador@nhs.net](mailto:josepedro.lavrador@nhs.net); Sabina Patel - [spatel21@nhs.net](mailto:spatel21@nhs.net); Francesco Vergani - [francesco.vergani@nhs.net](mailto:francesco.vergani@nhs.net); Sanjeev Bassi - [sanj.bassi@nhs.net](mailto:sanj.bassi@nhs.net); Gordan Grahovac - [gordan.grahovac@nhs.net](mailto:gordan.grahovac@nhs.net); Ranjeev Bhangoo - [ranj.bhangoo@nhs.net](mailto:ranj.bhangoo@nhs.net); Keyoumars Ashkan - [k.ashkan@nhs.net](mailto:k.ashkan@nhs.net)

\*Corresponding author

Received: 12 February 18 Accepted: 23 April 18 Published: 18 June 18

### Abstract

**Background:** Intradural disc herniations (IDH) are rare, particularly in the cervical spine, where they account for less than 5% of all discs. Adhesions between the ossified/calcified posterior longitudinal ligament (OPLL), dura, and ossified/calcified disc herniations increase the complexity of resecting these cervical lesions.

**Case Description:** A 42-year-old male presented with a rapidly progressive cervical myelopathy over a 2-month period. This was attributed to an ossified/calcified intradural cervical disc herniation in conjunction with OPLL. The anterior cervical discectomy and fusion (ACDF) resulted in a dural defect but there was no cerebrospinal fluid (CSF) fistula as the arachnoid membrane remained intact. Had there been a CSF leak, it would have warranted both wound-peritoneal (WP) and lumbo-peritoneal shunts (LP). The surgeons should have anticipated that a CSF leak would likely occur prior to performing the ACDF, and should have prophylactically prepared and draped the abdomen for a potential WP, followed by a LP shunt. Three months postoperatively, the patient's proprioceptive deficit improved, and he almost completely recovered motor function.

**Conclusion:** Performing an ACDF for resection of an intradural calcified/ossified disc with OPLL often results in both a dural defect and CSF fistula. As the arachnoid membrane rarely remains intact, the spine surgeon should be prepared to immediately perform both a WP shunt, and subsequently, an LP. In this case, following an ACDF, resection of an intradural ossified disc with OPLL resulted in an isolated dural defect without a CSF fistula and did not require no dural repair or shunting procedures.

**Key Words:** CSF leak, intradural cervical disc herniation, posterior longitudinal ligament

#### Access this article online

**Website:**

[www.surgicalneurologyint.com](http://www.surgicalneurologyint.com)

**DOI:**

10.4103/sni.sni\_29\_18

**Quick Response Code:**

This is an open access journal, and articles are distributed under the terms of the Creative Commons Attribution-NonCommercial-ShareAlike 4.0 License, which allows others to remix, tweak, and build upon the work non-commercially, as long as appropriate credit is given and the new creations are licensed under the identical terms.

**For reprints contact:** [reprints@medknow.com](mailto:reprints@medknow.com)

**How to cite this article:** Brogna C, Lavrador JP, Patel S, Vergani F, Bassi S, Grahovac G, et al. Posterior longitudinal ligament and its implications in intradural cervical disc herniation: Case report and review of the literature. *Surg Neurol Int* 2018;9:119.

<http://surgicalneurologyint.com/Posterior-longitudinal-ligament-and-its-implications-in-intradural-cervical-disc-herniation:-Case-report-and-review-of-the-literature/>

## INTRODUCTION

Intradural herniations (IDH) are rare and most commonly present in the lumbar (92%), followed by the thoracic (5%) and cervical spine (3%).<sup>[5]</sup> Since Marega first described a cervical IDH in 1959,<sup>[4]</sup> 30 such cases have been reported in the literature [Table 1].<sup>[1,3-9]</sup> When calcified/ossified IDH typically occur in conjunction with OPLL, they result in both durotomies and CSF fistulas.<sup>[6,8]</sup> Anticipation of such CSF leaks should prophylactically include preparation to perform a wound-peritoneal (WP) and subsequent lumbo-peritoneal (LP) shunts.<sup>[2]</sup>

Here, a patient with an ossified/calcified cervical IDH with OPLL underwent an ACDF with durotomy but without an accompanying cerebrospinal fluid (CSF) fistula that did not warrant any shunting procedures.

## CASE REPORT

### Clinical findings

A 42-year-old male presented with a 2-month history of a cervical myelopathy that had rapidly progressed over the past 2 weeks. He exhibited a left hemiparesis (2/5 motor) but normal function on the right side, which was accompanied by hypoesthesia in both lower extremities. Interestingly, reflexes remained intact bilaterally, and he retained normal sphincter function.

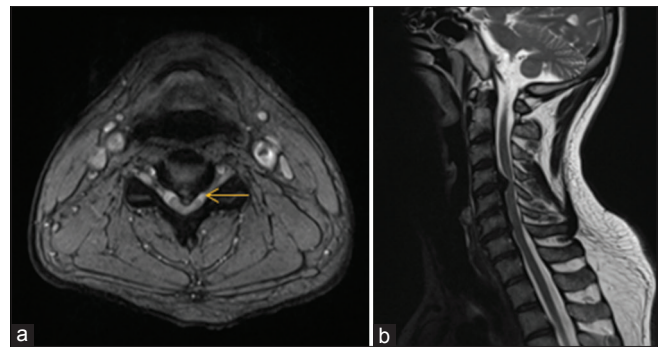
### Radiographic evaluation

The cervical spine magnetic resonance imaging (MRI) showed a large ossified/calcified central disc herniation at the C4/5 level with OPLL contributing to marked ventral cord compression [Figure 1]. As no preoperative computed tomography (CT) was performed, no single-layer or double-layer signs could clearly signal the presence of OPLL.

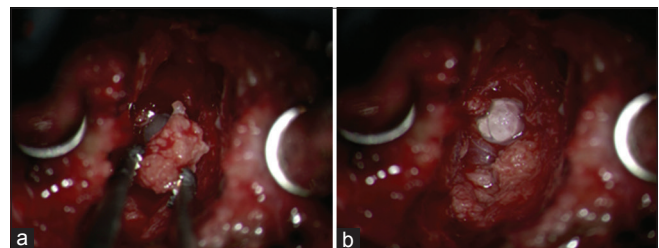
When an ACDF was performed, they encountered a large calcified disc fragment with OPLL that was removed *en bloc*. Although there was a tear in the dura, the arachnoid remained intact; there was no accompanying cerebrospinal fluid (CSF) fistula [Figure 2]. Therefore, no shunting procedures were warranted. Postoperatively, the patient's left hemiparesis was partially resolved, however, the sensory deficit remained. Notably, the postoperative MRI scan revealed adequate spinal cord decompression, but a punctate intramedullary C4-C5 cord contusion [Figure 3]. There were no postoperative complications, and 3 months later, the patient's motor deficit fully resolved; however, he exhibited residual proprioceptive deficits.

## DISCUSSION

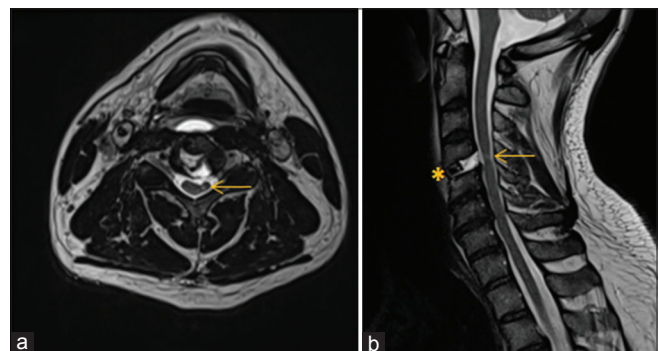
The pathogenesis of IDH include congenital narrowing of the spinal canal, chronic compression of a highly mobile



**Figure 1:** Axial T2-weighted (a) and Sagittal T2-weighted (b) images revealing central C4-C5 disc extrusion with effacement of the anterior subarachnoid space and compression / indentation of the spinal cord (hawk beak sign or Y sign, suggestive of intradural disc herniation – arrow)



**Figure 2:** (a) En bloc removal of the calcified disc fragment, protruding through the posterior longitudinal ligament and through the dura. (b) Central defect in the dura is observed, with arachnoid exposed. No CSF leak. Cord seen nicely pulsating through the arachnoid



**Figure 3:** Axial T2-weighted (a) and Sagittal T2-weighted (b) images revealing status post-anterior discectomy and fusion (asterisk) with repermeabilization of the anterior subarachnoid space and decompression of the spinal cord (punctate left paramedian spinal cord lesion is seen - arrow)

segment of the spinal canal, and adhesions between the calcified/ossified ligaments, OPLL, and dura.<sup>[6,8]</sup> Here, the patient had a calcified/ossified IDH with OPLL and chronic cervical cord compression.

IDH with OPLL can be intra-arachnoidal (e.g. due to adhesions/calcification between the PLL and the dura) or extra-arachnoidal. Therefore, high CSF leak rates are reported for anterior OPLL surgery (e.g. 4.3–32%).<sup>[5]</sup> In this review [Table 1],<sup>[1,3-9]</sup> we report 6 CSF leaks for

**Table 1: Historical review of the published cervical IDH cases<sup>[1,3-9]</sup>**

Author/year	Level	Sex	Age	Precipitant	PLL	Duration of symptoms	Onset of symptoms	Symptoms	Surgical approach	CSF leak	Follow-up
Marega (1959)	-	-	-	-	-	-	-	-	-	-	-
Durig <i>et al.</i> (1982)	-	-	-	Trauma of the cervical spine	Adhesions	8 years	Acute	Paraplegia and progression to Brown-Séquard syndrome	Laminectomy	-	-
Roda <i>et al.</i> (1982)	C6-C7	M	43	-	-	-	-	Cervical pain and right upper limb weakness	-	-	Mild residual hemiparesis
De Barros <i>et al.</i> (1984)	C4	M	young	Motor vehicle accident	-	3 months	Acute	Lhermitte sign	Corpectomy and adjacent discectomies	-	-
Jomin <i>et al.</i> (1985)	-	-	-	-	-	-	-	-	-	-	-
Eisenberg <i>et al.</i> (1986)	-	-	-	-	-	-	-	-	-	-	-
Lechowski <i>et al.</i> (1986)	C5-C6	-	-	Trauma	-	-	-	-	-	-	Incomplete recovery
Vernay <i>et al.</i> (1986)	-	-	-	-	-	-	-	-	-	-	-
Parnell (1988)	C5-C6	M	47	Sport activity	Intact PLL	2 months	Acute	Cervical pain and right-sided hemiparesis	Anterior cervical discectomy and fusion (Cloward technique)	Yes (duroplasty with surgicell)	Hemiparesis resolved and neck pain improved
Schneider <i>et al.</i> (1988)	-	-	-	-	-	-	-	-	-	-	-
Destee <i>et al.</i> (1989)	C5-C6 and C6/C7	M	31	Spinal manipulation	OPLL	10 days	Subacute	Spastic tetraparesis and areflexic bladder (previous torticollis for right-sided cervico-brachial neuralgia)	Two-level anterior discectomy	Yes	3 weeks after surgery, the patient was able to stand in the upright position
Lee <i>et al.</i> (1989)	C6-C7	M	53	Load lifting	-	-	-	Left hemiparesis	-	-	6 months later the patient had normal muscle strength on the left side
Epstein <i>et al.</i> (1990)	-	-	-	-	-	-	-	-	-	-	---
Sprick <i>et al.</i> (1991)	-	-	-	-	-	-	-	-	-	-	-
Yildizhan <i>et al.</i> (1991)	-	-	-	-	-	-	-	-	-	-	-
Ozer <i>et al.</i> (1994)	C5-C6	F	36	Motor vehicle accident	-	-	-	Cervical pain and right-sided hemiparesis and hypoesthesia	-	-	Cervical pain improved at 10 months of follow-up
Mihara <i>et al.</i> (1998)	-	-	-	-	-	-	-	-	-	-	-

Contd...

**Table 1: Contd...**

Author/year	Level	Sex	Age	Precipitant	PLL	Duration of symptoms	Onset of symptoms	Symptoms	Surgical approach	CSF leak	Follow-up
Borm <i>et al.</i> (2000)	C5-C6	M	40	-	-	-	-	Brown-Séquard syndrome	Anterior cervical discectomy	-	Complete resolution of symptoms
Iwamura <i>et al.</i> (2001)	C6-C7	M	45	-	Adhesion	-	-	Brown-Séquard syndrome	Corpectomy and fusion (C5-T1 with fibular strut graft)	No	Complete motor recovery with residual minor sensory disturbance
Neroni <i>et al.</i> (2007)	C6-C7	F	52	-	-	-	Acute	Right hemiparesis with right hand ataxia (diagnosed with Klippel-Feil syndrome)	ACDF and plating	No	Postoperative remission of symptoms
Woischneck <i>et al.</i> (2009)	C7-T1	F	-	Trauma	-	-	-	C8 cervico-brachialgia and hypoesthesia, lower limb ataxia	Dorsolateral approach	-	Complete recovery 6 months after surgery
Hsieh <i>et al.</i> (2010)	C3-C4	-	-	Spinal manipulation	OPLL	-	Acute	Brown-Séquard Syndrome	Anterior cervical discectomy and fusion with anterior plating	-	Brown-Sequard syndrome improved and the patient achieved 5/5 muscle power at 3-month follow-up
Kansal <i>et al.</i> 2011	C5/6	M	45	After heavy lifting	-	N/A	Immediate	Brown-Séquard syndrome	ACD	Post op	Improved weakness
Warade <i>et al.</i> (2013)	C6/7	M	64	Spontaneous	-	2 weeks	24 hours	Cervical pain and left-sided hemiparesis	ACD	Yes	Residual paresis
Westwick <i>et al.</i> (2014)	C4/5 - C5/6	F	52	Spontaneous	OPLL	4 weeks	72 hours	Cervical pain, tetraparesis and sensory deficits	Corpectomy and fusion	Yes	Full recovery
Wang (2014)	C5/6	M	52	Spontaneous	OPLL	6 months	Acute	Brown-Sequard Syndrome	Corpectomy and fusion	Yes	Improved weakness, mild paraesthesia
Yang <i>et al.</i> (2016)	C4-C5 and C5-C6	M	32	Spinal manipulation	Adhesions	24 hours	Acute	Tetraparesis and voiding difficulty	Two-level ACDF and plating	No	Nearly full muscle power at 12 months
Baudracco <i>et al.</i> (2017)	C4-C5	F	45	-	-	-	Acute	Brown-Séquard syndrome and Claude-Bernard-Horner syndrome	Anterior cervical corpectomy and fusion	No	Complete recovery at 6 months postoperative
Present report, 2018	C4/5	M	42	Spontaneous	No	2 months	1 week	Brown-Sequard syndrome	ACDF	No	Mild improvement, ongoing paraesthesia

ACDF; 50% were due to OPLL. In this case, the potential for a CSF leak should have been anticipated, and prophylactically, the patient should have been prepared and draped for a possible immediate intraoperative WP

shunt followed by a LP shunt.<sup>[2]</sup> Nevertheless, fortunately the C4-C5 calcified/ossified disc/OPLL excision resulted in a durotomy without a CSF fistula and no such shunts were required.

## CONCLUSION

Here, a patient with a calcified/ossified cervical IDH/OPLL sustained a durotomy without a CSF fistula during an ACDF. No shunting procedures (WP and LP shunts) were required as the arachnoid remained intact. In the future, the spinal surgeon should obtain a preoperative CT to supplement MRI as this would best identify the classical single or double-layer signs indicating OPLL dural penetrance. This would have warned the surgeon of a potential anterior dural/arachnoidal fistula, and would have enabled them to prophylactically prepare and drape for and anticipate a CSF fistula requiring both an immediate WP, followed by an LP shunt.

## Declaration of patient consent

The authors certify that they have obtained all appropriate patient consent forms. In the form the patient(s) has/have given his/her/their consent for his/her/their images and other clinical information to be reported in the journal. The patients understand that their names and initials will not be published and due efforts will be made to conceal their identity, but anonymity cannot be guaranteed.

## Financial support and sponsorship

Nil.

## Conflicts of interest

There are no conflicts of interest.

## REFERENCES

1. Baudracco I, Grahovac G, Russo VM. Spontaneous cervical intradural disc herniation presenting with Brown-Séquard and Horner's syndrome: Lesson learned from a very unique case. *Eur Spine J* 2017;26(Suppl 1):218-21.
2. Epstein NE. Wound-peritoneal shunts: Part of the complex management of anterior dural lacerations in patients with ossification of the posterior longitudinal ligament. *Surg Neurol* 2009;72:630-4;discussion 634.
3. Harrison J, Goldstein CL, Shamji MF. Acute spontaneous cervical disc herniation causing rapidly progressive myelopathy in a patient with comorbid ossified posterior longitudinal ligament: Case report and literature review. *Surg Neurol Int* 2014;5:68-72.
4. Marega T. Ernia del disco cervicale espulsa nel sacco durale. *Arch Putti Chir Organi Mov* 1959;12:425-30.
5. Pan J, Li Lijun, Qian L, Teng H, Shen B, Tan J, et al. Intradural cervical disc herniation. *Spine* 2011;36:1033-7.
6. Wang X, Chen D, Yuan W, Zhang Y, Xiao J, Zhao J. Anterior surgery in selective patients with massive ossification of posterior longitudinal ligament of cervical spine: Technical note. *Eur Spine J* 2012;121:314-21.
7. Wang Z, Sunna T. Intradural lumbar disc herniation associated with degenerative spine disease. *Int J Neurorehabil* 2015;2:2376-0281.
8. Warade AG, Misra BK. Spontaneous cervical intradural disc herniation. *J Clin Neurosci* 2014;21:872-3.
9. Yang HS, Oh YM, Eun JP. Cervical intradural disc herniation causing progressive quadriparesis after spinal manipulation therapy: A case report and literature review. *Medicine (Baltimore)* 2016;95:e2797.