

Ophthalmic associations of oculodermal melanocytosis in a tertiary eye hospital in South Asia

Bipul Kumer De Sarker , Mohammad Ibn Abdul Malek, Sadiq Abdullahi, Sazzad Iftekhar, Nazmus Sakeb, Mallika Mahatma and Mridul Kumar Sarkar

Ther Adv Ophthalmol

2021, Vol. 13: 1–6

DOI: 10.1177/
2515841421993539

© The Author(s), 2021.
Article reuse guidelines:
[sagepub.com/journals-](https://sagepub.com/journals-permissions)
permissions

Abstract: Oculodermal melanocytosis (ODM), though rare, is associated with a number of sight-threatening complications including glaucoma. The purpose of this Case Series study was to determine the ophthalmic features in patients diagnosed with ODM. Here, we describe five patients presented with ODM, with the most common ocular features identified being hyperpigmentation of the conjunctiva, sclera and heterochromia iridis. Others included hyperpigmentation of trabecular meshwork, glaucoma, cataract, retinal detachment and ocular hypertension in one patient. As such, all patients with ODM should have a comprehensive ocular evaluation.

Keywords: glaucoma, hyperpigmentation, oculodermal melanocytosis, ophthalmic features

Received: 28 April 2020; revised manuscript accepted: 11 January 2021.

Introduction

Oculodermal melanocytosis (ODM), also known as naevus of Ota, is a rare disease characterized by slate-grey hyperpigmentation of the facial area supplied by the ophthalmic and maxillary division of trigeminal nerve as well as some ocular structures.¹ The discoloration could also be brown or blue. It was first described by Ota in 1939 as an overgrowth of tissues normally found in the affected area and therefore can be termed a hamartoma.² The hyperpigmentation of the ocular tissues typically involves the conjunctiva, episclera, sclera, cornea, uveal tissues and angle of the anterior chamber. Others include retina, ocular muscles and orbit. The affected iris is darker leading to heterochromia iridis. Although considered as a sporadic congenital disorder, only half of the patients had skin pigmentation present at birth or shortly after. Sometimes, ODM appears as late as 20 years after birth.

Tanino³ graded the dermal hyperpigmentation in patients with the following conditions:

1. Type 1 with four subtypes: a (mild orbital type) distribution over the upper and lower eye lids and periocular and temple region; B (mild zygomatic type) pigmentation is

found between the infrapalpebral and nasolabial fold and over the zygomatic region; C (mild forehead type), only forehead is affected; and D, alae nasi alone is affected.

2. Type 2 (moderate type): distribution over the upper and lower lids, periocular and zygomatic regions, cheeks and temple.
3. Type 3 (intensive type): the lesion involves the scalp, forehead, eye brow and nose.
4. Type 4: bilateral involvement.

Vishnevskia-Dai et al.⁴ recently proposed an ocular classification of the disease based on the anatomical parts (conjunctiva, scleral, iris and choroid) of the eye involved and the extent of its quadrantal involvement. The eye is classified as 1 if only the surface of the eye (conjunctiva and/or sclera) is involved. If another ocular structure is involved with the surface, it is designated ‘+’ for the surface involvement (surface and iris (2+), or surface and choroid (3+), or surface and iris and choroid (4+)). The ‘+’ designation is only given for surface involvement.

Epidemiological data on this condition are generally not available. A study reported the incidence

Correspondence to:
Bipul Kumer De Sarker
Assistant Professor of
Glaucoma, Ispahani
Islamia Eye Institute and
Hospital, 47 Indira Road,
Farmgate, Dhaka 1215,
Bangladesh.
drbipul26@gmail.com;
bipul.sarker@islamia.org.bd

Mohammad Ibn Abdul Malek
Sadiq Abdullahi
Sazzad Iftekhar
Nazmus Sakeb
Mallika Mahatma
Mridul Kumar Sarkar
Ispahani Islamia Eye
Institute and Hospital,
Dhaka, Bangladesh

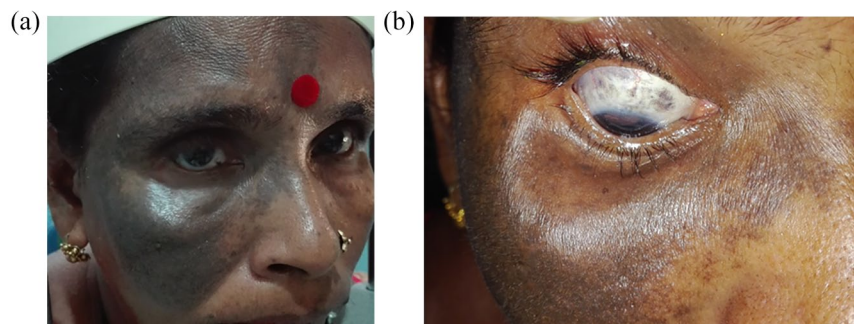


Figure 1. Slate-grey hyperpigmentation in the areas of distribution of ophthalmic and maxillary branches of the trigeminal nerve as well as nasal mucosa (a) and hyperpigmentation in the sclera (b).

to be 0.038% in a Caucasian population, with a lower incidence in a black population (0.014%).⁴ A higher incidence has been reported in patients with uveal melanoma.⁵

There is paucity of information on the pattern of presentation of ODM in South Asia. Therefore, the purpose of this Case Series is to present the ocular features of patients diagnosed with ODM.

Cases description

Five patients diagnosed with ODM at the glaucoma department of Ispahani Islamia Eye Institute and Hospital, Bangladesh, from January 2017 to December 2017 were included in this Case Series. All the patients had comprehensive ophthalmic evaluation by an experienced glaucoma specialist. The dermal pigmentation was graded according to Tanino's classification described above. Details of the individual cases are as follows.

Case 1

A 47-year-old Bangladeshi woman presented to our centre with complaints of occasional headache and blurring of vision in the right eye. There was no associated history of haloes and no previous trauma. She also had a pigmented patch in the right side of her face since birth which she said had been increasing gradually in size over time. Review of systems was not contributory and there was no family history of similar disorder or any ocular illness.

Examination of the face showed slate-grey hyperpigmentation in the areas of distribution of ophthalmic and maxillary branches of the trigeminal nerve as well as nasal mucosa (Figure 1(a)). Furthermore, there were hyperpigmented patches on the conjunctiva, episclera (Figure 1(b)) and

associated heterochromia with the right iris being darker; however, no iris mammillations were seen. This corresponds to type 3 as per Tanino's classification and 2D+ according to the ocular classification described by Vishnevskia-Dai et al.⁴

She had visual acuity of 6/9 and 6/6 in the right and left eyes, respectively. The anterior segments were normal and optic discs were pink with a cup-disc ratio (CDR) of 0.4 in both eyes. Gonioscopy revealed marked hyperpigmentation of the trabecular meshwork in the right eye and the angles were open in both eyes. The intraocular pressure (IOP) was 16 mmHg in both eyes.

She underwent routine glaucoma investigations, namely, central visual field test (CVF 24-2), fundal photograph, optical coherence tomography (OCT) and pachymetry. The findings were normal. She had refraction and spectacles was prescribed, with further follow-up scheduled for 6 months.

Case 2

The patient was a 53-year-old Bangladeshi woman who presented with slowly deteriorating vision in the left eye. She had no previous ocular trauma, surgery or family history of blindness or glaucoma. Review of systems was normal.

Examination revealed slate-grey hyperpigmentation of the skin left cheek, zygomatic and temple areas, corresponding to type 2 of Tanino's classification and 2D+ of Vishnevskia-Dai's ocular classification (Figure 2(a)).

She had visual acuity of 6/6 and 6/36 in the right and left eyes, respectively. The left eye had heterochromia with left being darker, posterior sub-scaphular cataract (Figure 2(b)), but there was no iris mammillation or loss of the iris crypt.

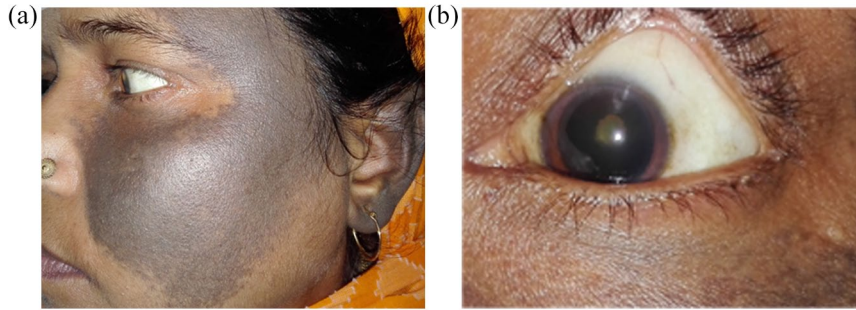


Figure 2. Hyperpigmentation of the skin left cheek, zygomatic and temple areas, corresponding to type 2 of Tanino's classification (a) and 2D+ of Vishnevskia-Dai's ocular classification with posterior subcapsular cataract (b).

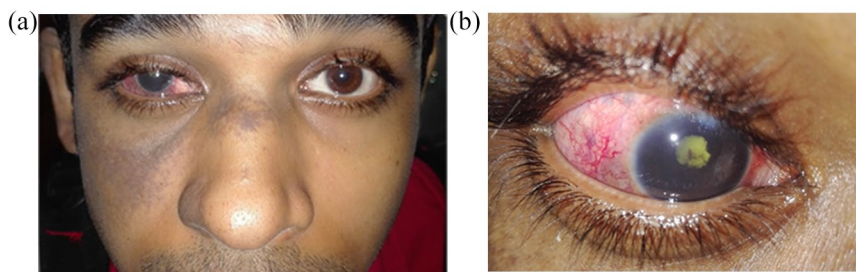


Figure 3. Hyperpigmented patches in the right zygomatic area, interpupillary area, nasal bridge, right side of the nose and auricular skin, corresponding to type 3 of Tanino's classification (a) and total retinal detachment with neovascular glaucoma (b).

Gonioscopy showed marked hyperpigmentation of trabecular meshwork in the left eye and both anterior chamber angles were open. The IOP measurements were 12 and 14 mmHg in the right and left eyes, respectively. Dilated stereoscopic fundal evaluation with 78 Diopter Volk lens revealed normal posterior segments with normal discs with a CDR of 0.4 in both eyes, thus corresponding to 2D+ ocular classification by Vishnevskia-Dai *et al.*⁴

The patient had uneventful left phacoemulsification with foldable intraocular lens and the visual acuity at last follow-up was 6/6, 4 months after the surgery.

Case 3

The patient was a 35-year-old Bangladeshi man who came to our hospital with complaints of severe pain, redness and loss of vision in the right eye. No antecedent history of trauma or foreign body in the eye was found.

In addition, he had a slate-grey hyperpigmented patch in his face since birth. The review of systems

was not contributory. He had visual acuity of light perception (PL) and 6/5 in the right and left eyes, respectively. In the right eye, there was conjunctival hyperemia, ciliary injection, corneal edema, flare, heterochromia and neovascularization on the iris.

There was 360 posterior synechia with complicated cataract and there was no view of fundus. On gonioscopy, the angle was closed in the right eye and opened in the left eye.

The IOP in the right and left eyes was 35 and 11 mmHg, respectively. There were hyperpigmented patches in the right zygomatic area, intrapupillary area, nasal bridge, right side of the nose and auricular skin, corresponding to type 3 of Tanino's classification (Figure 3(a)) and 4D+ ocular classification by Vishnevskia-Dai *et al.*⁴ There was also hyperpigmentation involving the nasal mucosa. Iris mammillations or crypts were not detected. Ultrasonography of the right eye revealed total retinal detachment with hyperchoic choroidal mass lesion. A diagnosis of total retinal detachment with neovascular glaucoma (painful blind eye) was made (Figure 3(b)).

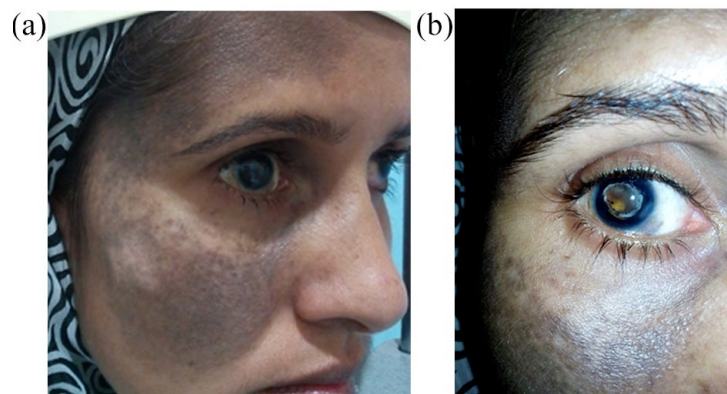

Figure 4. Hyperpigmented patches on right side of the face corresponding to type 2 of Tanino's classification (a) and total retinal detachment (b).

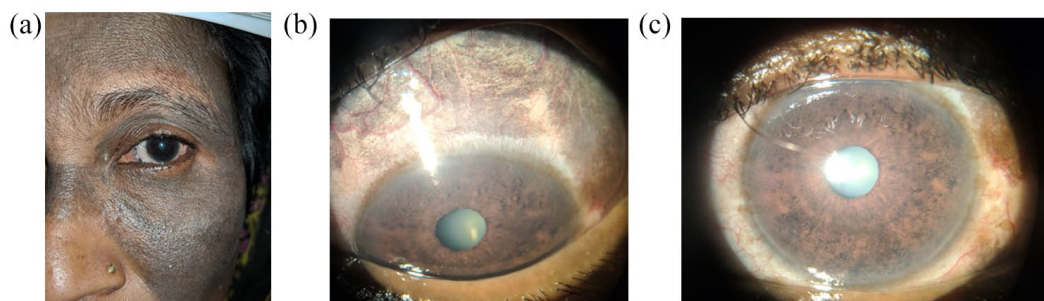


Figure 5. Hyperpigmented patches on left side of the face (a), hyperpigmented patches in the upper bulbar conjunctiva, episclera, and sclera as well as heterochromia iridis with darker left iris (b) with iris mammillations and loss of iris crypt (c).

Case 4

A 42-year-old woman presented with diminished vision in the right eye, no previous ocular trauma, no family history of similar disease or blindness. She had no systemic symptoms and no associated systemic illness. However, she had hyperpigmented facial patch noticed since childhood. She had visual acuity of PL and 6/6 in the right and left eyes, respectively. In addition, the right eye had slate-grey hyperpigmented patch in the inferior palpebral conjunctiva, episclera and sclera as well as heterochromia with darker iris in the right eye. There were also posterior synechiae, posterior sub-capsular cataract and gonioscopically closed angle. The IOP on the right and left eyes was 21 and 12 mmHg, respectively. B-scan of the right eye revealed total retinal detachment with hyperechoic choroidal mass lesion. The left eye was found to be normal after detailed clinical evaluation. On physical examination, she had hyperpigmented patches on right side of the face corresponding to type 2 of Tanino's classification (Figure 4(a) and (b)) and 4D+ ocular classification by Vishnevskia-Dai et al.

Iris mammillations, loss of iris crypt and iris atrophy were observed in this case.

The patient was managed conservatively with anti-glaucoma medications and counselled about her disease condition.

Case 5

A 55-year-old woman presented with headache, periocular pain and poor vision in the left eye. Review of symptoms was not contributory. She had visual acuity of 6/6 and 6/9 in the right and left eyes, respectively. Physical inspection revealed slate-grey hyperpigmentation in areas covering the right zygomatic, temporal, infraorbital, lower lid, supraorbital, upper lid and side of the nose, that is, type 3 Tanino's classification (Figure 5(a)). Hyperpigmentation was also present in the nasal mucosa. In the left eye, there were hyperpigmented patches in the upper bulbar conjunctiva, episclera and sclera as well as heterochromia irides with darker left iris (Figure 5(b)) with iris

mammillation and loss of iris crypt (Figure 5(c)) which corresponds to 2D+ ocular classification.

Stereoscopic fundal examination with 78D Volk lens revealed features of bilateral glaucomatous optic neuropathy. Gonioscopy showed closed angles in both eyes. The IOP was 16 mmHg in either eye. She had CVF examination using 24-2, OCT, central corneal thickness measurement and fundal photography. The results showed retinal nerve fibre layer defect in the left eye and paracentral scotoma in the same eye. The patient had laser peripheral iridotomy in both eyes and then placed on topical timolol bd.

Discussion

We reported various presentations of patients with oculo-dermal melanocytosis. Most of our patients were females with male-to-female ratio of 1:4, consistent with what was reported in other studies. Rutnin³ reported male-to-female ratio of 1:3, while Shield *et al.*⁶ reported 1:1.3. The female preponderance could be attributed to some genetic or hormonal factors. Unlike in previous study,³ none of our patients had family history suggestive of ODM. All the patients were of Asian origin. This is not unusual as ODM was said to be commoner among Asians and Africans.⁵

Naevus of Ota could be present at birth or during early childhood. Two of our patients had onset of dermal pigmentation at birth, while the other three had it during childhood.

A previous study found that 87.5% of their patients had pigmentation at birth.⁵ This figure is above what we reported, but it is difficult for us to compare because of our limited sample size. With regard to the dermal distribution of the hyperpigmentation, two patients (2/5) had type 2 and three (3/5) had type 3 dermal pigmentation in accordance with Tanino's classification of naevus of Ota. Ocular involvement in our patients included conjunctival, episcleral, scleral and iris hyperpigmentation as well as trabecular hyperpigmentation.

This is consistent with what was reported in previous studies. For example, Shield *et al.*⁶ reported ocular involvement affecting sclera (44%) and iris (65%), while others reported involvement of episcleral, sclera, iris and the angle of the anterior chamber which were graded in accordance with a

recent classification proposed by Vishnevskia-Dai *et al.* Furthermore, two of our patients had iris mammillations and loss of iris crypts which are also reported in a recent study.⁴

Two of the five patients had retinal detachment. Although retinal detachment is an uncommon association with ODM, it may be due to choroidal melanoma as patients had no other detectable risk factors for retinal detachment.

Glaucoma is a known sequelae of ODM reported in the literature.⁷ Two of our patients had glaucoma, while one had elevated IOP without glaucomatous optic neuropathy. Our finding was corroborated by a previous study that reported the presence of unilateral glaucoma in a patient with ODM.⁸ The glaucoma in ocular melanocytosis might be due to pigment clogging of the trabecular meshwork resulting in IOP elevation. It is however important to state that none of the patients presented primarily because of the hyperpigmentation. Therefore, the true prevalence of ophthalmic sequelae of ODM may be difficult to determine as asymptomatic patients are not likely to present in the hospital.

Conclusion

Oculodermal melanocytosis, though rare, is associated with a number of sight-threatening conditions (including glaucoma), and as such, all patients with this condition should have a comprehensive ocular evaluation. This case series will raise the awareness regarding this oculocutaneous condition.

Authorship

All authors declare that they meet the current ICMJE criteria for authorship.

Conflict of interest statement

The authors declared no potential conflicts of interest with respect to the research, authorship and/or publication of this article.

Funding


The authors received no financial support for the research, authorship and/or publication of this article.

Ethics statement

All patients provided written, informed consent for their medical information and photographs to be published. The Institutional Review Board

of Ispahani Islamia Eye Institute and Hospital (Dhaka, Bangladesh) waived the need for approval for this study.

ORCID iD

Bipul Kumer De Sarker  <https://orcid.org/0000-0001-7647-6644>

References

1. Plateroti AM, Scavella V, Abdolrahimzadeh B, *et al.* An update on oculodermal melanocytosis and rare associated. *Semin Ophthalmol* 2017; 32: 524–528.
2. Swann PG and Kwong E. The Naevus of Ota. *Clin Exp Optom* 2010; 93: 264–267.
3. Rutnin U. Findings in oculodermal melanocytosis. *Arch Ophthalmol* 1990; 108: 1114–1120.
4. Vishnevskia-Dai V, Moroz I, Davidy T, *et al.* Naevus of Ota: clinical characteristics and proposal for a new ocular classification and grading system. *Br J Ophthalmol* 2020; 105: 42–47.
5. Carrêo E, Saornil MA, Garcia-Alvarez C, *et al.* Prevalence of ocular and oculodermal melanocytosis in Spanish population with uveal melanoma. *Eye (Lond)* 2012; 26: 159–162.
6. Shields CL, Kaliki S, Livesey M, *et al.* Association of ocular and oculodermal melanocytosis with the rate of uveal melanoma metastasis analysis of 7872 consecutive eyes. *JAMA Ophthalmol* 2013; 131: 993–1003.
7. Magarasevic L and Abazi Z. Unilateral open-angle glaucoma associated with the ipsilateral nevus of Ota. *Case Rep Ophthalmol* 2013; 2013: 924937.
8. Nevus of ota. *Indian Pediatr* 2014; 51: 510.

Visit SAGE journals online
[journals.sagepub.com/
home/oed](https://journals.sagepub.com/home/oed)

 SAGE journals