



Since January 2020 Elsevier has created a COVID-19 resource centre with free information in English and Mandarin on the novel coronavirus COVID-19. The COVID-19 resource centre is hosted on Elsevier Connect, the company's public news and information website.

Elsevier hereby grants permission to make all its COVID-19-related research that is available on the COVID-19 resource centre - including this research content - immediately available in PubMed Central and other publicly funded repositories, such as the WHO COVID database with rights for unrestricted research re-use and analyses in any form or by any means with acknowledgement of the original source. These permissions are granted for free by Elsevier for as long as the COVID-19 resource centre remains active.

Chapter 20

Autoimmunity in visual loss

AXEL PETZOLD¹, SUI WONG², AND GORDON T. PLANT^{3*}

¹*The Dutch Expert Center for Neuro-ophthalmology, VU University Medical Center, Amsterdam, The Netherlands and Molecular Neuroscience, UCL Institute of Neurology, London, UK*

²*Moorfields Eye Hospital and St. Thomas' Hospital, London, UK*

³*Moorfields Eye Hospital, The National Hospital for Neurology and Neurosurgery and St. Thomas' Hospital, London, UK*

Abstract

There are a number of autoimmune disorders which can affect visual function. There are a very large number of mechanisms in the visual pathway which could potentially be the targets of autoimmune attack. In practice it is the retina and the anterior visual pathway (optic nerve and chiasm) that are recognised as being affected in autoimmune disorders. Multiple Sclerosis is one of the commonest causes of visual loss in young adults because of the frequency of attacks of optic neuritis in that condition, however the basis of the inflammation in Multiple Sclerosis and the confirmation of autoimmunity is lacking. The immune process is known to be highly unusual in that it is not systemic and confined to the CNS compartment. Previously an enigmatic partner to Multiple Sclerosis, Neuromyelitis Optica is now established to be autoimmune and two antibodies – to Aquaporin4 and to Myelin Oligodendrocyte Glycoprotein – have been implicated in the pathogenesis. The term Chronic Relapsing Inflammatory Optic Neuropathy is applied to those cases of optic neuritis which require long term immunosuppression and hence are presumed to be autoimmune but where no autoimmune pathogenesis has been confirmed. Optic neuritis occurring post-infection and post vaccination and conditions such as Systemic Lupus Erythematosus and various vasculitides may cause direct autoimmune attack to visual structures or indirect damage through occlusive vasculopathy. Chronic granulomatous disorders such as Sarcoidosis affect vision commonly by a variety of mechanisms, whether and how these are placed in the autoimmune panoply is unknown. As far as the retina is concerned Cancer Associated Retinopathy and Melanoma Associated Retinopathy are well characterised clinically but a candidate autoantibody (recoverin) is only described in the former disorder. Other, usually monophasic, focal retinal inflammatory disorders (Idiopathic Big Blind Spot Syndrome, Acute Zonal Occult Outer Retinopathy and Acute Macular Neuroretinitis) are of obscure pathogenesis but an autoimmune disorder of the post-infectious type is plausible. Visual loss in autoimmunity is an expanding field: the most significant advances in research have resulted from taking a well characterised phenotype and making educated guesses at the possible molecular targets of autoimmune attack.

INTRODUCTION

The role of the adaptive immune system is to protect the organism. Potential pathogens are either eliminated or isolated, and endogenous mechanisms of repair are promoted. Complex disorders arise when the adaptive

immune systems target the self, resulting in autoimmune disease. By definition autoimmunity is systemic and will, in a proportion of patients, affect structures relevant to vision.

*Correspondence to: Gordon T. Plant, Moorfields Eye Hospital, 162 City Road, London EC1V 2PD, UK. E-mail: gordon.plant@ucl.nhs.uk

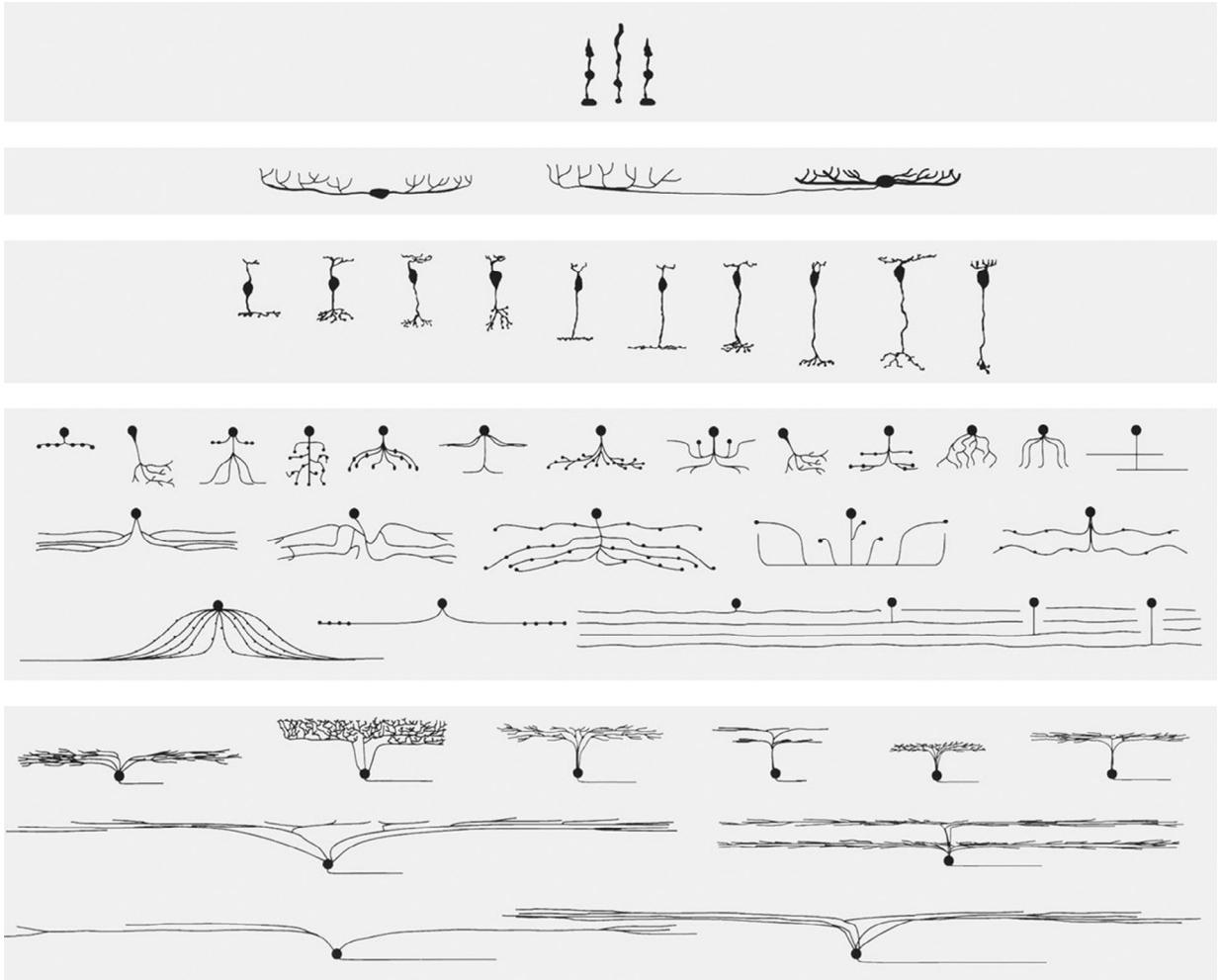


Fig. 20.1. The major cell types of a typical mammalian retina. From the top row to the bottom, photoreceptors, horizontal cells, bipolar cells, amacrine cells, and ganglion cells. For steric reasons, only a subset of the wide-field amacrine cells is shown. (Reprinted from Masland (2001) with permission from Macmillan Publishers (Nature Neuroscience)).

THE ANATOMIC BASIS FOR PATTERNS OF VISUAL LOSS

About two-thirds of the human brain is involved in processing visual information. Each eye has about 100 million photoreceptors (Fig. 20.1, top row). The flow of information starts with the conversion of photons to an analogue signal in the retinal photoreceptors, and this is then converted by the bipolar cells of the inner nuclear layer (Fig. 20.1, third row) into a digital signal coding for approximately 12 parallel information streams (Masland, 2012). This represents the first stage in the parallel analysis of the many submodalities of the visual image (contrast, motion, color, etc.). The size of retinal ganglion cells is minuscule – about 1% of the volume of a pyramidal cell in the hippocampus or cortex (Masland, 2012). Each retinal ganglion cell generates the visual signal along a “hard-wired” pathway to the primary visual cortex,

also known as striate cortex or V1 (Balk et al., 2015). This “hard-wired” pathway is the anatomic basis of what is known as the retinotopic (point-to-point) projection of the retina, and hence the basis for the visual field in the visual cortex (Table 20.1) (Holmes, 1945). There are also less numerous, but nonetheless significant, projections to other visual cortical areas (such as V5 involved in motion processing) and the tectum (involved in pupillary reflexes). There is, therefore, an ample substrate for differential effects of immune processes on parallel pathways of processing within a single anatomically defined structure such as the retina, optic nerve, or visual cortex. Selective deficits of color vision, motion perception, and other modalities are all potential manifestations of autoimmune-mediated dysfunction.

In more detail, in humans, each retina gives rise to about 1 158 000 retinal ganglion cell axons entering the

Table 20.1

Definition of terms used in visual sciences

Term	Definition
Hard-wired	In human vision the first-, second-, and third-order neurons and their axons are hard-wired into the human brain and transmit analogue and digital signals. This hard-wired single pathway enables the retinotopic map of the human visual cortex. There is no (or very little) potential for plasticity in the strict definition of this single pathway model (Balk et al., 2015)
Analogue signal	The analogue signal produced by the photoreceptors is continuous. The signal intensity varies over time depending on the light-induced metabolism of opsins. Therefore the variation of the signal carries information on light entering the eye (Fig. 20.2). The analogue signal of the photoreceptors is converted by retinal bipolar cells into a digital signal as required for higher-level visual network processing
Digital signal	The digital signal of the hard-wired visual pathway is sampled from the analogue signal fed into retinal bipolar cells by photoreceptors. The digital signal consists of a series of action potentials. The information of the digital signal is encoded in the time frequency of these action potentials
Retinotopic	A topographic map where adjacent locations on the retina are represented by adjacent neurons in the dorsal lateral geniculate nucleus and V1.
Rayleigh criterion	The minimum resolvable detail according to the generally accepted physical definition, diffraction limitation. Simplified, the limitation of image resolution relates to the order of wavelength of the wave used to image it. For example, the Rayleigh criterion for a wavelength of 500 nm and a circular pupil opening of 5 mm is: $\theta_R = 1.22 \times \frac{\lambda}{d} = \frac{1.22 \times 5 \times 10^{-5} \text{ cm}}{0.5 \text{ cm}} = 1.22 \times 10^{-4} \text{ rad}$. Put into relation, a Snellen acuity of 6/6 (UK notation, 20/20 US notation) corresponds to a resolution limitation of $\theta = 5 \times 10^{-4} \text{ rad}$ in most subjects. Under optimal circumstances a visual acuity of $\theta = 2 \times 10^{-4} \text{ rad}$ might be achieved. Essentially, visual acuity depends on the anatomic spacing of sensory neurons in the retina and the wavelengths of the light entering the eye
Vernier acuity	The human visual cortex can make spatial distinctions with a precision which is about 10 times better than visual acuity. This so-called hyperacuity depends on sophisticated information processing in the visual human brain. Vernier acuity represents the quintessential example of hyperacuity where the alignment of two edges or lines can be judged with a better precision than predicted by visual acuity. Clinically, the assessment of, for example, normal stereopsis relies on hyperacuity

optic nerve (Jonas et al., 1992). The axons of the optic nerve partially decussate (50% project contralaterally) in the chiasm. The retinal ganglion cell is the first-order neuron and synapses with the second-order neuron in the dorsal lateral geniculate nucleus, where visual processing continues (Prasad and Galetta, 2011). Finally, the retinotopic projections from these second-order neurons result in a retinotopic map and functional architecture of V1 (Hubel and Wiesel, 1977). The visual pathways projecting from the retina to V1 are shown in Figure 20.2. The primary visual cortex itself is an early stage of cortical visual processing (Tong, 2003). Beyond V1 are multiple extrastriate visual areas which are involved in further information processing (Sincich and Horton, 2005; Barton, 2011).

The optic nerve and the eye are developmentally part of the central nervous system (CNS) and hence share many targets for autoimmune attack with the rest of the CNS. Indeed, the optic nerve should be considered a white-matter tract with more in common with the spinal cord than with the other cranial nerves. At the same time, the seductive beauty of this fine anatomic network depends on visual information processing involving receptors, ion channels, and second-messenger cascades (Sterling, 1999); the receptors and

voltage-gated channels with their extracellular domains are also potential targets for autoimmunity.

Guiliano Toraldo di Francia was the first to recognize that the spatial resolution of stimuli reaching the retina is better than the dimensions of the photoreceptors in the retina should permit, based on the Rayleigh criterion (Westheimer, 2009) (Table 20.1). Thus, even the function of visual acuity, a basic measurement in clinical practice, is dependent upon postreceptor processing. All forms of hyperacuity (such as Vernier acuity) rely on visual cortical function. The full anatomic extent of higher visual cortical areas in humans continues to be unraveled with the aid of co-registered functional (functional magnetic resonance imaging (MRI), magnetoencephalography, positron emission tomography) and structural imaging (MRI) studies.

GENERAL CONSIDERATIONS FOR AUTOIMMUNE MECHANISMS FOR VISUAL LOSS

Autoimmune-mediated loss of vision refers to impairment or disruption of the neuronal network. In health, the eye and brain are protected from the systemic

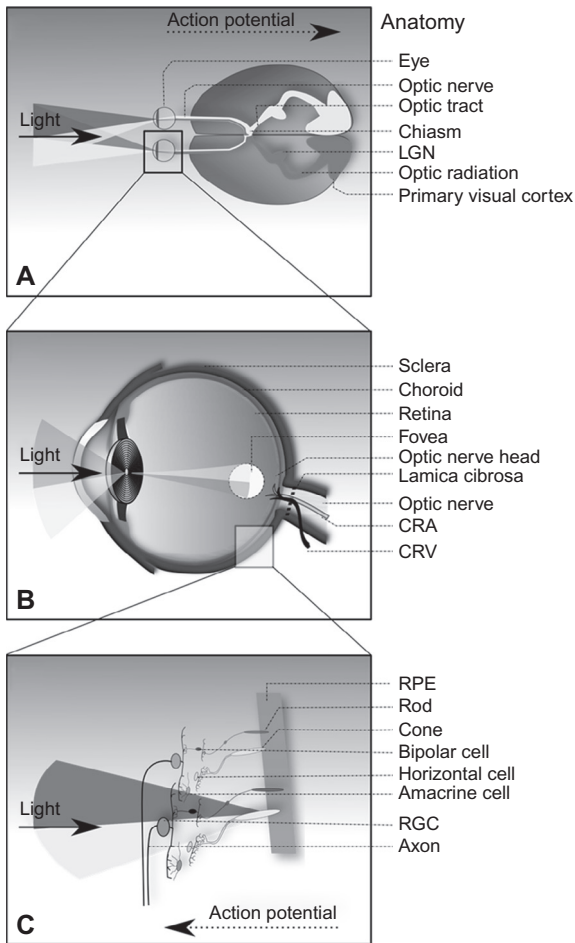


Fig. 20.2. (A) Graphic representation of the visual pathways in the human brain. (B) The eye optimizes transmission of light to specialist cell layers of the retina. (C) Light is converted by the photoreceptors into action potentials. A digitally coded electric signal is transmitted by the retinal ganglion cells (RGC) via a hard-wired pathways to the second-order neuron in the dorsal lateral geniculate nucleus (LGN) and the third-order neuron located in the primary visual cortex. Autoimmune disease can affect any of these structures at each station of the visual pathway, giving rise to distinct symptoms and signs. CRA, central retinal artery; CRV, central retinal vein; RPE, retinal pigment epithelium.

inflammatory response of the immune system. In autoimmune visual loss, the following protective mechanisms and structures may be impaired (see sections Blood brain barrier and Blood retina barrier).

The brain and the eye have in common immune privilege, which describes the relationship that some organs of the human body have with the immune system. It is thought that this immune privilege is necessary to protect the fine-tuned functions of the neuronal network. It is not yet fully understood how immune privilege has developed and is maintained, but the presence of anatomic barriers protecting the immune-privileged

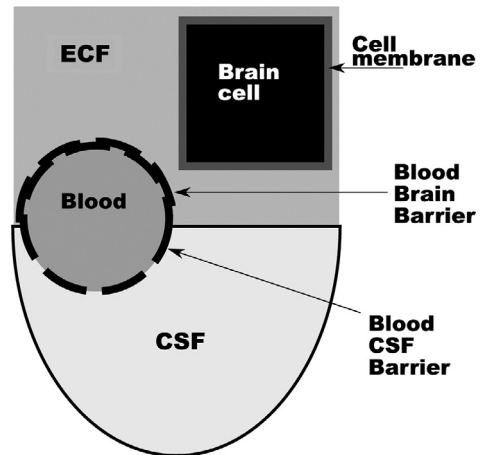


Fig. 20.3. A simplified diagram of the tight blood-brain barrier (BBB) which separates the blood from the extracellular fluid (ECF) of the brain parenchyma. The very tight cell membrane prevents proteins from the cytosol diffusing into the ECF. The less tight blood-cerebrospinal fluid (CSF) barrier allows substances to diffuse from the blood into the CSF. (Reprinted from [Petzold \(2007\)](#) with permission from Maney Publishing).

organ has long been recognized and molecular mechanisms such as induction of apoptosis of invading inflammatory cells have been discovered ([Ferguson and Griffith, 2006](#)).

The blood-brain barrier (BBB) is a structural component of the homeostatic mechanisms that prevent substances from the blood stream entering the extracellular fluid (ECF) of the CNS ([Fig. 20.3A](#)). In addition to the BBB there is also the blood-cerebrospinal fluid (CSF) barrier (BCB), which is a filter that permits substances to diffuse from the blood into the CSF according to molecular size. It is important to distinguish between the BBB and BCB, but this is not rigorously applied in the literature ([Petzold, 2007](#)).

Integrity of the BBB/BCB function is assessed by quantification of CSF and serum albumin. Because albumin is not produced intrathecally, all CSF albumin must be derived from the blood by diffusion through the meninges. An intact BBB/BCB will only allow a small amount of albumin to diffuse into the CSF. The normal quotient of CSF to serum albumin calculates to 0.0018–0.0074 (95% confidence limits), i.e. ratios of approximately 1:500 – 1:150 (see [Chapter 3](#)). ([Stangel et al., 2013](#)). A breakdown of the BCB leads to leakage of serum albumin locally into the CSF, and therefore an increase of the quotient indicates a loss of integrity of the BBB ([Stangel et al., 2013](#)). The wide range of the quotient reported in the literature highlights that each laboratory will need to establish its own normal range, which needs to be rigorously quality-controlled over time.

Similar to the BBB, the blood–retina barrier (BRB) is one of the mechanisms subserving retinal homeostasis (Cunha-Vaz et al., 2010). The inner BRB regulates the fluid shifts and molecular exchange between the retina capillary blood and the extracellular fluid of the retina. On a cellular level the inner BRB consists of tight junctions between the endothelium and Müller cells at the level of the inner limiting membrane. Likewise, the outer BRB consists of tight junctions between the retinal pigment epithelium (RPE) cells abutting the outer aspect of Bruch membrane. It is generally accepted that maintenance of visual function critically depends on an intact metabolic relationship between the RPE and the photoreceptors. Fluorescein angiography is the gold standard to assess the BRB integrity and fluorescein leakage indicates a loss of integrity. In addition, there is now a role for retinal optical coherence tomography (OCT) as a noninvasive technique to demonstrate fluid accumulation in the retina likely related to BRB breakdown (Gelfand et al., 2012; Burggraaff et al., 2014).

The complement system bears a crucial role in the autoimmune response (Minton, 2014). Antibodies bound to epitopes on antigens constitute an immune complex. If the isotypes of the antibodies are complement activating, complement is bound to the immune complex (Heyman, 2000). Complement activation can stimulate phagocytosis or directly destroy a cell. For example, in systemic lupus erythematosus (SLE), complement activation is involved in autoantibody-initiated tissue damage (Chen et al., 2010). Through a similar mechanism, aquaporin-4 (AQP4) autoantibodies in neuromyelitis optica (NMO) result in complement-mediated damage to astrocytes in the CNS and are associated with loss of glial fibrillary acidic protein staining on immunohistochemistry (Bradley et al., 2000; Bennett et al., 2009; Saadoun et al., 2010). An increase in CSF glial fibrillary acidic protein levels, the major specific protein antigen of the astrocyte, is consistently found in acute attacks of NMO (Petzold, 2015). This observation led to the term “autoimmune astrocytopathy” (Lucchinetti et al., 2014). The alternative term “autoimmune channelopathies” has been suggested (Pittock and Lucchinetti, 2015), but this applies to other disorders as well.

Autoimmune channelopathies

The spectrum of neurologic channelopathies is large, but none has yet been associated with visual loss (Vincent et al., 2006; Kullmann, 2010). This is surprising, because many immune targets for autoimmune channelopathies are highly expressed in the optic nerve, retina, and visual networks.

Paroxysmal episodes of visual loss observed clinically are not all understood. For example, some cases of

nonembolic transient monocular blindness could be due to a channelopathy (Petzold et al., 2013a, b), as might paroxysmal symptoms in multiple sclerosis (MS), including deterioration in vision with rise in body temperature (Uhthoff phenomenon) (Petzold et al., 2014). The potassium channel Kir4.1 (also known as Kcnj10), which resides in the astrocytes, is one of the most recent candidates for a possible autoimmune channelopathy affecting the visual system in MS (Srivastava et al., 2012). This potassium channel is highly expressed in optic nerve and the Müller cells of the retina. However, it has not yet been possible to replicate the findings of antibodies to Kir4.1 in MS (Brickshawana et al., 2014). For this and for most of the other antibodies described below, the gold standard has become detection of antibodies binding to the protein in its natural environment on the surface of human cells. This issue is discussed in detail in Chapter 9.

In health the immune system will not come into contact with many of the intracellular neuronal components due to the immune-privileged nature of the mother organ. However, any pathologic process causing a release of components from neurons within the visual system could give rise to an immune reaction to these self antigens. Each new pathologic event or relapse increases the likelihood of such a reactive or secondary autoimmune reaction. On the other hand, it is difficult to know whether such antibodies are epiphenomena or of direct pathogenic relevance (Petzold, 2013).

DIAGNOSIS AND DIFFERENTIAL DIAGNOSIS OF AUTOIMMUNE VISUAL LOSS

The diagnostic workup is guided by the patient history and clinical assessment (Fig. 20.4). Table 20.2 lists warning signs which should trigger escalation of the diagnostic procedures. Because the differential spectrum is dominated by MS-associated optic neuritis (MSON), these red flags should alert the clinician to potential alternative diagnoses. Red flags refer either to symptoms and signs at presentation or the disease course. Therefore patients will need to be followed up at least once.

Multiple sclerosis-associated optic neuritis

Optic neuritis is a common presenting symptom in patients with MS (Petzold et al., 2014). The prevalence of MS varies considerably on our planet (Fig. 20.5). To distinguish optic neuritis in MS from other forms of optic neuritis, we use the abbreviation MSON (Petzold et al., 2014). Historically, there are a number of reports of optic neuritis predating the seminal papers on MS from Charcot (1868), with Auguste D’Este being

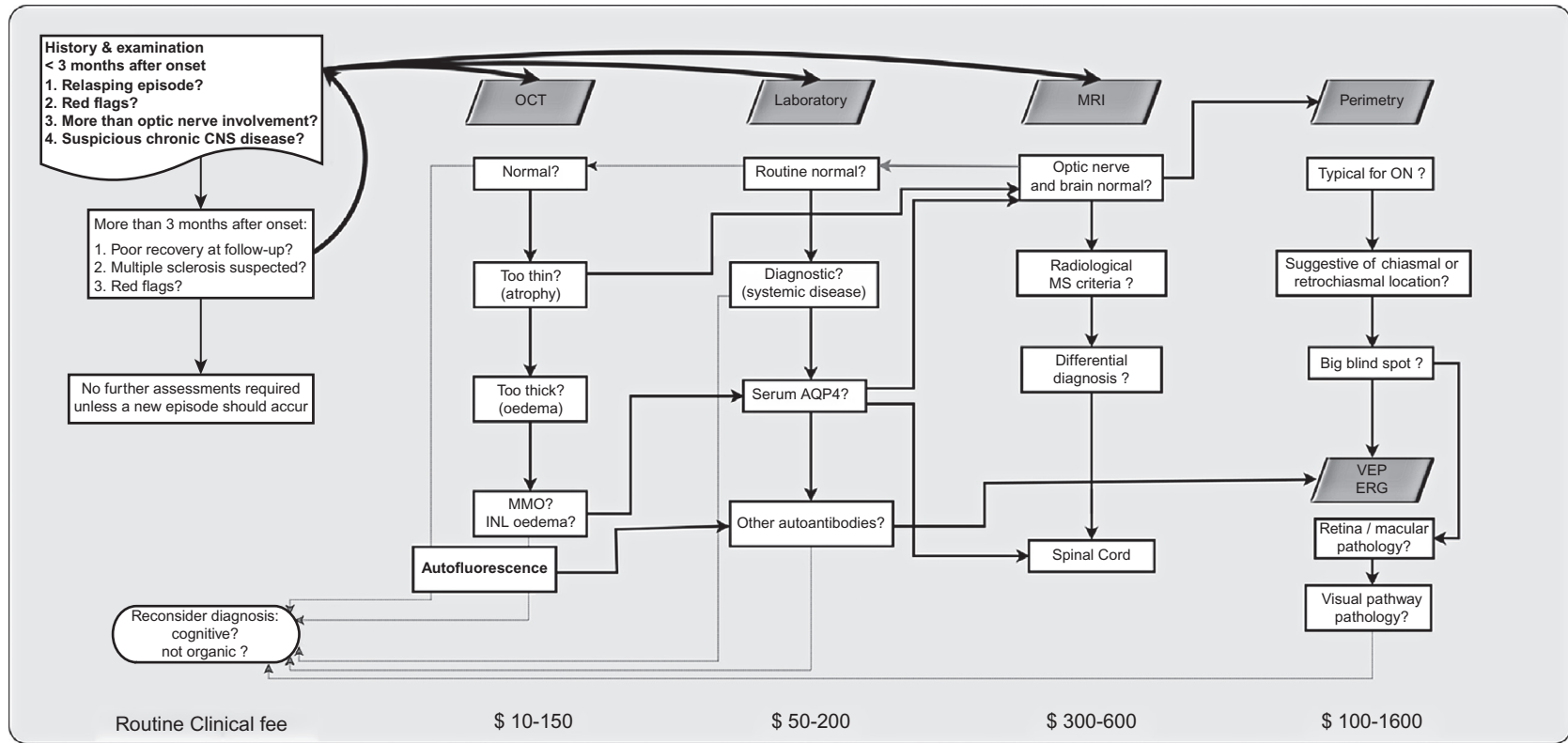


Fig. 20.4. Diagnostic workup for patients presenting with autoimmune visual loss. The clinical decision on whether or not a patient requires further investigations depends on key points from the history and clinical examination. The approximate costs in US dollars (\$) related to escalation of investigations are given for general guidance only, as fees vary substantially between institutions. The clinical decision tree emphasizes pertinent questions, pointing horizontally for “yes” (closed lines) and vertically for “no” answers (dotted lines). CNS, central nervous system; OCT, optical coherence toography; MRI, magnetic resonance imaging; MMO, microcystic macular edema; INL, inner nuclear layer; AQP4, aquaporin-4; MS, multiple sclerosis; ON, optic neuritis; VEP, visual evoked potential; ERG, electroretinography. (Modified from [Petzold et al., 2014.](#))

the most frequently cited case (Firth, 1948). The typical clinical presentation is that of periorbital pain, which occurs only or is exacerbated by eye movement and precedes visual loss. Positive visual symptoms may be present at onset; negative visual symptoms reach their nadir within about 2 weeks and have recovered substantially by

about 3 months. Residual symptoms include dyschromatopsia, impaired contrast sensitivity, Uhthoff phenomenon, Pulfrich phenomenon, visual fading, and glare disability (Table 20.3) (Petzold et al., 2014).

The clinical differential diagnosis is large and can be guided by analysis for autoantibodies, particularly in the presence of “red flags” indicating an atypical presentation or disease course (Table 20.2). Consistent with findings in MS and experimental models of MS, a number of autoantibodies against myelin proteins have been reported in MSON (Petzold, 2013). These are myelin oligodendrocyte glycoprotein (MOG), myelin basic protein, and myelin-associated oligodendrocytic basic protein. There is no evidence to suggest an association between paraneoplastic antibodies and MSON (Stich et al., 2011). However, a common limitation of these studies is the assumption that optic neuritis was due to MS but the clinical data are missing (Petzold et al., 2014) and, as more data regarding antibodies emerge, particularly antibodies to MOG in relapsing and bilateral simultaneous optic neuritis, the position may change.

Table 20.2

Red flags suggestive of autoimmune visual loss requiring specialized diagnostic workup

Atypical clinical presentation

- Bilateral visual loss
- Pain or loss of vision presenting for more than 2 weeks
- Painless loss of vision
- Retinal abnormalities
- Unexplained optic atrophy
- Severe loss of vision without early recovery

Risk factors

- Any suspicion of cancer
- Family history or past medical history of autoimmune disease
- Non-Caucasian ethnic background and severe loss of vision
- Visual loss following travel abroad, infection, or vaccination

Atypical course

- Progressive loss of vision
- Absence of recovery for more than 3 months
- Worsening of visual function after reducing immunosuppression
- Rapid sequential bilateral visual loss

Neuromyelitis optica

Eugène Devic published in 1894 the clinical course and postmortem examination of a 45-year-old woman who presented with bilateral visual loss 3 weeks after suffering from intestinal problems, sleeplessness, weakness, and headaches. Optic disc swelling was severe and

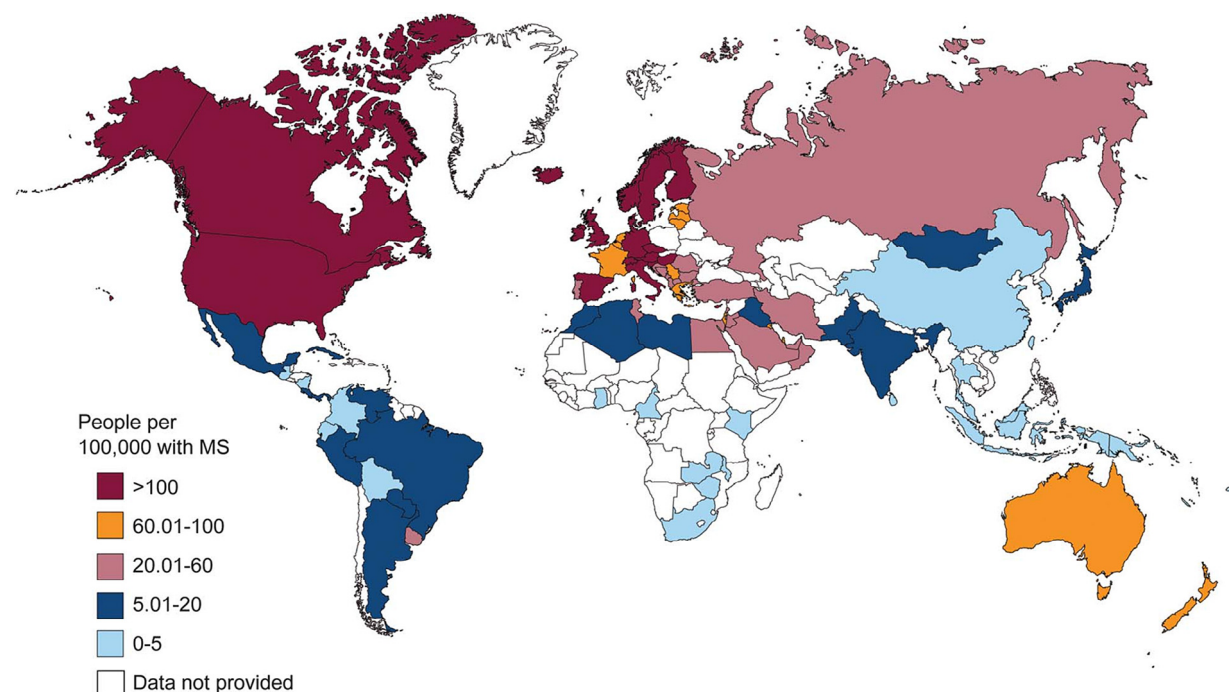


Fig. 20.5. Global prevalence of multiple sclerosis (MS) per country in 2013. (Reproduced from www.atlasofms.org, with permission.)

Table 20.3

Definition of terms used for visual symptoms typically observed following unilateral optic neuritis

Term	Definition
Contrast sensitivity	A measure of visual function relevant for a patient's visual quality of life because contrast sensitivity might be reduced whilst high-contrast (Snellen) visual acuity is normal. Contrast sensitivity is defined as the ability to discern between luminance of different levels in a static image. The optimal level of contrast sensitivity is reached within about 20 years of age and declines with age and disease and is strongly influenced by refraction at higher spatial frequencies (smaller spatial elements). Therefore reliable clinical assessment of contrast sensitivity requires best-corrected visual acuity to be used
Dyschromatopsia	Assessment of color vision provides an even finer measure of visual function than contrast sensitivity. Color is defined by hue, saturation, and brightness, each of which can be quantified. Following optic neuritis there is an acquired deficit with color perception with patient frequently reporting that colors appear to be more "washed out" in the affected eye, which is due to a loss of saturation
Glare	Defined as the difficulty seeing in presence of bright light. Most subjects experience glare disability with, for example, bright head lights in the back mirror of a car at night. Following optic neuritis patients also describe glare disability and discomfort (photosensitivity) with daylight or artificial light
Pulfrich phenomenon	Defined by Carl Pulfrich as a stereo-effect (Petzold and Pitz, 2009). Patients have difficulties judging movement in depth. This can readily be corrected by having tinted spectacle with the darker-shaded glass in front of the better eye
Uhthoff phenomenon	Transient worsening of function, such as vision, with change of body temperature. This may be reported by patients following a warm shower/bath, sport, stress, hot meals, or with higher environmental temperatures. Function restores with normalization of body temperature
Visual fading	A physiologic phenomenon, Troxler effect, occurring with prolonged visual fixation leading to fading or disappearance of small objects in the visual field. This phenomenon is enhanced following optic neuritis. At time of writing an increasing proportion of patients report problems with digital screens of computers, smartphones, tablets. For example, prolonged visual fixation of Excel sheets may lead to disappearance of lines or smaller print in the central visual field. The phenomenon is transient and looking away and back again will restore visual function. This should be distinguished from fading of vision in bright-light conditions not related to steady fixation (see above)

retinal hemorrhages were also present. She died 10 days later and the clinical diagnosis of acute myelitis and bilateral optic neuritis was confirmed pathologically. Historically, there are earlier descriptions of the association of visual loss and spinal cord inflammation (see [Jarius and Wildemann, 2012](#)), but it was not until the seminal discovery of a diagnostic autoantibody in 2004 that research on autoimmunity and visual loss in NMO made progress ([Lennon et al., 2004](#)). This topic is covered more generally in [Chapter 21](#).

Clinically, the differential diagnosis is straightforward for patients presenting with simultaneous optic neuritis and myelitis, but these cases are not always positive for AQP4 antibodies ([Wingerchuk et al., 1999](#)). More difficult are those patients presenting with acute unilateral optic neuritis in isolation (NMO-ON) ([Petzold et al., 2014](#)). In NMO visual loss tends to be more severe and with poorer outcome compared to MSON ([Petzold and Plant, 2014b](#)). This distinction may however also reflect the need for adequate treatment in NMO-ON while in MSON the outcome tends to be favorable even in the absence of treatment.

In NMO-ON visual field abnormalities are less diffuse than in MSON with a worse foveal threshold ([Nakajima](#)

[et al., 2010](#); [Merle et al., 2013](#)). About 40% of patients with NMO-ON suffered from total visual loss compared to 5.3% with MSON ([Merle et al., 2013](#)). Altitudinal visual field defects were also observed, anatomically suggesting focal pathology in the dorsal or ventral optic nerve ([Nakajima et al., 2010](#); [Merle et al., 2013](#)). Optic nerve imaging in NMO-ON demonstrates elongated lesions, posterior in the nerve, with more frequent involvement of the chiasm and contralateral optic nerve compared to MSON ([Khanna et al., 2012](#); [Storoni et al., 2013](#)).

With the discovery of NMO IgG ([Lennon et al., 2004](#)), later described as a specific autoantibody against the water channel AQP4 ([Lennon et al., 2005](#)), a highly specific diagnostic test for NMO-ON became available. The current gold standard is the cell-based assay because of its sensitivity ([Waters et al., 2012](#)). Following complement-mediated damage to astrocytes, glial fibrillary acidic protein, a specific astrocyte protein, is released into the extracellular fluid and CSF, providing an additional test that may be helpful in some cases ([Petzold, 2015](#)). This characteristic astrocytic damage in NMO leads to the pathologically motivated term "autoimmune astrocytopathy" ([Lucchinetti et al., 2014](#)).

Only 65–85% of patients who are defined clinically and radiologically as NMO have AQP4 antibodies using currently available techniques. In these patients MOG antibodies are proving to be helpful in defining a non-MS form of NMO spectrum disorder, including cases with optic neuritis (Kitley et al., 2014; Sato et al., 2014). Confusion in the field has stemmed partly from the use of unsuitable secondary antibodies and, with assays specific for IgG antibodies, MS patients are rarely positive (Waters et al., 2015). MOG antibodies are thus emerging as a new form of autoimmune white-matter disease which is particularly common in severe or relapsing optic neuritis.

Chronic relapsing inflammatory optic neuropathy (CRION)

In 2003, 15 patients with CRION were described (Kidd et al., 2003). The diagnostic criteria include dependence on immunosuppression, which makes an autoimmune pathogenesis likely (Petzold and Plant, 2014a). The geographic and therefore ethnic distribution probably differs from MS (Fig. 20.6), but data need to be interpreted with caution owing to the lack of population-based epidemiologic studies.

DIAGNOSTIC CRITERIA FOR CRION (PETZOLD AND PLANT, 2014A)

- History: optic neuritis and at least one relapse
- Clinical: objective evidence for loss of visual function
- Laboratory: NMO IgG seronegative
- Imaging: contrast enhancement of the acutely inflamed optic nerves.
- Treatment: response to immunosuppressive treatment and relapse on withdrawal or dose reduction of immunosuppressive treatment

Typically, patients experience a relapse on cessation of immunosuppression or on reduction of (usually corticosteroid) dosage below a certain critical, but individually variable, level (Petzold and Plant, 2014a, b). We recommend testing for AQP4 autoantibodies in all patients with suspected CRION to rule out NMO (Petzold et al., 2014). Likewise, testing for MOG antibodies could be helpful once validated assays become available more widely.

Patients with CRION will require long-term immunosuppression. We also advise hyperacute treatment of acute relapses of optic neuritis, which may occur despite systemic immunosuppression, particularly when the

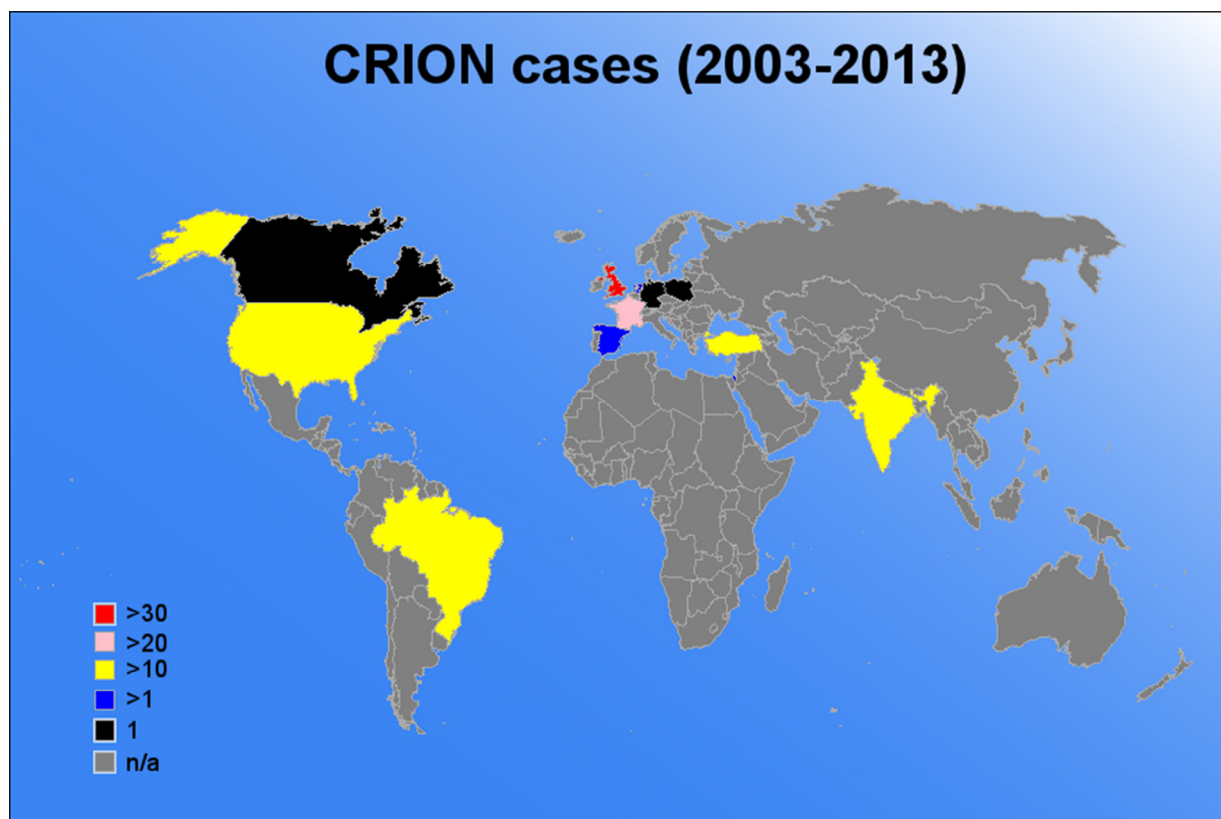


Fig. 20.6. Chronic relapsing inflammatory optic neuropathy (CRION) cases published per country between 2003 and 2013. (Reprinted from Petzold and Plant (2014a) with permission from Springer Science and Business Media).

dose is being tapered to establish minimum requirements (Plant et al., 2011).

Ganglioside antibody optic neuritis

In 2013 visual loss was described in a patient with anti-GQ1b and GT1a IgG (Biotti et al., 2013). This patient suffered from transient sensory symptoms following a febrile infection. The optic nerve has the second highest density of ganglioside expression in the CNS and therefore may be susceptible to transient antibody-mediated conduction block, similar to that which occurs in Miller–Fisher syndrome, where it affects the ocular motor nerves.

MOG antibody optic neuritis

The myelin proteins include MOG, which is a transmembrane protein exposed on myelin sheaths in the CNS. MOG is a well-recognized antigen target in human CNS demyelination and an experimental form of optic neuritis induced by active immunization against MOG epitopes (Weissert et al., 2002; Chapter 8).

A review of the spectrum of human diseases associated with MOG autoantibodies reveals a heterogeneous clinical group (Reindl et al., 2013). As discussed above for MSON, a limitation of previous studies on the possible association of MOG autoantibodies and optic neuritis was the need to have more detailed data on relapses, steroid dependence, and bilateral simultaneous/sequential onset (Petzold et al., 2014) in the presence of a reliable assay with high specificity.

Serum MOG IgG antibodies have been demonstrated in patients with relapsing optic neuritis by a number of groups (Reindl et al., 2013; Kitley et al., 2014; Martinez-Hernandez et al., 2015) and the majority are negative for AQP4 antibodies. These tests used cell-based assays to measure MOG antibodies (Reindl et al., 2013; Kitley et al., 2014). The coexistence of MOG autoantibodies and glycine receptor autoantibodies was described in 3/51 patients (Martinez-Hernandez et al., 2015).

The emerging clinical phenotype is that of a relapsing, potentially steroid-dependent, frequently bilateral (simultaneous or sequential) optic neuritis which may be isolated or associated with transverse myelitis. It will be important to test large cohorts of phenotypically well-defined patients with RION and CRION (Petzold et al., 2014) for the presence of MOG autoantibodies. These studies should be performed with the improved cell-based assay, which uses an IgG-specific secondary antibody rather than the commonly used anti-IgG (heavy and light chains), which binds to all classes of IgG, including IgM (Waters et al., 2015).

Figure 20.7 shows MRI and OCT of one of the authors' patients with MOG antibody relapsing optic neuritis. Serum AQP4 antibodies were not detected. This

patient had experienced bilateral, simultaneous optic neuritis as a child and this was associated with a less than three-segment myelopathy. Relapsing, sequential, bilateral optic neuritis developed in adulthood. Loss of vision in the right eye was preceded by severe pain on eye movements (pain visual analogue scale (VAS) 6–8/10). This was followed by pain on eye movements and visual loss in the left eye within 3 weeks. Active inflammation of the optic nerve was documented by MRI elsewhere (Fig. 20.7A). The patient was referred to our center, where bilateral pale optic discs were noted. During follow-up another episode of acute optic neuritis developed in the right eye. Again this was preceded by pain on eye movements and documented on MRI (Fig. 20.7B); immunosuppressive treatment was initiated and the situation had stabilized at 18-month follow-up. There was severe bilateral optic atrophy with an average peripapillary retinal nerve fiber layer thickness of 59 μm on the right and 64 μm on the left (Fig. 20.7C).

Leber hereditary optic neuropathy (LHON)

LHON is, as the name implies, a genetic disease (Riordan-Eva et al., 1995). Typically, a young male presents with painless loss of vision. A family history with visual loss in male cousins on the maternal side is not uncommon. Interestingly, it has been suggested that not all of the clinical features in LHON can be explained genetically (Smith et al., 1995). Smith et al. (1995) found tubulin autoantibodies in patients with LHON and these antibodies have been reported in optic neuritis, MS, and a range of other neurologic disorders. However, as tubulin is a ubiquitous intracellular protein, it is possible that the antibodies represent a response to tissue damage in general and are epiphenomenal.

Sarcoidosis

Sarcoidosis is a disease of unknown etiology for which the question of priority of description has not been resolved (Scadding, 1981). Ironically, one of the contenders for the first description, Jonathan Hutchinson (1828–1913), was surgeon to Moorfields Eye Hospital, but did not describe the association with visual loss. The reports on visual loss in sarcoidosis first appeared not long after Schaumann recognized the systemic nature of sarcoidosis (Levitt, 1941). The CNS is involved in about 5–26% of cases and optic nerve involvement in about 5%, depending on the patient's ethnic background (Kidd and Beynon, 2003; Scott et al., 2010). Typically there is dural-based granulomatous inflammation and, to a lesser degree, parenchymal noncaseating granuloma (Kidd and Beynon, 2003). Loss of vision can be due to uveitis or granuloma in the orbit or visual pathway.

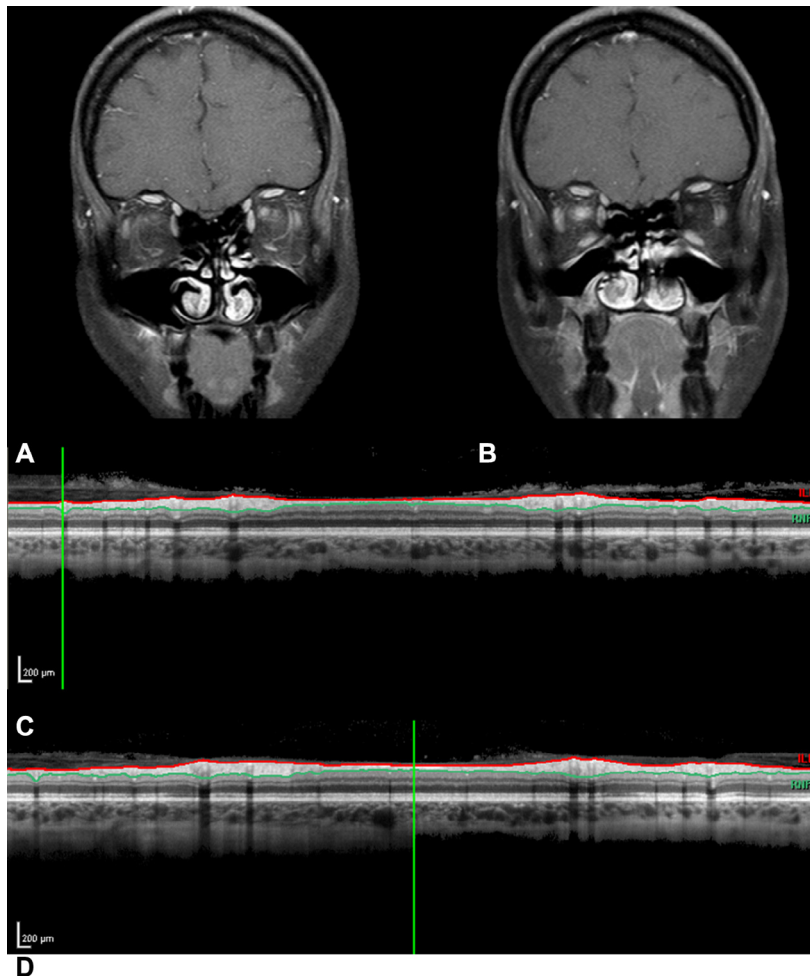


Fig. 20.7. Relapsing, sequential, bilateral optic neuritis in an own case with serum anti-myelin/oligodendrocyte glycoprotein (MOG) IgG autoantibodies. (A) The first magnetic resonance imaging (MRI: coronal short-tau inversion recovery with contrast) was taken during an episode of acute left optic neuritis. (B) The second MRI was taken a year later during an episode of acute right optic neuritis. Both MRIs show contrast enhancement of the respective optic nerves. There was severe atrophy of the posterior retinal nerve fiber layer on (C) the right and (D) the left.

Patients with sarcoidosis-associated optic neuropathy may experience Uhthoff phenomenon, a symptom more usually associated with demyelination (Haupert and Newman, 1997). Sarcoidosis may also mimic symptoms of cancer-associated retinopathy (Koestinger et al., 2006). The gold standard for diagnosis is a tissue biopsy, but this is not always possible in neuro-ophthalmic cases due to the site of involvement.

Patients of African or Afro-Caribbean heritage are at greater risk for sarcoidosis optic neuritis (Pokroy et al., 2001). A rare differential diagnosis is Blau syndrome, a hereditary granulomatous disease caused by mutations in the NOD2 gene (Caso et al., 2014). In Blau syndrome there is early eye involvement, iritis, and uveitis, which are aggressive and with a risk of blindness if not treated appropriately. This condition is interesting because it

carries features of both an inflammatory and an autoimmune condition (Caso et al., 2014).

A paradoxical observation, supporting the possibility of an autoimmune etiology in sarcoidosis, is the rare coexistence with common variable immunodeficiency (Dziadzio et al., 2011).

Systemic lupus erythematosus

Although the characteristic skin lesions of SLE were already documented by the 12th-century physician Rogerius (Keil, 2002), it was only in 1872 that Moric Kaposi (born Cohen) recognized the systemic nature of the disease (Kaposi, 1872). SLE has a variable clinical presentation, disease course, and prognosis. CNS involvement may indicate poorer prognosis and may

therefore lead to more aggressive treatments (Bertsias et al., 2008). MRI can show active SLE lesions in the CNS. Systemic laboratory markers in SLE include anemia, thrombocytopenia, leukopenia, increased serum creatinine, hyperferritinemia, and a range of positive antibodies to dsDNA, C1q, phospholipid, RNP, Ro/SSA, La/SSB, with reduced serum complement concentrations (Bertsias et al., 2008; Brey et al., 2011).

Visual impairment in SLE can be caused by inflammation of the CNS or vascular complications, typically branch retinal artery occlusion (Brandt et al., 1975; Brown et al., 1981), but it remains debatable whether SLE can cause autoimmune optic neuritis. Eleven cases have been reported in the literature (Cinefro and Frenkel, 1978; Deutsch and Corwin, 1988; Eckstein et al., 1995; Frigui et al., 2011); mild optic disc swelling was reported in 9/11 (82%). All patients were treated with corticosteroids and visual recovery was moderate to complete (Frigui et al., 2011). Focal vascular occlusive events involving the ciliary vasculature were suggested as an alternative differential diagnosis (Frigui et al., 2011). Optic chiasmitis associated with SLE has also been reported (Frohman et al., 2001). However, all but one of these studies (Frigui et al., 2011) predated the discovery of AQP4 autoantibodies, and the 2 patients from Frigui et al. did not appear to have been tested. This is important because there is an overlap between SLE and NMO, estimated to be 2–5% (Pittock et al., 2008; Jarius et al., 2012). Patients with SLE and optic neuritis or transverse myelitis should be tested for AQP4 autoantibodies (Petzold et al., 2014). It is possible that nonvascular-based damage to the optic nerves in SLE may be caused by such an overlap of autoimmunity.

Antiphospholipid autoantibodies are associated with an increased risk for ischemic stroke, which may require treatment with anticoagulation (Brey et al., 2011). One study, describing transient monocular blindness in SLE with antiphospholipid autoantibodies (Donders et al., 1998), showed frequent attacks in 9/10 (90%) patients, with 6/10 experiencing more than 10 attacks, typically lasting between 1 and 10 minutes, but in one patient lasting 3 hours. The pattern of visual field defects was heterogeneous, perceived as black, blurring, gray, or spotted (Donders et al., 1998), as is common in nonembolic transient monocular blindness (Petzold et al., 2013b). The differential diagnosis of transient monocular blindness in SLE includes secondary retinal vasospasm (Table 2 in Petzold et al., 2013a) and emboli (Giorgi et al., 2001). SLE can also present as pseudotumor cerebri, which can affect visual function as a result of the attendant papilledema (Deschler et al., 2010). The association of SLE with a retinopathy has also been described (Klinkhoff et al., 1986).

Table 20.4

Visual loss occurring in autoimmune or reactive vasculitis following infection, vaccination, or mediation

Condition	References
Cytomegalovirus	Pathanapitoon et al. (2013)
Dengue fever	Yip et al. (2012)
Human immunodeficiency virus	Stewart (2012)
Henoch–Schönlein purpura	Wen et al. (2005)
Human herpesvirus-6	Ogata et al. (2011)
Hypertrophic pachymeningitis	Kupersmith et al. (2004)
Immunoglobulin G subclass deficiency	Hassani et al. (2013)
Influenza vaccination	Blumberg et al. (1980)
Lyme disease	Karma et al. (1995)
Neurotoxocarosis	Finsterer and Auer (2007)
Ocular cat-scratch disease	Fukushima et al. (2001)
Syphilis	Halperin et al. (1989)
Toxoplasmosis	Raus et al. (2001)
Varicella-zoster virus	Wenkel et al. (1998)
Vigabatrin	Dieterle et al. (1994)
West Nile virus infection	Chan et al. (2006)
Hepatitis B and C infection	Achiron (1994)

Vasculitis

There is no consensus classification for vasculitic disorders. Some authors separate vasculitis related to infection (Table 20.4) from noninfectious primary and secondary vasculitis (Table 20.5). The latter group is dominated by rheumatic disease and the former embraces a large number of conditions. In all cases autoimmunity contributes at least partly to the pathologic process and many conditions respond well to corticosteroids.

Vasculitis can cause localized ischemia in any part of the visual system. In the retina small-vessel vasculitis causing branch retinal artery occlusion presents acutely as a localized ischemic area and at later stages as more atrophy of a sector. Central retinal artery occlusion causes ischemia of the whole retina, except for some sparing in the presence of a ciliary artery. Generally, ischemic tissue damage is more extensive with large-vessel vasculitis.

Vaccination

There is a large body of literature discussing the possible relationship between vaccination and autoimmune disease (Stübgen, 2013). In case of optic neuritis there is good evidence for at least a temporal relationship between vaccination and subsequent visual loss, mostly following influenza but also many other vaccinations. In children postvaccination optic neuritis may be a

Table 20.5

Visual loss from primary or secondary vasculitis

Condition	References
Antineutrophil cytoplasmic antibody (ANCA)-associated small-vessel vasculitis	Duran et al. (2004)
Allergic granulomatous angiitis	De Salvo et al. (2009)
Ankylosing spondylitis	Pazirandeh et al. (1988)
Behçet disease	Ozyazgan et al. (2014)
Churg–Strauss disease	Harris Nwanyanwu et al. (2013)
Cogan syndrome	Azami et al. (2014)
Giant cell arteritis	Bowers et al. (2009)
Granulomatosis with polyangiitis	Haynes et al. (1977)
Kawasaki disease	Okanishi and Enoki (2012)
Microscopic polyangiitis	Wacker et al. (2009)
Polyarteritis nodosa	Hutchinson (1984)
Primary antiphospholipid syndrome	Suvajac et al. (2007)
Rheumatic disease	Ciurtin et al. (2008)
Systemic lupus erythematosus	Ahmadieh et al. (1994)
Susac syndrome	Gross et al. (2004)
Sjögren syndrome	Gono et al. (2011)
Systemic sclerosis	Moulick et al. (2013)
Takayasu arteritis	Noel et al. (2013)
Ulcerative colitis	Ferro et al. (2014)

feature of acute demyelinating encephalomyelitis and recovery of vision is typically good (Fujii et al., 2012).

Infectious and postinfectious

There are numerous reports of optic neuritis following almost any type of infection (Table 20.6). It has been more challenging to establish a causal link. Any interpretation of these data will need to take the epidemiology of the related pathogen into account, with herpesviruses having a particular high prevalence. In these patients, retrobulbar optic neuritis, papillitis, neuroretinitis, and vasculitis may coexist or occur in isolation (Vishwanath et al., 2013). Accepting a likely reporting bias of first presentations, it seems that most cases are that of an isolated unilateral or bilateral optic neuritis. There is no solid evidence as to the cause in these cases, but as in postinfectious vasculitis, early treatment with corticosteroids might improve outcome, although that was not the situation in one of the authors’ cases with bilateral optic neuritis which followed a generalized infection of unknown etiology and poor outcome (Fig. 20.8; perception of light only both eyes), despite acute treatment with high-dose corticosteroids and a prolonged oral taper.

Table 20.6

Postinfectious optic neuritis following a presumed, limited autoimmune reaction

Condition	References
<i>Bartonella</i>	Täger et al. (2008)
<i>Brucella</i>	Romero et al. (1999)
Cytomegalovirus	Mansor and Li (1995)
Chikungunya fever	Mahesh et al. (2009)
Coronavirus	Dessau et al. (1999)
<i>Coxiella burnetii</i>	Ong et al. (2010)
Dengue	Preechawat and Poonyathalang (2005)
Epstein–Barr virus	Peponis et al. (2012)
Echovirus	Ihanamäki et al. (2004)
Ehrlichiosis	Lee et al. (2003)
Human immunodeficiency virus	Sweeney et al. (1993)
Hepatitis	Zhu et al. (2012)
Herpes simplex	Francis et al. (2003)
<i>Histoplasma</i>	Yau et al. (1996)
Inoue–Melnick virus	Inoue et al. (1984)
Leprosy	Prabha et al. (2013)
Lyme	Scott et al. (1997)
Measles	Srivastava and Nema (1963)
Mumps	Gnananayagam et al. (2005)
<i>Mycoplasma pneumoniae</i>	Sagui et al. (2007)
Rubella	Cansu et al. (2005)
<i>Streptococcus</i>	Kassiri et al. (2010)
Syphilis	Pokroy et al. (2001)
Tick-borne encephalitis virus	Stadtbäumer et al. (2004)
<i>Toxoplasma</i>	Moreno et al. (1992)
Tuberculosis	Lynn and Lightman (2004)
Typhus	Khairallah et al. (2009)
Varicella-zoster virus	de Mello Vitor et al. (2011)
West Nile virus	Garg and Jampol (2005)
Whipple disease	Vital Durand et al. (2002)

Vogt–Koyanagi–Harada syndrome

Vogt–Koyanagi–Harada syndrome is an autoimmune disease which affects multiple systems (Pan and Hirose, 2011). Pathology of the eye most frequently involves uveitis. Optic neuritis in Vogt–Koyanagi–Harada syndrome is very rare. Other organs involved are the inner ear (tinnitus, hearing loss), the skin (patchy depigmentation, vitiligo), the hair (patchy loss), and the meninges. Headaches and photophobia are frequent presenting symptoms (Rao et al., 2010). Autoantibodies have been found against Müller cells and the outer segments of the photoreceptors and against a range of tissue antigens (reviewed by Braithwaite et al., 2014). Most consistent have been data on autoantibodies directed at melanocytes. Immunosuppressive treatment may be required (Greco et al., 2013).

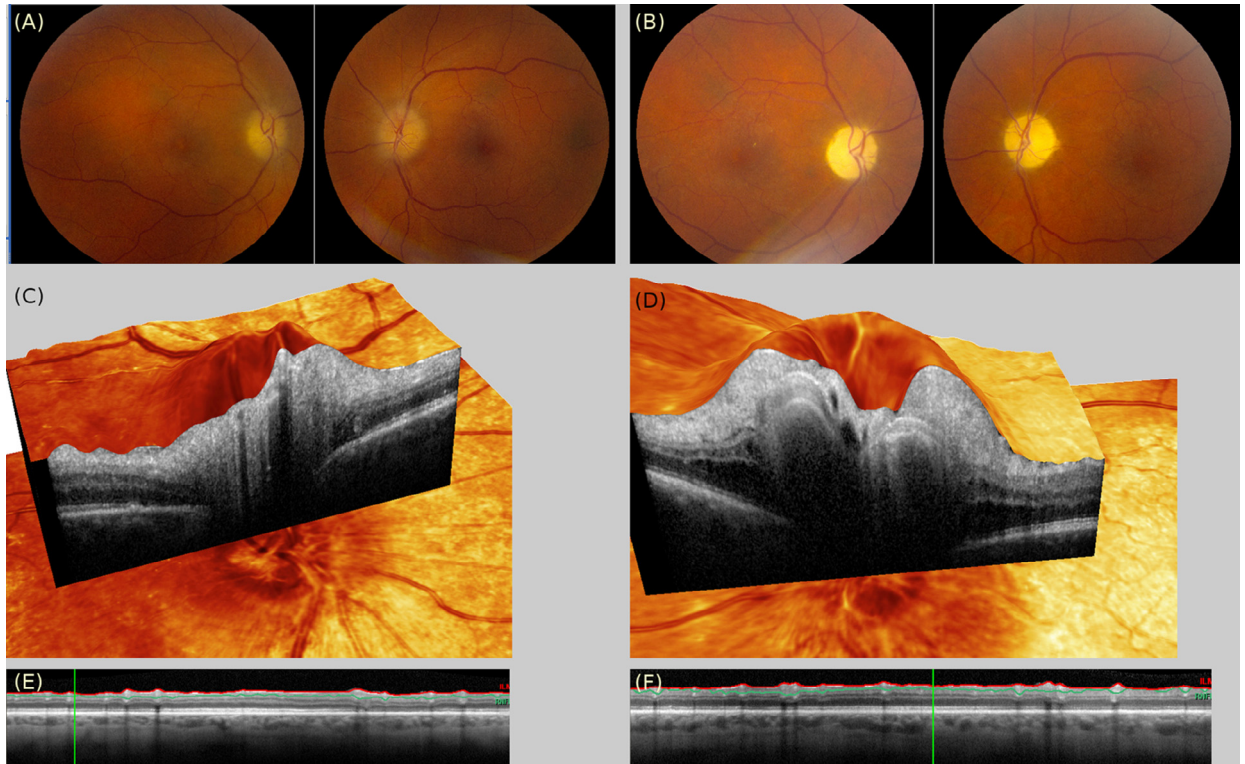


Fig. 20.8. Post infectious bilateral simultaneous optic neuritis in a patient. **(A)** In the acute phase there is bilateral papilledema, which is worse on the left, where splinter hemorrhages are present. **(B)** Bilateral optic atrophy ensued within 3 months. **(C)** In the acute phase, the three-dimensional confocal scanning laser ophthalmoscope/optical coherence tomography (OCT) image shows swelling of the axons as they exit the optic disc up to the retinal nerve fiber layer, where retinal folds are clearly visible. **(D)** Optic disc swelling is worse on the left with additional subretinal fluid. **(E)** At 3-month follow-up, the peripapillary OCT ring scan confirms almost complete loss of the posterior retinal nerve fiber layer on the right and **(F)** on the left consistent with the fundus photographs. The inner nuclear layer and outer retinal layers remain preserved.

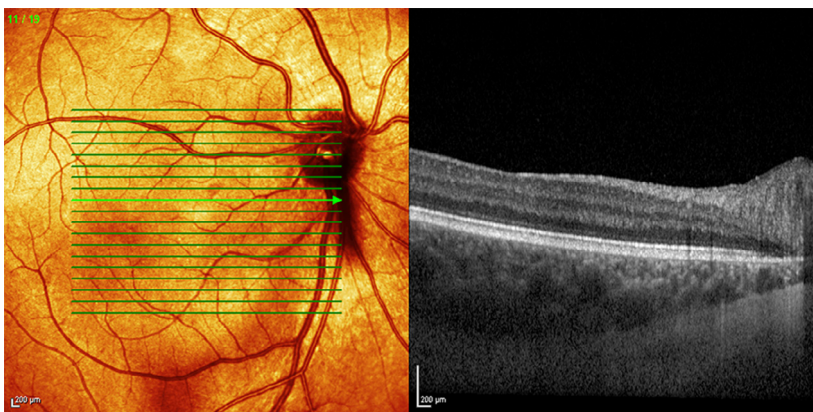


Fig. 20.9. Thickening of the choroid in a patient with Vogt-Koyanagi-Harada syndrome using enhanced depth imaging optical coherence tomography. The thickness of the choroid exceeds 400 µm in the perimacular rim.

OCT helps to distinguish serous retinal detachment type and optic disc swelling type in Vogt-Koyanagi-Harada disease. In addition, enhanced depth imaging OCT is a useful tool to assess thickening of the choroid,

a frequent finding in Vogt-Koyanagi-Harada syndrome (Fig. 20.9) (Nakayama et al., 2012). Following treatment there is thinning of the choroid (Nakayama et al., 2012).

Inflammatory bowel disease

Extraintestinal manifestations of inflammatory bowel disease include optic neuritis. Most reports are from patients suffering from Crohn disease (Gupta et al., 2005; Felekis et al., 2009b). Very occasionally a diagnosis of optic perineuritis is made (McClelland et al., 2012; Tung et al., 2013). Optic neuritis may be a complication of inflammatory bowel disease treatment, with several cases reported in association with treatment with tumor necrosis factor inhibitors (Chan and Castellanos, 2010; Tristano, 2010), and may require discontinuation of treatment and/or change to a different immunosuppressive drug (Felekis et al., 2009a).

Most patients improve with corticosteroid treatment (Tran et al., 2005; Han et al., 2006; Felekis et al., 2009b; Ouakaa-Kchaou et al., 2009; Barabino et al., 2011). Figure 20.10 shows a personal case suffering from Crohn disease who had an episode of painless isolated optic neuritis in her left eye. Notably, she had not been treated with any tumor necrosis factor inhibitors. The visual

evoked potentials were prolonged on the left (112 ms) and normal on the right (104 ms). This patient responded to corticosteroids, but was left with a disabling central scotoma due to localized atrophy of the papillomacular bundle in the left eye.

AUTOIMMUNE RETINOPATHIES

Nonparaneoplastic autoimmune retinopathies are more common than paraneoplastic retinopathies and will be discussed first (Braithwaite et al., 2014; Grange et al., 2014). The diagnostic workup of autoimmune retinopathies should include OCT, autofluorescence, and electrodiagnostic testing (Fig. 20.4). A common finding is a hyperautofluorescent, perimacular ring which is associated with OCT evidence for loss of outer retinal structures such as the inner/outer segment layer. Presence of microcystic changes, particularly of the inner nuclear layer, has also been reported (Grange et al., 2014).

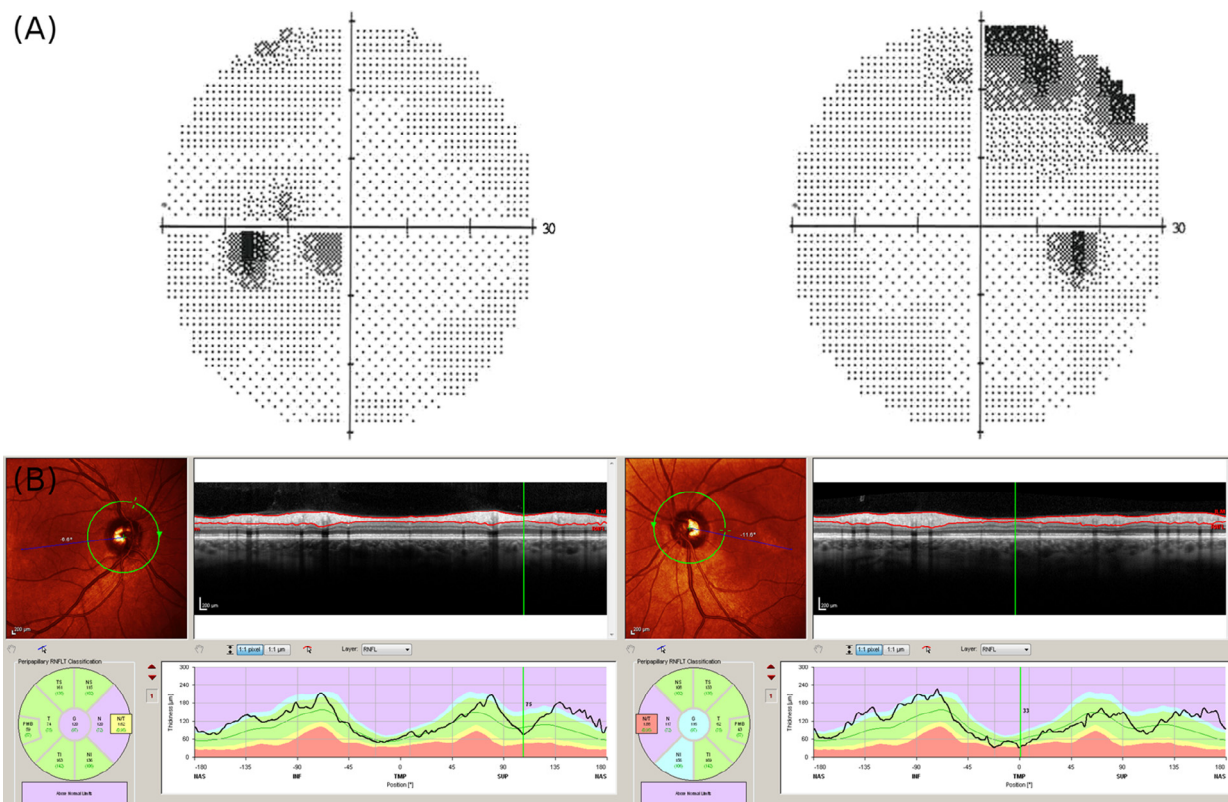


Fig. 20.10. Painless, isolated left optic neuritis (ION) in a patient with Crohn’s disease. (A) The visual fields (Humphrey 30-2, Swedish interactive thresholding algorithm) shown are generally depressed and show a cecocentral scotoma in the left eye and a small area of visual field loss in the superior temporal quadrant of the right eye, which indicates involvement of the prechiasmatic optic nerve and the chiasm. (B) The corresponding retinal optical coherence tomography documents segmental atrophy of the papillomacular bundle in the left eye. Note that by convention visual fields are shown as viewed by the patient with the left eye to the left of the figure and the fundus as viewed by the physician with the left eye to the right of the figure.

Nonparaneoplastic autoimmune retinopathy

The presence of autoimmune retinopathy in the absence of cancer has been described in 2 patients (Mizener et al., 1997). Both had clinical and electrophysiologic features typical for a cancer-associated retinopathy, but no evidence for cancer after 5 and 7 years of follow-up, respectively. Visual field loss progressed over the years. Both also had a strong family history for autoimmune disease, and the second patient was eventually diagnosed with common variable immunodeficiency. The typical staining of the inner plexiform layer with serum from these 2 patients is shown in Figure 20.11 (A, B), with absence

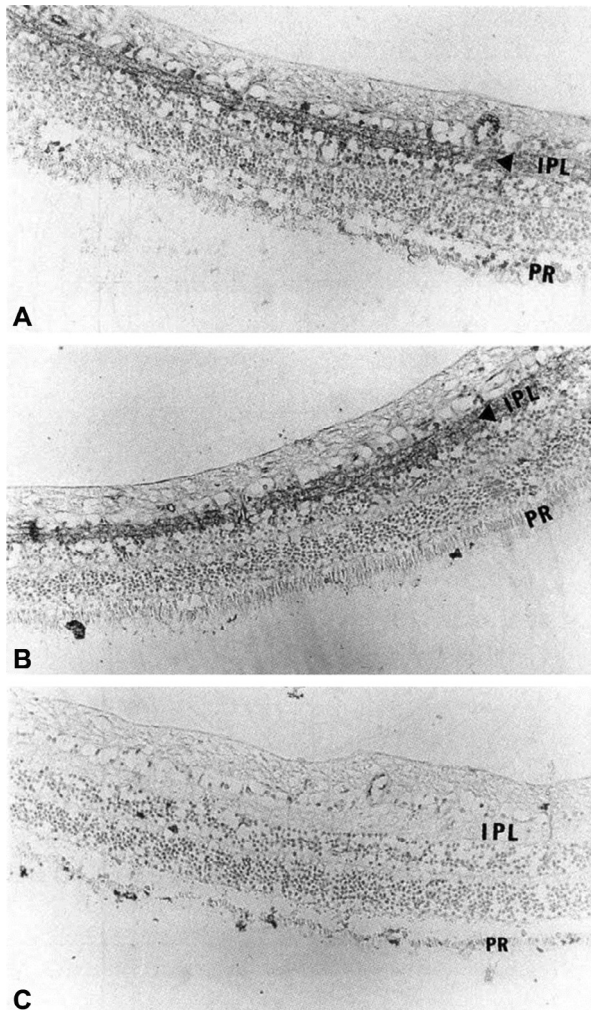


Fig. 20.11. Light microscopic photographs of retinal immunocytochemistry performed using serum from patient 1 (A), patient 2 (B), and a normal control subject (C). Tissue was stained with immunoperoxidase followed by counterstaining with methyl green. The inner retina is at the top of each photograph; the photoreceptor layer (PR) is at the bottom. Both patients' sera specifically label the inner plexiform layer (IPL, arrows). (Reproduced with permission from Mizener et al., 1997.)

of inner plexiform layer staining with control serum (Fig. 20.11C). Clinically these patients presented with more asymmetric clinical features, but both had electrophysiologic evidence of bilateral pathology and in one the second eye became symptomatic during follow-up. Particularly in the first patient the immunohistochemical evidence for IPL-targeted autoimmunity correlated well with electrophysiologic evidence for bipolar cell dysfunction (see reduced b-waves in Fig. 20.12).

The combination of progressive visual loss, scotomata, visual field deficits, electrophysiologic abnormalities, and the circulating retinal antibodies in these cases strongly supports the diagnosis of an autoimmune retinopathy (Braithwaite et al., 2014; Grange et al., 2014). There is a need to develop and validate a standardized test for these autoantibodies because of poor interlaboratory agreement (Braithwaite et al., 2014; Grange et al., 2014) and very low availability around the world. In various centers “autoimmune” forms of retinitis autoantibodies have been reported with antibodies against α -enolase, Müller cell-specific antigen, TULP1, arrestin, carbonic anhydrase, heat shock protein-70, neurofilament protein, photoreceptor cell-specific nuclear receptor, recoverin, transducin- β and transient receptor potential cation channel, subfamily M, member 1 (Braithwaite et al., 2014; Grange et al., 2014). There are no accepted standards for their detection, and the antibodies are in most cases not disease-specific.

Treatment of nonparaneoplastic autoimmune retinopathies remains essentially empirical. Corticosteroids, intravenous immunoglobulin, plasmapheresis, mycophenolate mofetil, azathioprine, cyclosporine, and rituximab have all been tried, with varying success (Braithwaite et al., 2014; Grange et al., 2014). A difficulty for future trials will be the small number of patients and the disease course which can stabilize over time.

Paraneoplastic autoimmune retinopathy

Patterns of visual field loss are variable but central or paracentral scotoma and peripheral constriction are common (Petzold and Plant, 2005). Progressive visual field loss combined with photopsia and nyctalopia is suggestive of melanoma-associated retinopathy and cancer-associated retinopathy (Rahimy and Sarraf, 2013). Cancer-associated retinopathy is more common than melanoma-associated retinopathy (Grange et al., 2014) and paraneoplastic-triggered autoimmune visual loss can be associated with antibodies to all the major paraneoplastic antigens, including Hu, Yo, Ma2, Ri, Tr, CRMP5 (CV2), and voltage-gated calcium channels associated with the relevant tumors (Bataller and Dalmau, 2004; Braithwaite et al., 2014). Electrodiagnostic testing will be helpful (Fig. 20.4). There are no data

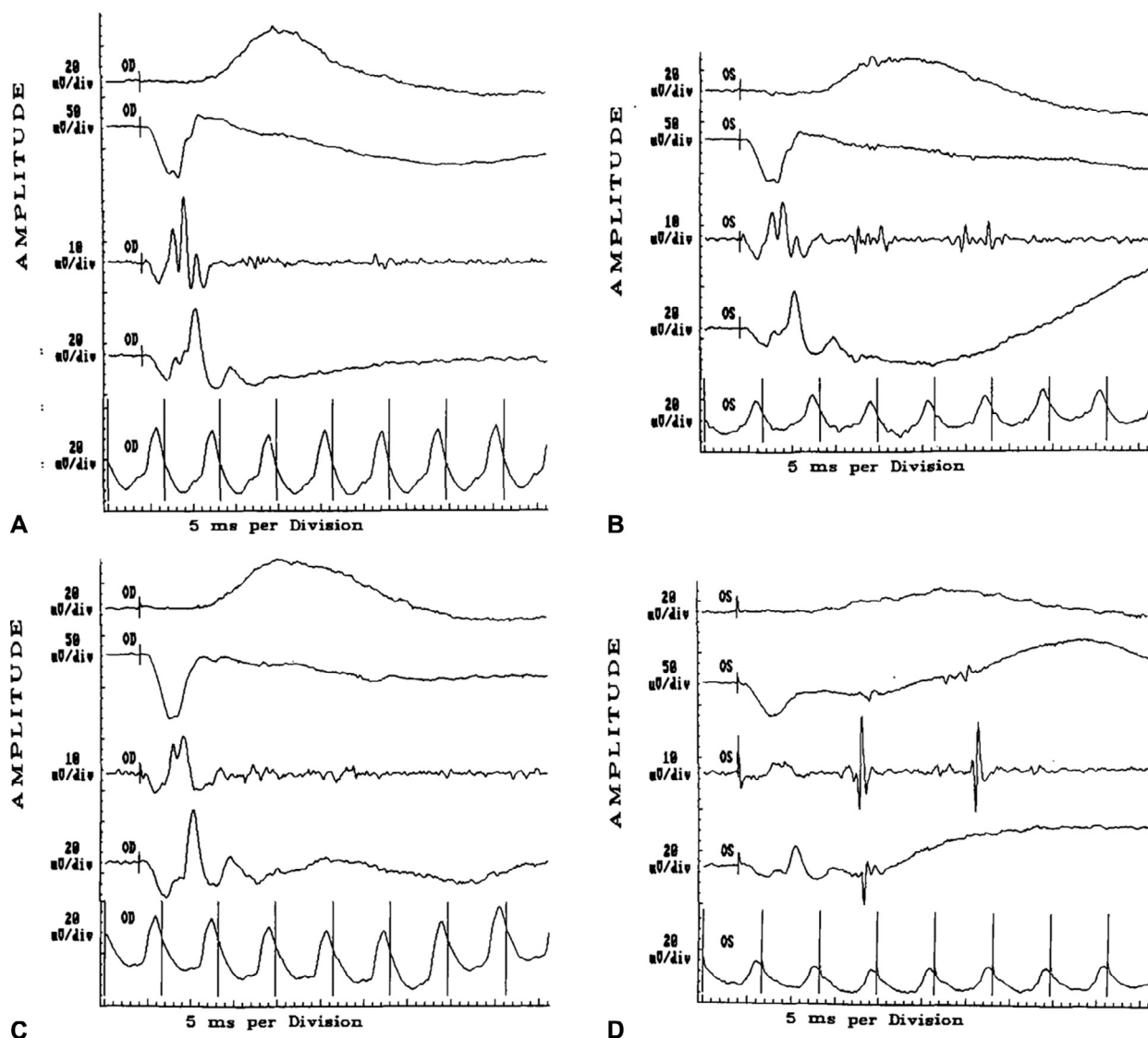


Fig. 20.12. Patient 1. Electroretinograms of the right eye (A) and left eye (B) recorded on June 11, 1993, showing decreased amplitude of dark-adapted (24-dB attenuated) rod response (top tracing, A and B) of the left eye compared with the right eye, and decreased b-wave (second tracing from the top, A and B) in the left eye compared with the right eye. Repeat electroretinograms of the right eye (C) and left eye (D) recorded on July 25, 1995 show further loss of amplitude on dark-adapted rod response (left eye, top tracing, D), further loss of b waves (both eyes, second tracing from top, C and D), and marked loss of oscillatory potentials (both eyes, third tracing from top, C and D). The waveforms shown represent (from top to bottom for each date) dark-adapted rod response (24-dB attenuation), maximal combined response (0-dB attenuation), oscillatory potentials (0-dB attenuation), single-flash light-adapted cone response (0-dB attenuation), and 30-Hz flicker responses. (Reproduced with permission from Mizener et al., 1997.)

from trials and treatment is targeted at the primary tumor, but plasma exchange may also be considered in some cases (Liu et al., 2014).

CANCER-ASSOCIATED RETINOPATHY

Sawyer et al. (1976) first described cancer-associated retinopathy in 3 patients with bronchial carcinoma. Cancer-

associated retinopathy has subsequently also been found with malignancies of the breast, cervix, endometrium, ovaries, prostate, bladder, thymus, thyroid, pancreas, colon, and hematologic malignancies (Rahimy and Sarraf, 2013). Central or paracentral scotoma is noted in 50–61% of cases, and there is rapid progression of visual field loss which is typically painless (Ohguro et al., 2004). Bilateral visual loss is the most common

presentation, followed by unilateral and asymmetric visual field loss (Chan, 2003).

As in the nonparaneoplastic neurologic diseases, it is unlikely that the paraneoplastic antibodies cause the visual symptoms. Complement-mediated autoimmunity is a possible mechanism in most patients, as visual field loss is typically persistent and autoantibodies bind to retinal ganglion cells, with antibodies against recoverin and enolase probably being most established (Braithwaite et al., 2014). However there are possibly other subgroups with more dominant outer retinal pathology. Cone dysfunction leads to photosensitivity, reduced color vision, and central scotomata. Rod dysfunction causes nyctalopia, prolonged dark adaptation, and peripheral and/or ring scotomata (Goldstein et al., 1999; Vaphiades et al., 2000).

MELANOMA-ASSOCIATED RETINOPATHY SYNDROME

Ripps et al. (1984) were the first to describe the association between night blindness (nyctalopia) and photopsia in a 30-year-old man with melanoma. The authors hypothesized that toxic properties of the chosen chemotherapy (vincristine) were the cause (Ripps et al., 1984). Generally, Gass is credited with recognizing the melanoma-associated retinopathy syndrome (Gass, 1984; Berson and Lessell, 1988). The typical clinical presentation is with night blindness, frequently associated with photopsia, which can have a shimmering border (Braithwaite et al., 2014). In contrast to cancer-associated retinopathy, there is no, or only very slow, progression. This makes the differential diagnosis to other retinal disorders such as acute zonal occult outer retinopathy (AZOOR) more challenging. There are, however, less likely to be discrete scotomata in melanoma-associated retinopathy as are found in AZOOR. Perimetry can be unreliable in melanoma-associated retinopathy because the constant photopsia occur throughout the visual field and mimic the target in automated perimetry. In AZOOR the photopsias tend to be restricted to the scotomata.

The autoantibodies found in melanoma-associated retinopathy stain for the bipolar layer of the retina (Weinstein et al., 1994; Keltner et al., 2001). Because nyctalopia is such a frequent clinical finding in melanoma-associated retinopathy, it would not be surprising if some of the autoantibodies found in melanoma-associated retinopathy would specifically target bipolar cells which are specific to rod function (Fig. 20.1, third row). However, at the time of writing there are no validated diagnostic antibodies (Braithwaite et al., 2014). Suggested candidate autoantibodies target two isoforms of the fructose biphosphate aldolase (aldolase A and C) (Lu et al., 2009). Historically, the association of

glycolytic enzymes with autoimmunity of the CNS is not uncommon and the jury is still out as to whether or not they are pathologically relevant or epiphenomenal (Petzold, 2013).

BILATERAL DIFFUSE UVEAL MELANOCYTIC PROLIFERATION

Machemer (1966) first described paraneoplastic melanocytic proliferation. Patients suffer from rapid progressive visual loss. Melanocytic proliferation causes destruction of the uveal tissue, retina, and RPE. Fundoscopy demonstrates pigmented and pale melanocytic tumors. OCT shows subretinal fluid, hyperreflective spots, and an irregular thickened RPE. At the level of the RPE, en face OCT shows dark spots which correspond to hyperfluorescence spots on the blue-light autofluorescence (Jansen et al., 2015). The visual symptoms can precede discovery of the primary tumor. Miles et al. (2012) suggested the presence of an antibody that induced melanocyte proliferation. This syndrome, now also called bilateral diffuse uveal melanocytic proliferation, responds to plasma exchange (Miles et al., 2012; Jansen et al., 2015), but the cause is unknown.

Acute zonal occult outer retinopathy

An important differential diagnosis, particular for non-paraneoplastic autoimmune retinopathies, is AZOOR (Grange et al., 2014; Mrejen et al., 2014). The typical clinical presentation of AZOOR is that of a unioocular circumscribed visual field defect with positive symptoms predominantly at the outer border of the defect (Gass et al., 2002). The border region appears brighter on blue autofluorescence. Electrodiagnostic tests and OCT support the diagnosis and confirm outer retinal (photoreceptor) dysfunction. A considerable proportion of patients with AZOOR have concomitant autoimmune disease (Gass et al., 2002; Heckenlively and Ferreyra, 2008). There is ongoing research to identify candidate retinal autoantibodies for future clinical and laboratory validation studies. There is no evidence base for treatment, although corticosteroids are sometimes prescribed in the acute phase. Some localized forms of retinitis are named according to the part of the retina affected – if peripapillary, then the “idiopathic big blind spot syndrome,” and if paramacular, “macular neuroretinitis.” How these conditions relate to AZOOR is uncertain, but OCT confirms similar location of the pathology. Idiopathic big blind spot syndrome tends to be unioocular and macular neuroretinitis tends to be binocular. Positive symptoms localized to the scotomata are characteristic of this group of conditions.

CONCLUSION

This chapter reviewed the diagnosis of autoimmune-related visual loss on a broader basis than usually covered in clinical reviews. This was designed to highlight the importance of considering autoimmune visual loss as a consequence of any systemic disease. However, the evidence for a primary autoimmune target in the visual system is missing in many conditions, and the differential diagnoses mostly include occlusive vascular pathology, autoimmunity epiphenomena following tissue damage, autoinflammation related to hereditary disease or cancer, and nonspecific systemic inflammation in response to a whole range of infectious diseases and vaccinations.

There are notable examples of specific autoimmunity targeted to the nonmyelinated and myelinated parts of the visual system, and in one disease (NMO) to astrocytes. Nonmyelinated axons and their neuronal cell bodies in the retina succumb to autoimmune disease just as their proximal myelinated partners, but the autoantibodies are distinct, although few are available as validated tests, and not all will be markers for an immunotherapy response disease.

REVIEW OF LITERATURE

We identified 8180 potentially relevant references. The full list can be requested from the authors. Our aim was to reach a balanced selection of references between original clinical descriptions and landmark autoimmune discoveries within the space limitations of this chapter.

CONFLICT OF INTEREST

The authors have no conflict of interest.

ACKNOWLEDGMENTS

The authors' work described in this paper is supported by the University College London Comprehensive Biomedical Research Centre, the Moorfields Biomedical Research Centre, and the Dutch MS Research Foundation. We apologize to those colleagues whose work we did not cite due to space limitations.

REFERENCES

Achiron LR (1994). Postinfectious hepatitis B optic neuritis. *Optom Vis Sci* 71: 53–56.
 Ahmadi H, Roodpeyma S, Azarmina M et al. (1994). Bilateral simultaneous optic neuritis in childhood systemic lupus erythematosus. A case report. *J Neuroophthalmol* 14: 84–86.
 Azami A, Maleki N, Kalantar Hormozi M et al. (2014). Interstitial keratitis, vertigo, and vasculitis: typical Cogan's syndrome. *Case Rep Med* 2014: 830831.

Balk LJ, Steenwijk MD, Tewarie P et al. (2015). Bidirectional trans-synaptic axonal degeneration in the visual pathway in multiple sclerosis. *J Neurol Neurosurg Psychiatry* 86: 419–424.
 Barabino AV, Gandullia P, Calvi A et al. (2011). Sudden blindness in a child with Crohn's disease. *World J Gastroenterol* 17: 4344–4346.
 Barton JJS (2011). Disorders of higher visual processing. *Handb Clin Neurol* 102: 223–261.
 Bataller L, Dalmau J (2004). Neuro-ophthalmology and paraneoplastic syndromes. *Curr Opin Neurol* 17: 3–8.
 Bennett JL, Lam C, Kalluri SR et al. (2009). Intrathecal pathogenic anti-aquaporin-4 antibodies in early neuromyelitis optica. *Ann Neurol* 66: 617–629.
 Berson EL, Lessell S (1988). Paraneoplastic night blindness with malignant melanoma. *Am J Ophthalmol* 106: 307–311.
 Bertsias G, Ioannidis JPA, Boletis J et al. (2008). EULAR recommendations for the management of systemic lupus erythematosus. Report of a Task Force of the EULAR Standing Committee for International Clinical Studies Including Therapeutics. *Ann Rheum Dis* 67: 195–205.
 Biotti D, Boucher S, Ong E et al. (2013). Optic neuritis as a possible phenotype of anti-GQ1b/GT1a antibody syndrome. *J Neurol* 260: 2890–2891.
 Blumberg S, Bienfang D, Kantrowitz FG (1980). A possible association between influenza vaccination and small-vessel vasculitis. *Arch Intern Med* 140: 847–848.
 Bowers B, Gupta D, Patel H et al. (2009). Exophthalmos as a presenting manifestation of limited Wegener's granulomatosis in a patient with prior Graves' disease. *Clin Med Case Rep* 2: 35–37.
 Bradley J, Blake J, Chamberlain S et al. (2000). Clinical, biochemical and molecular genetic correlations in Friedreich's ataxia. *Hum Mol Genet* 9: 275–282.
 Braithwaite T, Holder GE, Lee RWJ et al. (2014). Diagnostic features of the autoimmune retinopathies. *Autoimmun Rev* 13: 534–538.
 Brandt K, Lessell S, Cohen A (1975). Cerebral disorders of vision in systemic lupus erythematosus. *Ann Intern Med* 83: 163–169.
 Brey RL, Muscal E, Chapman J (2011). Antiphospholipid antibodies and the brain: a consensus report. *Lupus* 20: 153–157.
 Brickshawana A, Hinson SR, Romero MF et al. (2014). Investigation of the KIR4.1 potassium channel as a putative antigen in patients with multiple sclerosis: a comparative study. *Lancet Neurol* 13: 795–806.
 Brown GC, Magargal LE, Shields JA et al. (1981). Retinal arterial obstruction in children and young adults. *Ophthalmology* 88: 18–25.
 Burggraaff MC, Trieu J, de Vries-Knopfert WA et al. (2014). The clinical spectrum of microcystic macular oedema. *Invest Ophthalmol Vis Sci* 55: 952–961.
 Cansu A, Ayşe S, Sengül O et al. (2005). Bilateral isolated acute optic neuritis in a child after acute rubella infection. *Jpn J Ophthalmol* 49: 431–433.
 Caso F, Costa L, Rigante D et al. (2014). Caveats and truths in genetic, clinical, autoimmune and autoinflammatory issues in Blau syndrome and early onset sarcoidosis. *Autoimmun Rev* 13: 1220–1229.

- Chan JW (2003). Paraneoplastic retinopathies and optic neuropathies. *Surv Ophthalmol* 48: 12–38.
- Chan JW, Castellanos A (2010). Infliximab and anterior optic neuropathy: case report and review of the literature. *Graefes Arch Clin Exp Ophthalmol* 248: 283–287.
- Chan CK, Limstrom SA, Tarasewicz DG et al. (2006). Ocular features of West Nile virus infection in North America: a study of 14 eyes. *Ophthalmology* 113: 1539–1546.
- Charcot M (1868). *Leçons sur les maladies chroniques du système nerveux: I–II – Des scléroses de la moelle épinière*. Gazette des hopitaux 14: 405–406, 554–555, 557–558, 566.
- Chen M, Daha MR, Kallenberg CG (2010). The complement system in systemic autoimmune disease. *J Autoimmun* 34: J276–J286.
- Cinefro RJ, Frenkel M (1978). Systemic lupus erythematosus presenting as optic neuritis. *Ann Ophthalmol* 10: 559–563.
- Ciurtin C, Cojocaru VM, Aramă S et al. (2008). Epidemiology of ocular involvement in autoimmune diseases. *Rom J Intern Med* 46: 243–247.
- Cunha-Vaz J, Bernardes R, Lobo C (2010). Blood–retinal barrier. *Eur J Ophthalmol* 21: 3–9.
- De Mello Vitor B, Foureaux ECM, Porto FBO (2011). Herpes zoster optic neuritis. *Int Ophthalmol* 31: 233–236.
- De Salvo G, Li Calzi C, Anastasi M et al. (2009). Branch retinal vein occlusion followed by central retinal artery occlusion in Churg–Strauss syndrome: unusual ocular manifestations in allergic granulomatous angiitis. *Eur J Ophthalmol* 19: 314–317.
- Deschler EK, Miller NR, Subramanian PS (2010). Papilloedema and vision loss with elevated cerebrospinal fluid protein in a patient with systemic lupus erythematosus: diagnosis and management challenges. *Br J Ophthalmol* 94: 131–142.
- Dessau RB, Lisby G, Frederiksen JL (1999). Coronaviruses in spinal fluid of patients with acute monosymptomatic optic neuritis. *Acta Neurol Scand* 100: 88–91.
- Deutsch T, Corwin H (1988). Lupus optic neuritis with negative serology. *Ann Ophthalmol* 20: 383–384.
- Devic E (1894). Myélite subaiguë compliquée de névrite optique. *Bull Med* 8: 1033–1034.
- Dieterle L, Becker EW, Berg PA et al. (1994). Allergic vasculitis caused by vigabatrin. *Nervenarzt* 65: 122–124.
- Donders RC, Kappelle LJ, Derksen RH et al. (1998). Transient monocular blindness and antiphospholipid antibodies in systemic lupus erythematosus. *Neurology* 51: 535–540.
- Duran E, Merkel PA, Sweet S et al. (2004). ANCA-associated small vessel vasculitis presenting with ischemic optic neuropathy. *Neurology* 62: 152–153.
- Dziadzio M, Hortobágyi T, Kidd D et al. (2011). Common variable immunodeficiency with coexisting central nervous system sarcoidosis: case report and literature review with implications for diagnosis and pathogenesis. *Ideggyogy Sz* 64: 405–408.
- Eckstein A, Kotter I, Wilhelm H (1995). Atypical optic neuritis in systemic lupus erythematosus (SLE). *Klin Monatsbl Augenheilkd* 207: 310–313.
- Felekis T, Katsanos K, Christodoulou D et al. (2009a). Reversible bilateral optic neuritis after infliximab discontinuation in a patient with Crohn’s disease. *J Crohns Colitis* 3: 212–214.
- Felekis T, Katsanos K, Kitsanou M et al. (2009b). Spectrum and frequency of ophthalmologic manifestations in patients with inflammatory bowel disease: a prospective single-center study. *Inflamm Bowel Dis* 15: 29–34.
- Ferguson TA, Griffith TS (2006). A vision of cell death: Fas ligand and immune privilege 10 years later. *Immunol Rev* 213: 228–238.
- Ferro JM, Oliveira SN, Correia L (2014). Neurologic manifestations of inflammatory bowel diseases. *Handb Clin Neurol* 120: 595–605.
- Finsterer J, Auer H (2007). Neurotoxocarosis. *Rev Inst Med Trop Sao Paulo* 49: 279–287.
- Firth D (1948). *The case of Augustus d’Este*. Cambridge University Press, Cambridge.
- Francis PJ, Jackson H, Stanford MR et al. (2003). Inflammatory optic neuropathy as the presenting feature of herpes simplex acute retinal necrosis. *Br J Ophthalmol* 87: 512–514.
- Frigui M, Frikha F, Sellemi D et al. (2011). Optic neuropathy as a presenting feature of systemic lupus erythematosus: two case reports and literature review. *Lupus* 20: 1214–1218.
- Frohman L, Frieman B, Wolansky L (2001). Reversible blindness resulting from optic chiasmits secondary to systemic lupus erythematosus. *J Neuroophthalmol* 21: 18–21.
- Fujii K, Suyama M, Chiba K et al. (2012). Acute disseminated encephalomyelitis following 2009 H1N1 influenza vaccine. *Pediatr Int* 54: 539–541.
- Fukushima H, Numaga J, Yoshimoto M et al. (2001). An ocular cat-scratch disease patient positive for cytoplasmic anti-neutrophil cytoplasmic antibody. *Graefes Arch Clin Exp Ophthalmol* 239: 882–885.
- Garg S, Jampol LM (2005). Systemic and intraocular manifestations of West Nile virus infection. *Surv Ophthalmol* 50: 3–13.
- Gass J (1984). Uveitis Update. Proceedings of the International Symposium on Uveitis–Hanasaari in Espoo, Finland. Elsevier Science, Amsterdam. pp. 407–408.
- Gass JD, Agarwal A, Scott IU (2002). Acute zonal occult outer retinopathy: a long-term follow-up study. *Am J Ophthalmol* 134: 329–339.
- Gelfand JM, Nolan R, Schwartz DM et al. (2012). Microcystic macular oedema in multiple sclerosis is associated with disease severity. *Brain* 1786–1793.
- Giorgi D, David V, Afeltra A et al. (2001). Transient visual symptoms in systemic lupus erythematosus and antiphospholipid syndrome. *Ocul Immunol Inflamm* 9: 49–57.
- Gnananayagam EJ, Agarwal I, Peter J et al. (2005). Bilateral retrobulbar neuritis associated with mumps. *Ann Trop Paediatr* 25: 67–68.
- Goldstein S, Syed N, Milam A et al. (1999). Cancer-associated retinopathy. *Arch Ophthalmol* 117: 1641–1645.
- Gono T, Kawaguchi Y, Katsumata Y et al. (2011). Clinical manifestations of neurological involvement in primary Sjögren’s syndrome. *Clin Rheumatol* 30: 485–490.
- Grange L, Dalal M, Nussenblatt RB et al. (2014). Autoimmune retinopathy. *Am J Ophthalmol* 157: 266–272.e1.
- Greco A, Fusconi M, Gallo A et al. (2013). Vogt–Koyanagi–Harada syndrome. *Autoimmun Rev* 12: 1033–1038.
- Gross M, Banin E, Eliashar R et al. (2004). Susac syndrome. *Otol Neurotol* 25: 470–473.

- Gupta G, Gelfand JM, Lewis JD (2005). Increased risk for demyelinating diseases in patients with inflammatory bowel disease. *Gastroenterology* 129: 819–826.
- Halperin LS, Lewis H, Blumenkranz MS et al. (1989). Choroidal neovascular membrane and other chorioretinal complications of acquired syphilis. *Am J Ophthalmol* 108: 554–562.
- Han SH, Lee OY, Yang SY et al. (2006). A case of optic neuritis associated with Crohn's disease. *Korean J Gastroenterol* 48: 42–45.
- Harris Nwyanwu KM, De Lott LB, Cornblath WT et al. (2013). Transient monocular vision loss due to Churg–Strauss syndrome vasculitis. *JAMA Ophthalmol* 131: 117–119.
- Hassani RTJ, Rousseau A, de Monchy I et al. (2013). Retinal vasculitis revealing immunoglobulin G subclass deficiency. *Ocul Immunol Inflamm* 21: 84–86.
- Haupt CL, Newman NJ (1997). Prolonged Uhthoff phenomenon in sarcoidosis. *Am J Ophthalmol* 124: 564–566.
- Haynes BF, Fishman ML, Fauci AS et al. (1977). The ocular manifestations of Wegener's granulomatosis. Fifteen years experience and review of the literature. *Am J Med* 63: 131–141.
- Heckenlively JR, Ferreyra HA (2008). Autoimmune retinopathy: a review and summary. *Semin Immunopathol* 30: 127–134.
- Heyman B (2000). Regulation of antibody responses via antibodies, complement, and Fc receptors. *Annu Rev Immunol* 18: 709–737.
- Holmes G (1945). “Ferrier lecture: the organization of the visual cortex in man”. *Proceedings of the Royal Society of London. Series B, Biological Sciences* 132: 348–361.
- Hubel DH, Wiesel TN (1977). Ferrier lecture. Functional architecture of macaque monkey visual cortex. *Proc R Soc Lond B Biol Sci* 198: 1–59.
- Hutchinson CH (1984). Polyarteritis nodosa presenting as posterior ischaemic optic neuropathy. *J R Soc Med* 77: 1043–1046.
- Ihanamäki T, Seppänen M, Tiainen M et al. (2004). Echovirus type 4 as a probable cause of meningitis associated with bilateral optic neuritis: a case report. *Clin Infect Dis* 38: e49–e51.
- Inoue YK, Nishibe Y, Melnick JL (1984). Classification of Inoue–Melnick virus into three antigenic types. *J Clin Microbiol* 20: 118–119.
- Jansen JCG, Van Calster J, Pulido JS et al. (2015). Early diagnosis and successful treatment of paraneoplastic melanocytic proliferation. *Br J Ophthalmol*. in press.
- Jarius S, Wildemann B (2012). The case of the Marquis de Causan (1804): an early account of visual loss associated with spinal cord inflammation. *J Neurol* 259: 1354–1357.
- Jarius S, Ruprecht K, Wildemann B et al. (2012). Contrasting disease patterns in seropositive and seronegative neuromyelitis optica: a multicentre study of 175 patients. *J Neuroinflammation* 9: 14.
- Jonas JB, Schmidt AM, Müller-Bergh JA et al. (1992). Human optic nerve fiber count and optic disc size. *Invest Ophthalmol Vis Sci* 33: 2012–2018.
- Karma A, Seppälä I, Mikkilä H et al. (1995). Diagnosis and clinical characteristics of ocular Lyme borreliosis. *Am J Ophthalmol* 119: 127–135.
- Kaposi M (1872). Idiopathisches multiples Pigmentsarkom der Haut. *Arch Dermatol Syph* 4: 265–273.
- Kassiri K, Nathoo N, El-Hakim H et al. (2010). Parainfectious optic neuropathy in a young patient with group A *Streptococcus pyogenes* orbital cellulitis. *Can J Ophthalmol* 45: 411–412.
- Keil G (2002). Roger Frugardi und die Tradition langobardischer Chirurgie. *Sudhoffs Arch* 1–26.
- Keltner J, Thirkill C, Yip P (2001). Clinical and immunologic characteristics of melanoma-associated retinopathy syndrome: 11 new cases and a review of 51 previously published cases. *J Neuroophthalmol* 21: 173–187.
- Khairallah M, Ben Yahia S, Toumi A et al. (2009). Ocular manifestations associated with murine typhus. *Br J Ophthalmol* 93: 938–942.
- Khanna S, Sharma A, Huecker J et al. (2012). Magnetic resonance imaging of optic neuritis in patients with neuromyelitis optica versus multiple sclerosis. *J Neuroophthalmol* 32: 216–220.
- Kidd D, Beynon HLC (2003). The neurological complications of systemic sarcoidosis. *Sarcoidosis Vasc Diffuse Lung Dis* 20: 85–94.
- Kidd D, Burton B, Plant G et al. (2003). Chronic relapsing inflammatory optic neuropathy (CRION). *Brain* 126: 276–284.
- Kitley J, Waters P, Woodhall M et al. (2014). Neuromyelitis optica spectrum disorders with aquaporin-4 and myelin-oligodendrocyte glycoprotein antibodies: a comparative study. *JAMA Neurol* 71: 276–283.
- Klinkhoff A, Beattie C, Chalmers A (1986). Retinopathy in systemic lupus erythematosus: relationship to disease activity. *Arthritis Rheum* 29: 1152–1156.
- Koestinger A, Guex-Crosier Y, Borruat F-X (2006). Autoimmune retinal dysfunction in sarcoid chorioretinopathy. *Klin Monbl Augenheilkd* 223: 428–430.
- Kullmann DM (2010). Neurological channelopathies. *Annu Rev Neurosci* 33: 151–172.
- Kupersmith MJ, Martin V, Heller G et al. (2004). Idiopathic hypertrophic pachymeningitis. *Neurology* 62: 686–694.
- Lee MS, Goslee TE, Lessell S (2003). Ehrlichiosis optic neuritis. *Am J Ophthalmol* 135: 412–413.
- Lennon VA, Wingerchuk DM, Kryzer TJ et al. (2004). A serum autoantibody marker of neuromyelitis optica: distinction from multiple sclerosis. *Lancet* 364: 2106–2112.
- Lennon VA, Kryzer TJ, Pittock SJ et al. (2005). IgG marker of optic-spinal multiple sclerosis binds to the aquaporin-4 water channel. *J Exp Med* 202: 473–477.
- Levitt JM (1941). Boeck's sarcoid with ocular localization: survey of the literature and report of a case. *Arch Ophthalmol* 26: 358–388.
- Liu Y, Magro C, Loewenstein JI et al. (2014). A man with paraneoplastic retinopathy plus small fiber polyneuropathy associated with Waldenström macroglobulinemia (lymphoplasmacytic lymphoma): insights into mechanisms. *Ocul Immunol Inflamm*. in press.
- Lu Y, Jia L, He S et al. (2009). Melanoma-associated retinopathy: a paraneoplastic autoimmune complication. *Arch Ophthalmol* 127: 1572–1580.

- Lucchinetti CF, Guo Y, Popescu BFG et al. (2014). The pathology of an autoimmune astrocytopathy: lessons learned from neuromyelitis optica. *Brain Pathol* 24: 83–97.
- Lynn WA, Lightman S (2004). The eye in systemic infection. *Lancet* 364: 1439–1450.
- Machemer R (1966). On the pathogenesis of the flat malignant melanoma. *Klin Monbl Augenheilkd* 148: 641–652.
- Mahesh G, Giridhar A, Shedbele A et al. (2009). A case of bilateral presumed chikungunya neuroretinitis. *Indian J Ophthalmol* 57: 148–150.
- Mansor AM, Li HK (1995). Cytomegalovirus optic neuritis: characteristics, therapy and survival. *Ophthalmologica* 209: 260–266.
- Martinez-Hernandez E, Sepulveda M, Rostásy K et al. (2015). Antibodies to aquaporin 4, myelin-oligodendrocyte glycoprotein, and the glycine receptor 1 subunit in patients with isolated optic neuritis. *JAMA Neurol* 72: 187–193.
- Masland RH (2001). The fundamental plan of the retina. *Nat Neurosci* 4: 877–886.
- Masland RH (2012). The neuronal organization of the retina. *Neuron* 76: 266–280.
- McClelland C, Zaveri M, Walsh R et al. (2012). Optic perineuritis as the presenting feature of Crohn disease. *J Neuroophthalmol* 32: 345–347.
- Merle H, Olindo S, Jeannin S et al. (2013). Visual field characteristics in neuromyelitis optica in absence of and after one episode of optic neuritis. *Clin Ophthalmol* 7: 1145–1153.
- Miles SL, Niles RM, Pittock S et al. (2012). A factor found in the IgG fraction of serum of patients with paraneoplastic bilateral diffuse uveal melanocytic proliferation causes proliferation of cultured human melanocytes. *Retina* 32: 1959–1966.
- Minton K (2014). Innate immunity: the inside story on complement activation. *Nat Rev Immunol* 14: 61.
- Mizener JB, Kimura AE, Adamus G et al. (1997). Autoimmune retinopathy in the absence of cancer. *Am J Ophthalmol* 123: 607–618.
- Moreno RJ, Weisman J, Waller S (1992). Neuroretinitis: an unusual presentation of ocular toxoplasmosis. *Ann Ophthalmol* 24: 68–70.
- Moulick A, Sarkar BS, Jana A et al. (2013). Systemic sclerosis presenting with simultaneous retinal vasculitis in one eye and optic neuritis in the other along with severe immune haemolytic anaemia. *J Clin Diagn Res* 7: 2978–2980.
- Mrejen S, Khan S, Gallego-Pinazo R et al. (2014). Acute zonal occult outer retinopathy: a classification based on multimodal imaging. *JAMA Ophthalmol*. in press.
- Nakajima H, Hosokawa T, Sugino M et al. (2010). Visual field defects of optic neuritis in neuromyelitis optica compared with multiple sclerosis. *BMC Neurol* 10: 45.
- Nakayama M, Keino H, Okada AA et al. (2012). Enhanced depth imaging optical coherence tomography of the choroid in Vogt–Koyanagi–Harada disease. *Retina* 32: 2061–2069.
- Noel N, Butel N, Le Hoang P et al. (2013). Small vessel involvement in Takayasu’s arteritis. *Autoimmun Rev* 12: 355–362.
- Ogata N, Koike N, Yoshikawa T et al. (2011). Human herpesvirus 6-associated uveitis with optic neuritis diagnosed by multiplex PCR. *Jpn J Ophthalmol* 55: 502–505.
- Ohguro H, Yokoi Y, Ohguro I et al. (2004). Clinical and immunologic aspects of cancer-associated retinopathy. *Am J Ophthalmol* 137: 1117–1119.
- Okanishi T, Enoki H (2012). Transient subcortical high-signal lesions in Kawasaki syndrome. *Pediatr Neurol* 47: 295–298.
- Ong C, Ahmad O, Senanayake S et al. (2010). Optic neuritis associated with Q fever: case report and literature review. *Int J Infect Dis* 14 (Suppl 3): e269–e273.
- Ouakaa-Kchaou A, Gargouri D, Trojet S et al. (2009). Retrobulbar optic neuritis associated with infliximab in a patient with Crohn’s disease. *J Crohns Colitis* 3: 131–133.
- Ozyazgan Y, Ucar D, Hatemi G et al. (2014). Ocular involvement of Behçet’s syndrome: a comprehensive review. *Clin Rev Allergy Immunol*. in press.
- Pan D, Hirose T (2011). Vogt–Koyanagi–Harada syndrome: review of clinical features. *Semin Ophthalmol* 26: 312–315.
- Pathanapitton K, Tesavibul N, Choopong P et al. (2013). Clinical manifestations of cytomegalovirus-associated posterior uveitis and panuveitis in patients without human immunodeficiency virus infection. *JAMA Ophthalmol* 131: 638–645.
- Pazirandeh M, Ziran BH, Khandelwal BK et al. (1988). Relapsing polychondritis and spondyloarthropathies. *J Rheumatol* 15: 630–632.
- Peponis VG, Chatziralli IP, Parikakis EA et al. (2012). Bilateral multifocal chorioretinitis and optic neuritis due to Epstein–Barr virus: a case report. *Case Rep Ophthalmol* 3: 327–332.
- Petzold A (2007). CSF biomarkers for improved prognostic accuracy in acute CNS disease. *Neurol Res* 29: 691–708.
- Petzold A (2013). Intrathecal oligoclonal IgG synthesis in multiple sclerosis. *J Neuroimmunol* 262: 1–10.
- Petzold A (2015). Glial fibrillary acidic protein is a body fluid biomarker for glial pathology in human disease. *Brain Res* 1600: 17–31.
- Petzold A, Pitz E (2009). The historical origin of the Pulfrich effect: a serendipitous astronomical observation at the border of the Milky Way. *Neuro-ophthalmology* 33: 39–46.
- Petzold A, Plant G (2005). Central and paracentral visual field defects and driving abilities. *Ophthalmologica* 219: 191–201.
- Petzold A, Plant GT (2014a). Chronic relapsing inflammatory optic neuropathy: a systematic review of 122 cases reported. *J Neurol* 261: 17–26.
- Petzold A, Plant GT (2014b). Diagnosis and classification of autoimmune optic neuropathy. *Autoimmun Rev* 13: 539–545.
- Petzold A, Islam N, Hu H-H et al. (2013a). Embolic and nonembolic transient monocular visual field loss: a clinicopathologic review. *Surv Ophthalmol* 58: 42–62.
- Petzold A, Islam N, Plant GT (2013b). Patterns of non-embolic transient monocular visual field loss. *J Neurol* 1889–1900.
- Petzold A, Wattjes MP, Costello F et al. (2014). The investigation of acute optic neuritis: a review and proposed protocol. *Nat Rev Neurol* 10: 447–458.
- Pittock SJ, Lucchinetti CF (2015). Neuromyelitis optica and the evolving spectrum of autoimmune aquaporin-4 channelopathies: a decade later. *Ann N Y Acad Sci*. in press.

- Pitcock SJ, Lennon VA, de Seze J et al. (2008). Neuromyelitis optica and non organ-specific autoimmunity. *Arch Neurol* 65: 78–83.
- Plant GT, Sibtain NA, Thomas D (2011). Hyperacute corticosteroid treatment of optic neuritis at the onset of pain may prevent visual loss: a case series. *Mult Scler Int* 2011: 815068.
- Pokroy R, Modi G, Saffer D (2001). Optic neuritis in an urban black African community. *Eye* 15: 469–473.
- Prabha N, Mahajan VK, Sharma SK et al. (2013). Optic nerve involvement in a borderline lepromatous leprosy patient on multidrug therapy. *Lepr Rev* 84: 316–321.
- Prasad S, Galetta SL (2011). Anatomy and physiology of the afferent visual system. *Handb Clin Neurol* 102: 3–19.
- Preechawat P, Poonyathalang A (2005). Bilateral optic neuritis after dengue viral infection. *J Neuroophthalmol* 25: 51–52.
- Rahimy E, Sarraf D (2013). Paraneoplastic and non-paraneoplastic retinopathy and optic neuropathy: evaluation and management. *Surv Ophthalmol* 58: 430–458.
- Rao NA, Gupta A, Dustin L et al. (2010). Frequency of distinguishing clinical features in Vogt–Koyanagi–Harada disease. *Ophthalmology* 117: 591–599. 599.e1.
- Raus P, Stalmans P, Demeuter E et al. (2001). Unusual retinal vasculitis in a patient with protein S deficiency and systemic toxoplasmosis: a case report. *Bull Soc Belge Ophthalmol* 7–12.
- Reindl M, Di Pauli F, Rostásy K et al. (2013). The spectrum of MOG autoantibody-associated demyelinating diseases. *Nat Rev Neurol* 9: 455–461.
- Riordan-Eva P, Sanders MD, Govan GG et al. (1995). The clinical features of Leber’s hereditary optic neuropathy defined by the presence of a pathogenic mitochondrial DNA mutation. *Brain* 118: 319–337.
- Ripps H, Carr R, Siegel I et al. (1984). Functional abnormalities in vincristine-induced night blindness. *Invest Ophthalmol* 25: 787–794.
- Romero M, Sánchez F, Fernández-Bolaños R et al. (1999). Optic neuritis as a clinical manifestation of neurobrucellosis. *Rev Neurol* 28: 438.
- Saadoun S, Waters P, Bell BA et al. (2010). Intra-cerebral injection of neuromyelitis optica immunoglobulin G and human complement produces neuromyelitis optica lesions in mice. *Brain* 133: 349–361.
- Sagui E, Chazalon E, Bregigeon M et al. (2007). Optic neuritis attributable to *Mycoplasma pneumoniae*. *Rev Neurol (Paris)* 163: 1103–1105.
- Sato DK, Callegaro D, Lana-Peixoto MA et al. (2014). Distinction between MOG antibody-positive and AQP4 antibody-positive NMO spectrum disorders. *Neurology* 82: 474–481.
- Sawyer R, Selhorst J, Zimmerman L et al. (1976). Blindness caused by photoreceptor degeneration as a remote effect of cancer. *Am J Ophthalmol* 81: 606–613.
- Scadding JG (1981). The eponymy of sarcoidosis. *J R Soc Med* 74: 147–157.
- Scott IU, Silva-Lepe A, Siatkowski RM (1997). Chiasmal optic neuritis in Lyme disease. *Am J Ophthalmol* 123: 136–138.
- Scott TF, Yandora K, Kunschner LJ et al. (2010). Neurosarcoidosis mimicry of multiple sclerosis: clinical, laboratory, and imaging characteristics. *Neurologist* 16: 386–389.
- Sincich LC, Horton JC (2005). The circuitry of V1 and V2: integration of color, form, and motion. *Annu Rev Neurosci* 28: 303–326.
- Smith PR, Cooper JM, Govan GG et al. (1995). Antibodies to human optic nerve in Leber’s hereditary optic neuropathy. *J Neurol Sci* 130: 134–138.
- Srivastava SP, Nema HV (1963). Optic neuritis in measles. *Br J Ophthalmol* 47: 180–181.
- Srivastava R, Aslam M, Kalluri SR et al. (2012). Potassium channel KIR4.1 as an immune target in multiple sclerosis. *N Engl J Med* 367: 115–123.
- Stadtbäumer K, Leschnik MW, Nell B (2004). Tick-borne encephalitis virus as a possible cause of optic neuritis in a dog. *Vet Ophthalmol* 7: 271–277.
- Stangel M, Fredrikson S, Meinl E et al. (2013). The utility of cerebrospinal fluid analysis in patients with multiple sclerosis. *Nat Rev Neurol* 267–276.
- Sterling P (1999). Deciphering the retina’s wiring diagram. *Nat Neurosci* 2: 851–853.
- Stewart MW (2012). Human immunodeficiency virus and its effects on the visual system. *Infect Dis Rep* 4: e25.
- Stich O, Murek C, Rasiah C et al. (2011). Screening for well-characterized paraneoplastic antineuronal antibodies in multiple sclerosis. *Int J Neurosci* 121: 477–479.
- Storoni M, Davagnanam I, Radon M et al. (2013). Distinguishing optic neuritis in neuromyelitis optica spectrum disease from multiple sclerosis: a novel magnetic resonance imaging scoring system. *J Neuroophthalmol* 33: 123–127.
- Stübgen J-P (2013). A literature review on optic neuritis following vaccination against virus infections. *Autoimmun Rev* 12: 990–997.
- Suvajac G, Stojanovich L, Milenkovich S (2007). Ocular manifestations in antiphospholipid syndrome. *Autoimmun Rev* 6: 409–414.
- Sweeney BJ, Manji H, Gilson RJ et al. (1993). Optic neuritis and HIV-1 infection. *J Neurol Neurosurg Psychiatry* 56: 705–707.
- Täger FM, Jahnsen KJ, Mediavilla RM et al. (2008). Ocular bartonellosis: report of three clinical cases. *Rev Chilena Infectol* 25: 58–63.
- Tong F (2003). Primary visual cortex and visual awareness. *Nat Rev Neurosci* 4: 219–229.
- Tran THC, Milea D, Cassoux N et al. (2005). Optic neuritis associated with infliximab. *J Fr Ophthalmol* 28: 201–204.
- Tristano AG (2010). Neurological adverse events associated with anti-tumor necrosis factor α treatment. *J Neurol* 257: 1421–1431.
- Tung C, Hashemi N, Lee AG (2013). Spontaneous resolution of optic perineuritis. *J Neuroophthalmol* 33: 93–95.
- Vaphiades M, Brown H, Whitcup S (2000). Node way out. *Surv Ophthalmol* 45: 77–83.
- Vincent A, Lang B, Kleopa KA (2006). Autoimmune channelopathies and related neurological disorders. *Neuron* 52: 123–138.
- Vishwanath S, Badami K, Sriprakash KS et al. (2013). Post-fever retinitis: a single center experience from south India. *Int Ophthalmol*. in press.

- Vital Durand D, Gérard A, Rousset H (2002). Neurological manifestations of Whipple disease. *Rev Neurol (Paris)* 158: 988–992.
- Wacker J, Handschu R, Manger B et al. (2009). Sudden visual loss in a patient with microscopic polyangiitis. *Rheumatology (Oxford)* 48: 1173–1174.
- Waters PJ, McKeon A, Leite MI et al. (2012). Serologic diagnosis of NMO: a multicenter comparison of aquaporin-4-IgG assays. *Neurology* 78: 665–671.
- Waters P, Woodhall M, O'Connor KC et al. (2015). MOG cell-based assay detects non-MS patients with inflammatory neurologic disease. *Neurol Neuroimmunol Neuroinflammation* 2: e89.
- Weinstein J, Kelman S, Bresnick G et al. (1994). Paraneoplastic retinopathy associated with antiretinal bipolar cell antibodies in cutaneous malignant melanoma. *Ophthalmology* 101: 1236–1243.
- Weissert R, Kuhle J, de Graaf KL et al. (2002). High immunogenicity of intracellular myelin oligodendrocyte glycoprotein epitopes. *J Immunol* 169: 548–556.
- Wen Y-K, Yang Y, Chang C-C (2005). Cerebral vasculitis and intracerebral hemorrhage in Henoch–Schönlein purpura treated with plasmapheresis. *Pediatr Nephrol* 20: 223–225.
- Wenkel H, Rummelt V, Fleckenstein B et al. (1998). Detection of varicella zoster virus DNA and viral antigen in human eyes after herpes zoster ophthalmicus. *Ophthalmology* 105: 1323–1330.
- Westheimer G (2009). Visual acuity: information theory, retinal image structure and resolution thresholds. *Prog Retin Eye Res* 28: 178–186.
- Wingerchuk DM, Hogancamp WF, O'Brien PC et al. (1999). The clinical course of neuromyelitis optica (Devic's syndrome). *Neurology* 53: 1107–1114.
- Yau TH, Rivera-Velazquez PM, Mark AS et al. (1996). Unilateral optic neuritis caused by *Histoplasma capsulatum* in a patient with the acquired immunodeficiency syndrome. *Am J Ophthalmol* 121: 324–326.
- Yip VC-H, Sanjay S, Koh YT (2012). Ophthalmic complications of dengue fever: a systematic review. *Ophthalmol Ther* 1: 2.
- Zhu L-P, Lu H, Yan R et al. (2012). Clinical study of optic neuritis combined with viral hepatitis. *Zhonghua Yan Ke Za Zhi* 48: 428–431.