

The diagnostic utility of ultrasound elastography to differentiate tuberculosis and sarcoidosis during endobronchial ultrasound-guided transbronchial needle aspiration (EBUS-TBNA)

Manu Madan¹, Saurabh Mittal¹, Pawan Tiwari¹, Vijay Hadda¹, Anant Mohan¹, Randeep Guleria¹, Ravindra M Pandey², Karan Madan¹

¹Department of Pulmonary, Critical Care and Sleep Medicine, All India Institute of Medical Sciences, New Delhi, India,

²Department of Biostatistics, All India Institute of Medical Sciences, New Delhi, India

ABSTRACT

Introduction: Elastography is a non-invasive tool that may allow differentiation between benign and malignant lymph nodes during endobronchial ultrasound-guided transbronchial needle aspiration (EBUS-TBNA). In tuberculosis (TB) endemic areas, clinicoradiological features of mediastinal TB and sarcoidosis often overlap, rendering an accurate diagnosis challenging. There is interest in the identification of modalities to aid in this differentiation. There are currently no published data on the utility of EBUS-elastography in differentiating between TB and sarcoidosis. **Methods:** Subjects undergoing EBUS-TBNA were prospectively enrolled, and elastography features were observed. Subjects with definitive diagnosis of TB or sarcoidosis were enrolled. The elastography features recorded included the three-colour classification patterns and strain ratio. **Results:** We enrolled 96 subjects with a definitive diagnosis (53 with TB and 43 with sarcoidosis). Of the 27 patients in whom the lymph nodes were classified as type 1 on endobronchial ultrasound elastography colour pattern, 17 had a diagnosis of TB (62.9%), while 10 were sarcoidosis (37%). For type 2 lymph nodes, 20/45 (44.4%) were TB and 25/45 (55.6%) were sarcoidosis. Type 3 lymph nodes were TB in 16/24 (66.7%) and sarcoidosis in 8/24 (33.3%). In classifying type 1 as 'sarcoidosis' and Type 3 as 'tubercular', the sensitivity, specificity, positive predictive value (PPV), negative predictive value (NPV), and diagnostic accuracy were 48.5%, 55.6%, 66.7%, 37%, and 0.51, respectively. The strain ratio (Median [IQR]) was 1.29 (0.37–5.98) in TB and 2.10 (0.83–4.52) in sarcoidosis group ($P = 0.48$). **Conclusion:** Ultrasound elastographic lymph node characteristics have a poor diagnostic utility to differentiate between TB and sarcoidosis during EBUS-TBNA.

KEY WORDS: EBUS-TBNA, elastography, lymph node, mediastinum, sarcoidosis, tuberculosis

Address for correspondence: Dr. Karan Madan, Department of Pulmonary, Critical Care and Sleep Medicine, All India Institute of Medical Sciences, New Delhi, India.

E-mail: drkaranmadan@gmail.com

Submitted: 20-Apr-2022

Revised: 10-Aug-2022

Accepted: 15-Aug-2022

Published: 25-Oct-2022

This is an open access journal, and articles are distributed under the terms of the Creative Commons Attribution-NonCommercial-ShareAlike 4.0 License, which allows others to remix, tweak, and build upon the work non-commercially, as long as appropriate credit is given and the new creations are licensed under the identical terms.

For reprints contact: WKHLRPMedknow_reprints@wolterskluwer.com

How to cite this article: Madan M, Mittal S, Tiwari P, Hadda V, Mohan A, Guleria R, *et al.* The diagnostic utility of ultrasound elastography to differentiate tuberculosis and sarcoidosis during endobronchial ultrasound-guided transbronchial needle aspiration (EBUS-TBNA). *Lung India* 2022;39:532-6.

Access this article online	
Quick Response Code: 	Website: www.lungindia.com
	DOI: 10.4103/lungindia.lungindia_214_22

INTRODUCTION

Endobronchial ultrasound-guided transbronchial needle aspiration (EBUS-TBNA) is a minimally invasive modality to sample mediastinal lymph nodes or masses in adults and children.^[1-3] The EBUS bronchoscope has an ultrasonographic transducer at its distal end, giving real-time sonographic imaging, which aids in sampling the peribronchial and mediastinal lesions. Before mediastinal lymph node puncture, the operator can observe various ultrasonographic lymph node characteristics.^[4,5]

Multiple studies have described the utility of the ultrasonographic lymph node characteristics in differentiating various disease conditions. The majority of literature exists on the differentiation between malignant and benign lymph nodes.^[6] Based on sonographic features, few studies have focused on the differentiation between tuberculosis (TB) and sarcoidosis.^[7,8] In one study, heterogeneous echotexture and coagulation necrosis signs were significantly more common in TB than in sarcoidosis patients.^[7] Still, an assessment of ultrasonographic features does not preclude the requirement of mediastinal lymph node aspiration.

Ultrasound elastography is a non-invasive modality that indicates a tissue's hardness.^[9] The output is a coloured image with colour patterns depending on the area's hardness characteristics. The blue colour indicates a stiffer tissue than a green colour. Quantitative estimation of hardness is also possible by various methods, and many elastographic patterns have been studied.^[10] The most commonly reported methods include the qualitative three-colour classification method and the quantitative strain ratio method.^[9,11] Elastography may help differentiate malignant and benign lymph nodes, and among the available elastography assessment methods, the three-color classification method may be preferable.^[10]

A review of the available literature indicates a lack of published data on the role of elastographic lymph node features in differentiating TB and sarcoidosis. Differentiation of TB from sarcoidosis is often challenging, especially when microbiological investigations for TB are negative. The clinical, radiological, and histopathological often overlap. A large cohort study of sarcoidosis from a TB endemic setting reported tuberculin positivity in 10.1% and necrotizing granulomatous inflammation in 13.5% of patients.^[12] This highlights the challenges in differentiating TB from sarcoidosis and the need for methods to aid in this.

We hypothesized that elastography features may help differentiate between TB and sarcoidosis in patients undergoing EBUS-TBNA. The objectives were to compare the diagnostic sensitivity and specificity of various elastography characteristics to aid in this differentiation. This study compared elastography lymph

node characteristics between subjects diagnosed with TB and sarcoidosis related mediastinal lymphadenopathy.

METHODS

The study was a prospective observational study conducted in a large tertiary care and referral facility. Elastographic findings of consecutive patients with suspected clinical diagnosis of TB or sarcoidosis mediastinal lymph nodes undergoing EBUS-TBNA in our centre were recorded by blinded investigators. Subjects with a definitive diagnosis of TB or sarcoidosis mediastinal lymphadenopathy on EBUS-TBNA were included in the study. Informed consent to participate in the study was obtained. The institute ethics committee approved the study protocol. Study was performed during the period between January 2019 and October 2020.

EBUS-TBNA was performed in the bronchoscopy suite using the Olympus BF-UC-180-F bronchoscope with EU-ME2 ultrasound processor systems. Most procedures were performed through the oral route under moderate, proceduralist-directed sedation. 10% Lignocaine spray was applied to the pharynx. Topical anaesthesia to the vocal cords and the tracheobronchial tree was achieved using either a spray-as-you-go technique or cricothyroid injection of lignocaine solution. Both 21 Gauge and 22 Gauge needles were used. Rapid On-site evaluation (ROSE) was performed for most procedures, either by a cytopathologist or a pulmonologist. Glass slide-fixed smears were prepared, and cell blocks were also processed. Aspirates were also processed for microbiological investigations, including AFB smears, Xpert Mtb-RIF test, and Mycobacterial liquid cultures. A diagnosis of tuberculosis was made if any microbiological investigation for TB was positive or if the cytopathological examination showed necrotizing granulomatous inflammation and a compatible clinico-radiological profile. (The compatible clinico-radiological profile refers to the presence of any or more of the features such as necrotic lymph nodes on CT, a reactive tuberculin skin test, presence of fever/constitutional symptoms, and lack of classical CT parenchymal lung features to support sarcoidosis. In all these patients, the diagnosis on follow-up (response to antitubercular treatment) was taken as the final diagnosis.) Sarcoidosis was diagnosed when the cytopathological analysis of the aspirates demonstrated non-necrotizing granulomas with consistent clinico-radiological profiles and no microbiological evidence of tuberculosis.

After EBUS bronchoscope introduction through the trachea, a gentle contact was made with the tracheobronchial wall, and elastographic features were evaluated. Elastography analysis was performed using both qualitative and quantitative methods. The most commonly described three-color classification method (Izumo classification) was used for qualitative

analysis. According to Izumo classification,^[9] the type 1 colour pattern was referred to as a lymph node that was predominantly green, type 2 as the one which was part blue-part green. In contrast, type 3 was the one that showed a mostly blue pattern, indicating a harder node. For quantitative analysis, strain ratio was used, as described by previous studies.^[11] The inbuilt software determines the strain ratio, which computes the strain of two selected areas (A and B). It gives a final ratio of B/A, where A refers to the lymph nodal area in question and B refers to the perinodal, presumably normal area. The procedure videos are regularly maintained in an electronic database at our facility, and the same was reviewed if any additional information was required.

All videos were assessed by two blinded investigators for elastographic classification of lymph nodes, and in cases of discrepancy a third investigator's opinion was sought.

Statistical analysis

The demographic details and ultrasonographic characteristics were recorded in the RedCap data management system. Subjects with complete data on cytopathology, microbiological reports, and elastographic features were included in the analysis. Statistical analyses were performed using the Stata 16 package (StataCorp. 2019. Stata Statistical Software: Release 16. College Station, TX: StataCorp LLC). This was a pilot study and no predetermined sample size calculation was performed. Categorical variables were summarized as numbers (percentages), while quantitative variables as mean (SD) or median (IQR). The Chi-squared test was used to compare categorical variables. Sensitivity, specificity, positive and negative predictive values, diagnostic accuracy, and likelihood ratios were determined.

RESULTS

During the study period, 230 EBUS-TBNA procedures were carried out for suspected TB or sarcoidosis. We enrolled 96 subjects with mediastinal lymphadenopathy with a definite diagnosis following EBUS-TBNA. Of these, 53 patients (55.2%) had a final diagnosis of TB (35 had microbiologically confirmed diagnosis), while 43 (44.7%) were diagnosed with sarcoidosis. The mean age of the cohort was 42.07 (16.05) years. Patients diagnosed with TB were younger (mean age, 39.9 [18.4] years vs 44.7 [12.3] years) compared with sarcoidosis. The baseline characteristics are summarized in Table 1. The mean lymph node diameter (short axis) on the thoracic CT scans of the study population was 16.4 (12.21) mm, with 15.8 (6.65) mm for TB and 17.1 (16.6) mm for sarcoidosis. Heterogenous lymph node appearance on CT scans was more commonly seen in TB (46.2% vs 8.0%). Lymph node calcification on CT scan was also more common in TB (9.8% vs 2.5%). The median number of lymph node stations sampled was 1 (1–3). Most of the procedures were performed under moderate sedation (98.9%).

All of the included subjects underwent ultrasound elastography analysis during EBUS-TBNA. All patients underwent qualitative colour pattern assessment. The lymph nodes that were classified as type 1 on elastography had a diagnosis of TB in 17/27 (62.9%) and sarcoidosis in the remaining 10/27 (37%); for type 2 lymph nodes, 20/45 (44.4%) were TB, and 25/45 (55.6%) were sarcoidosis; type 3 lymph nodes were TB in 16/24 (66.7%) and sarcoidosis in 8/24 (33.3%). The data on the qualitative elastographic characteristics between the two groups are summarized in Table 2. In classifying type 1 as 'sarcoidosis' and type 3 as 'tubercular', the sensitivity, specificity, positive predictive value (PPV), negative predictive value (NPV), and diagnostic accuracy rates were 48.5%, 55.6%, 66.7%, 37%, and 0.51, respectively. Table 3 summarizes the diagnostic yield of various qualitative elastographic analysis parameters to differentiate between sarcoidosis and TB mediastinal lymphadenopathy. The highest accuracy was seen for type 3 vs type 1/2 analysis, with an accuracy of 0.53.

Strain ratio was performed for 91 patients. Amongst these, 50 patients (54.9%) were TB, while 41 (45.1%) had a diagnosis of sarcoidosis. The strain ratio (median [IQR]) was 1.29 (0.37–5.98) in TB and 2.10 (0.83–4.52) in the sarcoidosis group ($P = 0.48$). The optimal cut-off of strain ratio was also determined using the receiver operating characteristic (ROC) curve. At a cut-off of 1.78 from the ROC curve, sensitivity and specificity were 56.1% and 56%, respectively [Figure 1].

DISCUSSION

We have described the utility of elastographic image characteristics of intrathoracic lymph nodes studied during EBUS-TBNA for differentiating between sarcoidosis and

Table 1: Baseline characteristics of the subjects in two groups, tuberculosis and sarcoidosis mediastinal lymphadenopathy

Parameter	Tuberculosis <i>n</i> =53	Sarcoidosis <i>n</i> =43
Age (years), mean (SD)	39.9 (18.4)	44.7 (12.3)
Male, <i>n</i> (%)	24 (45.3%)	23 (53.5%)
CT node short axis diameter (mm), mean (SD)	15.8 (6.65)	17.1 (16.6)
CT node long axis diameter (mm), mean (SD)	17.7 (6.38)	17.5 (5.43)
EBUS node short axis diameter (mm), mean (SD)	15.2 (5.65)	14.4 (4.15)
EBUS node long axis diameter (mm), mean (SD)	18.1 (6.12)	17.8 (4.41)

Table 2: Elastography colour pattern distribution between tuberculosis and sarcoidosis mediastinal lymph nodes

	Tuberculosis <i>n</i> =53	Sarcoidosis <i>n</i> =43
Predominant non-blue (type 1)	17 (32.1%)	10 (23.2%)
Part blue-part non-blue (type 2)	20 (37.7%)	25 (58.1%)
Predominant blue (type 3)	16 (30.2%)	8 (18.6%)

Data is represented as absolute number (percentage)

Table 3: Diagnostic accuracy of various elastography characteristics in differentiating tuberculosis from sarcoidosis nodes

	<i>P</i>	Sensitivity	Specificity	Positive predictive value	Negative predictive value	Positive likelihood ratio	Negative likelihood ratio	Diagnostic odds ratio	Accuracy
Type 3 vs Type 1	0.78	48.5% (30.8-66.5)	55.6% (30.8-78.5)	66.7% (44.7-84.4)	37% (19.4-57.6)	1.09 (0.58-2.04)	0.93 (0.55-1.57)	1.18 (0.38-3.65)	0.51
Type 3 vs Type 1/2	0.19	30.2% (18.3-44.3)	81.4% (66.6-91.6)	66.7% (44.7-84.4)	48.6% (36.7-60.7)	1.62 (0.77-3.43)	0.86 (0.68-1.08)	1.89 (0.73-4.87)	0.53
Type 2/3 vs Type 1	0.33	67.9% (53.7-80.1)	23.3% (11.8-38.6)	52.2% (39.8-64.4)	37% (19.4-57.6)	0.89 (0.69-1.13)	1.38 (0.71-2.69)	0.64 (0.26-1.58)	0.48

() represents 95% confidence interval; comparisons are shown for TB vs sarcoidosis

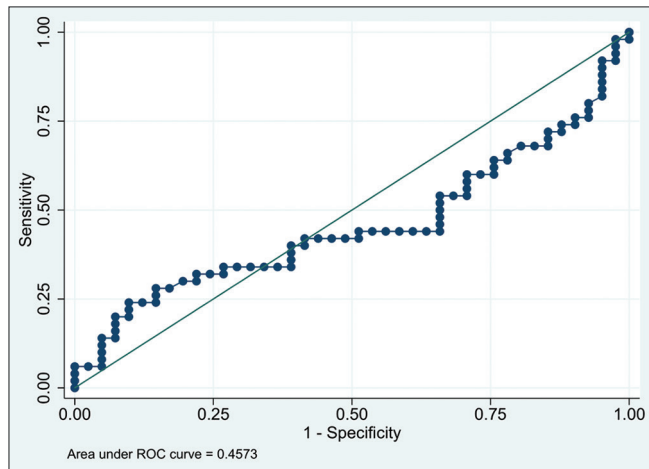


Figure 1: Receiver operator characteristic (ROC) curve of strain ratio to differentiate between sarcoidosis and tuberculosis

TB. This is the first study describing the comparative elastography characteristics of TB and sarcoidosis. The strengths of this study include a rigorous diagnostic algorithm and carefully selected diagnostic categories that prevent overlap with other conditions. The findings of the study are representative of the real-life practice of EBUS-TBNA.

We observed that elastography had poor performance to differentiate TB from sarcoidosis in patients undergoing EBUS-TBNA. Although a type 3 pattern has been found to correlate with a diagnosis of malignant mediastinal lymph nodes, the literature suggests that benign/granulomatous lymph nodes may also demonstrate similar hardness characteristics. In settings where the sarcoidosis lymph node is associated with fibrosis, the elastography appearance may show predominantly blue lymph nodes (type 3).^[13] Trisolini *et al.*^[14] reported that blue lymph nodes might be associated with more inadequate samples during EBUS-TBNA owing to more fibrotic nodes. A reason that we observed no difference between elastography features between TB and sarcoidosis might be contributed by the fact that as we included only those patients who were proven on EBUS-TBNA histo-cytopathology, more fibrotic lymph nodes may have been excluded. However, the results of our study indicate that the qualitative assessment of elastography images or the quantitative method, strain ratio, cannot differentiate between TB and sarcoidosis mediastinal lymphadenopathy.

According to the available literature, ultrasound B mode characteristics may help differentiate TB from sarcoidosis mediastinal lymphadenopathy during EBUS-TBNA. Two studies found coagulation necrosis and heterogenous lymph nodes as predictors of TB.^[7,8] Heterogenous lymph nodes have been shown to have sensitivity, specificity, PPV, and NPV in the range of 59.6%–60.2%, 80.5%–85.5%, 54.9%–69.0%, and 50.2%–83.3%, respectively. Coagulation necrosis sign has shown sensitivity, specificity, PPV, and NPV in the range of 34.0%–42.0%, 82.7%–93.2%, 66.7%–67.6%, and 78.0%–79.0%, respectively. These values seem to be better compared to elastography image results in our study; however, no head-to-head comparison is available, nor a study that combines both ultrasonographic B mode images and elastography analysis.

Our study has limitations. We performed a per-patient analysis rather than a per-node analysis (desirable but not feasible due to the study design). Patients with inadequate histo-cytopathology samples were not included in the calculation. Another limitation is that the observers were not blinded to the patient’s clinical history.

CONCLUSION

Further research is required to improve the diagnostic accuracy of image analysis modalities to differentiate between TB and sarcoidosis. At present, elastography performs poorly to differentiate between TB and sarcoidosis lymph nodes.

Declaration of patient consent

The authors certify that they have obtained all appropriate patient consent forms. In the form the patient(s) has/have given his/her/their consent for his/her/their images and other clinical information to be reported in the journal. The patients understand that their names and initials will not be published and due efforts will be made to conceal their identity, but anonymity cannot be guaranteed.

Author contributions

MM: Study design, data collection, preparation of manuscript draft, manuscript revision.

SM, PT, VH, AM, RG: Study design, manuscript revision.

RMP: Statistical analysis, revised the manuscript.

KM: Conceived the idea, study design, preparation of the manuscript draft, revised the manuscript.

Financial support and sponsorship

Nil.

Conflicts of interest

There are no conflicts of interest.

REFERENCES

- Iyer H, Anand A, Sryma PB, Gupta K, Naranje P, Damle N, *et al.* Mediastinal lymphadenopathy: A practical approach. *Expert Rev Respir Med* 2021;15:1317-34.
- Madan K, Iyer H, Madan NK, Mittal S, Tiwari P, Hadda V, *et al.* Efficacy and safety of EBUS-TBNA and EUS-B-FNA in children: A systematic review and meta-analysis. *Pediatr Pulmonol* 2021;56:23-33.
- Madan K, Mohan A, Ayub, II, Jain D, Hadda V, Khilnani GC, *et al.* Initial experience with endobronchial ultrasound-guided transbronchial needle aspiration (EBUS-TBNA) from a tuberculosis endemic population. *J Bronchology Interv Pulmonol* 2014;21:208-14.
- Ayub, II, Mohan A, Madan K, Hadda V, Jain D, Khilnani GC, *et al.* Identification of specific EBUS sonographic characteristics for predicting benign mediastinal lymph nodes. *Clin Respir J* 2018;12:681-90.
- Fujiwara T, Yasufuku K, Nakajima T, Chiyo M, Yoshida S, Suzuki M, *et al.* The utility of sonographic features during endobronchial ultrasound-guided transbronchial needle aspiration for lymph node staging in patients with lung cancer: A standard endobronchial ultrasound image classification system. *Chest* 2010;138:641-7.
- Hylton DA, Turner J, Shargall Y, Finley C, Agzarian J, Yasufuku K, *et al.* Ultrasonographic characteristics of lymph nodes as predictors of malignancy during endobronchial ultrasound (EBUS): A systematic review. *Lung Cancer (Amsterdam, Netherlands)* 2018;126:97-105.
- Dhooira S, Agarwal R, Aggarwal AN, Bal A, Gupta N, Gupta D. Differentiating tuberculosis from sarcoidosis by sonographic characteristics of lymph nodes on endobronchial ultrasonography: A study of 165 patients. *J Thorac Cardiovasc Surg* 2014;148:662-7.
- Erol S, Anar C, Erer OF, Biçmen C, Aydoğdu Z. The contribution of ultrasonographic characteristics of mediastinal lymph nodes on differential diagnosis of tuberculous lymphadenitis from sarcoidosis. *Tanaffos* 2018;17:250-6.
- Izumo T, Sasada S, Chavez C, Matsumoto Y, Tsuchida T. Endobronchial ultrasound elastography in the diagnosis of mediastinal and hilar lymph nodes. *Jpn J Clin Oncol* 2014;44:956-62.
- Madan K, Madan M, Iyer H, Mittal S, Madan NK, Rath V, *et al.* Utility of elastography for differentiating malignant and benign lymph nodes during EBUS-TBNA: A systematic review and meta-analysis. *J Bronchol Interv Pulmonol* 2022;29:18-33.
- Rozman A, Malovrh MM, Adamic K, Subic T, Kovac V, Flezar M. Endobronchial ultrasound elastography strain ratio for mediastinal lymph node diagnosis. *Radiol Oncol* 2015;49:334-40.
- Madan K, Sryma PB, Pattnaik B, Mittal S, Tiwari P, Hadda V, *et al.* Clinical profile of 327 patients with Sarcoidosis in India: An ambispective cohort study in a tuberculosis (TB) endemic population. *Lung India* 2022;39:51-7.
- Livi V, Cancellieri A, Pirina P, Fois A, van der Heijden E, Trisolini R. Endobronchial ultrasound elastography helps identify fibrotic lymph nodes in sarcoidosis. *Am J Respir Crit Care Med* 2019;199:e24-e5.
- Trisolini R, Verhoeven RLJ, Cancellieri A, De Silvestri A, Natali F, Van der Heijden E. Role of endobronchial ultrasound strain elastography in the identification of fibrotic lymph nodes in Sarcoidosis: A pilot study. *Respirology (Carlton, Vic)* 2020;25:1203-6.