

Bony island within the articular cartilage of the knee in a child: a rare condition for early osteoarthritis

Taku Hatta,¹ Takehiko Sugita,²
Toshimi Aizawa,¹ Masahiro Ohnuma,¹
Atsushi Takahashi,¹ Eiji Itoi¹

¹Department of Orthopaedic Surgery,
Tohoku University School of Medicine,
Sendai; ²Tohoku Orthopaedic Clinic,
Sendai, Japan

Abstract

Articular cartilage is a specific type of connective tissue composed of hydrated proteoglycans within a matrix of collagen fibrils. In the elderly population, it shows degenerative changes that may result in osteoarthritis. The more severe form of osteoarthritis occasionally demonstrates bone formation within the cartilage, which is designated as a bony protuberance, however, such lesions are rare in children. This report presents the case of a 10-year-old boy with a bony protuberance within the articular cartilage of the knee. The patient initially complained of knee pain and he subsequently developed flexion contracture. Radiological and arthroscopic examinations revealed a bony protuberance in the articular cartilage and degenerative changes of the cartilage above it. He was successfully treated by the removal of the bony protuberance and osteochondral grafting. The bony protuberance may have caused cartilage degradation since the thickness of the cartilage above it was thinner than that around the lesion. The bony protuberance within the articular cartilage formed in the younger population may be a possible cause of osteoarthritis. This case is a noteworthy with regard to the pathogenesis of osteoarthritis.

Introduction

The surface of the synovial joint is covered with articular cartilage, which is a specific type of connective tissue composed of hydrated proteoglycans within a matrix of collagen fibrils.¹ Articular cartilage is avascular and it is organized into four zones: the superficial zone, the transitional zone, the deep zone and the calcified cartilage.¹ Articular cartilage is connected to subchondral bone through the calcified cartilage.¹ Normal articular cartilage is only a few millimeters thick but gives synovial

joints the ability to provide low-friction and pain-free motion.² During the aging process, articular cartilage undergoes gradual degenerative changes, that may result in osteoarthritis.

Osteoarthritis of the knee is one of the most common disorders in the orthopedic field. Many articles have discussed its pathogenesis but regrettably, there still exists many unanswered questions. In 1994, Bergman AG. *et al.* first reported two cases histologically showing bone formation within the hyaline cartilage of the knee.³ We designated such a lesion as a bony protuberance and reported five additional cases although all had severe osteoarthritis of the knee joint.⁴ Such lesions are rare in children. This report presents the case of a 10-year-old boy with a bony protuberance within the articular cartilage of the knee and who was successfully treated by the removal of the bony protuberance and osteochondral grafting. We discuss the pathogenesis of the lesion and also the relationship to cartilage degradation. The patient and his family were informed that data from the case would be submitted for publication, and they gave their consent.

Case Report

A 10-year-old boy visited the outpatient clinic with complaints of left knee pain. He could not recall any history of knee injury or any preceding episodes of infection. The radiographs revealed no abnormal findings. His pain disappeared spontaneously but 10 months later, he could not fully extend his left knee and returned to the clinic.

Physical examination revealed a 20° of flexion contracture and pain sensation elicited upon forced extension. There was no pain either upon walking or at rest. In addition, no tenderness and no swelling developed on his left knee joint. No knee instability was detected and McMurray's test was also negative.

Plain radiographs revealed a free-body like bony fragment in the medial compartment of the knee (Figure 1 A,B). MR images revealed an island of low signal intensity with a clear margin in the articular cartilage of the medial femoral condyle on both T1- and T2-weighted images (Figure 2A). The articular cartilage appeared normal and no osteochondral fragment, bone destructive changes in the bone, or even bone edema, suggestive of osteochondritis dissecans (OCD), were detected.^{5,6} Plain radiographs and MR images demonstrated a bony fragment that enlarged in size, which united with medial femoral condyle with the appearance of a bony protuberance 18 months later (Figures 1C,D, 2B).⁴

Arthroscopic examination was performed to examine the pathological condition in the knee joint because his symptoms showed no

Correspondence: Toshimi Aizawa, Department of Orthopaedic Surgery, Tohoku University School of Medicine, 1-1 Seiryomachi, Aoba-ku, Sendai, 980-8574, Japan.

Tel. 81.22.717.7245 - Fax. 81.22.717.7248.

E-mail: toshi-7@ra2.so-net.ne.jp

Key words: bone protuberance, articular cartilage, osteoarthritis, child.

Contribution: TH, study conception and design, manuscript revision; TS, TA, study conception and design, manuscript revision and final approval; MO, AT, study conception and design; EI, manuscript final approval.

Conflict of interest: the authors report no conflicts of interest.

Received for publication: 28 December 2010.

Revision received: 21 March 2011.

Accepted for publication: 21 March 2011.

This work is licensed under a Creative Commons Attribution 3.0 License (by-nc 3.0).

©Copyright T. Hatta *et al.*, 2011

Licensee PAGEPress, Italy

Orthopedic Reviews 2011; 3:e7

doi:10.4081/or.2011.e7

improvement with conservative treatment. The surface of the articular cartilage above the bony protuberance was confirmed using an image intensifier, which revealed softening and fibrillation, and was spongy upon palpation (Figure 3). No other abnormal findings such as synovitis, or impingement of the articular surface against the meniscus or facing articular surface were found. The bony protuberance⁴ and the articular cartilage above it were the only pathological lesions and were thus considered to be the cause of flexion contracture. A cylindrical osteochondral plug (8 mm in diameter) including the bony protuberance⁴ was removed and an osteochondral plug (9 mm in diameter) obtained from the medial femoral trochlea was grafted into the lesions using the osteochondral autograft transfer system (OATS, Arthrex, Naples, FL, USA).

The patient's knee was supported by a knee brace and a continuous passive motion was initiated the day after the surgery. Partial weight bearing was permitted after 8 weeks and he could walk without any support at 12 weeks after the surgery. The patient experienced no knee pain soon after surgery. Flexion contracture was improved gradually by strenuous course of passive motion exercises and he achieved a full range of motion 10 months later. He could thereafter participate in all sport activities without restriction. MR images revealed a well-reconstructed articular cartilage 10 years after surgery (Figure 4).

The harvested osteochondral plug was ana-

lyzed histologically (Figure 5). The bony protuberance⁴ protruded into the articular cartilage with normal trabeculae. The articular cartilage above the bony protuberance⁴ was thin and with surface fibrillations and chondrocytes forming clusters at the osteochondral junction, indicating degenerative changes in the articular cartilage. Fibrous tissue filled the cleft of the articular cartilage. Many osteoblasts and osteoclasts were found around the trabeculae beneath the cleft, which suggested active bone remodelling occurred beneath the cleft. There were also regions with hypertrophic subchondral trabeculae. No cleft separating the harvested specimens like OCD was detected at osteochondral junction.⁷

Discussion

A couple of reports of the bony protuberance within the articular cartilage have been published.^{3,4} It is usually detected in the severe degenerative cartilage harvested during joint replacement surgery. Bergman *et al.* histopathologically examined nine osteoarthritic patients, where bone formation within the hyaline cartilage layer was observed in two cases.³ We also assessed the lateral tibial plateau in 24 varus osteoarthritic patients of which five contained a bony protuberance.⁴ However, this lesion is considered to be rare in children. Articular cartilage undergoes gradual degenerative changes during the aging

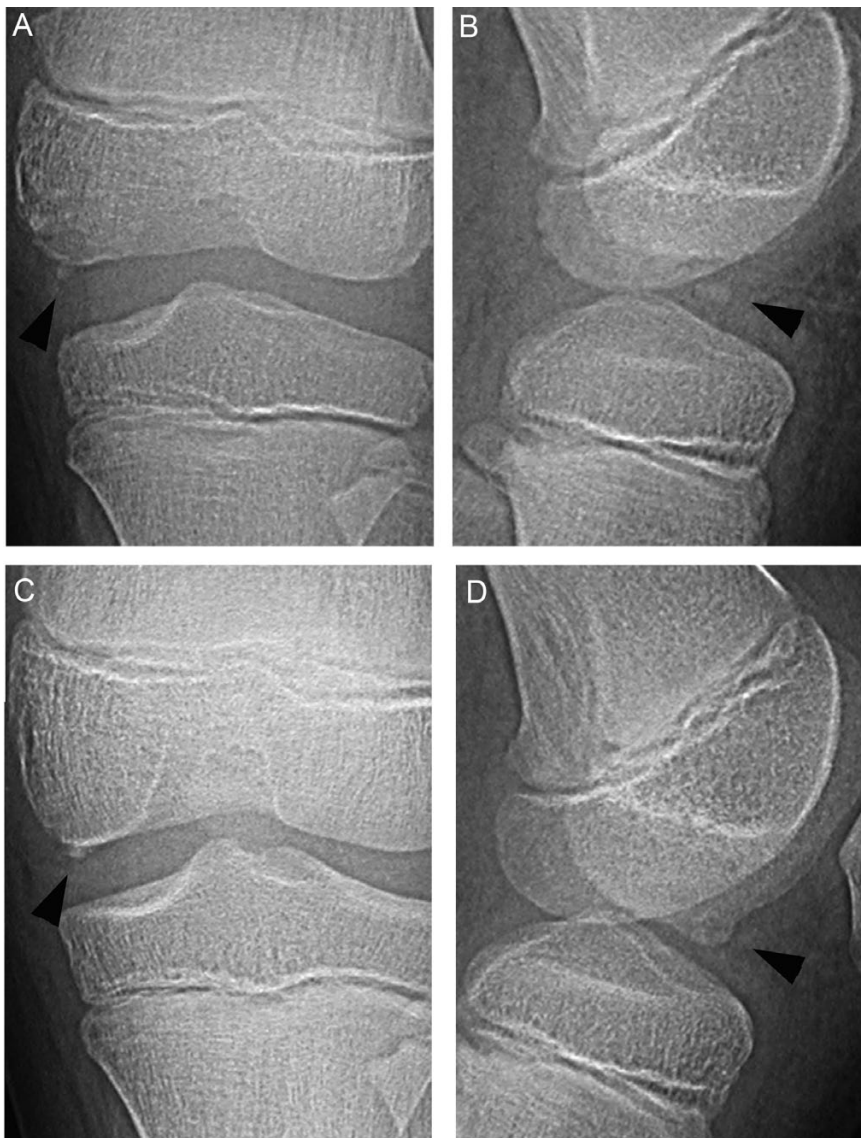


Figure 1. Plain radiographs of the left knee. (A) an anteroposterior view, (B) a lateral view. (A,B) At the 2nd visit to our outpatient clinic a free-body like bony fragment is detected in the medial compartment of the left knee (arrowheads). (C,D) 18 months after Figure 1A, the bony fragment detected is united with medial femoral condyle just like a bone protuberance (arrowheads).

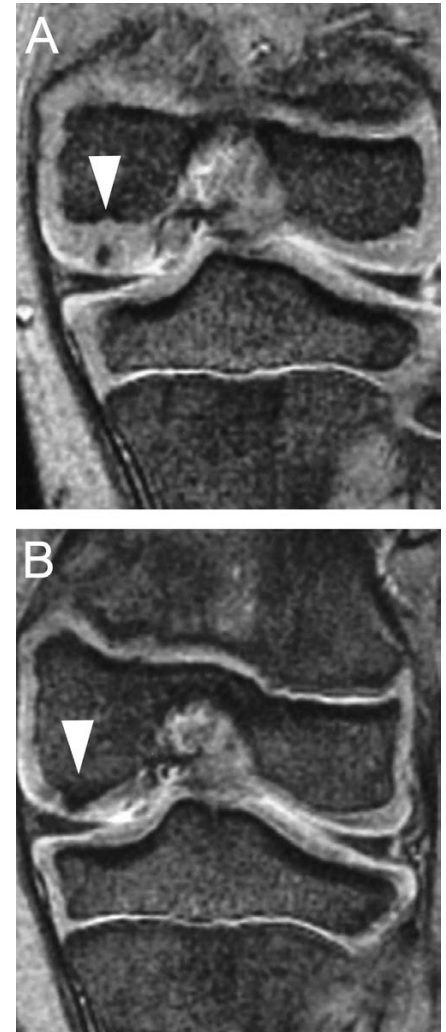


Figure 2. Coronal plain T2-weighted magnetic resonance imaging of the left knee. (A) At the 2nd visit to our outpatient clinic, a low signal intensity spot is detected within the articular cartilage (white arrowhead). (B) 18 months after Figure 2-A, the low signal intensity spot is united with medial femoral condyle (white arrowhead).

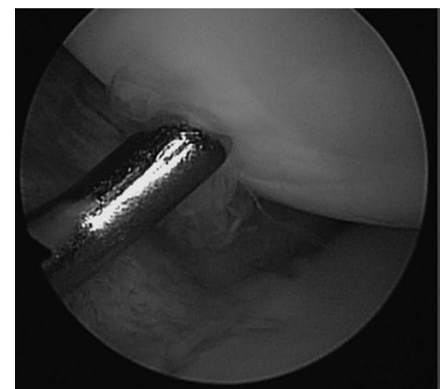


Figure 3. An arthroscopic examination reveals that the surface of the articular cartilage above the bony protuberance is fibrillated and slightly depressed.

process. Younger populations usually have normal articular cartilage with a smooth and intact surface. However, in the present case, the arthroscopic examination revealed softening and fibrillation of the surface of the articular cartilage above the bony protuberance.⁴ The histological findings in this lesion also demonstrated degenerative changes in the articular cartilage, which are rare in a 10-year-old child with no history of obvious trauma and were probably associated with the bony protuberance⁴ within the articular cartilage. The thickness of the cartilage above the protuberance was thinner than that around the lesion, which may be related to those degenerative changes.

What is the etiology of the bony protuberance⁴ within the articular cartilage? Bone formation by endochondral ossification in the articular cartilage would require a blood supply.^{8,9} The patient did not recall any history of trauma or infection, but a cleft filled with fibrous tissues in the articular cartilage suggested that the subchondral bone plate was damaged possibly by minor traumas with vessels subsequently invading into the articular cartilage. Bone formation may have been undersized initially like an island within the cartilage, but it enlarged and attached to the subchondral bone.

OCD is considered as one of the differential diagnosis. In OCD lesions, the articular cartilage is usually intact and the subchondral area is mainly affected.⁷ However, in the present case, the newly formed bone was detected within the degenerative articular cartilage. Moreover, the characteristic cleft revealed in the histological examination of OCD, which separated the affected area into basal- and fragment-side parts, was not demonstrated.⁷ A very early stage in the localized form of Trevor's disease (dysplasia epiphysealis hemimelica) may also be considered as another differential diagnosis.^{10,11} This condition is characterized by single or multiple ossification centers arising from the epiphysis, asymmetrical overgrowth on one side of an epiphysis with irregular or premature calcification, and osteochondroma-like histology.^{11,12} In the present case, plain radiographs and MR images revealed no asymmetry of the epiphysis in the distal femur and the histology was unlike that of osteochondroma. Therefore, the present case was thought to be neither OCD nor Trevor's disease.

A fibrotic change in the joint capsule, which usually occurs after trauma, infection, surgery, or immobilization, is the main causes of joint contracture.¹³ However, there was no apparent history of any such events in this case. In addition, the patient complained of knee pain only at the beginning of the disease process. Therefore, the exact cause of the flexion contracture of the knee was uncertain. The bony protuberance⁴ was a possible explanation. Its

presence strongly suggested the occurrence of some minor traumas preceding the bony lesion, which may have caused the pain. Subsequent self-immobilization by the patient himself in order to reduce the pain in addition to the direct damage of the joint capsule by the minor trauma may have resulted in fibrotic change to the joint capsule.¹³

The present case was surgically treated by the removal of the bony protuberance⁴ and osteochondral grafting since no other pathological lesions could be detected either by radiological or arthroscopical examination. This treatment was justified because the possible cause of cartilage degeneration was removed, and new articular surface was reconstructed. Fortunately, flexion contracture, his chief complaint, was improved by this treatment and also by a strenuous course of passive motion exercises. A well-reconstructed articular cartilage was observed 10-year postoperatively.

Recently, the pathogenesis of osteoarthritis has been clarified based on the findings from biomechanical, epidemiological, and molecular biological studies.¹⁴⁻¹⁸ In the elderly population, chondrocyte changes and cartilage degradation caused by mechanical stress and proteinases may be important in the pathogenesis of osteoarthritis.¹⁸ In addition, as we clearly demonstrated in the present case, a bony protuberance⁴ within the articular cartilage in the younger population occurred following trauma or infection, which can also lead to cartilage degradation. This may be one of the possible causes of osteoarthritis.

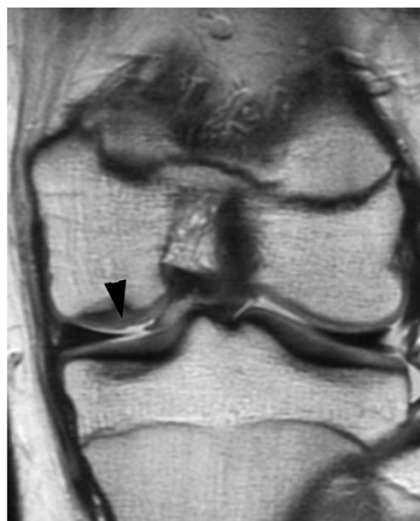

Figure 4. Coronal plain T2-weighted magnetic resonance imaging of the left knee at 10 years after the osteochondral plug autograft demonstrates the surface of the medial condyle is covered with well-reconstructed articular cartilage (arrowhead).

Conclusions

We reported the case of a 10-year-old boy with a bony protuberance⁴ within the articular cartilage of the knee joint. Arthroscopic and

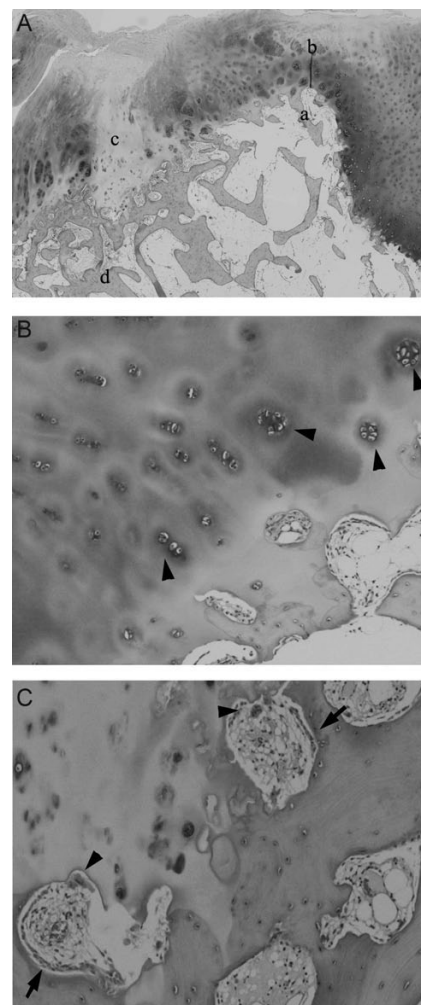


Figure 5. Histological findings of the removed osteochondral plug. (A) Low magnification photograph around the bone protuberance. Bony protuberance protrudes into the articular cartilage. The articular cartilage over the protuberance is thinned and there is a cleft in the articular cartilage filled with fibrous tissue. There are also regions with hypertrophic subchondral trabeculae. (Hematoxylin-eosin staining. The original magnification is 15 \times). (B) High magnification photograph at the osteochondral junction. There are many cluster formations of the articular chondrocytes (arrowheads). (Hematoxylin-eosin staining. The original magnification is 100 \times). (C) High magnification photograph at the trabecule bone beneath the cleft within the articular cartilage. Osteoblasts (arrows) and osteoclasts (arrowheads) are detected around the trabeculae suggesting that active bone remodelling beneath the cleft. (Hematoxylin-eosin staining. The original magnification is 100 \times).

histological findings of the articular cartilage suggest that this lesion in younger population is one of the possible pathogeneses of osteoarthritis of the knee joint.

References

- Clarke HD, Scott WN, Insall JN, et al. Anatomy, in Scott WN editors. *Surgery of the knee*, 4th ed. New York: Churchill Livingstone; 2006. p. 3-66.
- Buckwalter JA, Amendola A, Clark CR. Articular cartilage and meniscus: biology, biomechanics, and healing response, in Scott WN editors. *Surgery of the knee*, 4th ed. New York: Churchill Livingstone; 2006. p. 307-16.
- Bergman AG, Willen HK, Lindstrand AL, Pettersson HTA. Osteoarthritis of the knee: Correlation of subchondral MR signal abnormalities with histopathologic and radiographic features. *Skeletal Radiol* 1994;23:445-8.
- Sugita T, Chiba T, Kawamata T, et al. Assessment of articular cartilage of the lateral tibial plateau in varus osteoarthritis of the knee. *The Knee* 2000;7:217-20.
- Hefti F, Krause R, Möller-Madsen B, et al. Osteochondritis dissecans: a multicenter study of the European Pediatric Orthopedic Society. *J Pediatr Orthop B* 1999;8:231-45.
- Ganley TJ, Flynn JM. Osteochondritis dissecans, in Scott WN editors. *Surgery of the knee*, 4th ed. New York: Churchill Livingstone; 2006. p. 1234-41.
- Uozumi H, Sugita T, Aizawa T, et al. Histology and Possible Etiology of Osteochondritis Dissecans of the Knee. *Am J Sports Med* 2009;37:2003-8.
- Einhorn TA. The cell and molecular biology of fracture healing. *Clin Orthop* 1998;355S: S7-21.
- Farnum CE, Wilaman NJ. Cellular turnover at the chondro-osseous junction of growth plate cartilage: analysis by serial sections at the light microscopical level. *J Orthop Res* 1989;7: 654-6.
- Trevor D. Tarso-epiphyseal aklasis. A congenital error of epiphyseal development. *J Bone Joint Surg* 1950;32B:205-3.
- Smith EL, Raney EM, Matzkin EG, et al. Trevor's disease: the clinical manifestations and treatment of dysplasia epiphysealis hemimelica. *J Pediatr Orthop* 2007;16B:297-302.
- Volders D, Vandevenne JE, Van de Casseye W. Trevor's disease and whole-body MRI. *Eur J Radiol* 2010 April 7. [Epub ahead of print]
- Hagiwara Y, Chimoto E, Takahashi I, et al. Expression of transforming growth factor-beta1 and connective tissue growth factor in the capsule in a rat immobilized knee model. *Ups J Med Sci* 2008;113:221-34.
- Kawaguchi H. Endochondral ossification signals in cartilage degradation during osteoarthritis progression in experimental mouse models. *Mol Cells* 2008;29:1-6.
- Kawaguchi H. Regulation of osteoarthritis development by Wnt- β -catenin signaling through the endochondral ossification process. *J Bone Miner Res* 2009;24: 8-11.
- Muraki S, Oka H, Akune T, et al. Prevalence of radiographic knee osteoarthritis and its association with knee pain in the elderly of Japanese population-based cohorts: the ROAD study. *Osteoarthritis Cartilage* 2009;17:1137-43.
- Muraki S, Akune T, Oka H, et al. Association of occupational activity with radiographic knee osteoarthritis and lumbar spondylosis in elderly patients of population-based cohorts: a large-scale population-based study. *Arthritis Rheum* 2009;61: 779-86.
- Oka H, Muraki S, Akune T, et al. Fully automatic quantification of knee osteoarthritis severity on plain radiographs. *Osteoarthritis Cartilage* 2008;16:1300-6.