

# Neuro-ophthalmic Complications of Immune Checkpoint Inhibitors: A Systematic Review

This article was published in the following Dove Press journal:  
*Eye and Brain*

Caberry W Yu <sup>1</sup>  
Matthew Yau<sup>2</sup>  
Natalie Mezey<sup>1</sup>  
Ishraq Joarder <sup>3</sup>  
Jonathan A Micieli <sup>4,5</sup>

<sup>1</sup>Faculty of Medicine, Queen's University, Kingston, Canada; <sup>2</sup>Faculty of Medicine, University of Toronto, Toronto, Canada; <sup>3</sup>Faculty of Science, University of Toronto, Scarborough, Ontario, Canada; <sup>4</sup>Department of Ophthalmology and Vision Sciences and Division of Neurology, Department of Medicine, University of Toronto, Toronto, Canada; <sup>5</sup>Kensington Vision and Research Centre, Toronto, Canada

**Objective:** Immune checkpoint inhibitors (ICIs) are novel cancer therapies that may be associated with immune-related adverse events (IRAEs) and come to the attention of neuro-ophthalmologists. This systematic review aims to synthesize the reported ICI-associated IRAEs relevant to neuro-ophthalmologists to help in the diagnosis and management of these conditions.

**Methods:** A systematic review of the literature indexed by MEDLINE, Embase, CENTRAL, and Web of Science databases was searched from inception to May 2020. Reporting followed the Preferred Reporting Items for Systematic Review and Meta-analysis (PRISMA) guidelines. Primary studies on ICIs and neuro-ophthalmic complications were included. Outcomes included number of cases and incidence of neuro-ophthalmic IRAEs.

**Results:** Neuro-ophthalmic complications of ICIs occurred in 0.46% of patients undergoing ICI and may affect the afferent and efferent visual systems. Afferent complications include optic neuritis (12.8%), neuroretinitis (0.9%), and giant cell arteritis (3.7%). Efferent complications include myasthenia gravis (MG) (45.0%), thyroid-like eye disease (11.9%), orbital myositis (13.8%), general myositis with ptosis (7.3%), internuclear ophthalmoplegia (0.9%), opsoclonus-myoclonus-ataxia syndrome (0.9%), and oculomotor nerve palsy (0.9%). Pembrolizumab was the most common causative agent for neuro-ophthalmic complications (32.1%). Mortality was highest for MG (19.8%). Most patients (79.8%) experienced improvement or complete resolution of neuro-ophthalmic symptoms due to cessation of ICI and immunosuppression with systemic corticosteroids.

**Conclusion:** While incidence of neuro-ophthalmic IRAEs is low, clinicians involved in the care of cancer patients must be aware of their presentation to facilitate prompt recognition and management. Collaboration between oncology and neuro-ophthalmology teams is required to effectively manage patients and reduce morbidity and mortality.

**Keywords:** immune checkpoint inhibitors, cancer immunotherapy, CTLA-4 inhibitors, PD-1 inhibitors, PD-L1 inhibitors

## Introduction

Immune checkpoint inhibitors (ICIs) are novel immunologic monoclonal antibodies that block inhibitory receptors of the immune system, such as cytotoxic T-lymphocyte associated antigen-4 (CTLA-4), programmed death-1 receptor (PD-1), and programmed death ligand-1 (PD-L1).<sup>1</sup> They are increasingly used as cancer therapies for cancers such as melanoma due to their activation of specific antitumor T-cell immune responses.<sup>2</sup> These immune checkpoint molecules maintain immune homeostasis and prevent autoimmunity, but are also used by cancers to suppress normal antitumor immune responses.<sup>1,2</sup> CTLA-4, located on T-cells, regulates

Correspondence: Jonathan A Micieli  
Kensington Vision and Research Centre,  
340 College Street, Suite 501, Toronto,  
Ontario M5T 3A9, Canada  
Tel +1(416) 928-1335  
Fax +1(416) 928-5075  
Email jmiceli@kensingtonhealth.org

T-cell activity in the priming phase by preferentially binding to B7 on antigen-presenting cells. CTLA-4 inhibitors decrease the preferential binding between CTLA-4 and cluster of differentiation 28 (CD28) to allow binding of CD28 to B7 to occur and activate T-cells, thereby enhancing antitumor activity.<sup>3</sup> PD-1 and PD-L1 inhibitors work by inhibiting the PD-1 (expressed on T or B cells) and the PD-L1 (expressed on cells like tumor cells) interaction that dampens immune response.<sup>4</sup> There are currently seven ICIs approved by the US Food and Drug Administration, ipilimumab, pembrolizumab, nivolumab, cemiplimab, atezolizumab, avelumab, and durvalumab.

Due to their efficacious antitumor responses in advanced malignancies, ICIs are increasingly used, and potential new ICIs are investigated in clinical trials. However, there are frequent toxicities associated with their use that can lead to their discontinuation. The toxicities that occur due to immune system activation are termed immune-related adverse events (IRAEs), which can occur in 70–90% of patients and affect any organ system.<sup>5,6</sup> The skin and gastrointestinal systems are most affected by ICIs and usually involve low-grade IRAEs such as rashes, diarrhea, and nausea.<sup>7,8</sup> ICIs have also been associated with de novo endocrinopathies or exacerbations of existing ones.<sup>9</sup> Ophthalmic IRAEs have been reported in less than 1% of patients, common examples include anterior uveitis and dry eye.<sup>10–12</sup>

Neuro-ophthalmic complications warrant their own investigation and can present with higher morbidity and mortality than IRAEs of other systems.<sup>7</sup> Currently, established guidelines for the management of IRAEs contain very few neuro-ophthalmic conditions (eg myasthenia gravis (MG), general myositis and thyroid eye disease) and have been nonspecific in describing the unique complications in neuro-ophthalmology.<sup>13</sup> While there have been systematic reviews on ophthalmic<sup>10,14</sup> and neurologic<sup>15–17</sup> complications alone, they focus on complications like uveitis or central nervous system disorders that may not involve the visual pathways. No systematic reviews exist on neuro-ophthalmic IRAEs specifically. Thus, the present review was conducted to investigate the neuro-ophthalmic IRAEs of ICIs to collate information on presentation, treatment, and outcome to guide diagnosis and management.

## Methods

This systematic review and meta-analysis were performed in accordance with the *Cochrane Handbook for Systematic*

*Reviews of Interventions*<sup>18</sup> and the reporting followed the Preferred Reporting Items for Systematic Review and Meta-analysis (PRISMA) guidelines.<sup>19</sup>

## Search Methods

MEDLINE, Embase, CENTRAL, and Web of Science databases were comprehensively searched from inception to May 8, 2020 (complete search strategy available in [Table S1](#)). Articles were limited to English language with no year restrictions. A manual search of references in original studies and reviews and editorials was also conducted. When full-texts were unavailable, library copies were requested. Covidence was used to manage records identified by the literature search.<sup>20</sup>

## Eligibility Criteria and Study Selection

All published articles on ICIs and neuro-ophthalmic outcomes were considered for inclusion. Reviews were used to identify potential eligible articles, but excluded from final analysis. The primary outcomes of the review were the number of cases and incidence of neuro-ophthalmic IRAEs. These included complications of the afferent visual system (eg, optic neuritis; giant cell arteritis, GCA; neuroretinitis), efferent visual system (eg, MG, thyroid-like eye disease, orbital myositis, orbital apex syndrome, oculomotor nerve palsies), and other disorders (eg Tolosa–Hunt Syndrome, neuromyelitis optica). Neurological conditions such as MG were only included if ocular symptoms were involved.

Each study was reviewed by two reviewers, independently and in duplicate, by title and abstract, and subsequently by full text, with discrepancies resolved by an independent third reviewer. During abstract screening, all clinical trials, cohort studies, and case series on side effects not specific to neuro-ophthalmology with ICIs were included for full-text review to ensure that papers that only mentioned neuro-ophthalmic outcomes in the full-text were included.

## Data Collection and Synthesis

Data extraction occurred for each study using predefined data abstraction forms in accordance with PRISMA. Extracted data included study characteristics (eg, author, publication year, country, study design), patient demographics (eg, age, sex, cancer type), intervention (eg ICI name, cycles and duration prior to onset), and outcome (eg, neuro-ophthalmic diagnosis, presentation, treatment, and final outcome). Prevalence was also collected for

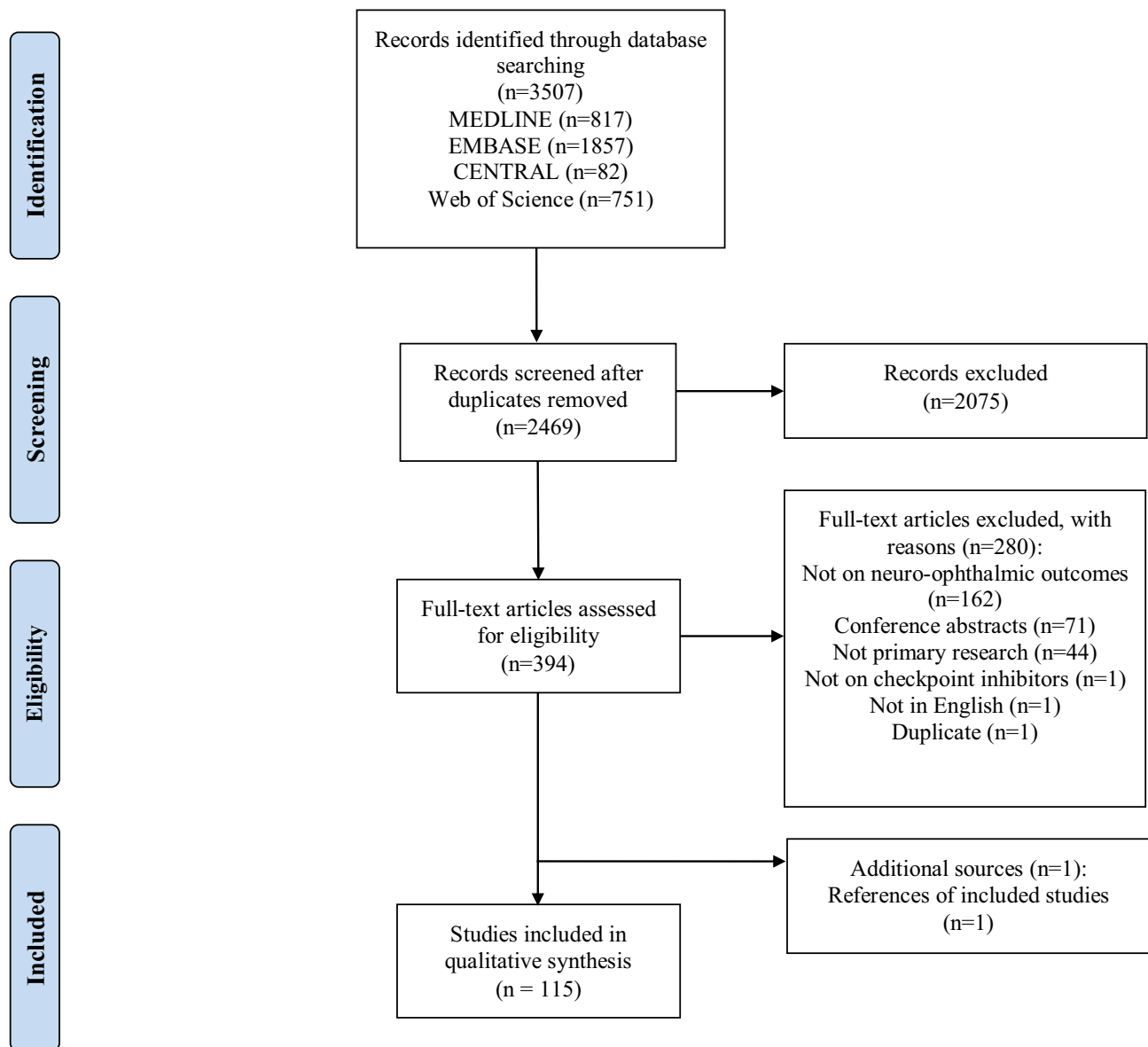
observational studies and clinical trials. Risk of bias was not assessed due to the higher number of case reports and series included. Qualitative analysis was carried out for each neuro-ophthalmic diagnosis reported. Quantitative analysis was performed using Microsoft Excel to calculate mean incidence or mortality of diagnoses when more than one pharmacovigilance or clinical trial reported such data. Overall prevalence of neuro-ophthalmic complications was calculated by dividing the number of cases of neuro-ophthalmic complications in included clinical trials and observational studies by the total number of patients who received ICIs in these studies.

## Results

From 3507 abstracts obtained from the search strategy, 2469 abstracts were screened after de-duplication, and 394 full texts were reviewed. Of these, 115 papers met our inclusion criteria. [Figure 1](#) depicts a PRISMA flow diagram.

## Study Characteristics

Of the 115 included studies, 98 were case reports or series and 17 were retrospective chart reviews or clinical trials that reported incidence of neuro-ophthalmic complications. [Table 1](#) provides a summary of these observational or pharmacovigilance studies.<sup>21–38</sup> [Tables 2–6](#) detail 109



**Figure 1** PRISMA chart for screening process, PRISMA figure adapted from Liberati A, Altman D, Tezloff J, et al. The PRISMA statement for reporting systematic reviews and meta-analyses of studies that evaluate health care interventions: explanation and elaboration. *Journal of clinical epidemiology*. 2009;62(10). Creative Commons.

**Table 1** Summary of Observational Studies or Clinical Trials

Author Year Ref	Purpose	Cancer Type	ICI Name	Diagnosis	Prevalence
Camacho 2009 <sup>21</sup>	Phase I and II study on safety of tremelimumab	Metastatic melanoma	Tremelimumab	Thyroid-like eye disease	1 of 28 patients in phase I
Voskens 2013 <sup>22</sup>	Retrospective chart review on prevalence of IRAEs for ipilimumab	Metastatic melanoma	Ipilimumab	Tolosa–Hunt Syndrome	1 of 752
Weber 2013 <sup>31</sup>	Phase I study evaluating safety and IRAEs of nivolumab with peptide vaccine in ipilimumab—refractory or —naïve melanoma	Unresectable stage III or IV melanoma	Nivolumab	Optic neuritis	1 of 90
Hodi 2014 <sup>32</sup>	Phase I study on safety of bevacizumab plus ipilimumab inpatients with metastatic melanoma	Metastatic melanoma	Ipilimumab + bevacizumab	Giant cell arteritis	1 of 46
Balar 2017 <sup>33</sup>	Phase II Study (KEYNOTE-052) evaluating safety of pembrolizumab in cisplatin-ineligible patients with urothelial cancer	Advanced urothelial cancer	Pembrolizumab	Eyelid ptosis	1 of 370
Diehl 2017 <sup>34</sup>	Retrospective chart review on relationship between absolute lymphocyte counts and risk of IRAEs	Lung cancer, melanoma, RCC, urothelial, HNSCC, Merkel cell carcinoma, and colon cancer	Nivolumab or pembrolizumab	Optic neuritis	1 of 167
Suzuki 2017 <sup>35</sup>	Safety databases based on postmarketing surveys in Japan investigating clinical features of myasthenia gravis induced by ICIs compared to idiopathic myasthenia gravis	Melanoma, NSCLC, and colon cancer	Nivolumab or ipilimumab	Myasthenia gravis with myositis and myocarditis	12 of 10,277, including 4 with concurrent myositis
Omuro 2018 <sup>36</sup>	Phase I study (CheckMate 143) evaluating safety and IRAEs of nivolumab ± ipilimumab for glioblastoma	Glioblastoma	Nivolumab ± ipilimumab	Optic neuritis	2 of 40
Touat 2018 <sup>37</sup>	Retrospective chart review on myositis for all ICIs, multicenter	Melanoma, NSCLC, breast cancer, and renal cell cancer	Nivolumab, pembrolizumab, durvalumab, or ipilimumab	Myocarditis and myositis	10 cases of myositis
Kao 2017 <sup>38</sup>	Retrospective cohort study on prevalence of neurological complications in all patients receiving anti-PD-1 therapy at one centre	Malignant melanoma and other solid-organ tumors	Pembrolizumab or nivolumab	Necrotizing myopathy, bilateral internuclear ophthalmoplegia	1 of 347 necrotizing myopathy, 1 of 347 bilateral internuclear ophthalmoplegia

(Continued)

Table 1 (Continued).

Author Year Ref	Purpose	Cancer Type	ICI Name	Diagnosis	Prevalence
Kaur 2019 <sup>23</sup>	Retrospective chart review on IRAEs at one centre for all ICIs	Melanoma, NSCLC, renal cell carcinoma, bladder cancer, clear cell sarcoma, Hodgkin's lymphoma, gastric adenocarcinoma, and squamous cell cancer	Pembrolizumab, nivolumab, ipilimumab, or combination therapy with nivolumab and ipilimumab	Optic neuritis	1 of 220
Mancone 2018 <sup>24</sup>	Retrospective chart review on prevalence of neurologic IRAEs at one centre	Squamous cell lung carcinoma	Nivolumab	Oculomotor nerve palsy	1 of 526
Johnson 2019 <sup>25</sup>	Disproportionality analysis using pharmacovigilance database to compare neurologic IRAEs in patients receiving ICI vs control	Lung cancer, melanoma, and other cancers	Nivolumab, pembrolizumab, atezolizumab, other anti-PD-1/PD-L1, anti CTLA-4 drugs, or combination of drugs	Myasthenia gravis	228 of 48,653
Kim 2019 <sup>26</sup>	Retrospective chart review on ophthalmic IRAEs at one centre	Metastatic cutaneous melanoma, uveal melanoma, NSCLC	Nivolumab ± ipilimumab	Optic neuritis	1 of 1474
Moreira 2019 <sup>27</sup>	Retrospective chart review on autoimmune neurological IRAEs at one centre for all ICIs	Metastatic skin cancers	Ipilimumab, tremelimumab, nivolumab, or pembrolizumab	All neurologic complications including myositis, myasthenia gravis (ocular involvement unknown)	38 cases of autoimmune neurological disorders
Safa 2019 <sup>28</sup>	Retrospective chart review on myasthenia gravis at one center for all ICIs	Metastatic melanoma and other cancers	Nivolumab, pembrolizumab, ipilimumab, or other ICIs	Myasthenia gravis	63 of 5898, including 24 with concurrent myositis
Seki 2019 <sup>29</sup>	Retrospective cohort study on inflammatory myopathy associated with PD-1 inhibitors	NSCLC and other cancers	Nivolumab or pembrolizumab	Myositis with ocular involvement	Of 19 cases of inflammatory myopathy, 13 had diplopia and 15 had ptosis
Williams 2019 <sup>30</sup>	Retrospective chart review of patients receiving ICIs to evaluate corticosteroid use in management of IRAEs at one centre	Melanoma, lung cancer, RCC, HNSCC, and other cancers	Nivolumab, ipilimumab, or pembrolizumab	Optic neuritis	3 of 103

**Abbreviations:** IRAEs, immune-related adverse effects; ICI, immune checkpoint inhibitors; PD-1, programmed death-1 receptor; NSCLC, non-squamous cell lung cancer; RCC, renal cell carcinoma; HNSCC, head and neck squamous cell carcinoma.

individual cases (including cases described in observational studies) of optic neuritis/neuroretinitis, neuromuscular disorders, orbital disorders, GCA, and other diseases.

A breakdown of the diagnoses can be found in Table 7. Of the cases, 31.2% of all patients with a neuro-ophthalmic complication were female. The mean (range) age at

**Table 2** Summary of Cases—Optic Neuritis or Neuroretinitis

Author Year Ref	Age M/F	Cancer Type	ICI Name	Cycles and Duration Before Symptoms	Neuro-Ophthalmic Diagnosis	Ophthalmic Presentation	Treatment	ICI Continued/Held/Terminated	Neuro-Ophthalmic Outcome	Follow-up Period (Months)
Boisseau 2017 <sup>42</sup>	27F	Renal cell carcinoma	Ipilimumab	5 cycles: then 5 weeks	Optic neuritis	OU: vision loss and optic disc edema	IV methylprednisolone 1 g daily for 3 days then po steroid taper; PLEX 10 sessions	Held	Resolution (1 month)	6
Francis 2020 <sup>43</sup>	61F	Melanoma	Ipilimumab	3 cycles	Optic neuritis	OU: vision loss and optic disc edema	Prednisone 80 mg with taper; topical prednisolone, timolol/dorzolamide	Terminated	Cecentral detect OD	33
Francis 2020 <sup>43</sup>	71M	NSCLC	Pembrolizumab	3 cycles	Optic neuritis	OU: vision loss and optic disc edema/pallor	IV methylprednisolone 1 g daily for 5 days, prednisone 80 mg with taper	Terminated	Disc pallor with resolved edema, thinning OU	7
Francis 2020 <sup>43</sup>	58M	Small-cell lung carcinoma	Ipilimumab and nivolumab	4 cycles	Optic neuritis	OU: vision loss	IV methylprednisolone 1 gx5 days and 5 PLEX, prednisone 50 mg with taper over 6 months	Terminated	Pink OD, 4+ pallor OS	6
Hahn 2015 <sup>48</sup>	44M	Melanoma	Ipilimumab	3 infusions then 2 months	Neuroretinitis	OD metamorphopsia, OS scotoma, OU: eye pain, redness, photophobia, optic disc edema	Prednisone 80 mg, gtts: prednisolone 1%, brimonidine 0.2%, timolol 0.5% TID OU	Terminated	Resolution (2 months)	2
Kartal 2018 <sup>45</sup>	9M	Glioblastoma multiforme	Nivolumab	2 cycles: then 2 days	Optic neuritis	OU: decreased vision, optic disc edema	IV corticosteroids 1 g daily for 5 days	Terminated	Improvement	1 week
Kaur 2019 <sup>23</sup>	27F	Melanoma	Ipilimumab	4 cycles	Optic neuritis	NR	Corticosteroids	Continued	Improvement	NR
Kim 2019 <sup>26</sup>	61F	Melanoma	Ipilimumab and nivolumab	4 cycles of combination, 1 cycle of nivolumab monotherapy	Optic neuritis	OU: decreased VF, optic disc edema	IVIg and infliximab	Terminated	Death (cancer progression)	18

Mori 2018 <sup>46</sup>	64M	NSCLC	Atezolizumab	NR cycles: then 12 months	Optic neuritis	OS: sudden vision loss, optic disc edema, venous congestion without bleeding	IV methylprednisolone 1 g for 3 days followed by 30 mg po prednisolone administration	NR	Resolution (24 months)	24
Noble 2019 <sup>11</sup>	65M	Prostate cancer	Durvalumab	NR	Optic neuritis	OS: inferior scotoma with central sparing, EOM discomfort, optic disc edema	IV corticosteroid bolus	Continued	Improvement	NR
Samanci 2019 <sup>47</sup>	53M	Lung adenocarcinoma	Atezolizumab	1 cycle: then 20 days	Optic neuritis	OU: blurry vision, optic disc edema	IV methylprednisolone 2 mg/kg followed by po methylprednisolone	Terminated	Resolution (1 month)	1
Sun 2008 <sup>39</sup>	72M	Bladder cancer	Ipilimumab	1 dose: then 3 weeks	Optic neuritis	OU: vision loss, optic disc edema	IV dexamethasone 20 mg, then IV methylprednisolone 250 mg q6 h, later prednisone 100 mg daily then taper	Terminated	Improvement	24 weeks
Sun 2020 <sup>40</sup>	43M	Melanoma	Pembrolizumab	NR	Optic neuritis	NR	NR	NR	NR	NR
Wilson 2016 <sup>41</sup>	53M	Melanoma	Ipilimumab	3 cycles: 4 months after start	Optic neuritis	OS: no light perception, optic disc edema, retinal whitening	Prednisone, methylprednisolone, mycophenolate mofetil with prednisone, plasmapheresis	Held	Resolution (15 months)	17
Yeh 2015 <sup>44</sup>	67M	Melanoma	Ipilimumab	3 infusion: then 3 weeks	Optic neuritis	OU: left VF vision loss, photopsia, blurry vision, optic disc edema; OD reduced color vision	gts: prednisolone and atropine OU	Terminated	Normal visual acuity, persistent VF defects	6

**Abbreviations:** NSCLC, non-squamous cell lung cancer; OU, both eyes; OD, right eye; OS, left eye; IV, intravenous; po, per os; IV, intravenous immunoglobulin; NR, not reported; PLEX, plasma exchange; BID, twice daily; TID, three times daily; QID, four times daily.

Table 3 Summary of Cases – Neuromuscular

Author Year Ref	Age M/F	Cancer Type	ICI Name	Cycles and Duration Before Symptoms	Neuro-Ophthalmic Diagnosis	Concomitant Myositis, CK Levels (IU/L)	Ophthalmic Presentation	Treatment	ICI Continued/Held/Terminated	Neuro-Ophthalmic Outcome	Follow-up Period (Months)
Algaed 2018 <sup>51</sup>	73M	Melanoma	Pembrolizumab	NR cycles: then 3 weeks	MG	N	OS: ptosis	IVig 2 g/kg daily, prednisone 60 mg daily, plasmapheresis 5 exchanges	NR	Improvement	5 weeks
Alnahhas 2016 <sup>52</sup>	84M	Melanoma	Pembrolizumab	2 cycles: then 2 months	MG	N	OU: ptosis, ophthalmoplegia	Prednisone 60 mg daily, pyridostigmine 60 mg TID, and IVig 0.4 g/kg/day for 5 days	Terminated	Death (hypercapnic respiratory failure)	3 days
Beccart 2019 <sup>63</sup>	75F	Melanoma	Nivolumab	3 cycles (6 weeks)	MG	N	OU: diplopia, ptosis	Prostigmine 3 mg daily	Continued	Improvement, continued prostigmine	21
Chang 2017 <sup>74</sup>	75M	Transitional cell carcinoma of bladder and ureter	Nivolumab	2 doses: then 3 weeks	MG	N	OU: diplopia, ptosis	Pyridostigmine 90 mg QID, and IVig 0.4 g/kg daily over 5 days	Terminated	Improvement in 6 days, death (unknown cause) 10 days	10 days
Chen 2017 <sup>85</sup>	57M	NSCLC	Nivolumab and ipilimumab	1 cycle ipilimumab, 2 cycles nivolumab: then 2 weeks	MG	Y, 2682	OD: ptosis	IV prednisolone 2 mg/kg daily for 5 days followed by 1 mg/kg daily for 2 days, po pyridostigmine 60 mg TID	Terminated	Improvement, death (pneumonia) 1 week	1 week
Chen 2017 <sup>92</sup>	65M	NSCLC	Nivolumab	3 cycles: then 5 days	MG	Y, CK NR	OU: ptosis	Methylprednisolone 1 mg/kg daily and pyridostigmine 60 mg po BID	Terminated	Death (hypercapnic respiratory failure)	3 weeks
Cooper 2017 <sup>93</sup>	68F	NSCLC	Nivolumab	5 cycles: then 1 month	MG	N	OU: diplopia, ophthalmoplegia	Pyridostigmine and prednisone at 60 mg daily, 5 exchanges of plasmapheresis	Terminated	Minimal improvement, hospice care	18 days



Crusz 2018 <sup>54</sup>	78M	Melanoma	Pembrolizumab	2 doses: then 6 days	MG		Y, I 109	OD: ptosis	IVlg, pyridostigmine, later mycophenolate + PLEX, later rituximab 1 g infusion	Terminated	Resolution	4
Dhein 2019 <sup>55</sup>	79F	Lung adenocarcinoma	Pembrolizumab	6 doses (22 weeks), then 3 months	MG		N	OU: ptosis	Pyridostigmine 60 mg, five times daily, IV methylprednisolone 80 mg daily	Completed	Resolution	3
Earl 2017 <sup>56</sup>	74M	Melanoma	Pembrolizumab	2 doses: then 12 days	MG	exacerbation	N	OD: impaired adduction, OU: ptosis, ophthalmoplegia	IVlg 2 g/kg total, prednisone 80 mg daily, mycophenolate 1500 mg BID, pyridostigmine 120 mg TID, plasmapheresis	Terminated	Minimal improvement, death (unknown cause)	NR
Fazel 2019 <sup>53</sup>	78F	Melanoma	Ipilimumab and nivolumab	1 cycle: then 5 days	MG		Y (systemic myositis), CK NR	OU: diplopia, ptosis	IV methylprednisolone 1000 mg daily for 3 days, IVlg 2 g/kg daily for 2 days	Continued	Worsened, hospice care	8 days
Fellner 2018 <sup>54</sup>	68M	Melanoma	Pembrolizumab	2 doses (5 weeks): then 2 weeks	MG		N	OS: ptosis, esophoria	Prednisone 10 mg daily then taper	Held	Resolution	6 weeks
Fukasawa 2017 <sup>55</sup>	69F	Lung adenocarcinoma	Nivolumab	3 cycles: then 1 week	MG		N	OU: diplopia, OS: impaired adduction	Methylprednisolone 1 g for 3 days followed by 1 mg/kg daily	NR	Improvement, continued steroids	36 days
Gonzalez 2017 <sup>56</sup>	71F	Uterine carcinosarcoma	Pembrolizumab	4 doses	MG		N	OU: diplopia, ptosis, OS: impaired abduction	po pyridostigmine up to 60 mg TID, prednisone 20 mg daily	Held	Resolution (3 weeks), death (cancer progression) 5 months	5
Hasegawa 2017 <sup>57</sup>	76F	NSCLC	Nivolumab	2 doses: then 26 days	MG		Y, 6566	OU: diplopia, OS: ptosis	IVlg, PLEX 3 sessions, prednisolone 10 mg daily	Terminated	Improvement	85 days

(Continued)

Table 3 (Continued).

Author Year Ref	Age M/F	Cancer Type	ICI Name	Cycles and Duration Before Symptoms	Neuro-Ophthalmic Diagnosis	Concomitant Myositis, CK Levels (IU/L)	Ophthalmic Presentation	Treatment	ICI Continued/Held/Terminated	Neuro-Ophthalmic Outcome	Follow-up Period (Months)
Hibino 2018 <sup>58</sup>	83M	Lung squamous cell carcinoma	Pembrolizumab	2 cycles (on day 38 of treatment)	MG	Y, 436 I	OU, ptosis, ophthalmoplegia, diplopia	po pyridostigmine 60 mg TID for 7 days	NR	Improvement	3
Huh 2017 <sup>59</sup>	34F	Thymic squamous cell carcinoma	Pembrolizumab	4 cycles	MG	Y, 2125	OU: ptosis, ophthalmoplegia	IVlg for 5 days, IV methylprednisolone 1 g daily for 3 days, prednisolone 1 mg/kg daily, then 5 cycles of plasmapheresis	Terminated	Improvement, ptosis resolved, ophthalmoplegia persisted	6
Johnson 2015 <sup>60</sup>	69F	Melanoma	Ipilimumab	3 doses: then several days	MG	N	OU: diplopia, ptosis	Pyridostigmine 30 mg TID, then IV methylprednisolone 2 mg/kg and plasmapheresis, then 40 mg prednisone daily	NR	Improvement	3
Kim 2019 <sup>61</sup>	76M	NSCLC	Nivolumab	4 doses: then 3 days	MG	Y, 2934	OD: ptosis, diplopia	IV methylprednisolone 1 mg/kg daily for 32 days, pyridostigmine 30 mg TID for 6 days and was increased to 60 mg TID, tapered to po prednisolone 40 mg BID	Completed	Improvement	8
Konstantina 2019 <sup>62</sup>	30F	Type B3 thymoma	Pembrolizumab	1 dose: then 3 days	Myasthenic crisis	Y, CK NR	Unilateral ptosis, diplopia	Corticosteroids and pyridostigmine 400 mg/kg for 5 days, then rituximab 375/m <sup>2</sup> for 3 weeks	Terminated	Death (septic shock)	54 days
Lara 2019 <sup>64</sup>	63F	NSCLC-adenocarcinoma	Pembrolizumab	2 cycles	MG	N	OU: ptosis, EOM palsies	IVlg, high-dose corticosteroid therapy, and pyridostigmine	Terminated	Improvement	NR

Lau 2016 <sup>65</sup>	75M	Melanoma	Pembrolizumab	5 weeks	MG	N	OS: ptosis	IV methylprednisolone 1 g daily for 5 days, IV Ig 0.5 g/kg daily for 4 days, discharged with prednisone 60 mg daily	Held	Resolution	4
Liao 2014 <sup>66</sup>	70F	Melanoma	Ipilimumab	2 cycles: then 1 week	MG	Y, 1200	OU: ptosis	Plasmapheresis daily for 3 days, 125 mg IV methylprednisolone daily	Terminated	Improvement	2 weeks
Liu 2019 <sup>67</sup>	73M	Melanoma	Pembrolizumab	2 doses: then <1 week	MG	N	OU: ptosis	IV Ig 2 g/kg daily for 5 days, and IV methylprednisolone 1 g daily for 3 days	Terminated	Improvement	6 weeks
Loochan 2015 <sup>68</sup>	70M	SCLC	Ipilimumab	Day 16	MG	N	OU: diplopia, ptosis	Prednisone 1 mg/kg daily, followed by 3 sessions of plasmapheresis, prednisone 90 mg daily	Terminated	Death (septic shock, cardiac, ulcers)	22 days
Maeda 2016 <sup>69</sup>	79M	Melanoma	Nivolumab	3 doses: day 106	MG exacerbation	Y, 1627	OU: diplopia	None	Held	Resolution (timing NR)	9
Mancano 2018 <sup>70</sup>	76F	NSCLC	Nivolumab	2 doses: day 26	Myasthenic crisis	Y, 6566	OS: ptosis	IV Ig for 2 days, then immunoadsorption plasmapheresis therapy and IV Ig for 5 days, prednisolone 10 mg daily	NR	Improvement	65 days
March 2017 <sup>71</sup>	63M	NSCLC	Pembrolizumab	1 dose: then 2 weeks	MG	Y, 10,386	OD: ptosis, blurry vision, periorbital edema with mild erythema	Pyridostigmine 120 mg q6 h and prednisone 60 mg daily, methylprednisolone 1 g daily for 9 days, 5 IV Ig treatments, 4 plasmapheresis rounds	Terminated	Death (respiratory failure)	12 days
Mitsune 2018 <sup>72</sup>	62M	Neuroendocrine carcinoma of trachea	Nivolumab	2 cycles: day 25	MG exacerbation	Y, 14,229	OU: diplopia, ptosis	IV methylprednisolone 2 mg/kg daily	Terminated	Resolution	60 days

(Continued)

Table 3 (Continued).

Author Year Ref	Age M/F	Cancer Type	ICI Name	Cycles and Duration Before Symptoms	Neuro-Ophthalmic Diagnosis	Concomitant Myositis, CK Levels (IU/L)	Ophthalmic Presentation	Treatment	ICI Continued/Held/Terminated	Neuro-Ophthalmic Outcome	Follow-up Period (Months)
Mohn 2019 <sup>73</sup>	82M	Melanoma	Nivolumab	1 dose: then 8 weeks	MG	Y, 2000	OU: ptosis, ophthalmoplegia	IV methylprednisolone 1000mg daily for 5 days, then IVlg	Terminated	Improvement, death (blood loss) at 8 weeks	8 weeks
Mohn 2019 <sup>73</sup>	87F	Melanoma	Nivolumab	1 dose: then 4 weeks	MG	Y, CK NR	OU: ptosis	Prednisolone 100mg daily	Terminated	Death (cause unknown)	12 days
Montes 2018 <sup>75</sup>	74M	Melanoma	Ipilimumab	3 doses: then 1 day	MG	N	OU: diplopia, OD: ophthalmoplegia	High-dose corticosteroids and pyridostigmine	Terminated	Improvement, diplopia persisted, continued steroids	1
Nakatani 2018 <sup>50</sup>	73F	Lung squamous cell carcinoma	Nivolumab	25 doses: at 51 weeks	Lambert-Eaton Myasthenic Syndrome	N	OU: photophobia, ptosis	po prednisolone 20 mg daily for 7 days, pyridostigmine and ambenonium, 3,4-DAP	Restarted then terminated	Improvement	16
Nguyen 2017 <sup>76</sup>	81M	Melanoma	Pembrolizumab	3 cycles: then 2 weeks	MG	N	OU: ptosis	Prednisolone 25 mg daily then taper	Continued	Resolution	6
Nguyen 2017 <sup>76</sup>	86F	Melanoma	Pembrolizumab	2 cycles	MG	N	OU: ptosis	IV methylprednisolone 500 mg daily for 5 days, then po prednisolone taper	Continued	Improvement	3
Onda 2019 <sup>77</sup>	73M	Lung adenocarcinoma	Pembrolizumab	Day 23	MG	Y, 7311	OU: diplopia, ptosis, ophthalmoplegia	Prednisolone total 20 mg, methylprednisolone 1g daily for 3 days	NR	Resolution	4
Phua 2020 <sup>78</sup>	66M	Lung adenocarcinoma	Durvalumab	5 doses: then 3 days	MG	Y, 499	OU: diplopia, ptosis	Prednisone 60 mg daily, pyridostigmine 120 mg TID, mycophenolate mofetil 1 g BID, IVlg 2 g/kg	Terminated	Improvement	2

Polat 2016 <sup>79</sup>	65M	NSCLC	Nivolumab	3 doses: then 3 days	MG	N	OU: blurry vision, diplopia, ptosis	Pyridostigmine 45 mg q6 h for 6 weeks	Completed	Resolution (6 weeks)	4
Sciacca 2016 <sup>80</sup>	81M	NSCLC	Nivolumab	3 cycles	MG	N	OU: blurry vision, diplopia, ptosis	Prednisone 50 mg daily for 4 weeks	Terminated	Resolution (4 weeks)	1
So 2019 <sup>81</sup>	55F	Melanoma	Nivolumab	2 doses: then 1 day	Myasthenic crisis	Y, CK NR	OU: ptosis, ophthalmoplegia	IVig 0.5 g/kg daily for 5 days, 4 cycles of steroid pulse, 2 cycles of PLEX	Terminated	Improvement	6
Takai 2020 <sup>82</sup>	77M	Bladder cancer	Pembrolizumab	1 dose: then 20 days	MG	Y, 8574	OU: diplopia, ptosis	Prednisone 80 mg daily, IVig at 0.4 g/kg daily for 5 days	Terminated	Death (cardiac arrest)	13 days
Tan 2017 <sup>83</sup>	45M	NSCLC	Nivolumab	1 dose: then 2 weeks	MG	Y, CK NR	OU: ptosis, ophthalmoplegia	Pyridostigmine, methylprednisolone 1 g daily for 3 days, and IVig 400 mg/kg daily for 5 days	Held for 5 months	Improvement	5
Tedbird 2019 <sup>84</sup>	77M	Melanoma	Pembrolizumab and nivolumab	4 doses	MG	N	OU: ptosis, visual disorders (unspecified)	IVig 0.4 g/kg daily for 5 days, pyridostigmine 360 mg daily, prednisone 60 mg daily	Held for 5 months	Recurrence of myasthenic syndrome, improvement	29
Thakolwiboon 2019 <sup>86</sup>	87M	Urothelial carcinoma	Atezolizumab	2 doses	MG	Y, 1542	OU: diplopia, ptosis	Prednisone 60 mg daily for 1 week, IVig 0.4 g/kg daily, low-dose pyridostigmine	Terminated	Death (cardiac arrest)	10 days
Tozuka 2018 <sup>87</sup>	82M	Pulmonary pleomorphic carcinoma	Pembrolizumab	3 cycles: then 44 days	MG with agranulocytosis	N	OU: diplopia	Pyridostigmine 60 mg TID	Terminated	NR	NR
Veccia 2020 <sup>88</sup>	65M	Lung squamous cell carcinoma	Nivolumab	2 doses: day 27	MG	Y, 3844	OU: diplopia, OD: ptosis	IVig 0.4 mg/kg daily for 5 days, pyridostigmine 60 mg daily for 1 week, IV dexamethasone 8 mg BID, prednisone 1 mg/kg daily	Terminated	Worsened, death	7 weeks

(Continued)

**Table 3 (Continued).**

Author Year Ref	Age M/F	Cancer Type	ICI Name	Cycles and Duration Before Symptoms	Neuro-Ophthalmic Diagnosis	Concomitant Myositis, CK Levels (IU/L)	Ophthalmic Presentation	Treatment	ICI Continued/ Held/ Terminated	Neuro-Ophthalmic Outcome	Follow-up Period (Months)
Werner 2019 <sup>89</sup>	62M	Melanoma	Nivolumab and ipilimumab	2 doses: then 1 week	MG	N	OD: ptosis	Pyridostigmine 300 mg daily, prednisone 20 mg daily	Held for 6 weeks	Resolution (6 weeks)	2
Wilson 2018 <sup>91</sup>	57M	Lung adenocarcinoma	Pembrolizumab	4 weeks	MG	N	OU: ptosis, ophthalmoplegia	Corticosteroids and pyridostigmine 400 mg/kg daily for 5 days, followed by rituximab 375 mg/m <sup>2</sup> for 3 weeks	Terminated	Resolution, death (cancer progression)	6
Wilson 2018 <sup>91</sup>	62F	Melanoma	Nivolumab and ipilimumab	4 weeks	MG	N	OU: ptosis	Pyridostigmine and corticosteroids	Terminated	Resolution	12
Xing 2020 <sup>90</sup>	66M	Lung adenocarcinoma	Sintilimab	2 doses: then 4 days	Myasthenic crisis	Y, 11,919	OU: ptosis, ophthalmoplegia	Pyridostigmine bromide 120 mg BID, IV methylprednisolone 2 mg/kg daily, IVlg 400 mg/kg daily for 5 days, PLEX	Terminated	Improvement	3

**Abbreviations:** NSCLC, non-squamous cell lung cancer; OU, both eyes; OD, right eye; OS, left eye; IV, intravenous; po, per os; IVlg, intravenous immunoglobulin. NR, not reported; PLEX, plasma exchange; BID, twice daily; TID, three times daily; QID, four times daily; MG, myasthenia gravis.

**Table 4** Summary of Cases—Orbit

Author Year Ref	Age M/F	Cancer Type	ICI Name	Cycles and Duration Before Symptoms	Neuro-Ophthalmic Diagnosis	For Myositis: EOMs Normal or Abnormal Size	Ophthalmic Presentation	Treatment	ICI Continued/Held/Terminated	Neuro-Ophthalmic Outcome	Follow-up Period (Months)
Borodic 2011 <sup>100</sup>	51F	Melanoma	Ipilimumab	2 infusions	TED <sup>a</sup>		OU: diplopia, proptosis	Cantholysis, corticosteroids	NR	Resolution	NR
Campredon 2018 <sup>61</sup>	61M	NSCLC	Nivolumab	3 infusions	TED		OU: ptosis, conjunctival injection with chemosis, proptosis, ophthalmoplegia	IV methylprednisolone 1 g for 2 weeks, 500 mg for 4 weeks, and 250 mg for 5 weeks	Terminated	Improvement of chemosis, ptosis and ophthalmoplegia unchanged, death (massive hemoptysis)	13 weeks
McElinea 2014 <sup>104</sup>	68F	Melanoma	Ipilimumab	3 cycles (4 doses each); then 5 weeks	TED		OU: ophthalmoplegia	IV methylprednisolone 1 g for 5 days and po prednisolone 60 mg daily for 1 week then taper	Terminated	Improvement	6 weeks
Min 2011 <sup>105</sup>	51F	Melanoma	Ipilimumab	4 doses (8 weeks)	TED <sup>a</sup>		OU: eye pain, proptosis, conjunctival injection, periorbital edema	IV methylprednisolone 250 mg q6h for 12 doses, prednisone 100 mg BID then taper	NR	Improvement	12
Park 2018 <sup>107</sup>	52M	Merkel cell carcinoma	Pembrolizumab	3 doses (6 weeks)	TED <sup>a</sup> (euthyroid)		OU: diplopia, proptosis	Prednisone daily, ocular lubricants and po atenolol, Fresnel prisms (diplopia)	Terminated	Improvement	3
Rhea 2018 <sup>106</sup>	83M	Melanoma	Ipilimumab and pembrolizumab	1 infusion of ipilimumab: then 3 days; 1 infusion of pembrolizumab: then 1 day	TED <sup>a</sup>		OU: diplopia, blurry vision, proptosis, chemosis	Prednisone 60 mg daily	Continued	Resolution then recurrence	10

(Continued)

Table 4 (Continued).

Author Year Ref	Age M/F	Cancer Type	ICI Name	Cycles and Duration Before Symptoms	Neuro-Ophthalmic Diagnosis	For Myositis: EOMs Normal or Abnormal Size	Ophthalmic Presentation	Treatment	ICI Continued/Held/Terminated	Neuro-Ophthalmic Outcome	Follow-up Period (Months)
Ricciuti 2017 <sup>102</sup>	63F	Non-squamous non-small-cell lung cancer	Nivolumab	6 cycles: then 7 months	TED		OU: diplopia, blurry vision, ophthalmoplegia, exophthalmos	High-dose steroids	Held for 6 months	Resolution	6
Sabini 2018 <sup>108</sup>	70M	Lung adenocarcinoma	Tremelimumab and durvalumab	1 month	TED <sup>a</sup>		OU: diplopia, exophthalmos, ophthalmoplegia	Prednisone 25 mg daily then taper	Terminated	Persistent bilateral orbitopathy with primary gaze diplopia and ophthalmoplegia	6
Sagiv 2019 <sup>103</sup>	42M	Renal cell carcinoma	Nivolumab	4 doses (2 months)	TED		OU: diplopia, eyelid retraction	NR	Continued	Resolution	24
Sagiv 2019 <sup>103</sup>	51M	Melanoma	Tremelimumab	6 months	TED <sup>a</sup>		OU: diplopia, periorcular swelling and erythema, exophthalmos.	Methylprednisolone 125 mg daily then taper	Continued	Resolution	3
Bitton 2019 <sup>109</sup>	80M	NSCLC	Pembrolizumab	2 infusions: then 1 day	Orbital myositis	NR	OU: ptosis, ophthalmoplegia OD ophthalmoplegia OS	Systemic corticosteroid 1 mg/kg daily, IVIg 2 g/kg daily, methotrexate 15 mg per week	Terminated	Resolution	6
Haddox 2017 <sup>111</sup>	78M	Melanoma	Pembrolizumab	2 cycles: then 2 weeks	Orbital myositis	NA	OU: ptosis, ophthalmoplegia	Prednisone 1 mg/kg, after 1 week: PLEX	Terminated	Worsened, death (respiratory failure)	3 days
Henderson 2015 <sup>112</sup>	55M	Melanoma	Ipilimumab	3 cycles	Orbital myositis	Abnormal size	OU: burning, injection, FB sensation, photophobia, diplopia, chemosis, ophthalmoplegia, ptosis, periorbital edema	Prednisone	Terminated	Improvement with persistent abduction deficit OS and binocular diplopia	NR



Kamo 2019 <sup>13</sup>	78M	Renal, pelvis, and ureter cancer	Pembrolizumab	NR	Orbital myositis	Abnormal size	OU: ophthalmoplegia, ptosis	IV methylprednisolone, PLEX	Terminated	Improvement, death (cancer progression)	NR
Kamo 2019 <sup>13</sup>	72F	Lung cancer	Pembrolizumab	NR	Orbital myositis	Abnormal size	OU: ophthalmoplegia, OD: ptosis	Prednisone 0.5 mg/kg daily then taper	NR	Resolution	NR
Liewluck 2018 <sup>14</sup>	78M	Melanoma	Pembrolizumab	2 cycles (28 days)	Orbital myositis	Normal size (assumed)	OU: diplopia, proptosis	Prednisone, PLEX	Terminated	Death (respiratory failure)	NR
Liewluck 2018 <sup>14</sup>	68M	Gastroesophageal adenocarcinoma	Pembrolizumab	2 cycles (30 days)	Orbital myositis	Abnormal size	OU: diplopia, proptosis	IV methylprednisolone, prednisone, and PLEX	Terminated	Resolution	NR
Liewluck 2018 <sup>14</sup>	55M	Non-Hodgkin's lymphoma	Pembrolizumab	4 cycles (72 days)	Orbital myositis	NR	OU: diplopia	Prednisone	Terminated	Resolution	NR
Nardin 2018 <sup>15</sup>	68M	Melanoma	Ipilimumab	51 cycles (3 years)	Orbital myositis	Abnormal size	OU: diplopia, eyelid swelling and retraction, proptosis, ophthalmoplegia, OD: retro-orbital pain, redness	IV methylprednisolone 500 mg weekly for 3 months, then prednisone 1 mg/kg daily	Terminated	Resolution	10
Nasr 2018 <sup>16</sup>	79M	Gastric adenocarcinoma	Pembrolizumab	2 doses: then 2 weeks	Orbital myositis	Abnormal size	OU: ptosis, ophthalmoplegia	IV prednisone 1 mg/kg daily, IVig 2 mg/kg for 4 days, pyridostigmine 10 mg daily	Terminated	No improvement, death (cause NR)	NR
Patel 2016 <sup>10</sup>	39M	Melanoma	Ipilimumab	4 cycles: then 4 days	Orbital myositis	Abnormal size	OU: blurry vision, diplopia	Prednisone up to 125 mg daily, later IV steroids	NR	Resolution	3
Pushkarevskaya 2017 <sup>17</sup>	60F	Melanoma	Ipilimumab	2 cycles (4 doses each): then 2 months	Orbital myositis	Abnormal size	OU: ptosis, ophthalmoplegia	IV methylprednisolone, mycophenolate mofetil 3 g daily, IVig 2 g/kg monthly	Terminated	Improvement with minor difficulties with distant vision	11

(Continued)

Table 4 (Continued).

Author Year Ref	Age M/F	Cancer Type	ICI Name	Cycles and Duration Before Symptoms	Neuro-Ophthalmic Diagnosis	For Myositis: EOMs Normal or Abnormal Size	Ophthalmic Presentation	Treatment	ICI Continued/Held/Terminated	Neuro-Ophthalmic Outcome	Follow-up Period (Months)
Pushkarevskaya 2017 <sup>17</sup>	60F	Melanoma	Ipilimumab	2 cycles: then 2 weeks	Orbital myositis	Abnormal size	OU: ophthalmoplegia, blurry vision, diplopia	Prednisolone up to 160 mg daily, then mycophenolate mofetil 3g daily	Continued	Resolution	3
Sagiv 2019 <sup>103</sup>	73M	Bladder urothelial carcinoma	Nivolumab and ipilimumab	3 doses	Orbital myositis	NR	OU: diplopia, periocular pain, ophthalmoplegia, exophthalmos, conjunctival injection, eyelid edema and erythema	Methylprednisolone 1g daily for 3 days, 80mg prednisone BID then tapered to 60 mg daily	Continued	Resolution (2 weeks), death (cancer progression, 1 months)	1
Valenti-Azcarate 2020 <sup>118</sup>	66M	NSCLC	Nivolumab and ipilimumab	2 cycles (4 weeks)	Orbital myositis	NR (MRI showed "inflammation" did not specify which muscle)	OU: diplopia	IV prednisolone 2 mg/kg daily	Continued	Improvement, death (cancer progression)	2
Williams 2020 <sup>119</sup>	69M	Prostate adenocarcinoma	Nivolumab and ipilimumab	2 cycles	Orbital myositis	Normal size	OS: ptosis	IV methylprednisolone 1 g daily, plasmapheresis, IVIg 4 cycles, and mycophenolate mofetil	Terminated	Resolution (6 months), death (cancer progression)	12
Hassanzadeh 2017 <sup>20</sup>	64F	Melanoma	Ipilimumab	NR	Orbital apex syndrome		OD: vision loss, right RAPD, proptosis, ptosis, ophthalmoplegia	IV methylprednisolone 1 g daily for 7 days, then taper prednisone 1 mg/kg	Terminated	Persistent esotropia on prednisone 10 mg daily	6

Voskens 2013 <sup>22</sup>	65M	Melanoma	Ipilimumab	1 dose; then 18 weeks	Tolosa-Hunt Syndrome		Unilateral headache, OU: diplopia, OD: pain, epiphora, mydriasis, ptosis, paresis of oculomotor nerve	IV methylprednisolone, oral dexamethasone, local radiotherapy (10×3 Gy)	Terminated	Improvement of pain and paresis, visual disturbance persisted	NR
----------------------------	-----	----------	------------	-----------------------	----------------------	--	---	---	------------	---	----

**Note:** <sup>a</sup>Associated with Graves' disease. **Abbreviations:** NSCLC, non-squamous cell lung cancer; OU, both eyes; OD, right eye; OS, left eye; IV, intravenous; po, per os; IVig, intravenous immunoglobulin; NR, not reported; PLEX, plasma exchange; BID, twice daily; TID, three times daily; QID, four times daily; TED, thyroid-like eye disease.

presentation was 66.5 (9–87) years. Cutaneous melanoma was the most common indication for ICI treatment for (48/109, 44.0%), followed by non-squamous cell lung cancer (NSCLC) (19/109, 17.4%). Pembrolizumab was the most common causative agent for neuro-ophthalmic complications (35/109, 32.1%), followed by nivolumab (27/109, 24.8%), ipilimumab (23/109, 21.1%), combination of ICIs (17/109, 15.6%), and atezolizumab (4/109, 3.7%). One case was reported for each of tremelimumab, durvalumab, and sintilimab. There were no reports on neuro-ophthalmic IRAEs for dostarlimab.

The overall incidence of neuro-ophthalmic outcomes following ICI therapy was 0.46%. The median time to symptom onset was two cycles and ranged from one to 51 doses. ICIs were terminated in most patients following neuro-ophthalmic complication (67/109, 61.5%). They were held in 12 patients (11.0%) and continued in 13 patients (11.9%). Death occurred in 20 of 109 patients (18.3%) due to various causes, including worsening symptoms or other causes prior to improvement of neuro-ophthalmic symptoms. Improvement in neuro-ophthalmic symptoms with persistent deficits (eg, ptosis, diplopia) at last follow-up was seen in 45 of 109 (41.3%) patients, while 42 of 109 (38.5%) patients experienced complete resolution of neuro-ophthalmic symptoms. Outcome was not reported in two patients.

### Optic Neuritis

Optic neuritis<sup>11,23,26,30,31,34,36,39–47</sup> (n=12 case reports, n=9 in larger studies) and neuroretinitis<sup>48</sup> (n=1) have been associated with various ICIs, most commonly with ipilimumab (60%). Pharmacovigilance studies showed a combined incidence of 9/2094 (0.43%) for ICI-associated optic neuritis. Of cases that reported laterality, optic neuritis was bilateral in most cases (9/12, 75.0%). While corticosteroids form the mainstay of the treatment, four of 14 patients (28.6%) required additional interventions: intravenous immunoglobulin (IVIg), plasma exchange (PLEX), infliximab, and/or mycophenolate mofetil. All cases experienced resolution (4/14) or improvement with residual symptoms or signs (eg, visual defects, disc pallor) (10/14). Hahn and Pepple reported a patient with neuroretinitis, which involved optic disc and macular edema that resolved with topical and systemic corticosteroids.<sup>48</sup>

Patients were only confirmed to have optic neuritis if abnormalities in optic nerve enhancement were shown on MRI and clinical presentation was consistent with optic

**Table 5** Summary of Cases—Giant Cell Arteritis

Author Year Ref	Age M/F	Cancer Type	ICI Name	Cycles and Duration Before Symptoms	Neuro-Ophthalmic Diagnosis	Ophthalmic Presentation	Treatment	ICI Continued/Held/Terminated	Outcome and Follow-up Period	Follow-up Period (Months)
Betrains 2020 <sup>121</sup>	72F	Melanoma	Nivolumab	30 cycles	GCA	Blurry vision, proximal myalgia, frontal headache, temporal artery tenderness, jaw claudication	Prednisolone 1 mg/kg then taper	Held	Resolution (timeline NR)	12
Chow 2020 <sup>22</sup>	69M	Pleural mesothelioma	Nivolumab and ipilimumab	5 months (weekly treatment)	GCA	1st visit: blurry vision, fatigue, myalgia; 2nd visit: diplopia, scalp tenderness, jaw claudication; 3rd visit: transient amaurosis fugax	High dose prednisolone	Terminated at 8 months	Resolution (4 days)	10
Goldstein 2014 <sup>23</sup>	62M	Melanoma	Ipiimumab	5 cycles: then 1 week	GCA	Transient diplopia, amaurosis fugax, occipital headache, scalp tenderness, jaw claudication, proximal myalgia	Prednisone 60 mg daily	Completed	Resolution (2 days)	6
Hid Cadena 2018 <sup>124</sup>	70M	Melanoma	Nivolumab or ipilimumab (clinical trial), then another ICI	9 months	GCA	Scalp tenderness, jaw claudication, proximal myalgia, no visual complaints	Prednisolone 60 mg daily then taper	Terminated, then started on another ICI	Persistence of low-grade symptoms	13
Micaily 2017 <sup>125</sup>	88F	NSCLC	Pembrolizumab	1 dose: then 1 week	GCA	OS: sudden onset blindness	High dose prednisone	Held	Resolution (timeline NR)	NR

**Abbreviations:** NSCLC, non-squamous cell lung cancer; OS, left eye; IV, intravenous; GCA, giant cell arteritis.

**Table 6** Summary of Cases— Other

Author Year Ref	Age M/F	Cancer Type	ICI Name	Cycles and Duration Before Symptoms	Neuro-Ophthalmic Diagnosis	For Myositis: EOMs Normal or Abnormal Size	Ophthalmic Presentation	Treatment	ICI Continued/ Held/ Terminated	Neuro-Ophthalmic Outcome	Follow-up Period (Months)
Maller 2018 <sup>134</sup>	74M	Epithelioid mesothelioma	Ipilimumab and nivolumab	2 ipilimumab and 5 nivolumab infusions: then 10 weeks	Opsoclonus-myoclonus-ataxia syndrome		OU: involuntary and conjugate horizontal eye movements	IV methylprednisolone 1 g daily, IVig 0.4 g/kg daily for 5 days, prednisone taper	Completed	Resolution	8 weeks
Alnabulsi 2018 <sup>130</sup>	67M	Melanoma	Ipilimumab and nivolumab	Day 10	Myositis	Normal size	OU: ptosis, ophthalmoplegia	IV methylprednisolone up to 1 g daily IVig 81 mg for 2 doses, IV infliximab 400 mg for 1 dose	Terminated	No improvement, death (cardiac arrest, multi-organ failure)	NR
Bourgeois-Vionnet 2018 <sup>126</sup>	79NR	Lung adenocarcinoma	Nivolumab	2 injections: then 1 week	Myositis	Normal size (assumed)	OU: ptosis	IVig, po corticosteroids 1 mg/kg daily for 6 months	Terminated	Resolution	6
Carrera 2017 <sup>31</sup>	68M	NSCLC	Tremelimumab and durvalumab	2 doses: then 4 days	Myositis	NR	OU: diplopia, OS: hypertropia, ptosis	60 mg prednisone then taper	Terminated	Resolution (1 month)	6
Diamantopoulos 2017 <sup>29</sup>	82M	Melanoma	Pembrolizumab	1 infusion: then 15 days	Myositis	NR	OS: ptosis, miosis, OU: diplopia	Prednisolone 75 mg, IVig 0.3 g/kg daily, plasmapheresis	Terminated	Improvement, death (respiratory failure)	34 days
Hamada 2018 <sup>28</sup>	83M	Lung adenocarcinoma	Pembrolizumab	2 cycles: then 1 week	Myositis	NR	OD: ptosis	Systemic prednisone 40 mg/day	Terminated	Resolution	2
Hellman 2019 <sup>127</sup>	83M	Urothelial carcinoma	Pembrolizumab	2 cycles	Myositis	NR	OU: ptosis, ophthalmoplegia	Prednisone 1 mg/kg daily, later IV methylprednisolone	Terminated	Improvement, death (pneumothorax)	33 days
Kang 2018 <sup>133</sup>	75M	HNSCC	Nivolumab	1 infusion: then 3 weeks	Myositis	Normal size (assumed)	OU: ptosis	IV methylprednisolone 80 mg daily for 3 weeks, then prednisone 100 mg daily, plasmapheresis, a trial of pyridostigmine 60 mg	Terminated	No improvement, death (cardiac arrest)	2

(Continued)

Table 6 (Continued).

Author Year Ref	Age M/F	Cancer Type	ICI Name	Cycles and Duration Before Symptoms	Neuro-Ophthalmic Diagnosis	For Myositis: EOMs Normal or Abnormal Size	Ophthalmic Presentation	Treatment	ICI Continued/Held/Terminated	Neuro-Ophthalmic Outcome	Follow-up Period (Months)
Khoo 2019 <sup>32</sup>	80F	Urothelial cancer	Atezolizumab	8 weeks	Myositis	Normal size (assumed)	OU: ptosis	IV methylprednisolone 1 g daily for 3 days, IVlg 2 g/kg total dose, po prednisolone slow taper	Terminated	Improvement with residual ptosis	3
Kao 2017 <sup>38</sup>	Age NR, F	Leiomyosarcoma	Nivolumab	3 cycles	Internuclear ophthalmoplegia		OU: internuclear ophthalmoplegia	Corticosteroid (dose NR) for 1 week	Continued	Improvement	NR
Mancone 2018 <sup>24</sup>	75M	Lung squamous cell carcinoma	Nivolumab	3 cycles	Oculomotor nerve palsy		OU: diplopia, OD: ptosis	Prednisone taper	Terminated	Resolution	NR

**Abbreviations:** NSCLC, non-squamous cell lung cancer; HNSCC, head and neck squamous cell carcinoma; OU, both eyes; OD, right eye; OS, left eye; IV, intravenous; po, per os; IVlg, intravenous immunoglobulin; NR, not reported; PLEX, plasma exchange; BID, twice daily; TID, three times daily; QID, four times daily; TED, thyroid-like eye disease.

Table 7 Breakdown of Neuro-ophthalmic Diagnoses. Excludes Pharmacovigilance or Observational Trials That Do Not Include Details of the Patients

Neuro-ophthalmic primary diagnosis	N	% of Total (n=109)
Optic neuritis	14	12.8
Neuroretinitis	1	0.9
Myasthenia gravis*	49	45.0
Lambert-Eaton myasthenic syndrome gravis*	1	0.9
Orbital myositis	15	13.8
Thyroid-like eye disease	13	11.9
Giant cell arteritis	4	3.7
General myositis*	8	7.3
Internuclear ophthalmoplegia	1	0.9
opsoclonus-myooclonus-ataxia syndrome	1	0.9
Oculomotor nerve palsy	1	0.9

**Note:** \*With ocular involvement.

neuritis as highlighted in a previous paper.<sup>49</sup> This could not be confirmed for several cases.<sup>26,41,44,45</sup>

### Neuromuscular Disorders

The most common disorder of neuromuscular transmission reported with ICI was MG. Only one case of Lambert–Eaton Myasthenic Syndrome (LEMS) occurred with nivolumab, with symptoms improving with amifampridine.<sup>50</sup> Forty-nine case reports of MG were found in the literature.<sup>51–96</sup> Pharmacovigilance studies suggested that ICI-associated MG has a combined incidence of 303/64,828 (0.47%).<sup>25,28,35</sup> However, milder cases of MG may be underdiagnosed due to nonspecific symptoms such as weakness and fatigue. While few cases involved exacerbation of underlying MG (4/49, 8.2%), the rest were de novo (45/49, 91.8%).

Among the 49 cases, most (38/49, 77.6%) occurred with anti-PD-1 (eg, pembrolizumab, nivolumab). Pharmacovigilance studies also supported that MG occurred more commonly in anti-PD-1 (eg, pembrolizumab or nivolumab) or anti-PD-L1 (eg, atezolizumab) compared to anti-CTLA-4 (eg, ipilimumab) therapy (ROR: 3.9, 95%CI: 2.3–6.8).<sup>28</sup> Suzuki et al found no cases of MG with ipilimumab.<sup>35</sup>

There was a shorter time to onset (median 29 days) for ICI-associated MG compared to other neurologic IRAEs (61–80 days).<sup>25</sup> The median number of cycles prior to symptom onset amongst all cases was two cycles and ranged from three days after the first dose to three months

after the sixth dose. The neuro-ophthalmic symptoms of MG included ptosis and diplopia. In comparison to idiopathic MG, ICI-associated MG patients were more likely to experience bulbar symptoms, specifically dysphagia, dysarthria, and dyspnea, as well as myasthenic crisis.<sup>35</sup> ICI-associated MG was also more frequently associated with undetectable or lower acetylcholine receptor antibodies compared to idiopathic MG.<sup>28,97,98</sup>

ICI-associated MG overlapped with myositis (myalgia and/or elevated creatine kinase, CK) in 24 of 49 cases (49.0%). These results were lower than findings in larger studies—MG was associated with myositis in 85% and myocarditis in 8% of patients.<sup>28</sup> There may be an underdiagnosis of concurrent myositis as many cases with elevated CK levels were not formally assessed. Few studies performed skeletal muscle biopsy, but five of seven tested patients had inflammatory infiltrates.<sup>28</sup>

ICI-associated MG presented with a more common life-threatening fulminant presentation than idiopathic MG.<sup>28</sup> Myasthenic crisis had a weighted incidence of 35/78 (46.7%) in larger studies.<sup>28,35</sup> In contrast, idiopathic MG has around 15% to 20% lifetime risk of myasthenic crisis in the literature.<sup>99</sup> Median onset from presentation to respiratory failure requiring intubation was one week for ICI-associated MG.<sup>28</sup>

A wide spectrum of clinical severity existed for MG, however, aggressive treatment led to improvement of symptoms in 55.5% and complete remission in 18.9% of patients in larger studies.<sup>28,35</sup> While corticosteroids are appropriate for MG, IVIg or PLEX used as a first-line therapy for patients presenting with severe respiratory or bulbar symptoms showed better MG outcomes compared to those who received steroids alone (95% vs 63% symptom improvement).<sup>28</sup> However, none of those who had respiratory failure following first-line corticosteroids showed clinical improvement with secondary IVIg or PLEX, unlike patients with idiopathic MG.<sup>28</sup>

A fatality rate of 19.8% (70/354) was found in case reports and larger studies.<sup>25,28,35</sup> Outcomes were worse in patients with concurrent myositis and/or myocarditis, with highest mortality in patients with both (5/8, 62.5%) compared with MG alone (29/179, 16.2%), or with myositis only (6/29; 20.7%).<sup>25,28</sup> Overall, complete recovery of MG symptoms occurred in (28/123, 22.8%) of patients. Most patients were maintained on prolonged steroid tapers and showed improvement (63/123, 51.2%).

## Orbital Disorders

ICIs were associated with both thyroid-like eye disease (TED)<sup>100–108</sup> (n=10) and idiopathic orbital myositis<sup>103,109–119</sup> (n=16). TED may develop in patients on ipilimumab, nivolumab, pembrolizumab, or tremelimumab, even in the absence of existing thyroid dysfunction. In TED, patients generally presented with proptosis, chemosis, and thickening of extra-ocular muscles. They were associated with Graves' disease in 6/10 (60%) of case reports. Labs usually showed abnormal thyroid function, but up to 5% of patients with TED can be euthyroid or hypothyroid.<sup>107</sup> Orbital myositis occurred in 15 patients, either from pembrolizumab or ipilimumab with or without nivolumab therapy. The median number of cycles prior to onset of symptoms for TED and myositis was three doses and ranged from one to 51 doses. In TED, orbital imaging showed thickening and enlargement of extraocular muscles without involvement of tendons, while in orbital myositis, tendons were involved. For TED, 9/10 patients (90%) showed improvement or resolution of TED with systemic corticosteroids, while one patient required canthotomy/cantholysis.<sup>100</sup> Outcomes were worse for orbital myositis, with nine of 16 patients requiring additional therapy beyond systemic steroids (IVIg, methotrexate, PLEX, mycophenolate mofetil). Thirteen of 16 patients improved or experienced resolution, while two patients died from respiratory failure<sup>111,114</sup> and one did not experience improvement before dying from unknown causes.<sup>116</sup>

In addition, one case each of orbital apex syndrome<sup>120</sup> and Tolosa–Hunt syndrome<sup>22</sup> occurred with ipilimumab. The former presented with painless vision loss, ptosis, ophthalmoplegia as a result of simultaneous dysfunction of the optic nerve and cranial nerves, and showed improvement on systemic steroids, albeit with persistent esotropia.<sup>120</sup> The latter presented with severe unilateral periorbital pain and ophthalmoplegia, which improved with systemic steroids and local radiotherapy.<sup>22</sup>

## Giant Cell Arteritis (GCA)

Five cases of GCA were reported following nivolumab, ipilimumab, combination of both, or pembrolizumab with one to 30 cycles of therapy.<sup>121–125</sup> Patients presented similar to idiopathic GCA with blurry vision, diplopia, transient vision loss, along with headache, scalp tenderness, and jaw claudication. One patient presented with sudden onset loss of vision alone, while another had no visual symptoms.<sup>124,125</sup> Three of five cases also had polymyalgia rheumatica.<sup>121,123,124</sup> Most cases resolved with discontinuation of ICI and high-dose corticosteroids between two



and four days, while one case persisted with low-grade symptoms and worsened upon starting another ICI.<sup>124</sup> No larger trials existed to evaluate incidence of ICI-associated GCA.

## Other Neuro-ophthalmic Disorders

Eight cases of generalized myositis with ptosis were reported in literature, most commonly following pembrolizumab therapy (3/8, 37.5%).<sup>126–133</sup> A high rate of mortality was seen with general myositis (4/8, 50%). The remaining cases improved or resolved with corticosteroids alone or with IVIg. Other neuro-ophthalmic disorders included one case of oculomotor nerve palsy in 526 patients receiving nivolumab.<sup>24</sup> This followed three cycles of nivolumab and resolved with a prednisone taper. Another study showed one case of bilateral internuclear ophthalmoplegia following nivolumab of 347 patients, which also improved with corticosteroids.<sup>38</sup> One case of opsoclonus-myoclonus-ataxia syndrome was reported following ipilimumab and nivolumab therapy, which resolved with systemic corticosteroids and IVIg.<sup>134</sup>

## Discussion

Neuro-ophthalmic complications may occur in patients being treated with ICIs. These include afferent disorders including optic neuritis, neuroretinitis, and GCA, and efferent disorders such as TED, MG, LEMS, orbital apex syndrome, oculomotor nerve palsy, orbital myositis, myositis with ptosis, Tolosa–Hunt Syndrome, and bilateral internuclear ophthalmoplegia. In general, ICIs may be held or discontinued for neuro-ophthalmic IRAEs, this decision should be made in consultation with the oncology team and appropriate guidelines, in particular, for more common IRAEs such as myasthenia gravis and myositis.<sup>13,135</sup> Almost all patients require initial therapy with high-dose corticosteroids and may require other immunomodulatory therapy. Most afferent visual disorders (12/20, 60.0%) were treated with intravenous corticosteroids while others were treated orally. Out of all the afferent and efferent complications, four of 20 (20.0%) and 40 of 89 (44.9%), respectively, required additional immunomodulatory therapy, most commonly single therapy of IVIg. ICI re-challenge can be considered in cases of mild symptoms that resolve. In our review, 19 cases had either continued or held and then were re-challenged with ICI. Of these cases, four had recurrence or worsening of the same IRAE.<sup>84,106,124,136</sup> In cases refractory to corticosteroids and recurrence of IRAE occurs to tapering of corticosteroids, IVIg and plasma exchange have been useful in the acute setting. Given the severity of symptoms and concern

for new neuro-ophthalmic symptoms in patients with cancer, hospitalization is often necessary in patients with severe symptoms and multidisciplinary care involving oncology, ophthalmology, neurology, and neuro-ophthalmology is often required.

While ICIs are highly effective in stimulating the immune system to lead to a robust antitumor response, our study supports existing literature that ICIs have significant IRAEs that must be properly managed. In the literature, combination therapies have been discontinued more frequently than monotherapy.<sup>137</sup> The mechanisms of induction of IRAEs is not fully elucidated, but are hypothesized to involve decreased peripheral tolerance and induction of organ-specific inflammatory processes.

In our review, several IRAEs occurred with a long duration after ICI administration and occurred with various doses and cycles of ICI. The earliest complication was TED, which arose after one dose (three days) of ipilimumab and pembrolizumab combination therapy,<sup>106</sup> while the latest complication of orbital myositis arose after 51 doses (three years) of ipilimumab.<sup>115</sup> Thus, the potential dose effects of ICIs on toxicity is difficult to determine at this time. There are key differences between neuro-ophthalmic and ophthalmic complications, our study found that neuro-ophthalmic ones were more likely to be associated with pembrolizumab, while ocular side effects were more common with ipilimumab in literature, likely due to differences in reporting adverse events between the two ICIs.<sup>14</sup> In addition, the mean age of patients with neuro-ophthalmic complications was 66.5 years, higher than the mean age of 54 years for ophthalmic complications like uveitis.<sup>46</sup> Ophthalmic complications generally had more favorable clinical outcomes compared to neuro-ophthalmic complications such as MG, which had a fatality rate of 19.8%.<sup>46</sup>

It is also unknown currently if neuro-ophthalmic IRAE severity can be used to predict treatment efficacy. An early study suggested that IRAE such as enterocolitis could signify response to treatment for metastatic melanoma,<sup>138</sup> however, other studies have shown that occurrence of IRAE did not correlate with survival outcome or ICI treatment failure.<sup>139,140</sup> Horvat et al also reported that the use of corticosteroids for IRAEs (primarily diarrhea, hepatitis, and dermatitis) did not impair overall survival in patients receiving ipilimumab for melanoma.<sup>140</sup> This finding was supported by a recent systematic review of nine studies.<sup>141</sup> There are currently a large number of novel ICIs, including two anti-CTLA-4, nine anti-PD-1, and four anti-PD-L1 currently in late-stage clinical studies for cancer indications.<sup>142</sup>



There are several limitations in this review. Data largely consisted of case series, which do not prove cause and effect between ICI and neuro-ophthalmic IRAEs. This link has not been firmly established, especially for conditions such as GCA where prevalence is higher in the patient demographics reported. We have reviewed each case to ensure that other common entities have been excluded in diagnostic consideration. Epidemiologic data on ICI complications were limited by the few number of studies that had neuro-ophthalmic complications. Some conditions may be under-reported due to nonspecific symptoms. While some diseases render a resemblance to established disorders, such as TED, it is possible that ICI-associated disorders (eg, inflammatory orbitopathy) is a distinct clinical syndrome. Future studies should aim to evaluate syndromes consistently (eg, tested for thyroid receptor antibody, thyroglobulin antibody, and thyroid peroxidase antibody). We have described misdiagnosis in previous reports of optic neuritis and emphasized the importance of proper investigations to confirm the diagnosis (eg, use of orbital MRI to detect optic nerve enhancement postgadolinium administration for optic neuritis, anti-aquaporin-4 antibodies for neuromyelitis optica).<sup>49</sup> Efforts must be made to exclude common entities.

With the growing number of ICIs and increasing number of indications, it is important for neuro-ophthalmologists to be aware of potential adverse events. Future directions will include identifying minimum active doses for ICIs to achieve antitumor responses while minimizing IRAEs. The rapid identification and initiation of immunosuppression can improve patient outcomes. A collaborative approach and open communication with oncology is necessary in management of these IRAEs.

## Funding

There is no funding to report.

## Disclosure

The authors report no conflicts of interest in this work.

## References

- Sharma P, Wagner K, Wolchok JD, Allison JP. Novel cancer immunotherapy agents with survival benefit: recent successes and next steps. *Nat Rev Cancer*. 2011;11:805–812.
- Garrett MD, Collins I. Anticancer therapy with checkpoint inhibitors: what, where and when? *Trends Pharmacol Sci*. 2011;32:308–316. doi:10.1016/j.tips.2011.02.014
- Buchbinder E, Stephen Hodi F. Cytotoxic T lymphocyte antigen-4 and immune checkpoint blockade. *J Clin Invest*. 2015;125:3377–3383. doi:10.1172/JCI80012
- Ohaegbulam KC, Assal A, Lazar-Molnar E, et al. Human cancer immunotherapy with antibodies to the PD-1 and PD-L1 pathway. *Trends Mol Med*. 2015;21:24–33. doi:10.1016/j.molmed.2014.10.009
- Michot JM, Bigenwald C, Champiat S, et al. Immune-related adverse events with immune checkpoint blockade: a comprehensive review. *Eur J Cancer*. 2016;54:139–148. doi:10.1016/j.ejca.2015.11.016
- Spain L, Diem S, Larkin J. Management of toxicities of immune checkpoint inhibitors. *Cancer Treat Rev*. 2016;44:51–60. doi:10.1016/j.ctrv.2016.02.001
- Cousin S, Italiano A. Molecular pathways: immune checkpoint antibodies and their toxicities. *Clin Cancer Res*. 2016;22:4550–4555. doi:10.1158/1078-0432.CCR-15-2569
- Bertrand A, Kostine M, Barnette T, et al. Immune related adverse events associated with anti-CTLA-4 antibodies: systematic review and meta-analysis. *BMC Med*. 2015;13. doi:10.1186/s12916-015-0455-8
- Puwanant A, Isfort M, Lacomis D, Živković SA. Clinical spectrum of neuromuscular complications after immune checkpoint inhibition. *Neuromuscul Disord*. 2019;29:127–133. doi:10.1016/j.nmd.2018.11.012
- Antoun J, Titah C, Cochereau I. Ocular and orbital side-effects of checkpoint inhibitors: a review article. *Curr Opin Oncol*. 2016;28:288–294. doi:10.1097/CCO.0000000000000296
- Noble CW, Gangaputra SS, Thompson IA, et al. Ocular adverse events following use of immune checkpoint inhibitors for metastatic malignancies. *Ocul Immunol Inflamm*. 2020;28(6):854–859. doi:10.1080/09273948.2019.1583347
- Cunningham ET, Moorthy RS, Zierhut M. Immune checkpoint inhibitor-induced uveitis. *Ocul Immunol Inflamm*. 2020;28:847–849. doi:10.1080/09273948.2020.1801286
- Brahmer JR, Lacchetti C, Schneider BJ, et al. Management of immune-related adverse events in patients treated with immune checkpoint inhibitor therapy: american society of clinical oncology clinical practice guideline. *J Clin Oncol*. 2018;36:1714–1768. doi:10.1200/JCO.2017.77.6385
- Dalvin LA, Shields CL, Orloff M, et al. Checkpoint inhibitor immune therapy. *Retina*. 2018;38:1063–1078. doi:10.1097/IAE.0000000000002181
- Pan PCW, Haggiagi A. Neurologic immune-related adverse events associated with immune checkpoint inhibition. *Curr Oncol Rep*. 2019;21. doi:10.1007/s11912-019-0859-2
- Möhn N, Beutel G, Gutzmer R, et al. Neurological immune related adverse events associated with nivolumab, ipilimumab, and pembrolizumab therapy—review of the literature and future outlook. *J Clin Med*. 2019;8:1777. doi:10.3390/jcm8111777
- Haugh AM, Probasco JC, Johnson DB. Neurologic complications of immune checkpoint inhibitors. *Expert Opin Drug Saf*. 2020;19:479–488. doi:10.1080/14740338.2020.1738382
- Higgins JPT GS, editors. *Cochrane Handbook for Systematic Reviews of Interventions Version 5.1.0*. Cochrane Collab; 2011.
- Liberati A, Altman DG, Tetzlaff J, et al. The PRISMA statement for reporting systematic reviews and meta-analyses of studies that evaluate healthcare interventions: explanation and elaboration. *BMJ*. 2009;339:b2700–b2700. doi:10.1136/bmj.b2700
- Veritas Health Innovation. Covidence systematic review software. 2019. Available from: [www.covidence.org](http://www.covidence.org). Accessed September 27, 2020.
- Camacho LH, Antonia S, Sosman J, et al. Phase I/II trial of tremelimumab in patients with metastatic melanoma. *J Clin Oncol*. 2009;27:1075–1081. doi:10.1200/JCO.2008.19.2435
- Voskens CJ, Goldinger SM, Loqui C, et al. The price of tumor control: an analysis of rare side effects of anti-CTLA-4 therapy in metastatic melanoma from the ipilimumab network. *PLoS One*. 2013;8:e53745. doi:10.1371/journal.pone.0053745

23. Kaur A, Doberstein T, Amberker RR, et al. Immune-related adverse events in cancer patients treated with immune checkpoint inhibitors: a single-center experience. *Med*. 2019;98.
24. Mancone S, Lycan T, Ahmed T, et al. Severe neurologic complications of immune checkpoint inhibitors: a single-center review. *J Neurol*. 2018;265:1636–1642. doi:10.1007/s00415-018-8890-z
25. Johnson DB, Manouchehri A, Haugh AM, et al. Neurologic toxicity associated with immune checkpoint inhibitors: a pharmacovigilance study. *J Immunother Cancer*. 2019;7:134. doi:10.1186/s40425-019-0617-x
26. Kim JM, Materin MA, Sznol M, et al. Ophthalmic immune-related adverse events of immunotherapy: a single-site case series. *Ophthalmology*. 2019;126:1058–1062. doi:10.1016/j.ophtha.2019.01.031
27. Moreira A, Loquai C, Pfoehler C, et al. Myositis and neuromuscular side-effects induced by immune checkpoint inhibitors. *Eur J Cancer*. 2019;106:12–23. doi:10.1016/j.ejca.2018.09.033
28. Safa H, Johnson DH, Trinh VA, et al. Immune checkpoint inhibitor related myasthenia gravis: single center experience and systematic review of the literature. *J Immunother Cancer*. 2019;7:319. doi:10.1186/s40425-019-0774-y
29. Seki M, Uruha A, Ohnuki Y, et al. Inflammatory myopathy associated with PD-1 inhibitors. *J Autoimmun*. 2019;100:105–113. doi:10.1016/j.jaut.2019.03.005
30. Williams KJ, Grauer DW, Henry DW, Rockey ML. Corticosteroids for the management of immune-related adverse events in patients receiving checkpoint inhibitors. *J Oncol Pharm Pract*. 2019;25:544–550. doi:10.1177/1078155217744872
31. Weber JS, Kudchadkar RR, Yu B, et al. Safety, efficacy, and biomarkers of nivolumab with vaccine in ipilimumab-refractory or -naive melanoma. *J Clin Oncol*. 2013;31:4311–4318. doi:10.1200/JCO.2013.51.4802
32. Hodi FS, Lawrence D, Lezcano C, et al. Bevacizumab plus ipilimumab in patients with metastatic melanoma. *Cancer Immunol Res*. 2014;2:632–642. doi:10.1158/2326-6066.CIR-14-0053
33. Balar AV, Castellano D, O'Donnell PH, et al. First-line pembrolizumab in cisplatin-ineligible patients with locally advanced and unresectable or metastatic urothelial cancer (KEYNOTE-052): a multicentre, single-arm, phase 2 study. *Lancet Oncol*. 2017;18:1483–1492. doi:10.1016/S1470-2045(17)30616-2
34. Diehl A, Yarchoan M, Hopkins A, et al. Relationships between lymphocyte counts and treatment-related toxicities and clinical responses in patients with solid tumors treated with PD-1 checkpoint inhibitors. *Oncotarget*. 2017;8:114268–114280. doi:10.18632/oncotarget.23217
35. Suzuki S, Ishikawa N, Konoeda F, et al. Nivolumab-related myasthenia gravis with myositis and myocarditis in Japan. *Neurology*. 2017;89:1127–1134. doi:10.1212/WNL.00000000000004359
36. Omuro A, Vlahovic G, Lim M, et al. Nivolumab with or without ipilimumab in patients with recurrent glioblastoma: results from exploratory Phase I cohorts of CheckMate 143. *Neuro Oncol*. 2018;20:674–686. doi:10.1093/neuonc/nox208
37. Touat M, Maisonobe T, Knauss S, et al. Immune checkpoint inhibitor-related myositis and myocarditis in patients with cancer. *Neurology*. 2018;91:e985–e994. doi:10.1212/WNL.00000000000006124
38. Kao JC, Liao B, Markovic SN, et al. Neurological complications associated with anti-programmed death 1 (PD-1) antibodies. *JAMA Neurol*. 2017;74:1216–1222. doi:10.1001/jamaneurol.2017.1912
39. Boisseau W, Touat M, Berzero G, et al. Safety of treatment with nivolumab after ipilimumab-related meningoradiculitis and bilateral optic neuropathy. *Eur J Cancer*. 2017;83:28–31. doi:10.1016/j.ejca.2017.05.036
40. Francis JH, Jaben K, Santomasso BD, et al. Immune checkpoint inhibitor associated optic neuritis. *Ophthalmology*. 2020.
41. Yeh OL, Francis CE. Ipilimumab-associated bilateral optic neuropathy. *J Neuro-Ophthalmology*. 2015;35:144–147.
42. Kartal Ö, Ataş E. Bilateral optic neuritis secondary to nivolumab therapy: a case report. *Med*. 2018;54:82.
43. Mori S, Kurimoto T, Ueda K, et al. Optic neuritis possibly induced by anti-PD-L1 antibody treatment in a patient with non-small cell lung carcinoma. *Case Rep Ophthalmol*. 2018;9:348–356. doi:10.1159/000491075
44. Samanci NS, Ozan T, Çelik E, Demirelli FH. Optic neuritis related to atezolizumab treatment in a patient with metastatic non-small-cell lung cancer. *JCO Oncol Pract*. 2020;16:96–98. doi:10.1200/JOP.19.00438
45. Sun J, Schiffman J, Raghunath A, et al. Concurrent decrease in IL-10 with development of immune-related adverse events in a patient treated with anti-CTLA-4 therapy. *Cancer Immun*. 2008;8:9.
46. Sun MM, Levinson RD, Filipowicz A, et al. Uveitis in patients treated with CTLA-4 and PD-1 checkpoint blockade inhibition. *Ocul Immunol Inflamm*. 2020;28:217–227. doi:10.1080/09273948.2019.1577978
47. Wilson MA, Guld K, Galetta S, et al. Acute visual loss after ipilimumab treatment for metastatic melanoma. *J Immunother Cancer*. 2016;4. doi:10.1186/s40425-016-0170-9
48. Hahn L, Pepple KL. Bilateral neuroretinitis and anterior uveitis following ipilimumab treatment for metastatic melanoma. *J Ophthalmic Inflamm Infect*. 2016;6. doi:10.1186/s12348-016-0082-3
49. Micieli JA, Margolin E. Re: Francis et al.: immune checkpoint inhibitor associated optic neuritis (Ophthalmology. 2020 May 8 [Epub ahead of print]). *Ophthalmology*. 2020. doi:10.1016/j.ophtha.2020.05.043
50. Nakatani Y, Tanaka N, Enami T, et al. Lambert-Eaton Myasthenic syndrome caused by Nivolumab in a patient with squamous cell lung cancer. *Case Rep Neurol*. 2018;10:346–352. doi:10.1159/000494078
51. Algaee M, Mukharesh L, Heinzelmann M, Kaminski HJ. Pearls & Oy-sters: pembrolizumab-induced myasthenia gravis. *Neurology*. 2018;91:E1365–E1367. doi:10.1212/WNL.0000000000006278
52. Alnahhas I, Wong J. A case of new-onset antibody-positive myasthenia gravis in a patient treated with pembrolizumab for melanoma. *Muscle Nerve*. 2017;55:E25–E26. doi:10.1002/mus.25496
53. Fazel M, Jedlowski PM. Severe myositis, myocarditis, and myasthenia gravis with elevated anti-striated muscle antibody following single dose of ipilimumab-nivolumab therapy in a patient with metastatic melanoma. *Case Reports Immunol*. 2019;2019:1–3. doi:10.1155/2019/2539493
54. Fellner A, Makranz C, Lotem M, et al. Neurologic complications of immune checkpoint inhibitors. *J Neurooncol*. 2018;137:601–609. doi:10.1007/s11060-018-2752-5
55. Fukasawa Y, Sasaki K, Natsume M, et al. Nivolumab-induced myocarditis concomitant with myasthenia gravis. *Case Rep Oncol*. 2017;10:809–812. doi:10.1159/000479958
56. Gonzalez NL, Puwanant A, Lu A, et al. Myasthenia triggered by immune checkpoint inhibitors: new case and literature review. *Neuromuscul Disord*. 2017;27:266–268. doi:10.1016/j.nmd.2017.01.002
57. Hasegawa Y, Kawai S, Ota T, et al. Myasthenia gravis induced by nivolumab in patients with non-small-cell lung cancer: a case report and literature review. *Immunotherapy*. 2017;9:701–707. doi:10.2217/imt-2017-0043
58. Hibino M, Maeda K, Horiuchi S, et al. Pembrolizumab-induced myasthenia gravis with myositis in a patient with lung cancer. *Respirol Case Reports*. 2018;6:e00355. doi:10.1002/rcr2.355

59. Huh SY, Shin SH, Kim MK, et al. Emergence of myasthenia gravis with myositis in a patient treated with pembrolizumab for thymic cancer. *J Clin Neurol*. 2018;14:115–117. doi:10.3988/jcn.2018.14.1.115
60. Johnson DB, Saranga-Perry V, Lavin PJM, et al. Myasthenia gravis induced by ipilimumab in patients with metastatic melanoma. *J Clin Oncol*. 2015;33:e122–e124. doi:10.1200/JCO.2013.51.1683
61. Kim JS, Nam TS, Kim J, et al. Myasthenia gravis and myopathy after nivolumab treatment for non-small cell lung carcinoma: a case report. *Thorac Cancer*. 2019;10:2045–2049.
62. Konstantina T, Konstantinos R, Anastasios K, et al. Fatal adverse events in two thymoma patients treated with anti-PD-1 immune check point inhibitor and literature review. *Lung Cancer*. 2019;135:29–32. doi:10.1016/j.lungcan.2019.06.015
63. Becquart O, Lacotte J, Malissart P, et al. Myasthenia gravis induced by immune checkpoint inhibitors. *J Immunother*. 2019;42:309–312. doi:10.1097/CJI.0000000000000278
64. Lara MS, Afify A, Ellis MP, et al. Immune checkpoint inhibitor-induced myasthenia gravis in a patient with advanced NSCLC and remote history of thymoma. *Clin Lung Cancer*. 2019;20:e489–e491. doi:10.1016/j.clcc.2019.04.007
65. Lau KHV, Kumar A, Yang IH, Nowak RJ. Exacerbation of myasthenia gravis in a patient with melanoma treated with pembrolizumab. *Muscle Nerve*. 2016;54:157–161.
66. Liao B, Shroff S, Kamiya-Matsuoka C, Tummala S. Atypical neurological complications of ipilimumab therapy in patients with metastatic melanoma. *Neuro Oncol*. 2014;16:589–593. doi:10.1093/neuonc/nou001
67. Liu Q, Ayyappan S, Broad A, Narita A. Pembrolizumab-associated ocular myasthenia gravis. *Clin Experiment Ophthalmol*. 2019;47:ce0.13499. doi:10.1111/ceo.13499
68. Loochtan AI, Nickolich MS, Hobson-Webb LD. Myasthenia gravis associated with ipilimumab and nivolumab in the treatment of small cell lung cancer. *Muscle Nerve*. 2015;52:307–308. doi:10.1002/mus.24648
69. Maeda O, Yokota K, Atsuta N, et al. Nivolumab for the treatment of malignant melanoma in a patient with pre-existing myasthenia gravis. *Nagoya J Med Sci*. 2016;78:119–122.
70. Mancano MA, Von BJE, Ro M. ISMP adverse drug reactions: lithium-induced cardiomyopathy fixed drug eruption due to cetirizine, levocetirizine, and hydroxyzine nivolumab-induced myasthenia gravis nivolumab-induced cholangitic liver disease torsade de pointes caused by psychiatric polypharmacy trichotilomania associated with aripiprazole. *Hosp Pharm*. 2018;53:371–375.
71. March KL, Samarin MJ, Sodhi A, Owens RE. Pembrolizumab-induced myasthenia gravis: a fatal case report. *J Oncol Pharm Pract*. 2018;24:146–149. doi:10.1177/1078155216687389
72. Mitsune A, Yanagisawa S, Fukuhara T, et al. Relapsed myasthenia gravis after nivolumab treatment. *Intern Med*. 2018;57:1893–1897. doi:10.2169/internalmedicine.9153-17
73. Möhn N, Sühs KW, Gingele S, et al. Acute progressive neuropathy-myositis-myasthenia-like syndrome associated with immune-checkpoint inhibitor therapy in patients with metastatic melanoma. *Melanoma Res*. 2019;29:435–440.
74. Chang E, Sabichi AL, Sada YH. Myasthenia gravis after nivolumab therapy for squamous cell carcinoma of the bladder. *J Immunother*. 2017;40:114–116. doi:10.1097/CJI.0000000000000161
75. Montes V, Sousa S, Pita F, et al. Myasthenia gravis induced by ipilimumab in a patient with metastatic melanoma. *Front Neurol*. 2018;9:150. doi:10.3389/fneur.2018.00150
76. Nguyen BHV, Kuo J, Budiman A, et al. Two cases of clinical myasthenia gravis associated with pembrolizumab use in responding melanoma patients. *Melanoma Res*. 2017;27:152–154. doi:10.1097/CMR.0000000000000310
77. Onda A, Miyagawa S, Takahashi N, et al. Pembrolizumab-induced ocular Myasthenia Gravis with anti-titin antibody and necrotizing myopathy. *Intern Med*. 2019;58:1635–1638. doi:10.2169/internalmedicine.1956-18
78. Phua CS, Murad A, Fraser C, et al. Myasthenia gravis and concurrent myositis following PD-L1 checkpoint inhibitor for non-small cell lung cancer. *BMJ Neurol Open*. 2020;2:e000028. doi:10.1136/bmjno-2019-000028
79. Polat P, Donofrio PD. Myasthenia gravis induced by nivolumab therapy in a patient with non-small-cell lung cancer. *Muscle Nerve*. 2016;54:507. doi:10.1002/mus.25163
80. Sciacca G, Nicoletti A, Rampello L, et al. Benign form of myasthenia gravis after nivolumab treatment. *Muscle Nerve*. 2016;54:507–509. doi:10.1002/mus.25212
81. So H, Ikeguchi R, Kobayashi M, et al. PD-1 inhibitor-associated severe myasthenia gravis with necrotizing myopathy and myocarditis. *J Neurol Sci*. 2019;399:97–100.
82. Takai M, Kato D, Iinuma K, et al. Simultaneous pembrolizumab-induced myasthenia gravis and myocarditis in a patient with metastatic bladder cancer: a case report. *Urol Case Reports*. 2020;31:101145.
83. Tan RYC, Toh CK, Takano A. Continued response to one dose of nivolumab complicated by myasthenic crisis and myositis. *J Thorac Oncol*. 2017;12:e90–e91. doi:10.1016/j.jtho.2017.02.024
84. Tedbirt B, De Pontville M, Branger P, et al. Rechallenge of immune checkpoint inhibitor after pembrolizumab-induced myasthenia gravis. *Eur J Cancer*. 2019;113:72–74. doi:10.1016/j.ejca.2019.03.006
85. Chen JH, Lee KY, Hu CJ, Chung CC. Coexisting myasthenia gravis, myositis, and polyneuropathy induced by ipilimumab and nivolumab in a patient with non-small-cell lung cancer: a case report and literature review. *Med*. 2017;96.
86. Thakolwiboon S, Karukote A, Wilms H. De novo myasthenia gravis induced by atezolizumab in a patient with urothelial carcinoma. *Ann Neurol*. 2019;86:S109–S110.
87. Tozuka T, Sugano T, Noro R, et al. Pembrolizumab-induced agranulocytosis in a pulmonary pleomorphic carcinoma patient who developed interstitial lung disease and ocular myasthenia gravis. *Oxford Med Case Reports*. 2018;11:398–402.
88. Veccia A, Kinspergher S, Grego E, et al. Myositis and myasthenia during nivolumab administration for advanced lung cancer: a case report and review of the literature. *Anticancer Drugs*. 2020;31:540–544. doi:10.1097/CAD.0000000000000903
89. Werner J-M, Schweinsberg V, Schroeter M, et al. Successful treatment of myasthenia gravis following PD-1/CTLA-4 combination checkpoint blockade in a patient with metastatic melanoma. *Front Oncol*. 2019;9:84. doi:10.3389/fonc.2019.00084
90. Xing Q, Zhang Z-W, Lin Q-H, et al. Myositis-myasthenia gravis overlap syndrome complicated with myasthenia crisis and myocarditis associated with anti-programmed cell death-1 (sintilimab) therapy for lung adenocarcinoma. *Ann Transl Med*. 2020;8:250. doi:10.21037/atm.2020.01.79
91. Wilson R, Menassa DA, Davies AJ, et al. Seronegative antibody-mediated neurology after immune checkpoint inhibitors. *Ann Clin Transl Neurol*. 2018;5:640–645. doi:10.1002/acn3.547
92. Chen YH, Liu FC, Hsu CH, Chian CF. Nivolumab-induced myasthenia gravis in a patient with squamous cell lung carcinoma. *Med*. 2017;96.
93. Cooper DS, Meriggioli MN, Bonomi PD, Malik R. Severe exacerbation of myasthenia gravis associated with checkpoint inhibitor immunotherapy. *J Neuromuscul Dis*. 2017;4:169–173. doi:10.3233/JND-170219
94. Crusz SM, Radunovic A, Shepherd S, et al. Rituximab in the treatment of pembrolizumab-induced myasthenia gravis. *Eur J Cancer*. 2018;102:49–51. doi:10.1016/j.ejca.2018.07.125



95. Dhenin A, Samartzis V, Lejeune S, Seront E. Cascade of immunologic adverse events related to pembrolizumab treatment. *BMJ Case Rep.* 2019;12:e229149. doi:10.1136/bcr-2018-229149
96. Earl DE, Loochtan AI, Bedlack RS. Refractory myasthenia gravis exacerbation triggered by pembrolizumab. *Muscle Nerve.* 2018;57:E120–E121. doi:10.1002/mus.26021
97. Kolb NA, Trevino CR, Waheed W, et al. Neuromuscular complications of immune checkpoint inhibitor therapy. *Muscle Nerve.* 2018;58:10–22. doi:10.1002/mus.26070
98. Psimaras D, Velasco R, Birzu C, et al. Immune checkpoint inhibitors-induced neuromuscular toxicity: from pathogenesis to treatment. *J Peripher Nerv Syst.* 2019;24:S74–S85. doi:10.1111/jns.12339
99. Wendell LC, Levine JM. Myasthenic crisis. *Neurohospitalist.* 2011;1:16–22. doi:10.1177/1941875210382918
100. Borodic G, Hinkle DM, Cia Y. Drug-induced graves disease from CTLA-4 receptor suppression. *Ophthalmic Plast Reconstr Surg.* 2011;27:e87–e88. doi:10.1097/IOP.0b013e3181ef72a1
101. Campredon P, Imbert P, Mouly C, et al. Severe inflammatory ophthalmopathy in a euthyroid patient during nivolumab treatment. *Eur Thyroid J.* 2018;7:84–87. doi:10.1159/000485742
102. Ricciuti B, Metro G, Baglivo S, et al. Long-lasting response to nivolumab and immune-related adverse events in a nonsquamous metastatic non-small cell lung cancer patient. *J Thorac Oncol.* 2017;12:e51–e55. doi:10.1016/j.jtho.2016.12.027
103. Sagiv O, Kandl TJ, Thakar SD, et al. Extraocular muscle enlargement and thyroid eye disease-like orbital inflammation associated with immune checkpoint inhibitor therapy in cancer patients. *Ophthal Plast Reconstr Surg.* 2019;35:50–52. doi:10.1097/IOP.0000000000001161
104. McElnea E, Á NM, Moran S, et al. Thyroid-like ophthalmopathy in a euthyroid patient receiving Ipilimumab. *Orbit.* 2014;33:424–427. doi:10.3109/01676830.2014.949792
105. Min L, Vaidya A, Becker C. Thyroid autoimmunity and ophthalmopathy related to melanoma biological therapy. *Eur J Endocrinol.* 2011;164:303–307. doi:10.1530/EJE-10-0833
106. Rhea L, Yoon JW, Jang S. Rapid development of Graves' ophthalmopathy after treatment with ipilimumab and recurrence with pembrolizumab in a patient with previously treated Graves' disease. *J Oncol Pract.* 2018;14:747–749. doi:10.1200/JOP.18.00442
107. Park ESY, Rabinowits G, Hamnvik OPR, Dagi LR. A case of Graves' ophthalmopathy associated with pembrolizumab (Keytruda) therapy. *J AAPOS.* 2018;22:310–312. doi:10.1016/j.jaapos.2018.01.006
108. Sabini E, Sframeli A, Marinò M. A case of drug-induced Graves' Orbitopathy after combination therapy with Tremelimumab and Durvalumab. *J Endocrinol Invest.* 2018;41:877–878. doi:10.1007/s40618-018-0906-0
109. Bitton K, Michot JM, Barreau E, et al. Prevalence and Clinical patterns of ocular complications associated with anti-PD-1/PD-L1 anticancer immunotherapy. *Am J Ophthalmol.* 2019;202:109–117. doi:10.1016/j.ajo.2019.02.012
110. Patel D, Tremont A, Fuloria J. Orbital myositis secondary to cytotoxic T-lymphocyte-associated protein 4 antibody – a case report. *Clin Oncol.* 2016;1:1149.
111. Haddox CL, Shenoy N, Shah KK, et al. Pembrolizumab induced bulbar myopathy and respiratory failure with necrotizing myositis of the diaphragm. *Ann Oncol.* 2017;28:673–675. doi:10.1093/annonc/mdw655
112. Henderson AD, Thomas DA. A case report of orbital inflammatory syndrome secondary to ipilimumab. *Ophthal Plast Reconstr Surg.* 2015;31:e68–e70. doi:10.1097/IOP.0000000000000081
113. Kamo H, Hatano T, Kanai K, et al. Pembrolizumab-related systemic myositis involving ocular and hindneck muscles resembling myasthenic gravis: A case report. *BMC Neurol.* 2019;19:184. doi:10.1186/s12883-019-1416-1
114. Liewluck T, Kao JC, Mauermann ML. PD-1 inhibitor-associated myopathies: emerging immune-mediated myopathies. *J Immunother.* 2018;41:208–211. doi:10.1097/CJI.0000000000000196
115. Nardin C, Borot S, Beaudoin MA, et al. Long-term adverse event: inflammatory orbitopathy induced by pembrolizumab in a patient with metastatic melanoma. *Invest New Drugs.* 2019;37:375–377. doi:10.1007/s10637-018-0659-9
116. Nasr F, El Rassy E, Maalouf G, et al. Severe ophthalmoplegia and myocarditis following the administration of pembrolizumab. *Eur J Cancer.* 2018;91:171–173. doi:10.1016/j.ejca.2017.11.026
117. Pushkarevskaya A, Neuberger U, Dimitrakopoulou-Strauss A, et al. Severe ocular myositis after ipilimumab treatment for melanoma: a report of 2 cases. *J Immunother.* 2017;40:282–285. doi:10.1097/CJI.0000000000000178
118. Valenti-Azcarate R, Esparragosa Vazquez I, Toledano Illan C, et al. Nivolumab and Ipilimumab-induced myositis and myocarditis mimicking a myasthenia gravis presentation. *Neuromuscul Disord.* 2020;30:67–69. doi:10.1016/j.nmd.2019.10.006
119. Williams KJ, Allen R. Immune checkpoint inhibitor-induced ptosis in a patient with prostate cancer. *J Neuro-Ophthalmology.* 2020. doi:10.1097/WNO.0000000000000927
120. Hassanzadeh B, DeSanto J, Kattah JC. Ipilimumab-induced adenohypophysitis and orbital apex syndrome: importance of early diagnosis and management. *Neuro-Ophthalmology.* 2018;42:176–181. doi:10.1080/01658107.2017.1368090
121. Betraims A, Blockmans DE. Immune checkpoint inhibitor-associated polymyalgia rheumatica/giant cell arteritis occurring in a patient after treatment with nivolumab. *J Clin Rheumatol.* 2019 Feb 19 [Epub ahead of print]. doi:10.1097/RHU.0000000000001012
122. Chow KL, Perju-Dumbrava L, Malhotra A, et al. Giant cell arteritis secondary to combined nivolumab and ipilimumab in metastatic pleural mesothelioma. *Neuro Asia.* 2020;25.
123. Goldstein BL, Gedmintas L, Todd DJ. Drug-associated polymyalgia rheumatica/giant cell arteritis occurring in two patients after treatment with ipilimumab, an antagonist of CTLA-4. *Arthritis Rheumatol.* 2014;66:768–769. doi:10.1002/art.38282
124. Hid Cadena R, Abdulhad WH, Hospers GAP, et al. Checks and balances in autoimmune vasculitis. *Front Immunol.* 2018;9:315. doi:10.3389/fimmu.2018.00315
125. Micaily I, Chernoff M. An unknown reaction to pembrolizumab: giant cell arteritis. *Ann Oncol.* 2017;28:2621–2622. doi:10.1093/annonc/mdx306
126. Bourgeois-Vionnet J, Joubert B, Bernard E, et al. Nivolumab-induced myositis: a case report and a literature review. *J Neurol Sci.* 2018;387:51–53. doi:10.1016/j.jns.2018.01.030
127. Hellman JB, Traynis I, Lin LK. Pembrolizumab and epacadostat induced fatal myocarditis and myositis presenting as a case of ptosis and ophthalmoplegia. *Orbit.* 2019;38:244–247. doi:10.1080/01676830.2018.1490439
128. Hamada S, Fuseya Y, Tsukino M. Pembrolizumab-induced rhabdomyolysis with myositis in a patient with lung adenocarcinoma. *Arch Bronconeumol.* 2018;54:346–348. doi:10.1016/j.arbres.2018.01.026
129. Diamantopoulos PT, Tsatsou K, Benopoulou O, et al. Inflammatory myopathy and axonal neuropathy in a patient with melanoma following pembrolizumab treatment. *J Immunother.* 2017;40:221–223. doi:10.1097/CJI.0000000000000172
130. Alnabulsi R, Hussain A, DeAngelis D. Complete ophthalmoplegia in Ipilimumab and Nivolumab combination treatment for metastatic melanoma. *Orbit.* 2018;37:381–384. doi:10.1080/01676830.2017.1423349
131. Carrera W, Baartman BJ, Kosmorsky G. A case report of drug-induced myopathy involving extraocular muscles after combination therapy with tremelimumab and durvalumab for non-small cell lung cancer. *Neuro-Ophthalmology.* 2017;41:140–143. doi:10.1080/01658107.2017.1291686

132. Khoo A, Zhuang YZ, Boundy K, Frasca J. Immune checkpoint inhibitor-related myositis associated with atezolizumab therapy. *Neurol Clin Pract*. 2019;9:E25–E26. doi:10.1212/CPJ.0000000000000597
133. Kang KH, Grubb W, Sawlani K, et al. Immune checkpoint-mediated myositis and myasthenia gravis: a case report and review of evaluation and management. *Am J Otolaryngol - Head Neck Med Surg*. 2018;39:642–645.
134. Maller B, Peguero E, Tanvetyanon T. Ipilimumab/nivolumab-related opsoclonus-myoclonus-ataxia syndrome variant in a patient with malignant pleural mesothelioma. *J Immunother*. 2018;41:411–412. doi:10.1097/CJI.0000000000000228
135. Puzanov I, Diab A, Abdallah K, et al. Managing toxicities associated with immune checkpoint inhibitors: consensus recommendations from the society for immunotherapy of cancer (SITC) toxicity management working group. *J Immunother Cancer*. 2017;5:95. doi:10.1186/s40425-017-0300-z
136. Fazel M, Jedlowski PM. Severe myositis, myocarditis, and myasthenia gravis with elevated anti-striated muscle antibody following single dose of ipilimumab-nivolumab therapy in a patient with metastatic melanoma. *Case Reports Immunol*. 2019;2019:1–3.
137. Larkin J, Chiarion-Sileni V, Gonzalez R, et al. Combined nivolumab and ipilimumab or monotherapy in untreated melanoma. *N Engl J Med*. 2015;373:23–34. doi:10.1056/NEJMoa1504030
138. Beck KE, Blansfield JA, Tran KQ, et al. Enterocolitis in patients with cancer after antibody blockade of cytotoxic T-lymphocyte-associated antigen 4. *J Clin Oncol*. 2006;24:2283–2289. doi:10.1200/JCO.2005.04.5716
139. Ascierto PA, Simeone E, Sileni VC, et al. Clinical experience with ipilimumab 3 mg/kg: real-world efficacy and safety data from an expanded access programme cohort. *J Transl Med*. 2014;12:116. doi:10.1186/1479-5876-12-116
140. Horvat TZ, Adel NG, Dang TO, et al. Immune-related adverse events, need for systemic immunosuppression, and effects on survival and time to treatment failure in patients with melanoma treated with ipilimumab at memorial sloan kettering cancer center. *J Clin Oncol*. 2015;33:3193–3198. doi:10.1200/JCO.2015.60.8448
141. Petrelli F, Signorelli D, Ghidini M, et al. Association of steroids use with survival in patients treated with immune checkpoint inhibitors: a systematic review and meta-analysis. *Cancers*. 2020;12:546. doi:10.3390/cancers12030546
142. Kaplon H, Muralidharan M, Schneider Z, Reichert JM. Antibodies to watch in 2020. *MAbs*. 2020;12:1703531. doi:10.1080/19420862.2019.1703531

## Eye and Brain

### Publish your work in this journal

Eye and Brain is an international, peer-reviewed, open access journal focusing on clinical and experimental research in the field of neuro-ophthalmology. All aspects of patient care are addressed within the journal as well as basic research. Papers covering original research, basic science, clinical and epidemiological studies, reviews and

evaluations, guidelines, expert opinion and commentary, case reports and extended reports are welcome. The manuscript management system is completely online and includes a very quick and fair peer-review system, which is all easy to use. Visit <http://www.dovepress.com/testimonials.php> to read real quotes from published authors.

Submit your manuscript here: <https://www.dovepress.com/eye-and-brain-journal>

Dovepress