

Differential response of idiopathic sporadic tumoral calcinosis to bisphosphonates

Karthik Balachandran, Sadishkumar Kamalanathan, Jaya Prakash Sahoo, Ashok Kumar Das, Dhanapathi Halanaik¹

Departments of Endocrinology, ¹Nuclear Medicine, Jawaharlal Institute of Post-Graduate Medical Education and Research, Puducherry, India

ABSTRACT

Context: Tumoral calcinosis is a disorder of phosphate metabolism characterized by ectopic calcification around major joints. Surgery is the current treatment of choice, but a suboptimal choice in recurrent and multicentric lesions. **Aims:** To evaluate the efficacy of bisphosphonates for the management of tumoral calcinosis on optimized medical treatment. **Settings and Design:** The study was done in the endocrine department of a tertiary care hospital in South India. We prospectively studied two patients with recurrent tumoral calcinosis who had failed therapy with phosphate lowering measures. **Materials and Methods:** After informed consent, we treated both patients with standard age adjusted doses of bisphosphonates for 18 months. The response was assessed by X ray and whole body 99mTc-methylene diphosphonate bone scan at the beginning of therapy and at the end of 1 year. We also estimated serum phosphate levels and urinary phosphate to document serial changes. **Results:** Two patients (aged 19 and 5 years) with recurrent idiopathic hyperphosphatemic tumoral calcinosis, following surgery were studied. Both patients had failed therapy with conventional medical management – low phosphate diet and phosphate binders. They had restriction of joint mobility. Both were given standard doses of oral alendronate and parenteral pamidronate respectively for more than a year, along with phosphate lowering measures. At the end of 1 year, one of the patients had more than 95% and 90% reduction in the size of the lesions in right and left shoulder joints respectively with total improvement in range of motion. In contrast, the other patient (5-year-old) had shown no improvement, despite continuing to maintain normophosphatemia following treatment. **Conclusions:** Bisphosphonate therapy in tumoral calcinosis is associated with lesion resolution and may be used as a viable alternative to surgery, especially in cases with multicentric recurrence or treatment failure to other drugs.

Key words: Bisphosphonates, fibroblast growth factor 23, hyperphosphatemia, tumoral calcinosis

INTRODUCTION

Tumoral calcinosis is a rare genetic disorder of phosphate homeostasis characterized by metastatic calcification in the subcutaneous tissue. The common sites include elbow, shoulder, hip and ankles. Pain is unusual, but large masses can lead to restriction of range of motion of the concerned joint. The primary driving force for

calcification is hyperphosphatemia, which, in the setting of normal calcium levels, leads to deposition of amorphous hydroxyapatite. The hyperphosphatemia is attributed to reduced bioactive fibroblast growth factor23 (FGF23) causing increased phosphate reabsorption. Standard management includes dietary restriction of phosphate and surgical resection of the calcified mass. However, recurrence of the tumor is the rule rather than exception.

Medical therapy of tumoral calcinosis has largely focused on control of hyperphosphatemia. Several agents like phosphate binders, acetazolamide, and calcitonin have been tried with varied results. Bisphosphonates show promise as a therapeutic modality in the management of this rare disorder as it has been shown to induce remission even in normophosphatemic variants. We wondered if medical management of the recurrent lesions with bisphosphonates

Access this article online

Quick Response Code:



Website:
www.ijem.in

DOI:
10.4103/2230-8210.137511

Corresponding Author: Dr. Sadishkumar Kamalanathan, Endocrinology, 557, Fourth floor, Inpatient Division, Superspecialty Block, Dhanvantri Nagar, Jawaharlal Institute of Post-graduate Medical Education and Research, Puducherry - 605 006, India. E-mail: sadishkk@gmail.com

would lead to resolution of the lesion. Our current lacuna in understanding the pathogenesis of tumoral calcinosis limits designing of an effective therapeutic regimen.

MATERIALS AND METHODS

Two cases of sporadic tumoral calcinosis which recurred after surgical therapy were tried on medical treatment with bisphosphonates in the absence of better alternative and for logistic reasons.

Case 1

A 19-year-old male presented with swelling in the left thigh for 3 months. The swelling was large and had shown relatively rapid growth. It had variegated consistency and the skin over the swelling was stretched. On evaluation, he had shown hyperphosphatemia as the sole metabolic abnormality which was missed by the treating surgeon. The swelling was subsequently excised and its biopsy showed tumoral calcinosis. The patient was lost to follow-up. One year later, the patient presented to our department with swelling involving bilateral shoulders with decreased range of motion and discomfort. On examination, he had globular swellings involving bilateral shoulders with winging of right scapula and drooping of the corresponding shoulder. Fluffy calcification in bilateral shoulder joints was seen in X ray examination. Computed tomography (CT) brain revealed calcified lesion of right temporal lobe. CT shoulder was done for further delineation of the lesion which showed infiltration into the joint space. Biochemical evaluation showed a normal calcium level, increased serum phosphate, and normal alkaline phosphatase. Parathormone was suppressed and calcitriol was inappropriately normal. C-terminal FGF23 level was grossly elevated [Table 1]. Bone scan done showed increased tracer activity associated with areas of bilateral shoulder lesions [Figure 1a and c].

Table 1: Laboratory and clinical values of patients at the time of presentation and after 1 year of bisphosphonate therapy

	Treatment			
	Case 1		Case 2	
	Before	After	Before	After
Recurrence	Yes	NA*	Yes	NA*
Number of lesions	2	NA	1	1
Size of the lesion	10,8 cm	1, 2 cm	12 cm	15 cm
Serum calcium (mg/dL)	9.6	9.4	8.7	7.7
Serum phosphate (mg/dL)	6.3	6.4	7.1	2.8
Serum alkaline phosphatase (IU/L)	70	74	112	156
iPTH (pg/mL)	6.4	5.6	9.6	12.9
FGF23 (RU/mL)	2620	2,264	5361	NA
25(OH) Vitamin D (ng/mL)	15.4	NA	18.6	NA
1,25(OH) 2 Vitamin D (pg/mL)	23.6	NA	28.9	NA

FGF23: Fibroblast growth factor23, iPTH : Intact PTH *NA: Not applicable/available

In view of the above features, a diagnosis of tumoral calcinosis was made.

Since the patient had presented with recurrence and the calcified mass had breached joint capsule, the risk of poor surgical outcome was deemed high. Hence, medical management was considered. He was initially prescribed low phosphate diet with phosphate binder, lanthanum carbonate 250 mg thrice daily for 6 months. Unfortunately, he had poor response to the above regimen. Hence, it was decided to try bisphosphonate therapy in this patient. He was started on alendronate 70 mg weekly.

Case 2

A 5-year-old female child presented to us with recurrent swelling in the right gluteal region after surgery for a similar swelling in the same site 1 year back. The swelling had increased in size over the past few months [Figure 2a and c] and now was causing severe pain and restriction of movement of the hip joint. She also had loss of appetite and loss of weight. She had been found to have hyperphosphatemia during evaluation of previous swelling prior to surgery.

The biopsy was reported as tumoral calcinosis and the patient was lost to follow-up. During the current admission, the patient was noted to have hyperphosphatemia and normal calcium levels with suppressed parathyroid hormone (PTH) [Table 1]. Calcitriol levels were inappropriately normal. Considering the age and size of the lesion, she was initiated on intravenous pamidronate

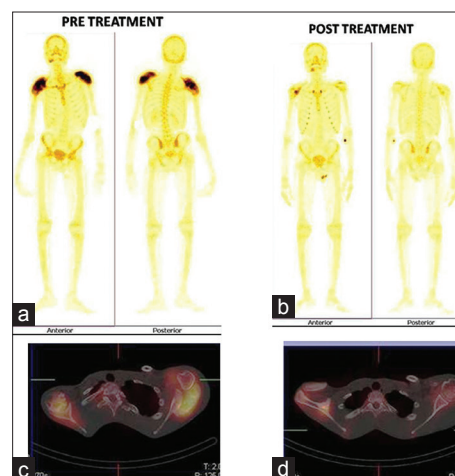


Figure 1: 99mTc-methylene diphosphonate whole body bone scan (a and b with anterior and posterior views) and their respective single-photon emission computed tomography (SPECT). Computed tomography (CT) fused (c and d) images before and after treatment. a and c are pre treatment images showing intense uptake in bilateral shoulder joints with evidence of shoulder joints infiltration on SPECT. CT fused images. b and d are posttreatment images showing significant reduction of activity from both shoulder joints

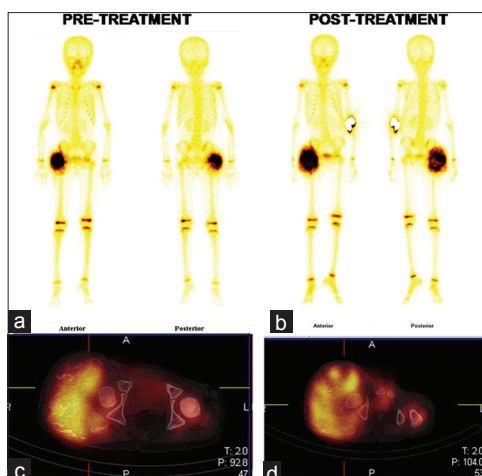


Figure 2: ^{99m}Tc -methylene diphosphonate whole body bone scan (a and b with anterior and posterior views) and their respective single-photon emission computed tomography (SPECT). Computed tomography (CT) fused (c and d) images before and after treatment. a and c are pretreatment images showing intense uptake in right gluteal with large calcified soft tissue mass on SPECT. CT. b and d are posttreatment images showing significant increase in size of calcified soft tissue mass with increased tracer uptake in right gluteal region

therapy. Like the previous patient, she was also on regular medication with lanthanum carbonate 250 mg thrice daily and low phosphate diet. After a transient initial improvement, the lesion increased in size. Acetazolamide was added to her regimen, but it had no benefit.

RESULTS

Case 1

On follow-up after 1 year, the patient had shown marked improvement with reduction in size of the lesion by 95% on the right side and 90% on the left side [Figure 1b and d]. The range of movements in shoulder joint was normal. The patient continues to improve on this regimen and is currently continuing bisphosphonates with low phosphate diet.

Case 2

During follow-up, her lesion had increased in size [Figure 2b and d], resulting in pain and severe restriction of movement in the hip joint. Surgical option was ruled out as the removal of the entire lesion would compromise muscle mass so much that the patient would not be able to walk postoperatively. Following failure of intravenous pamidronate, she was considered for more potent intravenous bisphosphonate, zoledronic acid. After informed consent, she was given injection zoledronic acid 1 mg intravenous. Similar to the first attempt, she had a mild initial regression in size after which there is no change in size of swelling. The patient is on regular follow-up and she is on therapy with low phosphate diet, lanthanum, and acetazolamide.

DISCUSSION

Idiopathic tumoral calcinosis is a rare genetically heterogeneous disorder of phosphate metabolism, resulting in ectopic calcification around the joints or in blood vessels. It is diagnosed after ruling out family history of tumoral calcinosis and secondary causes for the same like chronic kidney disease, hyperparathyroidism, and hypervitaminosis D as was done in our cases. The disorder can be hyperphosphatemic or normophosphatemic. The deranged phosphate metabolism is due reduced FGF23 bioactivity, leading to increased renal resorption of phosphate. This can occur due to mutation of FGF23 itself, GALNT3 (an enzyme involved in O-glycosylation and stabilization of wild type FGF23), or α klotho (the cofactor for FGF23 action).^[1]

Slavin *et al.*, proposed the following theory for the pathogenesis of this disorder. Tumoral calcinosis is initiated by periarticular microtrauma in the setting of hyperphosphatemia. The first line of defence involves infiltration by histiocytes, attempting an adventitious bursa formation. The purpose is to shield the joint from further trauma. However, the continuing hyperphosphatemia leads to apoptosis of the histiocytes, causing release of hydroxyapatite. Thus, the reparative response is ineffective, as the compartments are obliterated by continued deposition of hydroxyapatite. The next line of defense involves multinucleate giant cells which try to resorb the calcified lesion. As the lesion lacks the normal bony scaffolding necessary for the action of these “osteoclast-like” giant cells, resorption of calcification fails. Furthermore, the calcific crystals are coated with chymotrypsin and the extrusion of bicarbonate by the giant cells creates an alkaline milieu, inhibiting resolution of lesion. This leads to continued growth of the lesion.^[2] Therefore, tumoral calcinosis does not follow the regular schema of metastatic or dystrophic calcification.

The treatment of tumoral calcinosis has traditionally been complete surgical excision. However, recurrence is the rule rather than exception.^[3] The option for medical treatment of this disorder has never been formally evaluated in any clinical trial due to the rarity and heterogeneity of this disorder. Indeed, the definition of successful therapeutic outcome itself is not clear.

Currently, used medical therapy focuses on the reduction in phosphate levels with the hope that resolution of hyperphosphatemia will lead to reduction in size of the lesion or at least eliminate the cardiovascular risk associated with hyperphosphatemia, as it can lead to vascular calcification. However, the response is variable and this approach does not

address the normophosphatemic variant of tumoral calcinosis. The approach to medical management of hyperphosphatemia is twofold-limiting absorption (phosphate-restricted diet,^[4] phosphate binders-lanthanum, sevelamer^[5]) and increasing renal clearance (acetazolamide,^[6] calcitonin^[7]). Dialysis with low phosphate containing dialysate and parathyroidectomy for severe secondary hyperparathyroidism has also been tried.^[8] Bisphosphonates have recently been reported to be helpful in management. Sodium thiosulphate is another topical option.^[9]

For any drug to be useful in tumoral calcinosis, it must not only inhibit formation of new hydroxyapatite crystals, but also dissolve the existing ones. Bisphosphonates act on the osteoclasts and osteoclast-like cells, which are implicated in the pathogenesis of tumoral calcinosis. This results in the alteration of biochemical and cellular milieu leading to reduced crystal formation and aggregation.^[10] The ability of bisphosphonates to promote dissolution of existing crystals^[11] makes them an attractive option in management of tumoral calcinosis.

Initial use of bisphosphonates (as long as 3 decades back) was met with failure in cases of familial or idiopathic tumoral calcinosis.^[12,13] The first successful use of bisphosphonates in idiopathic tumoral calcinosis was shown by Jubbin *et al.*,^[10] who reported complete resolution of the lesion in a patient treated with oral alendronate for 18 months. However, the patient did not have hyperphosphatemia and the size of the lesion was small, unlike our cases where the lesion was very large. Both of our patients had recurrent tumoral calcinosis with poor response to conventional therapy. The two cases differ only in age, gender, and size of the recurrent lesion. Their biochemical profiles were identical except for the degree of serum C-terminal FGF23 level elevation. Both of our cases have decreased serum PTH levels and inappropriately normal calcitriol levels. Albeit atypical, this has been reported in literature before.^[14]

C-terminal FGF23 levels can be elevated in tumoral calcinosis due to mutations in FGF23, GALNT3, or α klotho. The elevation of C terminal FGF23 is the common denominator of all three mutations. Elevated C-terminal fragments with low intact FGF23 is seen in FGF23 and GALNT3 mutation, while both intact FGF23 and C-terminal fragments are increased in α klotho mutation, which leads to FGF23 resistance.^[15] As we could not estimate intact FGF23 level, it was not possible to hypothesize the causative mutation behind our cases.

Both had raised C-terminal FGF23 levels demonstrating the presence in circulation of inactive fragments. This possibly reflects a compensatory attempt at increasing

production of FGF23 as a response to raised phosphate levels.^[3] The fact that control of hyperphosphatemia was achieved in both cases indicates that phosphate (and hence calcium phosphate product) is not the only driver of ectopic calcification and that additional mechanisms probably exist. The difference in size is unlikely to be an explanation for the lack of response as very large lesions have been noted to undergo remission with oral therapy and reduction in phosphate levels.^[5]

The reasons for lack of response could be the short duration of therapy, the possibility of some patients being “slow responders.” Since we could not do genetic analysis of these patients, the possibility of a mutation resulting in a more severe phenotype cannot be excluded. This is more likely due to the fact that the patient who did not respond presented at a much younger age than what is typical for tumoral calcinosis. However, this does not explain the apparent “uncoupling” of phosphate metabolism and therapeutic response. This also questions the assumption that calcium phosphate product is the principal determinant in cases of ectopic calcification.

The singular advantage of bisphosphonate therapy over the other methods is its possible use in normophosphatemic variant of tumoral calcinosis.^[10] The use of parenteral bisphosphonates would lead to better compliance and obviate the need for daily treatment. Unfortunately, the biochemical heterogeneity and rarity of the disorder precludes the possibility of well-designed clinical trials which can throw light on this question. The wider availability and utilization of molecular techniques would likely result in better design of treatment regimens in future. Until recombinant FGF23 or its agonist is available, a prudent therapeutic regimen would include a multipronged approach for correction of hyperphosphatemia and concomitant use of bisphosphonates. This is especially important in patients with recurrence, to whom, it will provide a much needed alternative to surgery.

REFERENCES

1. Fukumoto S. Physiological regulation and disorders of phosphate metabolism--pivotal role of fibroblast growth factor 23. *Intern Med* 2008;47:337-43.
2. Slavin RE, Wen J, Barmada A. Tumoral calcinosis--a pathogenetic overview: A histological and ultrastructural study with a report of two new cases, one in infancy. *Int J Surg Pathol* 2012;20:462-73.
3. Farrow EG, Imel EA, White KE. Miscellaneous non-inflammatory musculoskeletal conditions. Hyperphosphatemic familial tumoral calcinosis (FGF23, GALNT3 and α Klotho). *Best Pract Res Clin Rheumatol* 2011;25:735-47.
4. Alkhooly AZ. Medical treatment for tumoral calcinosis with eight years of follow-up: A report of four cases. *J Orthop Surg (Hong Kong)* 2009;17:379-82.
5. Garringer HJ, Fisher C, Larsson TE, Davis SI, Koller DL, Cullen MJ, *et al.* The role of mutant UDP-N-acetyl-alpha-D-galactosamine-polypeptide

- N-acetylgalactosaminyltransferase 3 in regulating serum intact fibroblast growth factor 23 and matrix extracellular phosphoglycoprotein in heritable tumoral calcinosis. *J Clin Endocrinol Metab* 2006;91:4037-42.
6. Yamaguchi T, Sugimoto T, Imai Y, Fukase M, Fujita T, Chihara K. Successful treatment of hyperphosphatemic tumoral calcinosis with long-term acetazolamide. *Bone* 1995;16 (4 Suppl):247-50S.
 7. Candrina R, Cerudelli B, Braga V, Salvi A. Effects of the acute subcutaneous administration of synthetic salmon calcitonin in tumoral calcinosis. *J Endocrinol Invest* 1989;12:55-7.
 8. Thakur A, Hines OJ, Thakur V, Gordon HE. Tumoral calcinosis regression after subtotal parathyroidectomy: A case presentation and review of the literature. *Surgery* 1999;126:95-8.
 9. Ratsimbazafy V, Bahans C, Guignonis V. Dramatic diminution of a large calcification treated with topical sodium thiosulfate. *Arthritis Rheum* 2012;64:3826.
 10. Jacob JJ, Mathew K, Thomas N. Idiopathic sporadic tumoral calcinosis of the hip: Successful oral bisphosphonate therapy. *Endocrine Pract* 2007;13:182-6.
 11. Russell RG. Bisphosphonates: The first 40 years. *Bone* 2011;49:2-19.
 12. Hug I, Guncaga J. Tumoral calcinosis with sedimentation sign. *Br J Radiol* 1974;47:734-6.
 13. Leicht E, Tkocz HJ, Seeliger H, Lauffenburger T, Haas HG. Tumoral calcinosis. Observations during six years. *Horm Metab Res* 1980;12:269-73.
 14. Feldman D. Vitamin D, parathyroid hormone, and calcium: A complex regulatory network. *Am J Med* 1999;107:637-9.
 15. Ichikawa S, Imel EA, Sorenson AH, Severe R, Knudson P, Harris GJ, *et al.* Tumoral calcinosis presenting with eyelid calcifications due to novel missense mutations in the glycosyl transferase domain of the GALNT3 gene. *J Clin Endocrinol Metabol* 2006;91:4472-5.

Cite this article as: Balachandran K, Kamalanathan S, Sahoo JP, Das AK, Halanaik D. Differential response of idiopathic sporadic tumoral calcinosis to bisphosphonates. *Indian J Endocr Metab* 2014;18:521-5.

Source of Support: Nil, **Conflict of Interest:** None declared.