



Case Report

Parasitic Hypereosinophilia in Childhood: a Diagnostic Challenge

Roberto Antonucci¹, Nadia Vacca¹, Giulia Boz¹, Cristian Locci¹, Rosanna Mannazzu¹, Claudio Cherchi², Giacomo Lai¹ and Claudio Fozza³.

¹ Pediatric Clinic, Department of Medical, Surgical and Experimental Sciences, University of Sassari, Sassari, Italy.

² Respiratory Unit, Academic Department of Pediatrics, Bambino Gesù Children's Hospital, IRCCS, Rome, Italy.

³ Hematology, Department of Medical, Surgical and Experimental Sciences, University of Sassari, Sassari, Italy.

Competing interests: The authors have declared that no competing interests exist.

Abstract. Severe hypereosinophilia (HE) in children is rare, and its etiological diagnosis is challenging. We describe a case of a 30-month-old boy, living in a rural area, who was admitted to our Clinic with a 7-day history of fever and severe hypereosinophilia. A comprehensive diagnostic workup could not identify the cause of this condition. On day 6, the rapidly increasing eosinophil count (maximum value of 56,000/mm³), the risk of developing hypereosinophilic syndrome, and the patient's history prompted us to undertake an empiric treatment with albendazole. The eosinophil count progressively decreased following treatment. On day 13, clinical condition and hematological data were satisfactory, therefore the treatment was discontinued, and the patient was discharged. Three months later, anti-nematode IgG antibodies were detected in patient serum, thus establishing the etiological diagnosis. In conclusion, an empiric anthelmintic treatment seems to be justified when parasitic hypereosinophilia is strongly suspected, and other causes have been excluded.

Keywords: Hypereosinophilia, Hypereosinophilic Syndrome, Children, Diagnosis, Albendazole, Parasitosis, Helminthiasis, Nematode.

Citation: Antonucci R., Vacca N., Boz G., Locci C., Mannazzu R., Cherchi C., Lai G., Fozza C. Parasitic hypereosinophilia in childhood: a diagnostic challenge. *Mediterr J Hematol Infect Dis* 2018, 10(1): e2018034, DOI: <http://dx.doi.org/10.4084/MJHID.2018.034>

Published: May 1, 2018

Received: February 21, 2018

Accepted: April 19, 2018

This is an Open Access article distributed under the terms of the Creative Commons Attribution License (<https://creativecommons.org/licenses/by-nc/4.0>), which permits unrestricted use, distribution, and reproduction in any medium, provided the original work is properly cited.

Correspondence to: Prof. Roberto Antonucci, MD, Associate Professor of Pediatrics. Pediatric Clinic, Department of Medical, Surgical and Experimental Sciences, University of Sassari, Sassari, Italy. Tel. +39 079 228239. E-mail: rantonucci@uniss.it

Introduction. Hypereosinophilia (HE) is defined as an eosinophil count in peripheral blood >1,500/mm³. The World Health Organisation categorizes eosinophilia into mild (600-1,500/mm³), moderate (1,500-5,000/mm³), and severe (>5,000/mm³). An increased number of eosinophils can be potentially associated with organ damage.¹ HE can be distinguished into primary, secondary, familial and idiopathic. The primary form is a clonal disease classified in the context of hematologic malignancies.² Secondary (or reactive) HE is caused by underlying conditions, such as parasitosis, allergic or

autoimmune diseases, or drug reactions, and results from a non-clonal increase in blood eosinophil levels, often driven by the overproduction of IL-5.³ Hereditary (familial) HE (HEFA) is a rare autosomal dominant condition, characterized by HE associated with end-organ damage. Idiopathic hypereosinophilia (or hypereosinophilia of undetermined significance) (HEUS) is a diagnosis of exclusion which can be considered when all causes of a reactive HE have been ruled out. Rarely, a severe HE can be associated with organ damage or dysfunction, in the context of the so-called hypereosinophilic

syndrome (HES). In such cases, the tissue infiltration by eosinophils can result in cell damage, due to the release of eosinophil granule contents, thus leading to significant morbidity.⁴ Severe hypereosinophilia (HE) is a rare condition in children. The etiological diagnosis of this condition is often challenging, with a possible delay in treatment.

Case Report. We describe a case of a 30-month-old boy who was admitted to the Pediatric Clinic, University of Sassari, Italy, with a 7-day history of fever. Two weeks before hospitalization, the patient had had a transient episode of diarrhea. Just before admission, laboratory tests revealed a raised white blood cell (WBC) count of 49,920/mm³ with an eosinophil count of 26,310/mm³, mild microcytic anemia (11.1 g/dL) and high serum total IgE levels (968 UI/mL). The child lived in a rural area of the Mediterranean island of Sardinia, in close contact with animals, and had never experienced any medical problem. Moreover, the history revealed that the patient was not atopic, had been regularly vaccinated, and had not received any pharmacological treatment before hospital admission. Moreover, he had no history of recent travels.

On admission, the patient was apparently well, afebrile, with no other clinical manifestations. At physical examination, there was no evidence of hepato-splenomegaly and lymphadenopathy. Laboratory tests showed an increase in both WBC count (WBC, 58,020/mm³), and eosinophil count (eosinophils, 33,400/mm³; 57.5%); in addition, a moderate elevation of CRP levels (2.85 mg/dL) was found, while serum electrolytes, hepatic and renal markers were normal. Anamnestic, clinical and laboratory findings were considered suggestive for neoplastic or parasitic etiology. In order to exclude a neoplastic HE, a peripheral blood smear and a bone marrow aspirate were performed. The former was normal except for the raised eosinophil percentage, while the bone marrow smear showed an expansion of the eosinophilic lineage (90%) in the absence of blasts. RT-PCR excluded the presence of leukemia-associated genetic abnormalities, and lymphocyte subpopulations, when analyzed by flow cytometry, were normal. In order to exclude a parasitic etiology, the major types of helminths and protozoa responsible for infections associated with hypereosinophilia were investigated by

examination of fresh stool, “scotch tape test” (specific for *Enterobius Vermicularis*), examination of urine, and serologic testing (Echinococcus, Toxocara canis, Cysticercus and Trichinella sp.). All tests were negative for parasitic infection. Chest X-Ray, Doppler echocardiography, abdominal and pelvic ultrasound as well as an eye examination excluded thoracic, abdominal or pelvic lesions and eosinophilic organ infiltration.

During hospitalization, blood eosinophil count further increased, reaching the maximum value of 56,000/mm³ after six days. Under suspicion of parasitic etiology, mainly driven by the patient's living conditions, and to prevent possible organ damage due to eosinophil infiltration, empiric treatment with albendazole (15 mg/kg/day) was started. After only 24 hours, the eosinophil count was 21,000/mm³ and continued to decrease in the following days (**Figure 1**). On day 13, blood eosinophils were 6,700/mm³, the clinical condition was satisfactory, and therefore the treatment was discontinued, and the patient was discharged home. The eosinophil count was found to be within the normal range one month after the end of therapy.

At three months after discharge, IgG anti-nematode antibodies were detected in serum samples from the patient and his father by ELISA test (using raw antigen), which was performed by the Italian Higher Institute of Health.

Discussion. Hypereosinophilia can be associated with many infectious, neoplastic, immunological and genetic diseases, or to drug reactions. Therefore, a careful family and personal history is

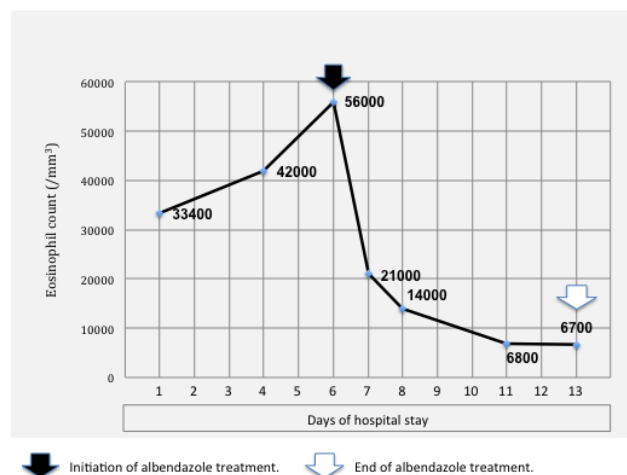


Figure 1. Blood eosinophil count changes with albendazole treatment. Black and white arrows indicate initiation and end of treatment, respectively.

mandatory to investigate conditions related to eosinophilia, such as atopy, medications, diet, travels and environmental exposure to parasites.⁵ In this case, the specific living environment of the child, a country farm with close contact with animals, played a central role in generating our diagnostic hypothesis. In details, an atopic condition was excluded based on the dramatic increase in eosinophils and the history of fever. On the other hand, a neoplastic etiology was ruled out by performing peripheral and medullary smears, RT-PCR and lymphocyte subpopulations studies. Eosinophilic Granulomatosis with Polyangiitis (EGPA), a rare systemic necrotizing vasculitis, was also taken into consideration in the differential diagnosis, but it was ruled out because of the age of the patient, the absence of history of atopy, asthma or rhinitis, as well as the lack of signs of vasculitis and extra-vascular granulomas.

Finally, a parasitic etiology, which was supported by the patient's history, remained the most likely option. In this regard, it is known that the specific diagnostic characterization of a parasitic intestinal infection is difficult. A wide variety of parasites can elicit eosinophilia,⁶ even if only relatively few of them can be responsible for such a marked increase in eosinophil levels.⁷ The pattern and degree of eosinophilia in parasitic infections result from the development, migration, and distribution of the parasite within the host, as well as from the host's immune response. Parasites tend to elicit marked eosinophilia when they or their products come into contact with immune effector cells in tissues, particularly during migration. When mechanical barriers separate the parasite from the host, or when parasites no longer invade tissues, the stimulus to eosinophilia is usually absent. Therefore, eosinophilia is highest in infections with a phase of parasite development that involves migration through tissues (eg, trichinosis, ascariasis, gnathostomiasis,

strongyloidiasis, schistosomiasis, and filariasis).⁸ Detection of eggs, larvae or adult worms in feces is necessary to make a diagnosis. However, being very difficult to obtain, a negative examination does not allow to exclude a parasitic infection with certainty. The rapid increase in eosinophil count, the potential risk of evolution to the hypereosinophilic syndrome or to organ damage,⁹ and the history suggestive of a parasite infection prompted us to undertake an albendazole-based empiric therapy. Albendazole is a safe medication, and its use is promoted by WHO to control the infection in high endemic areas, even when an exact diagnosis is lacking.¹⁰ Also, empiric albendazole therapy is recommended by the British Infection Society in returning travelers and migrants from the tropics to cover the possibility of geohelminth infection as the cause of transient eosinophilia with negative stool microscopy.¹¹ In our case, the treatment was readily effective, leading to a steep decrease in the eosinophil count in just 24 hours. Therefore, the diagnosis of parasitic hypereosinophilia was challenging and required an 'ex-iuvantibus' approach, while the diagnosis of nematode infection was established by serologic testing only three months later.

The picture of extreme hypereosinophilia is rare in childhood. The etiological diagnosis of this condition is often challenging for the clinician, and this may lead to difficulties in deciding upon the specific choice of treatment for individual patients. The case described here can be considered emblematic of this hematological condition and offers the example of a diagnostic-therapeutic approach that might be applicable in similar contexts. Based on this case report and the literature data, we can conclude that an empiric anthelmintic treatment is justified and potentially decisive when hypereosinophilia of parasitic origin is strongly suspected.

References:

1. Valent P, Klion AD, Horny H-P, Roufosse F, Gotlib J, Weller PF, Hellmann A, Metzgeroth G, Leiferman KM, Arock M, Butterfield JH, Sperr WR, Sotlar K, Vandenberghe P, Haferlach T, Simon H-U, Reiter A, Gleich GJ. Contemporary consensus proposal on criteria and classification of eosinophilic disorders and related syndromes. *J Allergy Clin Immunol* 2012;130:607-12. <https://doi.org/10.1016/j.jaci.2012.02.019>
2. Bain BJ, Fletcher SH. Chronic eosinophilic leukemias and the myeloproliferative variant of the hypereosinophilic syndrome. *Immunol Allergy Clin North Am*. 2007;27:377-88. <https://doi.org/10.1016/j.jiac.2007.06.001>
3. Ackerman SJ, Bochner BS. Mechanisms of eosinophilia in the pathogenesis of hypereosinophilic disorders. *Immunol Allergy Clin North Am*. 2007;27:357-75. <https://doi.org/10.1016/j.jiac.2007.07.004>
4. Crane MM, Chang CM, Kobayashi MG, Weller PF. Incidence of myeloproliferative hypereosinophilic syndrome in the United States and an estimate of all hypereosinophilic syndrome incidence. *J Allergy Clin Immunol*. 2010;126:179-81. <https://doi.org/10.1016/j.jaci.2010.03.035>
5. Curtis C, Ogbogu PU. Evaluation and Differential Diagnosis of Persistent Marked Eosinophilia. *Immunol Allergy Clin North Am*. 2015;35:387-402. <https://doi.org/10.1016/j.jiac.2015.04.001>
6. Weller PF. Eosinophilia in travelers. *Med Clin North Am*. 1992;76:1413-32. [https://doi.org/10.1016/S0025-7125\(16\)30294-2](https://doi.org/10.1016/S0025-7125(16)30294-2)
7. Nutman TB. Evaluation and differential diagnosis of marked, persistent eosinophilia. *Immunol Allergy Clin North Am*.

- 2007;27:529-49. <https://doi.org/10.1016/j.iac.2007.07.008>
8. Moore TA, Nutman TB. Eosinophilia in the returning traveler. *Infect Dis Clin North Am.* 1998;12:503-21. [https://doi.org/10.1016/S0891-5520\(05\)70016-7](https://doi.org/10.1016/S0891-5520(05)70016-7)
 9. Roufosse F, Weller PF. Practical approach to the patient with hypereosinophilia. *J Allergy Clin Immunol.* 2010;126:39-44. <https://doi.org/10.1016/j.jaci.2010.04.011>
 10. Crompton DWT. Preventive chemotherapy in human helminthiasis: coordinated use of anthelmintic drugs in control interventions: a manual for health professionals and programme managers. Geneva: World Health Organization 2006 http://apps.who.int/iris/bitstream/10665/43545/1/9241547103_eng.pdf
 11. Checkley AM, Chiodini PL, Dockrell DH, Bates I, Thwaites GE, Booth HL, Brown M, Wright SG, Grant AD, Mabey DC, Whitty CJM, Sanderson F, British Infection Society and Hospital for Tropical Diseases. Eosinophilia in returning travellers and migrants from the tropics: UK recommendations for investigation and initial management. *J Infect.* 2010; 60:1-20. <https://doi.org/10.1016/j.jinf.2009.11.003>