

Multidimensional evaluation of prosthetically rehabilitated cranial defects using key behavior change inventory

Thiruvalluvan Nagarajan, Poonam Prakash¹, Sujit Kumar Bhandari²

Graded Specialist Prosthodontics, CMDC(NC), Udampur, Jammu and Kashmir, ¹Division of Prosthodontics and Crown and Bridge, Department of Dental Surgery and Oral Health Sciences, AFMC, ²Department of Dental Surgery and Oral Health Sciences, AFMC, Pune, Maharashtra, India

Abstract

Defects of the cranial vault can result from the decompressive craniectomy secondary to trauma, cerebral infections, resection of intracranial processes, or bone invading skin tumors. Reconstruction of the cranial vault not only provides protection and esthetic reasons but also maintains and restores physiological circulatory system of the cerebrum essential for the regulation of intracranial pressure. This paper presents prosthetic rehabilitation of two patients, who suffered head injury resulting in extensive frontoparieto temporal defects that induced symptoms such as headache, fatigue, loss of concentration, loss of memory, and depression. Along with the physical dysfunction and disfigurement, the injury resulted in a deep psychological impact on overall well-being and self-esteem of the patient as well as the close family members. The patients were prosthetically rehabilitated with custom-made heat polymerized polymethyl methacrylate cranial prosthesis and the assessment of postrehabilitation outcome was done using a specific measurement tool; key behaviors change inventory (KBCI) a 64-item questionnaire that evaluates executive, interpersonal, and emotional functioning behaviors following traumatic brain injury. Rehabilitation resulted in the restoration of form, function, and esthetics along with the improvement in psychological status and general health as reflected in KBCI scores posttreatment. Based on the posttreatment scores obtained in the cases under study, it is suggested that KBCI may serve as an important prognostic tool for the assessment of treatment outcomes.

Keywords: Cranial defects, cranial prosthesis, key behavior change inventory, sunken skin flap syndrome, traumatic brain injury

Address for correspondence: Lt Col Poonam Prakash, Associate Professor, Division of Prosthodontics and Crown and Bridge, Department of Dental Surgery and Oral Health Sciences, Armed Forces Medical College, Pune, Maharashtra, India.

E-mail: pnmprakash1977@gmail.com

Submitted: 22-Nov-2020, **Revised:** 08-Jul-2021, **Accepted:** 09-Jul-2021, **Published:** 10-Aug-2021

INTRODUCTION

Cranial defects may result from trauma, disease, and congenital malformations. Decompressive craniectomy performed as immediate surgical management results in “Sinking skin flap syndrome or syndrome of the

trephined (SSFS)” that is a serious disabling neurological deficit and impairment of the general status which develops several weeks to months postinjury. It presents with concave deformity along with the relaxation of the skin flap. Neurological symptoms of SSFS include headache, vertigo, tinnitus, fatigue, loss of

Access this article online	
Quick Response Code:	Website: www.j-ips.org
	DOI: 10.4103/jips.jips_587_20

This is an open access journal, and articles are distributed under the terms of the Creative Commons Attribution-NonCommercial-ShareAlike 4.0 License, which allows others to remix, tweak, and build upon the work non-commercially, as long as appropriate credit is given and the new creations are licensed under the identical terms.

For reprints contact: WKHLRPMedknow_reprints@wolterskluwer.com

How to cite this article: Nagarajan T, Prakash P, Bhandari SK. Multidimensional evaluation of prosthetically rehabilitated cranial defects using key behavior change inventory. J Indian Prosthodont Soc 2021;21:311-5.

concentration, loss of memory, depression, dysphagia, apraxia, paresis of extremities, and convulsions. This has been attributed to the compression of the underlying cortex by an infolded scalp, changes in cerebral blood flow, and cerebrospinal fluid hydrodynamics.^[1]

Cranioplasty is accomplished either with osteoplastic flaps or with alloplastic implants.^[2,3] Prosthetic rehabilitation to restore the lost contour is achieved with alloplastic implant materials such as metal, acrylic resin, polyethylene, and silicone.

CASE REPORTS

Case-1

A 26-year-old male was referred from the department of neurosurgery for rehabilitation of residual cranial defect [Figure 1]. The patient had sustained gunshot wound injury, a year ago that resulted in head injury with the fracture of multiple cranial bones. Craniectomy and evacuation of hematoma on left side were performed as an emergency management protocol. The clinical examination revealed a frontoparietotemporal defect of 11 cm × 7 cm in maximum dimensions. The radiological investigations such as X-ray skull (anteroposterior and lateral) supplemented with computed tomography (CT) were done to define the site and size of the defect. Based on the clinical examination and radiological investigation, a diagnosis of residual cranial defect was arrived at.

The surgical and prosthetic management was discussed with the multidisciplinary team comprising of neurosurgeon, plastic and reconstructive surgeon, anesthetist, psychologist, and prosthodontist. Owing to the involvement of multiple cranial bone and the large size of the defect, rehabilitation with custom-made polymethyl methacrylate (PMMA) alloplastic implant was planned. The detailed procedure was explained to the patient, and an informed consent was obtained.

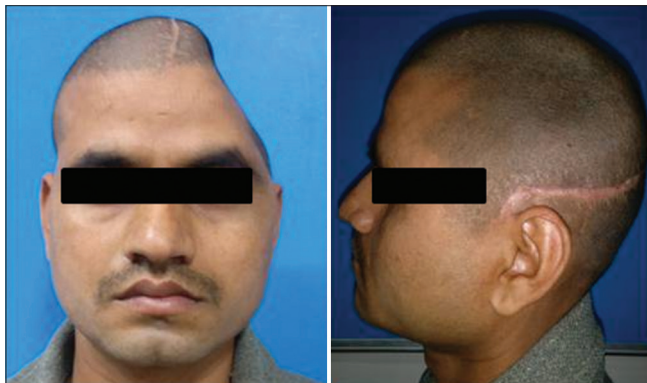

Figure 1: Preoperative case 1

Procedure

The rehabilitation comprised two phases, prosthetic and surgical.

Prosthetic phase

The outer and inner tables of the bony defect were marked with an indelible pencil. A special tray was fabricated by adapting impression compound (Pinnacle Impression Compound, DPI, India) over the defect and face; facial impression was made with irreversible hydrocolloid (Dentsply Zelgan, India) [Figure 2]. Cast was made with dental stone (Kalabhai, Kalstone, India) and defect marked on the stone cast. As the defect was large, it was blocked out with the plaster (Neelkanth Plaster India) in the center to reduce the thickness of the implant [Figure 3]. A wax (Modelling Wax DPI, India) pattern was fabricated on the stone cast [Figure 4] and tried on to the defect. Contours of the wax pattern were viewed and adjusted from all angles (frontal, lateral, superior, and inferior), and the corrections were made to restore the normal anatomy. The pattern was invested by conventional technique, processed with heat-polymerized acrylic resin (DPI Heat Cure, India) using long curing cycle (168°F for 12 h and terminally boiled for 30 min). Multiple holes of 1.5 mm diameter, at a distance of 1.5 mm to 2 mm from each other, were made over the entire plate and trial done on the defect site [Figure 5]. The edges of the prosthesis were beveled with a flame-shaped acrylic bur, for a smooth transition of prosthesis over the bony margins. The prosthesis was finished, polished, and disinfected by soaking in 2% glutaraldehyde solution for 48 h.^[4]

Surgical phase

A hemicoronal incision was placed along the previous existing scar line for craniotomy. A step cut of 2 mm depth was made at the periphery of the defect to facilitate

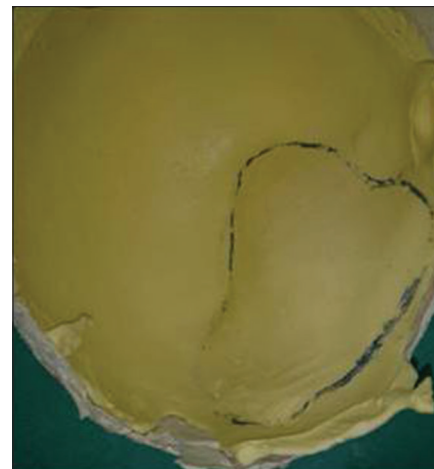


Figure 2: Impression

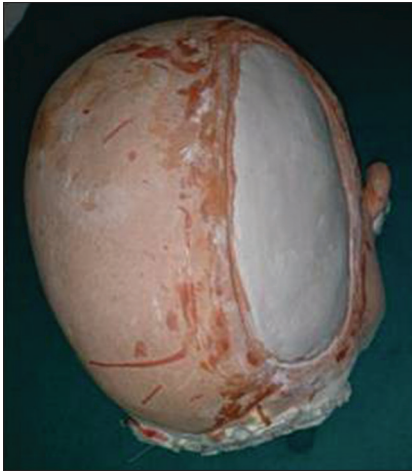

Figure 3: Cast with block out

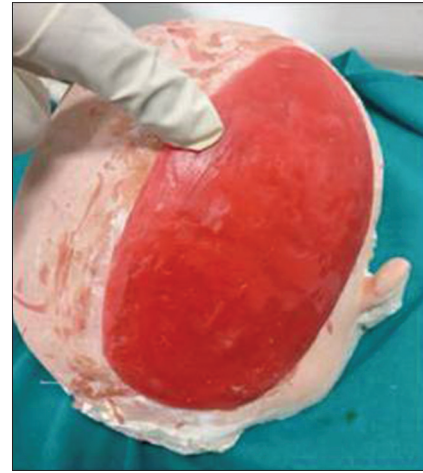


Figure 4: Wax pattern try in



Figure 5: Polymethyl methacrylate alloplastic implant

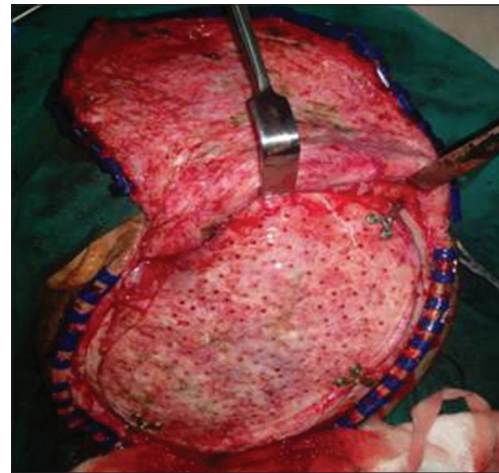


Figure 6: Intraoperative-cranial plate in situ

the proper seating of prosthesis and smooth marginal adaptation. The plate was made slightly larger than the actual defect so that it would not dip into the defect, resulting in poor esthetics.

The marginal discrepancies were marked, and the implant was adjusted to fit the defect as closely as possible. It was secured with 3 × 4-holed titanium mini plates and screws to the underlying bone [Figure 6]. The surgical wound was debrided and closed in multiple layers. Postoperatively, the patient had an uneventful recovery. There was marked improvement in contour of the skull and facial asymmetry [Figure 7].

Case-2

A 23-year-old male reported with residual frontoparietotemporal cranial defect of 15 cm × 9 cm size secondary to decompressive craniectomy for the management of mine blast injury. The patient was rehabilitated with custom-made PMMA cranial prosthesis using the same procedure as described in Figure 8.

Evaluation of clinical outcome using key behavior change inventory

KBCI questionnaires were given to both patients, pre and postoperatively during the follow-up period of 1-month. Analysis of KBCI in both cases showed improvement in three domains; (a) apathy where he showed marked improvement from sitting idly to working independently, (b) somatic improvements included higher tolerance to normal aches, and (c) improvements in emotional domain were exhibited in the form of adjustments to life's difficulties. There were no changes in the other subscales. However, the patient's caregivers reported an improvement in psychological status and general behavior along with better communication with the family.

DISCUSSION

The material used for cranioplasty can be broadly classified under autografts and allografts. Autografts have the advantage of better acceptance and successful

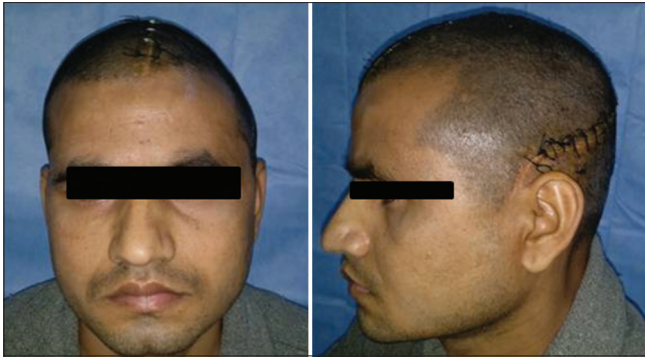

Figure 7: Postoperative case 1

incorporation. In case of large defects, problems such as donor site morbidity, insufficient amount or quality of donor material, and difficulty in crafting the correct shape may arise. The most frequently used alloplastic materials are hydroxyapatite cements, acrylics (especially PMMA), and carbon fiber-reinforced plastics. They allow the repair of large defects with no donor site morbidity and lesser costs.^[5,6] The advantages of PMMA implant include ease of use, availability, radiolucency, dimensional stability, chemical inertness, nonconductivity, ease of modification and low cost, and accurate reproduction.^[7-9]

Various scales have been developed to measure the consequences of traumatic brain injury (TBI). The frontal lobe personality scale is a 46-item rating scale. Neuropsychology Behavior and Affect Profile is composed of five scales that measure behavioral and emotional changes in brain-injured individuals: indifference, inappropriateness, pragnosia, and specificity to various neurologic conditions. Neurobehavioral functioning inventory comprises six scales: depression, somatic, memory/attention, communication, aggression, and motor. Several behavioral domains relevant to TBI such as apathy, impulsivity, and limited awareness of problems (anosognosia) are not assessed.^[10]

The key behaviors change inventory (KBCI) was developed to overcome the shortcomings of existing measures used in TBI rehabilitation settings. KBCI, a 64-item instrument, measures a wide range of behavioral outcomes commonly experienced by individuals with TBI to assess executive, interpersonal, and emotional functioning behaviors. The eight subscales of KBCI test for unawareness, inattention, impulsivity, apathy, interpersonal difficulties, communication problems, emotional adjustment, and somatic difficulties. It is given to the patient and caregivers pre and postintervention to assess the outcome of the rehabilitation.^[10]

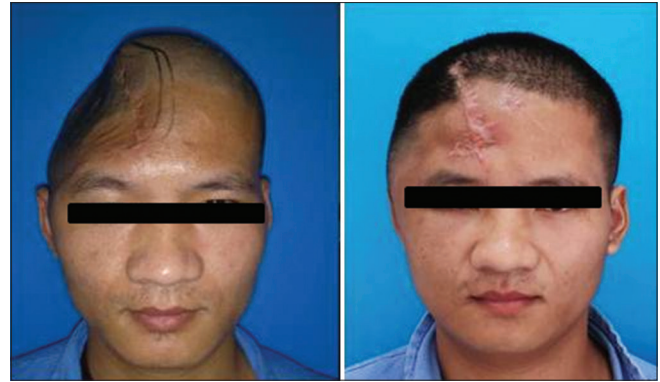

Figure 8: Pre and postcomparison case 2

Clinical significance

The patients have an excellent memory of their preinjury functioning status but other sources provide reliable information of postinjury functioning. KBCI scores obtained from both patient and caregiver serve as a reliable tool to evaluate the postrehabilitation treatment outcome objectively over time that can serve as a guide to customize the treatment approach.

CONCLUSION

The trauma results in the loss of form, function, and esthetics along with the psychological impairment which is restored by surgical reconstruction and prosthetic rehabilitation, perceived by the patient, and the family. However, the psychological impact of the trauma and the positive outcome of the rehabilitation are not taken into consideration. KBCI gives an objective assessment of the impact of trauma as well as the treatment instituted over time. The cases under the study were rehabilitated using custom-made alloplastic PMMA implants that resulted in physical restoration of the defect along with the improvement in psychological status and general health as reflected in KBCI scores posttreatment. Based on the posttreatment scores obtained in the cases under the study, it is suggested that KBCI is made an integral component of rehabilitation and assessment protocol in residual cranial defects.

Declaration of patient consent

The authors certify that they have obtained all appropriate patient consent forms. In the form, the patient has given his consent for his images and other clinical information to be reported in the journal. The patient understands that name and initials will not be published and due efforts will be made to conceal identity, but anonymity cannot be guaranteed.

Financial support and sponsorship

Nil.

Conflicts of interest

There are no conflicts of interest.

REFERENCES

1. Yamaura A, Makino H. Neurological deficits in the presence of the sinking skin flap following decompressive craniectomy. *Neurol Med Chir (Tokyo)* 1977;17:43-53.
2. Beumer J 3rd, Firtell DN, Curtis TA. Current concepts in cranioplasty. *J Prosthet Dent* 1979;42:67-77.
3. Martin JW, Ganz SD, King GE, Jacob RF, Kramer DC. Cranial implant modification. *J Prosthet Dent* 1984;52:414-6.
4. Joseph TM, Ravichandran R, Harshakumar K, Lylajam S. Prosthetic rehabilitation in neurosurgical cranioplasty. *J Indian Prosthodont Soc* 2018;18:76-81.
5. Schupper N. Cranioplasty prostheses for replacement of cranial bone. *J Prosthet Dent* 1968;19:594-7.
6. Bandyopadhyay TK, Thapliyal GK, Dubey AK. Reconstruction of cranial defects in armed forces personnel-Our experience. *Med J Armed Forces India* 2005;61:36-40.
7. Aquilino SA, Jordan RD, White JT. Fabrication of an alloplastic implant for the cranial defect. *J Prosthet Dent* 1988;59:68-71.
8. Jordan RD, White JT, Schupper N. Technique for cranioplasty prosthesis fabrication. *J Prosthet Dent* 1978;40:230-3.
9. Pavaiya A, Tyagi VK, Tripathi A, Singh SV, Chand P. Cranioplasty with alloplastic cranial implant. *J Indian Prosthodont Soc* 2009;9:109-11.
10. Koltz BP, Vanderploeg RD, Curtiss G. Development of the key behaviors change inventory: A traumatic brain injury behavioral outcome assessment instrument. *Arch Phys Med Rehabil* 2003;84:277-84.