

Phlegmasia Cerulea Dolens and May–Thurner Syndrome in the first trimester of Pregnancy

Aliya B. Ladha, MS, MD¹ Rizwana Fareeduddin, MD, FACOG²

¹Department of Obstetrics, Gynecology and Reproductive Sciences, Magee-Women’s Hospital of UPMC, Pittsburgh, Pennsylvania
²Maternal Fetal Medicine, North Florida Regional Medical Center, Gainesville, Florida

Address for correspondence Aliya B. Ladha, MS, MD, Magee-Women’s Specialty, 100 Matthew Drive, Uniontown, PA 15401 (e-mail: aliyalb@upmc.edu).

Am J Perinatol Rep 2016;6:e71–e73.

Abstract

Keywords

- ▶ venous thromboembolism
- ▶ May–Thurner syndrome
- ▶ pregnancy
- ▶ phlegmasia cerulea dolens

Background Venous thromboembolism in pregnancy remains one of the leading causes of morbidity and mortality.

Case A young, gravid patient presented with a cyanotic, edematous left lower extremity with no distal pulses palpable. She was emergently taken to the operating room and was found to have extensive iliofemoral thrombosis requiring femoral angioplasty and embolectomy with 43.7-rad intraoperative radiation exposure. Phlegmasia cerulea dolens and May–Thurner syndrome were diagnosed.

Conclusion Timely diagnosis and prompt surgical management are necessary due to the limb-threatening nature of this condition. Despite maternal radiation exposure, the nature and extent of fetal effects depends upon radiation dose and gestational age.

Background

May–Thurner syndrome is a rare congenital anomaly in which the right iliac artery abnormally passes over the left iliac vein causing venous hypertension with or without left iliofemoral deep vein thrombosis. Phlegmasia cerulea dolens is a rare condition involving total or near-total intravenous thrombotic obstruction that can rapidly progress to limb ischemia and venous gangrene. Pregnancy increases the risk of venous thromboembolism by four- to fivefold.¹ Approximately 90% of deep venous thrombosis (DVT) in pregnancy are located on the left side due to compression of the left iliac vein. The expected left-sided predominance of DVT in pregnancy may delay recognition of May–Thurner syndrome.² We report a case of a gravid patient with acute limb ischemia and total intravenous thrombotic obstruction secondary to May–Thurner syndrome and phlegmasia cerulea dolens requiring angiography, ultimately resulting in a viable, appropriately grown neonate.

Case Presentation

A 30-year-old African American female, gravida 3 para 1011, at 8 weeks 3 days of gestation by last menstrual period,

presented with 12-hour history of low back pain, which acutely progressed within 2 hours to left lower extremity pain. The patient reported motor and sensory deficits including numbness and tingling with a subsequent inability to bear weight. The patient denied any recent travel, trauma, or fall. The patient’s medical history was significant for ulcerative colitis with an exacerbation 2 months prior for which she was taking mesalamine three times daily. There was no personal or family history of thromboembolic disease. She had no prior history of other thromboembolic risk factors such as estrogen-containing oral contraceptive use, obesity (her body mass index was 18), or smoking. She had an uncomplicated spontaneous vaginal delivery 2 years earlier.

Upon presentation, the patient was in acute distress secondary to pain. Her respiratory rate was 18, pulse rate 102, blood pressure 149/89, and oxygen saturation was 98% on room air. On physical exam, her left lower extremity was noted to be mottled, warm, edematous, and tender to palpation with no dorsal pedis or tibialis posterior pulses palpable (→ Fig. 1. Bedside Doppler also revealed absent pulses. Unfractionated heparin load of 3,000 units was given intravenously followed by an intravenous infusion and the patient was emergently taken to the operating room.

received
 June 8, 2015
 accepted after revision
 September 18, 2015
 published online
 November 16, 2015

DOI <http://dx.doi.org/10.1055/s-0035-1566250>.
 ISSN 2157-6998.

Copyright © 2016 by Thieme Medical Publishers, Inc., 333 Seventh Avenue, New York, NY 10001, USA.
 Tel: +1(212) 584-4662.

License terms



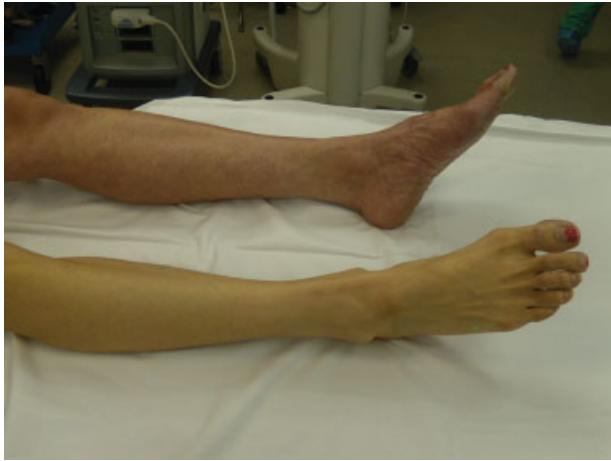

Fig. 1 Cyanosis of affected left limb.

Intraoperative duplex ultrasonography demonstrated marked dilatation of the left common femoral and external iliac vein. Additionally, the left popliteal and tibial veins were markedly dilated and noncompressible, suggesting extensive iliofemoral thrombosis. Phlegmasia cerulea dolens and May–Thurner syndrome were diagnosed. Given the extensive thrombus and severity of ischemia, the patient underwent four-compartment fasciotomy with left iliofemoral venous thromboembolectomy, left popliteal and tibial vein embolectomy, chemical and mechanical thrombolysis of left common iliac vein with a Trellis device, balloon angioplasty of the left common femoral vein, and placement of a left iliac vein stent (→**Fig. 2**). At the completion of the procedure, the patient gained reestablishment of perfusion in the left lower extremity.

Prior to surgery, the patient and family were counseled regarding the risks associated with angiography and radiation exposure to the fetus in order for limb salvage. The intraoperative cumulative dose of radiation exposure to the patient was 43.7 rad.

Postoperatively, the patient was observed in the intensive care unit where she was treated with volume repletion and

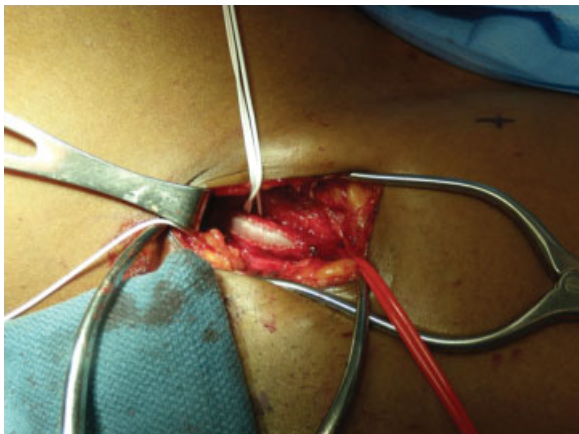


Fig. 2 Left iliac vein.

transfused a total of three units of packed red blood cells. She remained on systemic infusion of heparin with a goal of an activated partial thromboplastin time of 1.5 to 2.0 times the control value. She was subsequently bridged to enoxaparin for anticoagulation antepartum and was given 60 mg every 12 hours. On postoperative day 4, a left lower extremity duplex Doppler revealed normal compressibility of the femoral and popliteal veins and normal patency of the left common iliac vein stent. By postoperative day 5, the patient was ambulating with physical therapy and was discharged home in stable condition.

The patient's obstetric care was continued at a different facility. At 36 weeks of gestation, the patient was converted from therapeutic enoxaparin to unfractionated heparin for anticoagulation in the last month of pregnancy. It does not appear that anti-Xa levels were followed during her pregnancy. At 39 weeks and 1 day of gestation, labor was induced by intravenous oxytocin administration followed by cervical ripening with misoprostol. Labor proceeded uneventfully and a male infant weighing 3,155 g was born with Apgar scores of 9 at both 1 and 10 minutes. The third stage of labor was uncomplicated and estimated blood loss at delivery was 300 mL. Twelve hours after delivery, therapeutic enoxaparin was resumed, which the patient continued for 6 weeks postpartum.

Discussion

A rare and serious complication of iliofemoral DVT is phlegmasia cerulea dolens, first described in the 16th century by Fabricius Hildanus and later in 1938 by Gregoire as ischemia-associated massive venous thrombosis.³ The affected limb becomes ischemic, edematous, extremely painful, and cyanotic (a pathognomonic finding) due to near-total venous occlusion.⁴ Phlegmasia cerulea dolens is limb-threatening and life-threatening with amputation rates of 12 to 50% and mortality rates of 20 to 40%.^{3,5} Risk factors include malignancy, hypercoagulable syndrome, trauma, heart failure, ulcerative colitis, and May–Thurner syndrome.^{4,5} Our patient was diagnosed with the latter two risk factors in addition to pregnancy. May–Thurner syndrome has been reported to occur in 2 to 5% of patients undergoing DVT evaluation and tends to occur more frequently in women.^{2,5} However, there is a paucity of data related to this condition in pregnancy. May–Thurner syndrome confers an anatomic predisposition to vein compression resulting in endothelial damage and decreased venous flow. A hypercoagulable state such as pregnancy can place these patients at high risk of developing thrombosis. May–Thurner syndrome should be considered when pregnant patients present with left-sided iliofemoral vein thrombosis. Contrast venography demonstrating a flattening or narrowing of the iliac vein at the pelvic brim is the gold standard for May–Thurner syndrome diagnosis. There are no management guidelines for pregnant women with May–Thurner syndrome and iliofemoral DVT. Anticoagulation with intravenous heparin may prevent further clot formation and propagation as well as the development of pulmonary embolism. However, due to the coexisting

anatomic compression, patients are still at very high risk of developing debilitating postthrombotic syndrome characterized by chronic pain, swelling, and ulceration of the affected extremity. More aggressive treatment including catheter-directed thrombolysis, mechanical thrombectomy, angioplasty and stent placement, fasciotomy, and placement of an inferior vena cava filter has been reported to improve prognosis in nonpregnant patients.^{2,4,5} Several authors have reported 1- to 2-year patency rates ranging from 92 to 100% in patients receiving stent placement.^{5,6} Suwanabol et al recommend stent placement as an essential component of treatment in patients with May–Thurner syndrome due to the acquired nature of mechanical obstruction.⁵ These treatments have traditionally been avoided in pregnancy due to concern for fetal radiation exposure.

The effects of ionizing radiation on pregnancy are determined by the radiation dose and the trimester of pregnancy. Pregnancy loss is most likely a result of high-dose radiation in the first trimester. Radiation induces cell death likely inhibiting the implantation of an embryo, resulting in miscarriage.⁸ Animal studies show doses as small as 10 to 20 rad can be lethal for a 3- to 4-week gestation.⁹ Interestingly, however, malformation rates of surviving embryos during this preorganogenesis stage are similar to nonradiated controls, thus confirming the “all-or-none” phenomenon seen in animal models.^{6,7} Our patient presented in this case report was counseled on this phenomenon prior to surgery, although the cumulative dose of radiation exposure was unknown at the time. It is reported that the fetal radiation dose resulting from pharmacomechanical catheter-directed thrombolysis in the first trimester can be as high as 25 rad, which is associated with a childhood risk of 1.3 to 2%.⁸ Malformations such as microcephaly, microphthalmia, growth restriction, and cataracts may occur between 3 and 8 weeks of gestation.⁶ Development of the fetal central nervous system occurs between gestational weeks 8 and 25; therefore, cognitive and/or behavioral deficits may occur if in utero exposure exceeds radiation doses of 35 to 50 rad during this period.⁶

Fetal radiation doses from radiographic or fluoroscopic examinations rarely exceed 25 mGy (2.5 rad). If the uterus is outside the field of view, the fetus is exposed to scattered radiation only and the fetal dose is minimal. Higher dose values occur when the uterus is positioned within the field of view. The maternal tissue attenuates the fetal absorption and for fluoroscopy or radiography, and when discussing dose limits, the value applies to the fetal dose. For example, a personal dosimeter worn at the waist by diagnostic radiology workers is likely to overestimate fetal dose.⁹ If the dosimeter is worn outside a lead apron, the measured dose is a significant overestimate and, while it can be used as an upward bound on fetal dose if no other information is available, is not recommended for use in estimating fetal dose. Fetal doses are not likely to exceed 25% of the personal dosimeter measure-

ment. It is thought that for fluoroscopy, fetal dose can be conservatively estimated as 0.15 times the entrance skin dose.⁹

In our patient's case, her dose was estimated to be 43.7 rad; therefore, the estimated fetal dose would be 6.5 rad. At 6 months of age, the infant of the patient in this case report was reported to demonstrate appropriate neurobehavioral milestones. Currently, there is no known threshold radiation dose for which detrimental effects on a fetus may occur. The American College of Obstetricians and Gynecologists has suggested that the threshold for medical concern and congenital malformations should be 5 rad.⁶

Although rare, occlusive thrombosis of the lower extremity deep veins can lead to significant morbidity, including arterial compromise, gangrene, and, ultimately, amputation. In patients with extensive pelvic and lower extremity thrombosis as in the present case, prompt diagnosis and aggressive endovascular treatment can result in optimal outcomes. To the best of our knowledge, this is the first report of a patient with phlegmasia cerulea dolens and May–Thurner syndrome during the antepartum period of pregnancy resulting in complete limb salvage and a viable, appropriately grown neonate with no congenital deficits apparent at the time of delivery following radiation exposure.

References

- 1 Thromboembolism in Pregnancy. ACOG Practice Bulletin. Number 123, August 2011
- 2 Nakajima Y, Masaoka N, Tsuzuki Y, Morooka M, Sakai M. May-Thurner syndrome resulting in acute iliofemoral deep vein thrombosis during the second trimester of pregnancy. *J Obstet Gynaecol Res* 2012;38(8):1106–1110
- 3 Veltchev LM, Kalniev MA, Todorov TA. Phlegmasia cerulea dolens—risk factors and prevention. Case report. *J IMAB Annu Proc* 2009;Book 1:89–91
- 4 Marques Filho J. Phlegmasia cerulea dolens in patient with systemic lupus erythematosus in the remote postpartum period. *Rev Bras Reumatol* 2011;51(5):514–516
- 5 Suwanabol PA, Tefera G, Schwarze ML. Syndromes associated with the deep veins: phlegmasia cerulea dolens, May-Thurner syndrome, and nutcracker syndrome. *Perspect Vasc Surg Endovasc Ther* 2010;22(4):223–230
- 6 Groen RS, Bae JY, Lim KJ. Fear of the unknown: ionizing radiation exposure during pregnancy. *Am J Obstet Gynecol* 2012;206(6):456–462
- 7 Brent RL. Saving lives and changing family histories: appropriate counseling of pregnant women and men and women of reproductive age, concerning the risk of diagnostic radiation exposures during and before pregnancy. *Am J Obstet Gynecol* 2009;200(1):4–24
- 8 Bloom AI, Farkas A, Kalish Y, Elchahal U, Spectre G. Pharmacomechanical catheter-directed thrombolysis for pregnancy-related iliofemoral deep vein thrombosis. *J Vasc Interv Radiol* 2015;26(7):992–1000
- 9 Wagner LK, Lester RG, Saldana LR. Exposure of the Pregnant Patient to Diagnostic Radiations: A Guide to Medical Management. 2nd ed. Madison, WI: Medical Physics Publishing; 1997