

An Extremely Rare Case Report of Aphallia with Horseshoe Kidney and Ureterohydronephrosis

Tigabu Daniel ¹, Yonas Abera²

¹Surgery Department, Hawassa University, Hawassa, Ethiopia; ²Surgery Department, Ethiopian Defense University, Addis Ababa, Ethiopia

Correspondence: Tigabu Daniel, Email danieltigabu96@gmail.com

Background: Aphallia (absent penis) is an extremely rare congenital anomaly happening in 1 in 30 million births worldwide. It can occur alone or in combination with other congenital anomalies.

Case Presentation: A two-day-old neonate presented to Arba Minch General Hospital with an absent penis. The delivery was performed at home by a 34-year-old primigravida mother with no antenatal follow-up. As the mother described, the baby cried immediately after birth. The baby was sucking initially but failed to suck hours after delivery. The neonate died of neonatal distress syndrome after two hours of resuscitation.

Conclusion: Aphallia is a complex, extremely rare congenital anomaly that is commonly associated with other congenital anomalies. Sometimes, it may be associated with a lethal anomaly and requires sophisticated workup to diagnose and treat grave anomalies early.

Keywords: aphallia, penis, horseshoe kidney

Introduction

Aphallia is an extremely rare congenital anomaly. It can occur either alone or with other congenital anomalies.¹⁻⁶ It is an absent genital tubercle or the absence of progression of the genital tubercle to the penis.¹ To date, only 80–100 cases have been reported.⁷ It is typically characterized by an absent penis, well-developed scrotal rugae, normal bilateral testes normal serum testosterone levels, and an XY karyotype.⁴ Aphallia can have multiple associated anomalies and one of the mortality causes will be renal pathology by causing oligohydramnios and then hypoplastic lung that will be incompatible with extra uterine lifetime.¹ The urethral opening is commonly between the scrotum and anal orifice but can manifest as a urethrorectal fistula.³ The diagnosis was clinically confirmed.⁷ The treatment options were sophisticated and needed a multidisciplinary approach including family involvement. Gender determination also depends on family decisions and existing anatomic structures.^{1,6,7}

Case Report

A two-day-old neonate was brought to the hospital with an absent penis. The baby was born to a 34-year-old primigravida mother with no antenatal follow-up. The delivery was at home and the baby cried immediately after birth. He was sucking well after birth, but failed hours later. The infant was tachypneic and, had subcostal and intercostal retraction, bilateral fine crackles on auscultation, and respiratory distress. He was 2.8 kg weight at the time of arrival. Absent penis, well-formed scrotal rugae, and normally descended bilateral testis (Figure 1). The urethral opening was absent in the perineum and scrotal folds. The urine passes through the rectum, but it is difficult to localize the urethral orifice in the rectum. The anal opening and sphincter were normal. The results of other system examinations were normal.

The white blood cell count was normal for age, serum electrolytes were within the normal range (sodium 142meq/l and potassium 4.8meq/l), and serum creatinine was 2.8_mg/dl. Abdominal ultrasonography revealed a horseshoe kidney and bilateral ureterohydronephrosis on the bedside. The echocardiographic findings were normal. Because the patient was critical and had no portable X-rays, chest X-rays, and other sophisticated investigations were not performed. The patient was resuscitated and tried to stabilize, but died after a 2-hour stay in the neonatal intensive care unit because of neonatal distress syndrome. The family refused postmortem examination.

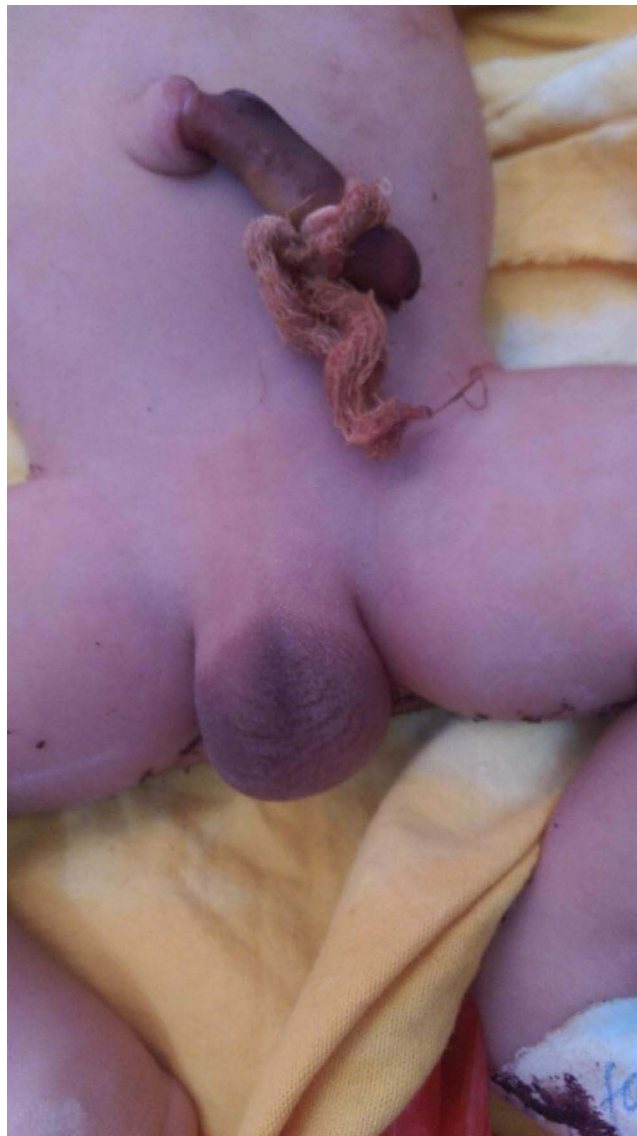


Figure 1 Absent penis and well-formed scrotum.

Discussion

Aphallia is an extremely rare congenital anomaly. It can occur either alone or with other congenital anomalies.^{1–6} It is absent genital tubercle or the absence of progression of the genital tubercle to the penis.^{1,5} To date, only 80–100 cases have been reported.^{7,8} It is typically characterized by an absent penis, well-developed scrotal rugae, normal bilateral testes, normal serum testosterone levels, and an XY karyotype.^{3,9} The urethral opening is commonly between the scrotum and anal orifice but can manifest as a urethrorectal fistula.^{3,9} Among the three anatomical classifications of urethral opening (post-sphincteric, pre-sphincteric, and urethral atresia), urethral atresia is 100% lethal.⁹ The diagnosis is commonly made clinically.⁷ More than half of the patients with aphallia have concomitant urogenital, gastrointestinal, cardiovascular, and musculoskeletal anomalies.⁸ Thus, the isolated aphallia were less likely to be identified. Treatment is individualized, and multistage reconstructive surgery and hormonal supplementation are needed.¹⁰ In addition, the involvement of a multidisciplinary medical team is required.

Some neonates will have less-developed lungs and will not survive beyond the early neonatal period, as in our patients.¹¹ El Qadiry et al reported ureterohydronephrosis associated with aphallia, similar to our case.¹ Since the mother had no antenatal follow-up, it was difficult to determine amniotic fluid status. Our patient had a rare anomaly (horseshoe) that has not yet been reported.

Our patient died after a two-hour resuscitation trial, possibly because of an immature lung leading to neonatal respiratory distress syndrome, as reported by El Qadiry et al.¹ Still, there was a chance of having uremia but the creatinine was not aggressively raised.

Conclusion

Aphallia is an extremely rare complex congenital anomaly that is commonly associated with other congenital anomalies. Sometimes, it may be associated with a lethal anomaly and requires sophisticated workup to diagnose and treat grave anomalies early.

Data Sharing Statement

The data in this case report will be accessed through the Corresponding author contact addresses (danielgabu96@gmail.com).

Ethical Review

Written informed consent was obtained from the family for the publication of this case report. According to the Arba Minch University IRB guideline, an IRB approval letter is not needed for publication.

Acknowledgments

My deepest gratitude goes to the family.

Funding

There is no financial support.

Disclosure

The authors report no conflicts of interest in this work.

References

1. Sharma D, Singh R, Shastri S. A case report of aphallia with urorectal septum malformation sequence in a newborn: a very rarely seen condition. *Int Med Case Rep J*. 2015;8:317–320.
2. Sasirekha M, Kumar AA. A case report of aphallia. *J Evol Med Dent Sci*. 2014;3(12):3087–3089. doi:10.14260/jemds/2014/2248
3. El Qadiry R, Lalaoui A, Nassih H, Bourrahout A, Ait Sab I, Takaya J. A new presentation: aphallia, vesicoureteral reflux, rectovesical fistula, and adrenal insufficiency. *Case Rep Pediatr*. 2020;2020:1–3. doi:10.1155/2020/8826520
4. Pan P. Aphallia: an extremely rare congenital anomaly. Report of two cases. *Acta Sci Paediatr*. 2019;2(9):67–69. doi:10.31080/ASPE.2019.02.0133
5. Gupta A, Gupta H. Aphallia: a rare congenital anomaly. *JK Sci*. 2008;10(3):142–143.
6. Palacios-Juárez J, Hanson-Viana E, Rodríguez-Quintero JH, Morales-Maza J. Aphallia: do sociocultural issues affect treatment decisions? *BMJ Case Rep*. 2018;2018:1–2.
7. si LS, Yang Z, Xin WW, et al. Congenital aphallia associated with congenital urethrorectal fistula: a rare case report. *Medicine*. 2022;101(7):1–5.
8. Med SJ, Rep C, Sk J, et al. Aphallia: an adult presentation. *Sch J Med Case Rep*. 2014;2(8):515–517.
9. Faiz N, Kumar A. Aphallia: case report and review of the literature. *Saudi Surg J*. 2015;3(1):13. doi:10.4103/2320-3846.153801
10. Sathaye S, Sathaye U. Isolated aphallia: a case report and review of the literature. *African J Urol*. 2023;29(1):10–12.
11. Carter L, Bozick C. P140: aphallia: a complex case of a rare anomaly. *Genet Med Open*. 2023;1(1):100169. doi:10.1016/j.gimo.2023.100169

International Medical Case Reports Journal

Dovepress

Publish your work in this journal

The International Medical Case Reports Journal is an international, peer-reviewed open-access journal publishing original case reports from all medical specialties. Previously unpublished medical posters are also accepted relating to any area of clinical or preclinical science. Submissions should not normally exceed 2,000 words or 4 published pages including figures, diagrams and references. The manuscript management system is completely online and includes a very quick and fair peer-review system, which is all easy to use. Visit <http://www.dovepress.com/testimonials.php> to read real quotes from published authors.

Submit your manuscript here: <https://www.dovepress.com/international-medical-case-reports-journal-journal>