

Rhinolith in the concha bullosa as a rare location: a case report

Journal of International Medical Research
48(8) 1–4

© The Author(s) 2020

Article reuse guidelines:

sagepub.com/journals-permissions

DOI: 10.1177/0300060520951019

journals.sagepub.com/home/imr



Tolga Ersözlü  and Erdogan Gültekin

Abstract

The presence of a rhinolith is a rare condition, which can cause long-standing symptoms, such as rhinorrhea, foul-smelling discharge, nasal obstruction, and headache. A rhinolith is usually easily diagnosed by a clinical examination and a paranasal computed tomographic scan. Rhinoliths are usually found in nasal cavities, but rare locations are also possible. We report a patient who was evaluated in our clinic for nasal obstruction, headache, and snoring symptoms. A clinical examination showed no major findings, but a paranasal computed tomographic scan of coronal sections showed a hyperdense mass within the right concha bullosa. A rhinolith in the concha bullosa is a rare condition. Our case is the third case of a rhinolith in the concha bullosa to be reported in the literature.

Keywords

Rhinosinusitis, upper respiratory infection, rhinolith, nasal obstruction, computed tomography, concha bullosa

Date received: 9 March 2020; accepted: 28 July 2020

Introduction

A rhinolith is a hard mass that can be formed over time in nasal cavities after calcification of an endogenous or exogenous nidus. Exogenous rhinoliths arise from non-human materials, such as beads, buttons, erasers, fruit seeds, and similar foreign bodies, which are usually inserted into the nasal cavities, mostly in children. Although endogenous rhinoliths arise from endogenous materials, such as ectopic teeth, dried blood clots, and epithelial debris, they may act like foreign bodies and cause nidus formation for mineralization.

If a foreign body within the nasal cavity is asymptomatic and/or remains undiagnosed, it is commonly diagnosed as a rhinolith

Namık Kemal University, Department of Otorhinolaryngology, Head and Neck Surgery, Tekirdağ, Turkey

Corresponding author:

Tolga Ersözlü, Department of Otorhinolaryngology, Head and Neck Surgery, Namık Kemal University, Faculty of Medicine, Kampüs Cad. No. 1/14, Sağlık Uygulama ve Araştırma Merkezi, 59100 SüleymanPaşa/Tekirdağ, Turkey. Email: tolga76@hotmail.com



many years later. Although foreign bodies in nasal cavities are more common and mostly found in children, rhinoliths are rare, but more common in adults.¹ Symptoms of rhinoliths are usually nasal obstruction, continuous discharge, headache, nasal malodor, halitosis, and intermittent epistaxis. Some cases are asymptomatic and can be found incidentally.

Rhinoliths that have a high radiodensity can be easily detected using a plain X-ray. However, rhinoliths that have a low radiodensity need to be detected by computed tomography (CT).² CT is helpful for understanding the location and extent of the foreign body, and if surgery is required, CT is also useful in preoperative visualization of anatomical variations. A rhinolith can also be found as an underlying cause while evaluating pathologies, such as septal perforation or resistant chronic sinusitis.

We report here an extremely rare case where a rhinolith was found inside a concha bullosa.

Case report

A 59-year-old male patient was admitted to our ear, nose, and throat clinic with nasal obstruction, headache, and snoring complaints for approximately 5 years. He did not have any other symptoms, such as nasal discharge, foul smelling discharge, or epistaxis. Anterior rhinoscopy showed no

abnormality, except for bilateral hypertrophic inferior nasal conchae. A 0° rigid nasal endoscopic examination showed bilateral hypertrophic inferior conchae, no abnormality within the nasal cavities, normal mucosal lining, and a normal nasopharynx.

He mentioned that he was diagnosed and treated for allergic rhinitis 1 year previously, but his complaints did not improve. He was not under any medication for 6 months, and he had not been diagnosed with any systemic disease. When the patient presented to the clinic, no imaging technique was performed. Therefore, he underwent CT imaging. A coronal paranasal CT scan showed minimal septal deviation to the left side, bilateral hypertrophic inferior conchae, and bilateral aerated middle conchae, which is called concha bullosa. A hyperdense mass within the right concha bullosa was observed, and it was evaluated as a rhinolith (Figure 1).

The patient underwent endoscopic sinus surgery under general anesthesia. During the surgery (Supplemental Video 1), the right-sided concha bullosa was resected and the rhinolith was removed (Figure 1). A histopathological examination showed fragments of non-viable tissue with an area of calcification, which was determined as a rhinolith.

At 2 weeks of follow-up after surgery, the patient was relieved of all of his

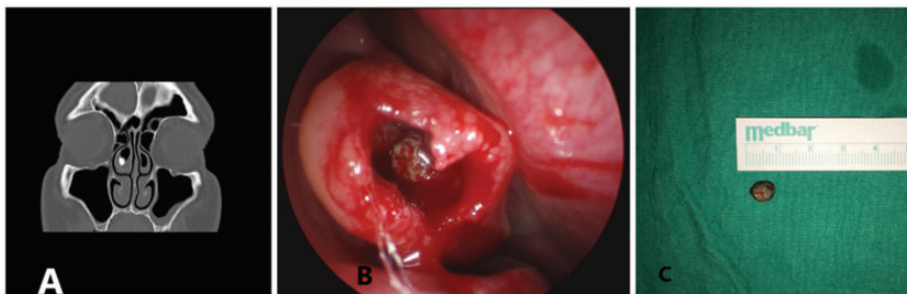


Figure 1. (a) Paranasal computed tomographic scan showing a rhinolith within the right concha bullosa before surgery. (b) A rhinolith in the concha bullosa was observed in nasal endoscopy during the surgery. (c) Gross appearance of the extracted rhinolith.

symptoms, including nasal obstruction, headache, and snoring.

Discussion

Concha bullosa is defined as pneumatization of the middle concha. Concha bullosa is a common anatomical variation that can be unilateral or bilateral, and can cause nasal obstruction, headache, or be asymptomatic in some cases.

A rhinolith is a calcification of an endogenous or exogenous nidus that can be found anywhere in the upper respiratory tract, mostly in the nasal cavities. The first case of rhinolithiasis was reported by Bartholin in 1654, and more than 600 cases of rhinoliths have been reported since 1654.³ A rhinolith is usually formed by insertion of a foreign object in the nasal cavity, which causes a local inflammatory reaction, leading to mineralization and calcification.³ Foreign bodies can be found in the head and neck cavities. However, mineralized accumulation in the paranasal sinus, concha bullosa, and nasopharynx is rare. Although nidus is necessary for the onset of rhinolith, other factors contribute to formation of a rhinolith. These factors include stagnation of nasal secretion, chronic inflammation, accumulation of calcium and magnesium salts, and enzymatic activity of bacterial pathogens.⁴

Unfortunately, the diagnosis of rhinolithiasis is often overlooked. This is because rhinolithiasis is ignored in differential diagnosis. Rhinoliths continue to grow because of vague symptoms for a long time. These symptoms usually can be ignored by the patient. The most frequent symptoms of rhinolithiasis are unilateral discharge, which is usually bloody, nasal obstruction, intermittent epistaxis, and malodor. In rare cases, perforation of the nasal septum or palate is also possible.⁵

After a clinical examination and radiological scans, a hyperdense mass is suspected for rhinoliths, but differential diagnosis should be carefully made to exclude other

possible causes for masses, such as ossifying fibroma, hemangioma, osteoma, calcified nasal polyps, chondroma, dermoid tumor, osteosarcoma, chondrosarcoma, calcified angiofibroma, fungal infections, and chronic granulomatous infections, which could change treatment approaches.^{4,6} Akkoca et al.⁷ reported the most common localization of rhinoliths was between the inferior concha and nasal septum. Although the most common accompanying paranasal variation was septal deviation, concha bullosa was also observed in some patients. However, no rhinolith was in a concha bullosa in their case series.

Even though a concha bullosa is the most common anatomical variation of the osteomeatal complex region,^{2,7,8} a rhinolith in the concha bullosa is relatively rare. The first case of a rhinolith in the concha bullosa was reported by Dursun et al.⁹ in 2003. They reported a radiopaque mass within the left middle concha as a rhinolith. The second related case was reported by Baykara et al.¹⁰ in 2017. They reported a rhinolith in an aerated middle nasal turbinate, which was diagnosed by coronal CT imaging, and the patient denied any surgical treatment and follow-up. Our case is the third case of a rhinolith in the concha bullosa to be reported. Unlike the cases of rhinoliths reported by Dursun et al.⁹ and Baykara et al.,¹⁰ our patient showed severe signs of infection and nasal obstruction.

Turbulent air is hardly sufficient alone to trigger formation of a stone. There are several conditions for development of such a lesion as follows: acute or chronic inflammation of the nasal mucosa with consecutive suppuration due to a foreign body; putrid discharge with a high content of calcium and/or magnesium; mechanical obstruction that blocks the outflow of pus and mucus; and secretion must be exposed to a current of air (turbulent air) to concentrate pus and mucus, and permit mineral salts to precipitate, thus leading to incrustation (stone formation). In all

cases of rhinolithiasis, treatment is removal of the rhinolith by a surgical procedure under general or local anesthesia depending on the location and size of the rhinolith and the age of the patient.

Conclusion

Although rhinolithiasis is a rare condition, it should be considered while evaluating patients who have long-standing and treatment-resistant symptoms. Paranasal CT is helpful for diagnosis and differential diagnosis of this condition. Treatment of a rhinolith, regardless of its location, is always its extraction. Extraction can be performed under local anesthesia or general anesthesia according to the location and size of the rhinolith and the age of the patient.

Authors' contributions

T.E. designed and conceived the study, performed data collection and processing, searched the literature, and wrote the manuscript. E.G. supervised the study, analyzed and interpreted the data, and critically reviewed the manuscript.

Declaration of conflicting interest

The authors declare that there is no conflict of interest.

Ethics statement

Ethics committee approval was not obtained because this was a case report and no research protocol was applied for. Written and verbal informed consent was obtained from the patient for publication.

Funding

This research received no specific grant from any funding agency in the public, commercial, or not-for-profit sectors.

ORCID iD

Tolga Ersözlü  <https://orcid.org/0000-0001-8629-6022>

Supplemental material

Supplemental material for this article is available online.

References

1. Keck T, Liener K, Sträter J, et al. Rhinolith of the nasal septum. *Int J Pediatr Otorhinolaryngol* 2000; 53: 225–228. doi:10.1016/s0165-5876(00)82011-x.
2. Chatziavramidis A, Kondylidou-Sidira A, Stefanidis A, et al. Longstanding rhinolith leading to anatomical alterations of the ipsilateral inferior nasal meatus and turbinate. *BMJ Case Rep* 2010; 2010: bcr0720103155. doi:10.1136/bcr.07.2010.3155.
3. Pitt SK and Rout PG. Rhinoliths presenting during routine radiography: two cases. *Dent Update* 2000; 27: 505–507.
4. Hadi U, Ghossaini S and Zaytoun G. Rhinolithiasis: a forgotten entity. *Otolaryngol Head Neck Surg* 2002; 126: 48–51. doi:10.1067/mhn.2002.121018
5. Aziz Y, Chauhan J, Hasan SA, et al. Staghorn rhinolith in nasopharynx: an unusual case. *Indian J Otolaryngol Head Neck Surg* 2008; 60: 91–93.
6. Yuca K, Caksen H, Etlik O, et al. The importance of rigid nasal endoscopy in the diagnosis and treatment of rhinolithiasis. *Auris Nasus Larynx* 2006; 33: 19–22.
7. Akkoca Ö, Tüzüner A, Demirci Ş, et al. Patient Characteristics and Frequent Localizations of Rhinoliths. *Turk Arch Otorhinolaryngol* 2016; 54: 154–157.
8. Koo SK, Kim JD, Moon JS, et al. The incidence of concha bullosa, unusual anatomic variation and its relationship to nasal septal deviation: A retrospective radiologic study. *Auris Nasus Larynx* 2017; 44: 561–570.
9. Dursun E, Korkmaz H, Bayiz U, et al. Concholith: an unusual case. *Otolaryngol Head Neck Surg* 2003; 128: 764–765.
10. Baykara M, Polat C, Vicdan H, et al. First, Described A Rhinolith Case In An Aerated Middle Nasal Turbinate. *Medical Journal of Kahramanmaraş Sütçü İmam University* 2017; 12: 73–75.