

A retrospective cross-sectional study of maxillofacial trauma in Delhi-NCR Region

Lokesh Chandra¹, D. Deepa², Mansi Atri³, Souvir Mohan Pandey⁴,
Deepak Passi⁵, Jyoti Goyal⁶, Abhimanyu Sharma¹, Utkarsh Gupta⁷

Departments of ¹Oral and Maxillofacial Surgery and ³Public Health Dentistry, ESIC Dental College and Hospital, Rohini, Delhi, ²Department of Oral and Maxillofacial Surgery, NSVK Sri Venkateshwara Dental College and Hospital, Bengaluru, Karnataka, ⁴Department of Prosthodontics, Teerthankar Mahaveer Dental College and Hospital, Moradabad, ⁶Department of Public Health Dentistry, ITSCDSR, Ghaziabad, Uttar Pradesh, ⁵Department of Dentistry, Subdivisional Hospital, Bundu, Ranchi, Jharkhand, ⁷Department of Public Health Dentistry, Post Graduate Institute of Dental Sciences, Rohtak, Haryana, India

ABSTRACT

Aim and Objectives: To evaluate the pattern, prevalence, etiology, site of fractures, and their management in patients with maxillofacial injury in Delhi-NCR region. **Materials and Methods:** A total of 1278 maxillofacial trauma patients visiting different registered hospitals from Delhi-NCR region from January 2012 to December 2017, treated by open reduction and internal fixation under general anesthesia (GA)/local anesthesia (LA) or closed reduction/conservatively, were taken into the study. The parameters considered in the study were age and sex distribution, etiological factors and incidence of maxillofacial trauma, pattern and site distribution of maxillofacial fractures, and management. **Results:** From a total of 2250 trauma patients, 1278 patients (1053 males and 225 females) had maxillofacial injury. The average prevalence rate was 56.8%. Yearly incidence rate was 20.4%. Road traffic accident (RTA) was the most common cause of trauma in 1029 (80.5%) patients, followed by physical assault [158 (12.3%)] with significant male predominance in different age groups. Isolated mandibular fractures were the most common [48.6% (parasymphysis 31.6%, condyle 28.2%)], followed by midface with maxilla fracture [27.6% (zygomatic bone and arch 50.2% and Lefort II fractures 18%)]. Treatment modalities were conservative management, closed reduction, and open reduction with internal fixation under GA/LA. **Conclusion:** RTA followed by physical assault is still the leading cause of maxillofacial trauma in young males in Delhi-NCR region. Mini plate osteosynthesis is the main treatment procedure for maxillofacial trauma. We need to enforce strict traffic rules, road safety law, and preventive measures along with improvement in education and socioeconomic status in the population to avoid maxillofacial injuries.

Keywords: Intermaxillary fixation, maxillofacial trauma, open reduction and internal fixation, road traffic accident, zygomatico complex

Introduction

Face is one of the most exposed parts of our body and is highly prone to traumatic injury. Maxillofacial injuries are the most common component involved along with other injuries in the emergency department. Maxillofacial region

is composed of upper face (frontal), midface (maxilla, nasal complex, and zygomatic), and lower face (mandible). Trauma to the maxillofacial region involves skeletal, dental, and soft tissue components of the face. The etiology of maxillofacial trauma in India differs in various regions due to difference in topography, increased urbanization, culture, environment, and socioeconomic factors. This difference may lead to a change in pattern incidence/prevalence of maxillofacial trauma. The

Address for correspondence: Dr. Deepak Passi,
Subdivisional Hospital, Bundu, Ranchi, Jharkhand, India.
E-mail: drdeepakpassi@gmail.com

This is an open access journal, and articles are distributed under the terms of the Creative Commons Attribution-NonCommercial-ShareAlike 4.0 License, which allows others to remix, tweak, and build upon the work non-commercially, as long as appropriate credit is given and the new creations are licensed under the identical terms.

For reprints contact: reprints@medknow.com

How to cite this article: Chandra L, Deepa D, Atri M, Pandey SM, Passi D, Goyal J, *et al.* A retrospective cross-sectional study of maxillofacial trauma in Delhi-NCR Region. J Family Med Prim Care 2019;8:1453-9.

Access this article online

Quick Response Code:



Website:
www.jfmprc.com

DOI:
10.4103/jfmprc.jfmprc_89_19

severity of trauma depends on the magnitude of impact force, its duration, acceleration produced, impact, and surface area on which impact occurs along with the etiology and mechanism of injury. Maxillofacial trauma is usually associated with other systemic injuries, thus multidisciplinary approach is required for their management.^[1]

The basic principle and methodology of fracture management, that is, reduction, fixation, and immobilization, is also applied to maxillofacial fractures. However, treatment outcome depends on other factors such as the degree of injury, type of fractures, maxillofacial surgeon expertise, experience, and the available technology.^[2] Over the past two decades, the epidemiology of maxillofacial trauma along with different variations in etiology, pattern of injuries, and their management have been constantly changing, hence continuous efforts in documenting these injuries and to follow recent evolution, developments, and the changing pattern of their management are required.

There are many epidemiological studies on maxillofacial trauma in different population and parts of India. However, there are still limited data on epidemiology of maxillofacial trauma in Delhi–NCR region of North India. An increased and updated knowledge of the cause and severity of facial trauma could help in effective treatment and preventive measures of maxillofacial trauma. Hence, this retrospective study was done to evaluate the pattern, prevalence of maxillofacial injury, etiology, site of maxillofacial fractures, and their management in patients in Delhi-NCR region.

Materials and Methods

A retrospective study of patients was carried out from January 2012 to December 2017 in the registered hospitals of Delhi-NCR region. A total of 2250 trauma patients visiting the emergency department/dental department of these hospitals during this study period were taken into the study. Inclusion criteria were patients between 15 and 65 years of age with maxillofacial trauma treated by open reduction and internal fixation (ORIF) under general anesthesia (GA)/local anesthesia (LA) or closed reduction. Exclusion criteria were pediatrics fracture, edentulous jaw fracture, dentoalveolar fracture, and fracture including base of skull or head injury component. The diagnosis of maxillofacial fracture was based on history, clinical examination of sign/symptoms of fracture, and interpretation of radiographs. The critical points considered in the study are age and sex distribution, etiological factors and incidence of maxillofacial trauma, pattern, and site distribution of maxillofacial fractures. The mandibular fractures were divided into condyle, ramus, angle, body, parasymphysis, and symphysis fractures.^[3] Midface fractures were divided into maxillary fractures (Le Fort I, II, III), zygomatic complex fractures, orbit fractures, nasal bone and complex fractures, and frontal bone fractures.

Various methods of treatment such as conservative management, closed reduction, intermaxillary fixation (IMF) for 4–6 weeks,

and open reduction and internal fixation with mini plates were used for management. The reasons for treatment choice were well-explained, and written informed consent was taken and documented. ORIF method was used for a large number of fractures treated in this study; good result was obtained with minimal complications and patient compliance.

Results

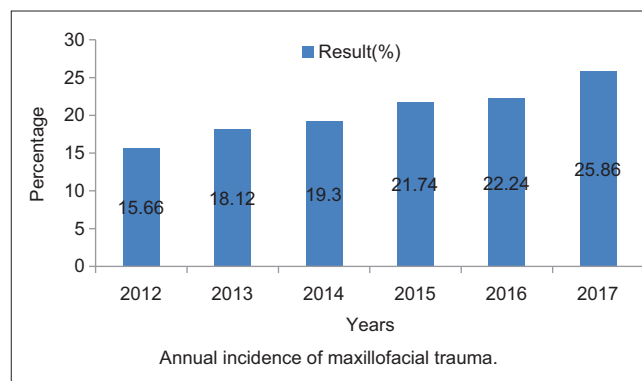
Data obtained from the study were documented in percentage. From a total of 2250 trauma patients reporting to the emergency department during 2012–2017, maxillofacial fracture was present in 1278 patients. The average prevalence rate was 56.8%. The average yearly incidence rate was 20.4%. Annual incidence of maxillofacial trauma was increased in the years of the study, that is, 2012–2017 [Graph 1].

Of 1278, 1053 were males and 225 were females. A significant male predominance was observed in different age groups with a male-to-female ratio of 4.6:1.

Road traffic accident (RTA) was the most common cause of trauma in 1029 (80.5%) patients observed in our study. The second most common cause of maxillofacial trauma was physical assault [158 (12.3%)] followed by fall from height and sport injury assault [91 (7.1%)].

Isolated mandibular fractures were the most common finding in maxillofacial trauma present in 622 (48.6%) patients followed by midface fracture seen in 354 (27.6%) patients. Combined maxilla and mandibular fracture was seen in 210 (16.43%) patients. Other sites for fractures of the face were nasal complex seen in 56 (4.3%), followed by orbital fracture in 26 (2%) patients and frontal bone fracture in 10 (0.7%) patients [Graph 2].

In the mandibular fracture sites, parasymphysis fracture was the most common fracture site involved in 197 (31.6%) cases followed by mandibular condyle in 175 (28.2%) cases. Other sites of fractures of the mandible in our study were angle in 121 (19.4%) cases, body in 78 (12.5%) cases, symphysis in 38 (6.2%) cases, and coronoid in 13 (2.1%) cases [Graph 3].



Graph 1: Annual incidence of maxillofacial trauma

Following mandibular fractures, midface fractures (27.6%) were the most common site for maxillofacial injury. Among midface, zygomatic complex fractures were the most common finding accounting for 50.2%, followed by Lefort II fracture of the maxilla (18%). Other fracture sites were nasal complex (15.8%), orbital fractures (7.3%), Lefort I fractures (3.6%), frontal bone fractures (2.8%), and Lefort III fractures (1.9%) [Graph 4].

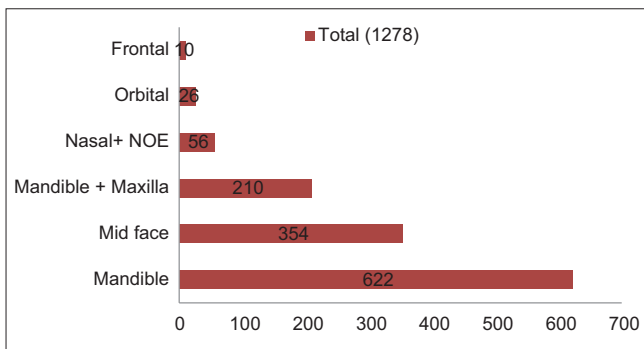
Treatment modalities given to patients involved in the study were conservative management, closed reduction/IMF for 4–6 weeks, and ORIF using 1.5/2-mm titanium mini plates followed by short-term IMF. Strict oral hygiene maintenance was advised to all patients with regular follow-up. Conservative treatment was done in 14.8% of the patients. They were managed conservatively under regular observation and follow-up by prescribing medication (antibiotics and analgesics) and were advised soft/liquid diet, limiting jaw movement, rest, and oral hygiene instructions. Closed reduction method was used in 32.4% of the patients. Manual reduction in fracture and IMF using Erich arch bar and elastics for 4–6 weeks was done followed by release of IMF and active mouth opening exercise. Most of the nasal complex fractures were treated by manual reduction, external nasal splint/plaster cast application. Few cases of zygoma fractures were managed by arch elevation without fixation. About 50.8% of the patients were treated by ORIF followed by short-term IMF. All panfacial fractures, displaced/unstable fractures, were treated by ORIF with titanium plates (1.5 mm for maxilla and zygoma and 2 mm for mandibular fractures)

under GA/LA. It was the most commonly used treatment modality for maxillofacial fractures [Graph 5]. Unfortunately, few cases (2%) refused to undergo treatment due to cost factor and compliance with IMF period and hence were discharged with direct interdental wiring; the consequence of nonunion and malunion was explained to them and they were included in conservative treatment methods.

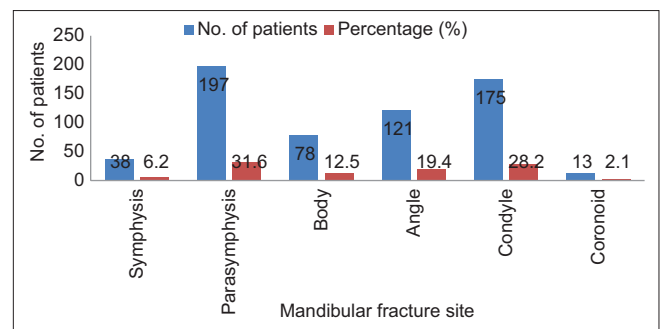
Discussion

Maxillofacial injury is one of the most commonly involved component following trauma patients presenting in the medical emergency department and is the major cause of death among people in the third to fourth decades of life.^[4] Maxillofacial injuries can affect both skeletal and soft tissue components of the facial structure and if not properly managed can negatively influence both the psychosocial and functional activities of the patients.^[5] Management of maxillofacial trauma is still a challenge for oral and maxillofacial surgeons as it requires both skill and experience.^[6]

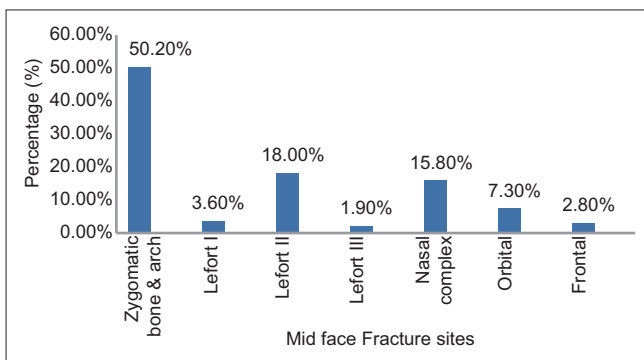
The etiology of maxillofacial trauma varies from one region to another along with different age groups. RTA is the leading cause of maxillofacial injury, mortality, and morbidity worldwide especially in younger population in developing countries, whereas physical assault is the main cause in developed countries.^[7] The common reasons for this high rate of RTA are poor road conditions, improper or no licensing, nonapplication of seat belts and helmets, traffic rules violations, and so on.^[8] Other causes



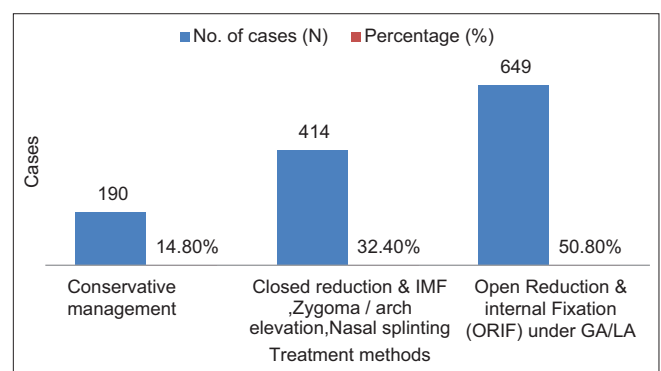
Graph 2: Distribution of facial fractures in maxillofacial trauma



Graph 3: Anatomical distribution of mandibular fractures in maxillofacial trauma



Graph 4: Anatomical distribution of midface fractures in maxillofacial trauma



Graph 5: Treatment modalities for maxillofacial trauma

are fall from height, sport injuries, occupational and domestic accidents, animal bites, and so on.

Our study shows that RTA is the most common cause of trauma in 1029 (80.5%) patients, followed by physical assault [158 (12.3%)] and fall from height and sport injury assault [91 (7.1%)]. This result is in correlation with the studies by Pandey and Roychoudhary and Singaram *et al.* Mohanavalli who demonstrated that RTA is the most common etiology of maxillofacial trauma.^[9-11] Demographic data of our study show that male (80.5%) predominantly suffered from maxillofacial trauma than females with a male: female ratio of 4.6:1. Similar results were reported by Septa *et al.*, Mohan, and Jagnoor concluding that a higher number of maxillofacial trauma occurs in males when compared with females. Also, medical literature shows a male: female ratio of up to 7:1. This can be attributed to the fact that males are mostly involved in outdoor jobs, social activities, traveling, driving profession, sports, and so on. Alcohol addiction and its influence with driving is also an important factor in male predominance of maxillofacial injury.^[12-14]

Regarding age distribution, the most common age group vulnerable to maxillofacial injuries was second to fourth decades of life especially between 25 and 35 years and it accounts for 41.1%. Our finding is in correlation with the findings by Chrcanovic *et al.*^[15] According to them, 21–30 years were the most frequently affected age group in maxillofacial trauma. Similar results were also reported by Udeabor *et al.* and Singaram *et al.*^[8,9]

Gross distribution of facial injury shows that isolated mandibular fracture was the most common fracture (48.6%) among total maxillofacial trauma, followed by isolated maxilla fracture (27.6%), combined maxilla and mandibular fracture (16.43%), fracture nasal complex [56 (4.3%)], orbital fractures (2%), and frontal bone fractures (0.7%). A similar result was also showed by Pandey and Roychoudhary and Ansari.^[10,16] This could be attributed to relatively more prominence of mandible and comparative lack of bony and soft tissue support. Also due to its anatomical location, free movement, and less support from cranium, mandible is more vulnerable to trauma. However, Singaram *et al.*, Subhasraj *et al.*, and Septa *et al.* observed that midfacial fracture was common than mandible specially zygomatic bone and arches.^[9,12,17] Erol *et al.* stated that pattern and trends in maxillofacial trauma are changing, and fracture of midface is increasing with RTA, fall, and assault.^[18] Arslan *et al.*^[19] in their studies showed that nasal bone fracture is the most common, and Dibaie *et al.*^[5] showed that zygomatic complex fractures are the most common in maxillofacial injuries.

In the mandibular fracture sites, parasymphysis fracture was the most common fracture site involved in 31.6% of cases. Our finding is in correlation with King Re *et al.* who observed that parasymphysis was the most common fracture site.^[20] Mandibular condyle was fractured in 28.2% of cases in our study. Al Ahmed He and Jaber observed 25% of involvement of condyle as the most common fracture site in their study.^[21] High incidence of parasymphysis and condyle fracture can be

explained by the fact that chin is one of the most prominent and movable parts and not wearing helmets or seatbelts while speeding may cause direct injury to chin resulting in anterior–posterior force transmission to condyle. Since parasymphysis region is anatomically weak, partly due to long roots of canine teeth, a direct blow to chin can result in parasymphysis fracture. Condyles get fractured as protective mechanism to avoid force transmission and injury to middle cranial fossa and base of the skull. Angle of mandible was involved in 19.4% of cases in our study. Ogundare *et al.* reported 36% of involvement of angle as the most common fracture site.^[22] Udeabor *et al.* discussed body of mandible as the most common fracture site with 23.7% involvement.^[23] Incidence of other sites of fractures of mandible in our study was body (12.5%), symphysis (6.2%), and coronoid (2.1%) [Figure 1].

Following mandibular fractures, our study interprets that midface fractures were the next common fracture (27.6%). Among midface fractures, zygomatic bone and arch fractures are most commonly involved (about 50.2%). Similar results were observed by Shankar *et al.* and Bakardjiev and Pechalova (2007).^[24,25] Zaleckas *et al.* also observed that zygomatic fractures (68.8%) were the most common types of midface fractures.^[26] High incidence of zygomatic complex fracture is due to anatomically prominent position and its multiple articulations with other facial bones. It forms the outer circle or rim of the face making it vulnerable to trauma. In isolated maxilla fracture, Lefort II was the most common fracture (about 18% of cases), followed by Lefort I and Lefort III. Other midface fractures include nasal complex (NOE) fractures (15.8), orbital fractures (7.3%), and frontal fractures (2.8%). This finding was in correlation with the observations by Septa *et al.*^[12] Zaleckas *et al.* also reported a similar

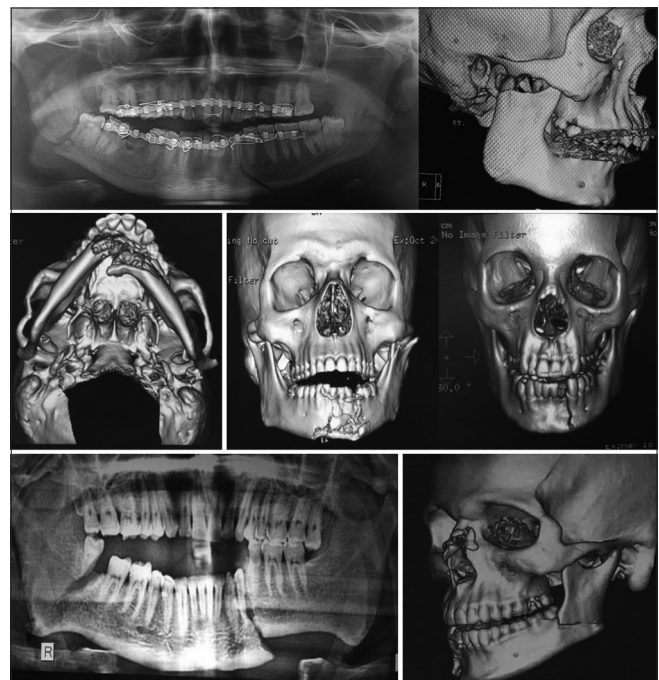


Figure 1: Distribution of mandibular fractures

finding.^[26] However, Zandi *et al.* reported that nasal bone (63.4%) was the most common fracture in their study^[27] [Figure 2].

Management of maxillofacial injuries

Management of maxillofacial trauma is a real challenge for oral and maxillofacial surgeons as it requires both skill and experience. Maxillofacial injuries vary from simple nasal fracture to severe comminution of facial structure, that is, nasal complex, maxilla, zygoma, frontal bone, and mandible. Management of these injuries is extremely challenging as these are highly vascularized areas and are complicated by near presence of upper airway, cranial structures, and cervical spine. Management of maxillofacial trauma patient involves initial assessment of airway, breathing, circulation, hemorrhage, and their definitive and prompt management. Comminuted midface, nasal complex, and bilateral parasymphysis fractures may lead to airway obstruction. Assessment of cervical spine and head injury component and its definitive management is the next quick step in maxillofacial trauma patients.^[28]

Definitive management of maxillofacial fractures

Various treatment modalities for maxillofacial trauma are conservative management, closed reduction/IMF, and ORIF. *Conservative management:* Undisplaced midface and zygomatic complex without any functional or esthetic or neurological involvement is managed by conservative approach. Medications, soft/liquid diet, restrict mouth opening/jaw movement, and oral hygiene maintenance are usually advised.

Closed reduction and IMF

Single linear mandibular fractures, condyle fractures without displacement or dislocation, and other facial fractures with mild

displacement and with mild occlusion disturbance are treated by manual reduction of fracture and IMF using Erich arch bar and elastics for 4–6 weeks. This is followed by IMF release, physiotherapy, and mouth opening exercises. Difficulties with closed reduction method are poor nutrition and weight loss, speech difficulty, delay recovery of jaw function, and work loss along with social inconvenience^[29] [Figure 3].

Zygoma/arch elevation

Zygomatico complex (ZMC) and zygomatic arch fractures not involving occlusion are elevated by the Keen's upper buccal sulcus approach. If fractures are stable after elevation, no direct plate fixation is required.

Open reduction and internal fixation

All panfacial fractures, fractures with deranged occlusion, displaced fractures that were not reduced by close reduction, and unstable ZMC fracture following elevation are treated by ORIF by mini plate osteosynthesis under GA/LA. A 2.0/1.5-mm titanium mini plating system is used for mandibular fractures and 1.5 mm for maxillary and zygomatic fixation. The advantage of open reduction internal fixations is that it reduces the postoperative IMF period and promotes primary bony healing, early bony union with minimal callus formation, early re-establishment of normal jaw functions, and maintenance of normal body weights when compared with closed reduction in long IMF period. The disadvantages include surgical trauma, risk of infection in bone plates, wound dehiscence, nerve injury, hospital stay, and cost factor [Figure 4].^[30]

As truly said, “prevention is better than cure,” and treatment of patients with maxillofacial injury not only includes management of the acute condition but also involves combined preventive and interventional efforts to reduce the incidence of maxillofacial trauma. Hence, there is an urgent need to obey traffic rules and regulations, to improve automobiles safety measures, and to implement school education about alcohol abuse and minimize physical assaults, sports activities protection, and compulsory wearing of protective headgear in industrial and construction workers. Prevention of injury is an effective way to decrease direct and indirect consequences of maxillofacial trauma.

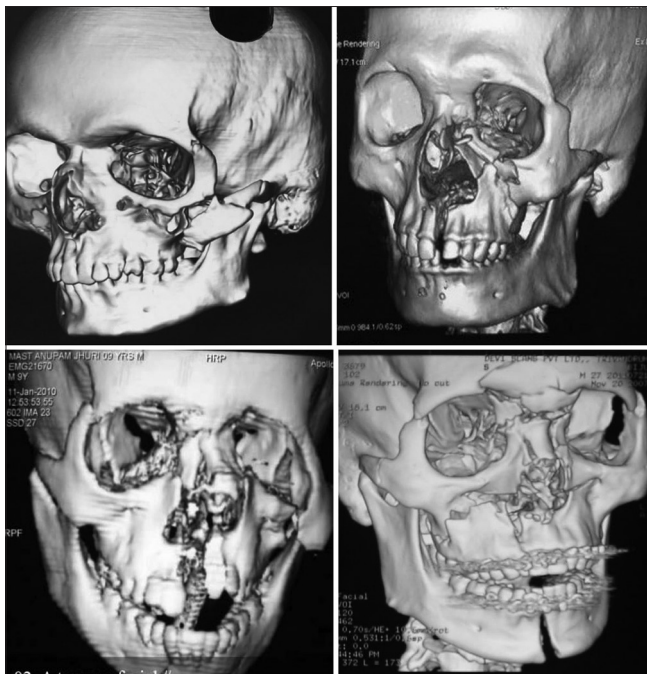


Figure 2: Distribution of mid face fractures

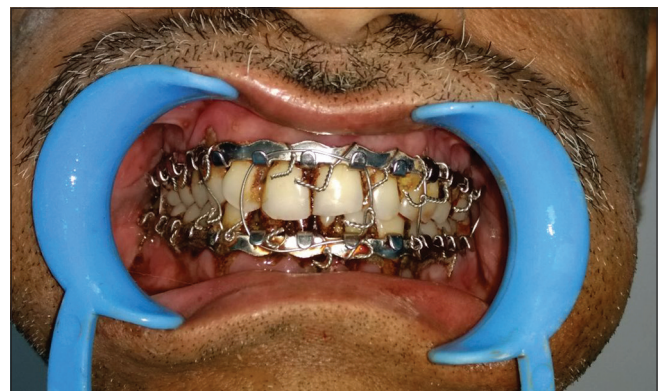

Figure 3: Closed reduction and intermaxillary fixation

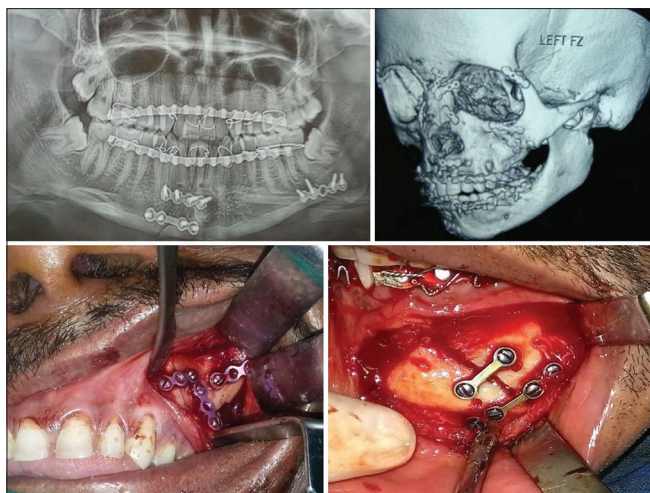


Figure 4: Open reduction and internal fixation

Conclusion

Maxillofacial trauma involves skeletal, dental, and soft tissue components of face and may lead to significant morbidity with functional and esthetic concerns. Maxillofacial injuries depend on the geographical conditions, road safety regulations, socioeconomic status, alcohol abuse, and so on; but from the results of our study, we can conclude that RTA is still the leading cause of maxillofacial trauma in young males in Delhi-NCR region. Increased RTA in this region is due to underage driving, poor road conditions, overspeeding practice, overload, lack of seat belt law obligation, traffic rules' violations, and alcohol drinking and driving.

Physical assault is the next main cause reported in our study. Hence, in view of the results of our study, it can be concluded that strict traffic rules, road safety law, and preventive measures need to be enforced along with education and socioeconomic status improvement. The main limitation of our study is its retrospective design and small sample size. Therefore, a prospective study with larger sample size and data is required for conclusive result and to record any change in the trend and pattern maxillofacial injuries.

Financial support and sponsorship

Nil.

Conflicts of interest

There are no conflicts of interest.

References

- Simpson DA, Mac Lean AJ. Mechanisms of injury. In: David DJ, Simpson DA, editors. *Cranio-maxillofacial Trauma*. Edinburgh: Churchill Livingstone; 1995. p. 101.
- Yamamoto K, Matsusue Y, Horita S, Murakami K, Sugiura T, Kirita T. Clinical analysis of midfacial fractures. *Mater Sociomed* 2014;26:21-5.
- Passi D, Malkunje L, Atri M, Chahal D, Singh TK, Goyal J. Newer proposed classification of mandibular fractures: A critical review with recent updates. *Ann Med Health Sci Res* 2017;7:314-8.
- Gassner R, Tuli T, Hächl O, Rudisch A, Ulmer H. Cranio-maxillofacial trauma: A 10 year review of 9543 cases with 21 067 injuries. *J Craniomaxillofac Surg* 2003;31:51-61. doi: 10.1016/S1010-5182 (02) 00168-3.
- Dibaie A, Raissian S, Ghafarzadeh S. Evaluation of maxillofacial traumatic injuries of Forensic Medical Center of Ahwaz, Iran, in 2005. *Pakistan J Med Sci* 2009;25:79-82.
- Perry M. Maxillofacial trauma - Developments, innovations and controversies. *Injury* 2009;40:1252-9.
- Bali R, Sharma P, Garg A, Dhillon G. A comprehensive study on maxillofacial trauma conducted in Yamunanagar, India. *J Inj Violence Res* 2013;5:108-16.
- Udeabor S, Akinmoladum VI, Obiechina AE, Olusanya AA. Pattern of midface trauma with associated concomitant injuries in a Nigerian referral centre. *Niger J Surg* 2014;20:26-9.
- Singaram M, Sree Vijayabala G, Udhayakumar RK. Prevalence, pattern, etiology and management of maxillofacial trauma in a developing country: A retrospective study. *J Korean Assoc Oral Maxillofac Surg* 2016;42:174-81.
- Pandey S, Roychoudhary A. Study of the pattern of maxillofacial fractures seen at a tertiary care hospital in North India. *J Maxillofac Oral Surg* 2015;32-9.
- Lin S, Levin L, Goldman S, Peled M. Dentoalveolar and maxillofacial injuries: Retrospective study from a Level I trauma Center in Israel. *Dent Traumatol* 2007;23:155-7.
- Septa D, Newaskar VP, Agrawal D, Tibra S. Etiology, incidence and patterns of mid-face fractures and associated ocular injuries. *J Maxillofac Oral Surg* 2014;13:115-9.
- Mohan D. *The Road Ahead: Traffic Injuries and Fatalities in India*. New Delhi: Transportation Research and Injury Prevention Programme, Indian Institute of Technology Delhi; 2004. p. 1-30.
- Jagnoor J. Road traffic injury prevention: A public health challenge. *Indian J Community Med* 2006;31:129-31
- Chrcanovic BR, Freire-Maia B, Souza LN, Vasco de Oliveira Araújo VO, Abreu MHNG. Facial fractures: A 1-year retrospective study in a hospital in Belo Horizonte. *Braz Oral Res* 2004;18:322-8.
- Ansari MH. Maxillofacial fractures in Iran, a retrospective study (1987-2001). *J Craniomaxillofac Surg* 2004;32:28-34.
- Subhasraj K, Nandakumar N, Ravindran C. Review of maxillofacial injuries in Chennai, India; a study of 2748 cases. *Br J Oral Maxillofac Surg* 2007;45:637-9.
- Erol B, Tanrikulu R, Gorgun B. Maxillofacial fractures, analysis of demographic distribution and treatment in 2901 patients (25 years experience). *J Craniomaxillofac Surg* 2004;32:308-13.
- Arslan ED, Solakoglu AG, Komut E, Kavalci C, Yilmaz F, Karakilic E *et al*. Assessment of maxillofacial trauma in emergency department. *World J Emerg Surg* 2014;9:13.
- King RE, Scianna JM, Petruzzelli GJ. Mandible fracture patterns. A suburban trauma center experience. *Am J Otolaryngol* 2004;25:301-7.
- Al Ahmed HE, Jaber MA. The pattern of maxillofacial fractures in United Arab Emirates: A review of 230 cases. *Oral Surg Oral Med Oral Pathol* 2004; 98,166-70.

22. Ogundare BO, Bonnicksen A, Bayley N. Pattern of mandibular fractures in an urban major trauma center. *J Oral Maxillofac Surg* 2003;61:713-8.
23. Udeabor SE, Akinbami BO, Yarhere KS, Obiechina AE. Maxillofacial fractures: Etiology, pattern of presentation, and treatment in University of Port Harcourt Teaching Hospital, Port Harcourt, Nigeria. *J Dent Surg* 2014; Article ID 850814, 5 pages.
24. Shankar AN, Shankar VN, Hegde N, Sharma, Prasad R. The pattern of maxillofacial fractures - A multicentric retrospective study. *J Craniomaxillofac Surg* 2012;40:675-9.
25. Bakardjiev A, Pechalova P. Maxillofacial fractures in Southern Bulgaria: A retrospective study of 1706 cases. *J Craniomaxillofac Surg* 2007 Apr; 35:147-150.
26. Zaleckas L, Pečiulienė V, Gendvilienė I, Pūrienė A, Rimkuvienė J. Prevalence and etiology of midfacial fractures: A study of 799 cases. *Medicina* 2015;51:222-7.
27. Zandi M, Khayati A, Lamei A, Zarei H. Maxillofacial injuries in western Iran: A prospective study. *Oral Maxillofac Surg* 2011;15:201-9.
28. Hutchison I, Lawlor M, Skinner D. ABC of major trauma. Major maxillofacial injuries. *BMJ* 1990;301:595-9.
29. Schneidr M, Erasmus F, Gerlach K, Kuhlich E, Loukota RA, Rasse M, *et al.* Open reduction and internal fixation versus closed treatment and mandibulomaxillary fixation of fracture of the mandible condylar process. *J Oral Maxillofac Surg* 2008;66:2537-44.
30. Singh V, Bhagol A, Kumar I. A new and easy technique for maxillomandibular fixation. *Natl J Maxillofac Surg* 2010;1:245.