

## Pathological significance and classification of endolymphatic hydrops in otological disorders

Michihiko Sone<sup>1</sup>, Tadao Yoshida<sup>1</sup>, Satofumi Sugimoto<sup>1</sup>, Masumi Kobayashi<sup>1</sup>, Masaaki Teranishi<sup>1</sup> and Shinji Naganawa<sup>2</sup>

<sup>1</sup>*Department of Otorhinolaryngology, Nagoya University Graduate School of Medicine, Nagoya, Japan*

<sup>2</sup>*Department of Radiology, Nagoya University Graduate School of Medicine, Nagoya, Japan*

### ABSTRACT

We summarize the presence of endolymphatic hydrops (EH) in otological disorders evaluated with magnetic resonance imaging (MRI) of temporal bones, and propose a classification of EH based on its pathological significance. A search of the literature published in English-language journals was performed using electronic databases, especially focusing on EH-related otological disorders. Clinical articles that contained the terms EH and contrast-MRI published from 2007 to the present, with relevant human temporal bone studies, were included. The following three main points are discussed based on the results in the relevant articles: i) otological disorders that present EH, ii) current grading for evaluation of EH on MRI, and iii) a proposed classification of EH based on its pathological significance. MRI evaluation revealed that EH exists extensively not only in ears with typical Meniere's disease (MD), but also in those with various other otological disorders. The etiological classification of EH helps to summarize ideas for determining the pathophysiology of otological disorders, while a therapeutic classification provides clues to their management. MRI evaluations of EH have led to breakthroughs in investigations of EH in otological disorders. Precise grading for evaluation and clarification of EH on MRI based on its pathological significance could provide keys to elucidating the pathophysiology of EH-related otological disorders.

Keywords: endolymphatic hydrops, magnetic resonance imaging, otological disorder, classification

#### Abbreviations:

EH: endolymphatic hydrops

MD: Meniere's disease

MRI: magnetic resonance imaging

SNHL: sensorineural hearing loss

This is an Open Access article distributed under the Creative Commons Attribution-NonCommercial-NoDerivatives 4.0 International License. To view the details of this license, please visit (<http://creativecommons.org/licenses/by-nc-nd/4.0/>).

### INTRODUCTION

Meniere's disease (MD) causes audio-vestibular symptoms, including episodic attacks of vertigo or fluctuating sensorineural hearing loss (SNHL). Endolymphatic hydrops (EH) is a characteristic

---

Received: August 19, 2021; accepted: September 15, 2021

Corresponding Author: Michihiko Sone, MD

Department of Otorhinolaryngology, Nagoya University Graduate School of Medicine, 65 Tsurumai-cho, Showa-ku, Nagoya 466-8550, Japan

Tel: +81-52-744-2323, Fax: +81-52-744-2325, E-mail: michsone@med.nagoya-u.ac.jp

marker of MD in the presence of other clinical symptoms, but the presence of EH does not by itself indicate a diagnosis of MD. Human temporal bone studies have been performed to elucidate the pathology of MD for many years; however, the relationship between MD and EH remains to be fully understood.<sup>1,2</sup> The presence of EH is not included in the current diagnostic criteria for MD,<sup>3</sup> although EH is still the key to elucidating the pathophysiological mechanism of MD. Since the audio-vestibular symptoms of MD cause significant deterioration in the quality of life of patients with the disease, precise diagnosis and adequate management are strongly recommended.

In 2007, our group first demonstrated the presence of EH in patients with MD on 3 Tesla magnetic resonance imaging (MRI) performed 24 hours after intravenous injection of gadolinium-based contrast agents (GBCAs).<sup>4</sup> Thereafter, with technical advances, visualization of EH became possible on MRI performed 4 hours after intravenous injection of GBCAs.<sup>5</sup> Evaluation of EH on MRI has led to a breakthrough in the diagnosis of MD. MRI examination is now recommended in patients with SNHL, vertigo and tinnitus, to verify the inner ear pathology and for better management of EH-related diseases.<sup>6</sup>

The endolymphatic space varies between healthy subjects. Consequently, MRI evaluation of EH is associated with challenges in recognizing pathological or clinically relevant variants.<sup>7</sup> Asymmetry between an individual's ears on MRI could provide the most useful information for predicting and quantitatively assessing clinical data.<sup>8</sup> In the present paper, we summarize the presence of EH in otological disorders and the current gradings for evaluation of EH on MRI, and propose a classification for EH based on its pathological significance.

## METHODS

A search of the literature published in English-language journals from 2007 to the present was performed using electronic databases (PubMed, Web of Science, and Scopes). The main search terms were EH and MRI (3 Tesla with contrast agents), and the relevant human temporal bone studies were examined, excluding case reports or those with unclear images. Since most previous papers that have been published focus on the presence of EH on MRI for diagnosing MD, we focused on otological disorders other than MD, to clarify the significance of EH. The following three points are addressed based on the results of the researched articles: i) presence of EH in various otological disorders, ii) current gradings for evaluation of EH on MRI, and iii) a proposed classification of EH based on its pathological significance.

## RESULTS

### *Presence of EH in various otological disorders*

Table 1 lists the various otological disorders that have EH as one of the features. MRI evaluation has revealed that EH exists extensively not only in ears with typical MD, but also in those with various other otological disorders, including atypical type of MD,<sup>9</sup> delayed EH (DEH),<sup>10,11</sup> acute low tone SNHL,<sup>12,13</sup> vestibular schwannoma,<sup>14,15</sup> idiopathic sudden sensorineural hearing loss (ISSNHL),<sup>16-18</sup> recurrent peripheral vestibulopathy or benign recurrent vestibulopathy,<sup>19,20</sup> large vestibular aqueduct syndrome (LVAS) or superior canal dehiscence (SCDS) syndrome,<sup>21</sup> deafness due to mumps<sup>18</sup> and otosclerosis.<sup>22,23</sup> Figure 1 shows sample MRI images of EH from a case of deafness due to mumps.

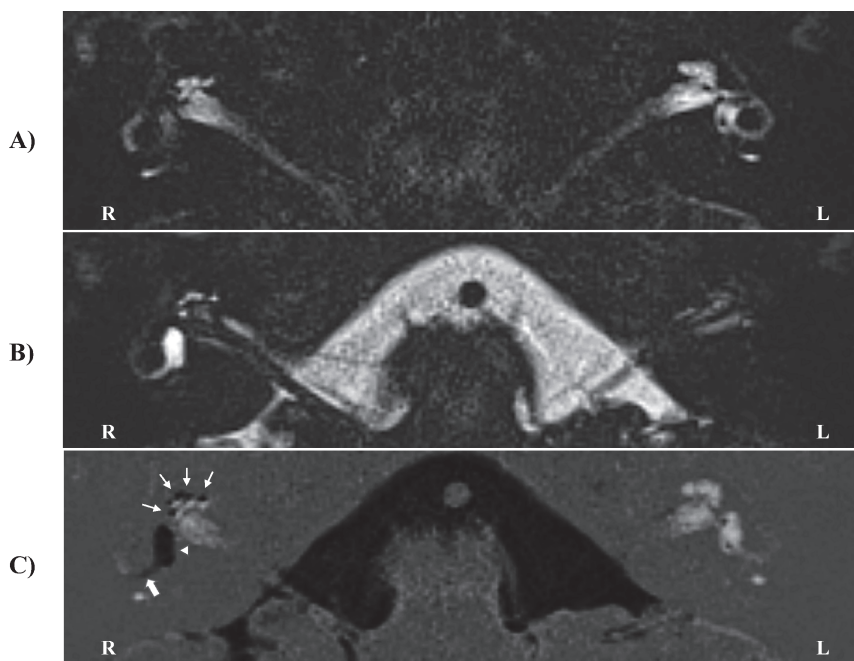
In addition to MRI evaluation, human temporal bone studies have revealed that traumatic and inflammatory insults, such as those following middle or inner ear surgeries, acoustic and mechanical trauma, or systemic inflammatory processes, can all cause secondary EH.<sup>24-26</sup>

**Table 1** Otolological disorders that present endolymphatic hydrops

---

# Meniere's disease
# Atypical type of Meniere's disease
# Delayed endolymphatic hydrops
# Acute low tone sensorineural hearing loss
# Vestibular schwannoma
# Idiopathic sudden sensorineural hearing loss
# Recurrent vestibulopathy
# Large vestibular aqueduct syndrome / Superior canal dehiscence syndrome
# Deafness due to mumps
# Otosclerosis
# Ear surgery
# Acoustic or mechanical trauma
# Inflammation

---



**Fig. 1** Sample images of EH from a case with deafness due to mumps (axial plane)

**Fig. 1A:** Native image of positive perilymph signal

**Fig. 1B:** Reversed image of positive endolymph signal

**Fig. 1C:** HYDROPS

Images are used to detect EH. EH is seen as black areas surrounded by gadolinium-filled perilymphatic spaces, as depicted on the right side (C). All turns of the cochlea (C, arrows) and the vestibule (C, arrowhead) show significant EH. Herniation of the EH into the lateral semicircular canal (C, bold arrow) was also observed.

EH: endolymphatic hydrops

HYDROPS: hybrid of reversed image of positive endolymph signal and native image of positive perilymph signal

*Current gradings for evaluation of EH in otological disorders*

The first grading for evaluation of EH on MRI was proposed by Nakashima et al<sup>27</sup> aiming for a convenient evaluation. Following their report, many gradings have been proposed for the diagnostic evaluation of MD.<sup>8,28-35</sup> A temporal bone study on MD revealed that severe EH was observed most frequently in the saccule, followed by the cochlea, the utricle, and the three semicircular canals.<sup>36</sup> MRI showed that EH in the vestibule is a more specific predictor of definite MD as compared to EH in the cochlea.<sup>37</sup> Inversion of the saccule to utricle area ratio has been introduced as a semi-quantitative method of diagnosing EH in the vestibule,<sup>31,38</sup> although it is difficult to distinguish the saccule from the utricle in ears in which EH occupies the whole vestibule.

Significant EH in the vestibule on MRI, which was included in the first grading of EH,<sup>27</sup> can be classified into two types: EH with or without adjacency to the oval window.<sup>39</sup> A clinical difference between the two types of EH is the significantly higher appearance of air-bone gaps at low-frequencies on pure tone audiometry in ears with adjacency than those without adjacency of the EH to the oval window,<sup>39</sup> in which difference of acoustic energy absorbance has been speculated as a contributing factor.<sup>40</sup> Another study demonstrated that EH in the vestibule contacting the oval window had high specificity and positive predictive value in differentiating ears with MD from other ears.<sup>41</sup> LVAS and SCDS, as pathological third window lesions,<sup>42</sup> have significant EH both in the cochlea and the vestibule, and the mechanism of appearance of air-bone gaps at low-frequencies might be partially related to the presence of significant EH.<sup>21</sup>

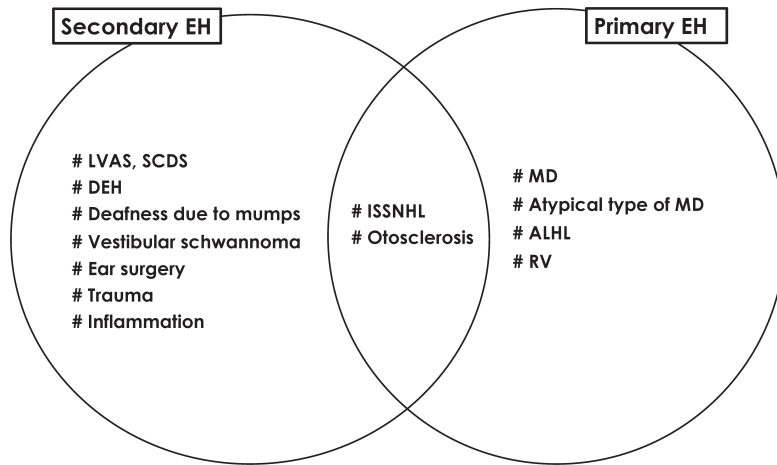
Occasionally, herniation of EH into the semicircular canals (SCCs) can be detected on MRI. Gürkov et al investigated the relationship between EH herniation into the lateral SCC and caloric function in patients with definite unilateral MD, and demonstrated a morphological correlation with impaired caloric responses.<sup>43</sup> However, EH herniation into the lateral SCC might not necessarily reflect the degree of EH. Unilateral herniation occurs with EH progression, and bilateral herniation might occur regardless of EH progression and might be influenced by other factors that alter the membranous labyrinth.<sup>44</sup> A recent study revealed that dilatation of the endolymphatic space in the ampulla was observed selectively in the posterior SCC without accompanying vestibular EH, and that it might be a cause of vertigo and dizziness.<sup>45</sup>

*Proposed classification of EH based on its pathological significance*

Gürkov et al have proposed a new terminology based on the symptomatic and imaging characteristics of various clinical entities, to clarify and simplify the diagnostic classification, as: primary hydropic ear disease including MD, and secondary hydropic ear disease.<sup>46,47</sup> The significance of EH should be considered from etiological and therapeutic perspectives. The etiological classification of EH might help to summarize ideas for determining the pathophysiology of otological disorders, while a therapeutic classification provides clues to their management.

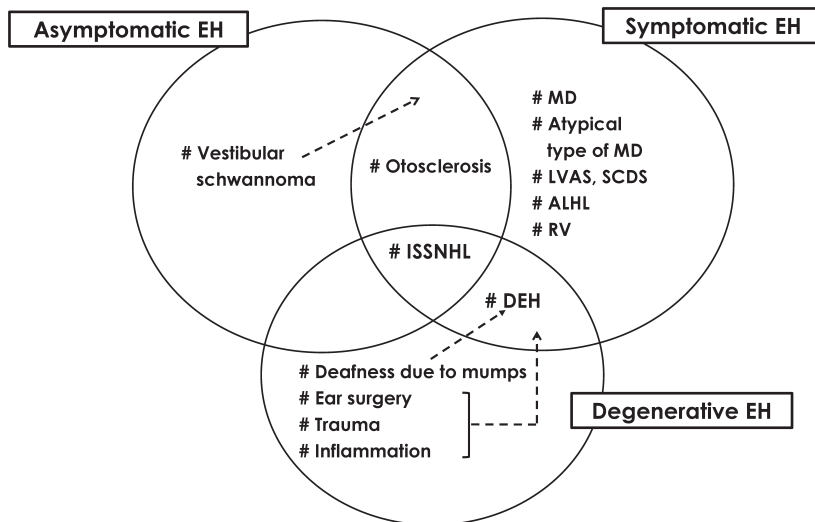
Figure 2 shows the significance of EH from an etiological perspective, considering MRI and temporal bone studies. In addition to MD with typical audio-vestibular symptoms, atypical types of MD,<sup>9</sup> formerly defined as cochlear or vestibular MD,<sup>48</sup> are also representative of primary EH. Recurrent peripheral vestibulopathy and benign recurrent vestibulopathy are considered to represent primary EH.<sup>19,20</sup> LVAS and SCD are types of secondary EH caused by pathological third window lesions.<sup>21</sup> Ears with otosclerosis also present EH, as primary EH concomitant with otosclerosis or secondary EH caused by lesions in the otic capsule.<sup>22,23</sup> The presence of EH in ears with ISSNHL is considered to represent secondary EH, although the presence of EH in affected and unaffected ears in patients with unilateral ISSNHL suggests the following speculations: i) EH develops secondarily following development of the disease in affected ears, and ii) pre-existing primary EH is a risk factor for the onset of ISSNHL.<sup>17</sup>

Significance of endolymphatic hydrops



**Fig. 2** Significance of endolymphatic hydrops from an etiological perspective

EH: endolymphatic hydrops  
 MD: Meniere’s disease  
 ALHL: acute low tone sensorineural hearing loss  
 RV: recurrent vestibulopathy  
 ISSNHL: idiopathic sudden sensorineural hearing loss  
 LVAS: large vestibular aqueduct syndrome  
 SCDS: superior canal dehiscence syndrome  
 DEH: delayed endolymphatic hydrops



**Fig. 3** Significance of endolymphatic hydrops from a therapeutic perspective

EH: endolymphatic hydrops  
 MD: Meniere’s disease  
 LVAS: large vestibular aqueduct syndrome  
 SCDS: superior canal dehiscence syndrome  
 ALHL: acute low tone sensorineural hearing loss  
 RV: recurrent vestibulopathy  
 ISSNHL: idiopathic sudden sensorineural hearing loss  
 DEH: delayed endolymphatic hydrops

Figure 3 shows the significance of EH from a therapeutic perspective. DEH induces the development of recurrent vestibular symptoms resembling those of MD after many years of monaural profound SNHL,<sup>49</sup> and a representative condition is deafness due to mumps. In the presence of additional unknown cofactors, degenerative EH following ear surgeries, trauma or inflammation might lead to the development of symptomatic EH. Significant EH was also detected on MRI in ears with otosclerosis; some patients ears presented acute SNHL or rotatory vertigo as symptoms of EH, while the others had asymptomatic EH.<sup>22</sup> Thus, presence of EH in ears with ISSNHL might represent a combination of three possibilities: symptomatic EH is the primary etiology that requires treatment, asymptomatic EH is a risk factor requiring careful follow-up, and degenerative EH develops after acquiring the disease. The mixed significance of EH might indicate various pathologies of the disease.

## DISCUSSION

Visualization of EH on MRI has high diagnostic value in patients with definite MD, although substantial discrepancies exist between histologically-confirmed EH and radiologically-detected EH.<sup>7</sup> It is important to appreciate the relatively high prevalence of EH in healthy populations and in patients with other vestibular disorders, because detection of EH on MRI does not directly indicate a diagnosis of MD.<sup>7</sup>

In addition to the presence of EH, recent studies have reported the combination of perilymphatic enhancement and EH on MRI as having positive predictive value in the diagnosis of definite MD.<sup>50,51</sup> A correlation between EH and permeability of the blood labyrinth barrier was originally proposed in the progression of MD.<sup>52</sup>

It should be cautioned that although EH evaluation on MRI has become a cutting-edge method for diagnosing MD, there might be a significant misdiagnosis if all portions with enlarged endolymphatic spaces detected on MRI are identified as pathological EH, regardless of their significance. Conversely, inadequate imaging analysis might lead to underdiagnosis.

A limitation of the present study is that the reviewed papers used differential imaging protocols since most of them involved the evaluation of MD. Detection of EH on MRI requires highly specialized imaging protocols, since specific MR parameters and the specific contrast agent used can all have dramatic impact on imaging results. Clinicians experienced in interpretation of these images are also essential for making an accurate diagnosis.

## CONCLUSION

Evaluation of EH on MRI has led to breakthroughs in the investigation of EH in otological disorders. Precise grading using appropriate MR imaging for the evaluation and clarification of EH based on its pathological significance could provide keys to elucidating the pathophysiology of EH-related otological disorders.

## CONFLICT OF INTEREST

The authors declare no conflicts of interest associated with this manuscript.

## FUNDING

This work was partially supported by Society for Promotion of International Oto-Rhino-Laryngology (SPIO).

## REFERENCES

- 1 Merchant SN, Adams JC, Nadol JB Jr. Pathophysiology of Meniere's syndrome: are symptoms caused by endolymphatic hydrops? *Otol Neurotol.* 2005;26(1):74–81. doi:10.1097/00129492-200501000-00013.
- 2 Foster CA, Breeze RB. Endolymphatic Hydrops in Ménière's Disease: cause, consequence, or epiphenomenon? *Otol Neurotol.* 2013;34(7):1210–1214. doi:10.1097/MAO.0b013e31829e83df.
- 3 Lopez-Escamez JA, Carey J, Chung WH, et al. Diagnostic criteria for Ménière's disease. *J Vestib Res.* 2015;25(1):1–7. doi:10.3233/VES-150549.
- 4 Nakashima T, Naganawa S, Sugiura M, et al. Visualization of endolymphatic hydrops in patients with Meniere's disease. *Laryngoscope.* 2007;117(3):415–420. doi:10.1097/MLG.0b013e31802c300c.
- 5 Naganawa S, Yamazaki M, Kawai H, Bokura K, Sone M, Nakashima T. Visualization of endolymphatic hydrops in Ménière's disease with single-dose intravenous gadolinium-based contrast media using heavily T<sub>2</sub>-weighted 3D-FLAIR. *Magn Reson Med Sci.* 2010;9(4):237–242. doi:10.2463/mrms.9.237.
- 6 Pyykkö I, Nakashima T, Yoshida T, Zou J, Naganawa S. Ménière's disease: a reappraisal supported by a variable latency of symptoms and the MRI visualisation of endolymphatic hydrops. *BMJ Open.* 2013;3(2):e001555. doi:10.1136/bmjopen-2012-001555.
- 7 van der Lubbe MFJA, Vaidyanathan A, Rompaey VV, et al. The “hype” of hydrops in classifying vestibular disorders: a narrative review. *J Neurol.* 2020;267(Suppl 1): 197–211. doi: 10.1007/s00415-020-10278-8.
- 8 Boegle R, Gerb J, Kierig E, et al. Intravenous delayed gadolinium-enhanced MR imaging of the endolymphatic space: a methodological comparative study. *Front Neurol.* 2021;12:647296. doi:10.3389/fneur.2021.647296.
- 9 Kato M, Sugiura M, Shimono M, et al. Endolymphatic hydrops revealed by magnetic resonance imaging in patients with atypical Meniere's disease. *Acta Otolaryngol.* 2013;133(2):123–129. doi:10.3109/00016489.2012.726374.
- 10 Kasai S, Teranishi M, Katayama N, et al. Endolymphatic space imaging in patients with delayed endolymphatic hydrops. *Acta Otolaryngol.* 2009;129(11):1169–1174. doi:10.3109/00016480802691143.
- 11 Iwasa Y, Tsukada K, Kobayashi M, et al. Bilateral delayed endolymphatic hydrops evaluated by bilateral intratympanic injection of gadodiamide with 3T-MRI. *PLoS One.* 2018;13(12):e0206891. doi:10.1371/journal.pone.0206891.
- 12 Shimono M, Teranishi M, Yoshida T, et al. Endolymphatic hydrops revealed by magnetic resonance imaging in patients with acute low-tone sensorineural hearing loss. *Otol Neurotol.* 2013;34(7):1241–1246. doi:10.1097/MAO.0b013e3182990e81.
- 13 Inui H, Sakamoto T, Ito T, Kitahara T. Magnetic resonance imaging of the endolymphatic space in patients with acute low-tone sensorineural hearing loss. *Auris Nasus Larynx.* 2019;46(6):859–865. doi:10.1016/j.anl.2019.04.003.
- 14 Naganawa S, Kawai H, Sone M, Nakashima T, Ikeda M. Endolymphatic hydrops in patients with vestibular schwannoma: visualization by non-contrast-enhanced 3D FLAIR. *Neuroradiology.* 2011;53(12):1009–1015. doi:10.1007/s00234-010-0834-y.
- 15 Zhang Y, Li F, Dai C, Wang W. Endolymphatic hydrops in patients with intralabyrinthine schwannomas. *Front Surg.* 2020;7: 623078. doi:10.3389/fsurg.2020.623078.
- 16 Chen X, Zhang XD, Gu X, Fang ZM, Zhang R. Endolymphatic space imaging in idiopathic sudden sensorineural hearing loss with vertigo. *Laryngoscope.* 2012;122(10):2265–2268. doi:10.1002/lary.23452.
- 17 Okazaki Y, Yoshida T, Sugimoto S, et al. Significance of endolymphatic hydrops in ears with unilateral sensorineural hearing loss. *Otol Neurotol.* 2017;38(8):1076–1080. doi:10.1097/MAO.0000000000001499.
- 18 Inui H, Sakamoto T, Ito T, Kitahara T. Magnetic resonance imaging of endolymphatic space in patients with sensorineural hearing loss: comparison between fluctuating and idiopathic sudden sensorineural hearing loss. *Acta Otolaryngol.* 2020;140(5):345–350. doi:10.1080/00016489.2020.1720919.
- 19 Attye A, Dumas G, Tropres I, et al. Recurrent peripheral vestibulopathy: is MRI useful for the diagnosis of endolymphatic hydrops in clinical practice? *Eur Radiol.* 2015;25(10):3043–3049. doi:10.1007/s00330-015-3712-5.

- 20 Ducroz C, Dumas G, Quatre R, Attyé A, Fabre, C, Schmerber S. Benign recurrent vestibulopathy: MRI and vestibular tests results in a series of 128 cases. *Eur Arch Otorhinolaryngol.* 2022;279(1):169–173. doi:10.1007/s00405-021-06637-4.
- 21 Sone M, Yoshida T, Morimoto K, Teranishi M, Nakashima T, Naganawa S. Endolymphatic hydrops in superior canal dehiscence and large vestibular aqueduct syndromes. *Laryngoscope.* 126(6):1446–1450. doi:10.1002/lary.25747.
- 22 Mukaida T, Sone M, Yoshida T, et al. Magnetic resonance imaging evaluation of endolymphatic hydrops in cases with otosclerosis. *Ototo Neurotol.* 2015;36(7):1146–1150. doi:10.1097/MAO.0000000000000685.
- 23 Sone M, Yoshida T, Sugimoto S, et al. Magnetic resonance imaging evaluation of endolymphatic hydrops and post-operative findings in cases with otosclerosis. *Acta Otolaryngol.* 2017;137(3):242–245. doi:10.1080/00016489.2016.1232862.
- 24 Ishai R, Halpin C, McKenna MJ, Quesnel AM. How often does stapedectomy for otosclerosis result in endolymphatic hydrops? *Otol Neurotol.* 2016;37(7):984–990. doi:10.1097/MAO.0000000000001116.
- 25 Ishiyama A, Doherty J, Ishiyama G, Quesnel AM, Lopez I, Linthicum FH. Post hybrid cochlear implant hearing loss and endolymphatic hydrops. *Otol Neurotol.* 2016;37(10):1516–1521. doi:10.1097/MAO.0000000000001199.
- 26 Ferster APO, Cureoglu S, Keskin N, Paparella MM, Isildak H. Secondary Endolymphatic Hydrops. *Otol Neurotol.* 2017;38(5):774–779. doi:10.1097/MAO.0000000000001377.
- 27 Nakashima T, Naganawa S, Pyykö I, et al. Grading of endolymphatic hydrops using magnetic resonance imaging. *Acta Otolaryngol Suppl.* 2009;560:5-8. doi:10.1080/00016480902729827.
- 28 Gürkov R, Flatz W, Louza J, Strupp M, Ertl-Wagner B, Krause E. In vivo visualized endolymphatic hydrops and inner ear functions in patients with electrocochleographically confirmed Ménière's disease. *Otol Neurotol.* 2012;33(6):1040–1045. doi:10.1097/MAO.0b013e31825d9a95.
- 29 Baráth K, Schuknecht B, Naldi AM, Schrepfer T, Bockisch CJ, Hegemann SCA. Detection and grading of endolymphatic hydrops in Ménière disease using MR imaging. *AJNR Am J Neuroradiol.* 2014;35(7):1387–1392. doi:10.3174/ajnr.A3856.
- 30 Homann G, Vieth V, Weiss D, et al. Semi-quantitative vs. volumetric determination of endolymphatic space in Ménière's disease using endolymphatic hydrops 3T-HR-MRI after intravenous gadolinium injection. *PLoS One.* 2015;10(3):e0120357. doi:10.1371/journal.pone.0120357.
- 31 Attyé A, Eliezer M, Boudiaf N, et al. MRI of endolymphatic hydrops in patients with Meniere's disease: a case-controlled study with a simplified classification based on saccular morphology. *Eur Radiol.* 2017;27(8):3138–3146. doi:10.1007/s00330-016-4701-z.
- 32 Yang S, Zhu H, Zhu B, et al. Correlations between the degree of endolymphatic hydrops and symptoms and audiological test results in patients with Ménière's disease: a reevaluation. *Otol Neurotol.* 2018;39(3):351–356. doi:10.1007/s00330-016-4701-z.
- 33 Bernaerts A, Vanspauwen R, Blaivie C, et al. The value of four stage vestibular hydrops grading and asymmetric perilymphatic enhancement in the diagnosis of Ménière's disease on MRI. *Neuroradiology.* 2019;61(4):421–429. doi:10.1007/s00234-019-02155-7.
- 34 Ito T, Inui H, Miyasaka T, et al. Three-dimensional magnetic resonance imaging reveals the relationship between the control of vertigo and decreases in endolymphatic hydrops after endolymphatic sac drainage with steroids for Meniere's disease. *Front Neurol.* 2019;10:46. doi:10.3389/fneur.2019.00046.
- 35 Ohashi T, Naganawa S, Takeuchi A, Katagiri T, Kuno K. Quantification of endolymphatic space volume after intravenous administration of a single dose of gadolinium-based contrast agent: 3D-real inversion recovery versus HYDROPS-Mi2. *Magn Reson Med Sci.* 2020;19(2):119–124. doi:10.2463/mrms.mp.2019-0013.
- 36 Okuno T, Sando I. Localization, frequency, and severity of endolymphatic hydrops and the pathology of the labyrinthine membrane in Ménière's disease. *Ann Otol Rhinol Laryngol.* 1987;96(4):438–445. doi:10.1177/000348948709600418.
- 37 Yoshida T, Sugimoto S, Teranishi M, et al. Imaging of the endolymphatic space in patients with Ménière's disease. *Auris Nasus Larynx.* 2017;45(1):33–38. doi:10.1016/j.anl.2017.02.002.
- 38 Attyé A, Eliezer M, Medici M, et al. In vivo imaging of saccular hydrops in humans reflects sensorineural hearing loss rather than Meniere's disease symptoms. *Eur Radiol.* 2018;28(7):2916–2922. doi:10.1007/s00330-017-5260-7.
- 39 Sugimoto S, Yoshida T, Teranishi M, Okazaki Y, Naganawa S, Sone M. The relationship between endolymphatic hydrops in the vestibule and low-frequency air-bone gaps. *Laryngoscope.* 2018;128(7):1658–1662. doi:10.1002/lary.26898.
- 40 Kobayashi M, Yoshida T, Sugimoto S, et al. Effects of endolymphatic hydrops on acoustic energy absorbance. *Acta Otolaryngol.* 2020;140(8):626–631. doi:10.1080/00016489.2020.1754460.



- 41 Conte G, Caschera L, Calloni S, et al. MR imaging in Menière disease: is the contact between the vestibular endolymphatic space and the oval window a reliable biomarker? *AJNR Am J Neuroradiol.* 2018;39(11):2114–2119. doi:10.3174/ajnr.A5841.
- 42 Merchant SN, Rosowski JJ. Conductive Hearing Loss Caused by Third-Window Lesions of the Inner Ear. *Otol Neurotol.* 2008;29(3):282–289. doi:10.1097/mao.0b013e318161ab24.
- 43 Gürkov R, Flatz W, Louza J, Strupp M, Ertl-Wagner B, Krause E. Herniation of the membranous labyrinth into the horizontal semicircular canal is correlated with impaired caloric response in Meniere's disease. *Otol Neurotol.* 2012;33(8):1375–1379. doi:10.1097/MAO.0b013e318268d087.
- 44 Sugimoto S, Yoshida T, Teranishi M, et al. Significance of endolymphatic hydrops herniation into the semicircular canals detected on MRI. *Otol Neurotol.* 2018;39(10):1229–1234. doi:10.1097/MAO.0000000000002022.
- 45 Morioka M, Sugimoto S, Yoshida T, et al. Dilatation of the endolymphatic space in the ampulla of the posterior semicircular canal: A new clinical finding detected on magnetic resonance imaging. *Otol Neurotol.* 2021;42(6):e643-e647. doi:10.1097/MAO.0000000000003073.
- 46 Gürkov R, Pyykö I, Zou J, Kentala E. What is Menière's disease? A contemporary re-evaluation of endolymphatic hydrops. *J Neurol.* 2016;263 Suppl 1:S71-S81. doi:10.1007/s00415-015-7930-1.
- 47 Gürkov R. Menière and Friends: Imaging and Classification of Hydropic Ear Disease. *Otol Neurotol.* 2017;38(10):e539-e544. doi:10.1097/MAO.0000000000001479.
- 48 Horii A, Osaki Y, Kitahara T, et al. Endolymphatic hydrops in Meniere's disease detected by MRI after intratympanic administration of gadolinium: comparison with sudden deafness. *Acta Otolaryngol.* 2011;131(6):602–609. doi:10.3109/00016489.2010.548403.
- 49 Kamei T. Delayed endolymphatic hydrops as a clinical entity. *Int Tinnitus J.* 2004;10(2):137–143.
- 50 Bernaerts A, Vanspauwen R, Blaivie C, et al. The value of four stage vestibular hydrops grading and asymmetric perilymphatic enhancement in the diagnosis of Menière's disease on MRI. *Neuroradiology.* 2019;61(4):421–429. doi:10.1007/s00234-019-02155-7.
- 51 van Steekelenburg JM, van Weijnen A, de Pont LMH, et al. Value of Endolymphatic Hydrops and Perilymph Signal Intensity in Suspected Ménière Disease. *AJNR Am J Neuroradiol.* 2020;41(3):529–534. doi:10.3174/ajnr.A6410.
- 52 Tagaya M, Yamazaki M, Teranishi M, et al. Endolymphatic hydrops and blood-labyrinth barrier in Ménière's disease. *Acta Otolaryngol.* 2011;131(5):474–479. doi:10.3109/00016489.2010.534114.