



## Case Report

# Successful minimal invasive treatment of chylous ascites following pancreaticoduodenectomy: A case report and review of literature

Thanh Khiem Nguyen<sup>a</sup>, Tuan Hiep Luong<sup>b,\*</sup>, Ngoc Cuong Nguyen<sup>c</sup>, Ham Hoi Nguyen<sup>a</sup>,  
Ngoc Hung Nguyen<sup>a</sup>, Hong Son Trinh<sup>d</sup>

<sup>a</sup> Department of Gastrointestinal and Hepato-pancreato-biliary Surgery, Bach Mai Hospital, Hanoi, Viet Nam

<sup>b</sup> Department of Surgery, Hanoi Medical University, Hanoi, Viet Nam

<sup>c</sup> Department of Diagnostic and Interventional Radiology, Hospital of Hanoi Medical University, Hanoi, Viet Nam

<sup>d</sup> Department of Oncology, Viet Duc Hospital, Hanoi, Viet Nam



## ARTICLE INFO

## Keywords:

Pancreatic cancer  
Lymphadenectomy  
Chylous ascites  
Pancreaticoduodenectomy  
Postoperative lymphatic leakage  
Case report

## ABSTRACT

**Introduction:** Chylous ascites is an uncommon but potentially life-threatening type of postoperative lymphatic leakage, especially following pancreaticoduodenectomy.

**Case presentation:** A 59-year-old man underwent pancreaticoduodenectomy (PD) with extended lymphadenectomy and segmental Superior Mesenteric Vein (SMV) resection for SMV-involved pancreatic ductal adenocarcinoma (PDAC). After 20th postoperative day, patient had a drain output with a milky appearance, and with a triglyceride level was 1.6 mmol/L, and the daily output volume was up to 1500 mL per day. She has been performed Conventional Lymphangiography (CLAG) to identify the broken lymphatic vessels as well as close the leakage. Following two consecutive lymphangiography, the source of chylous leakage was identified from hilar lymphatic system, and injection of Aetoxisclerol 2% into lymphatic vessels to close the leakage was performed. Partial parenteral nutrition with limited fat components or medium-chain triglyceride (MCT) was administered, and the amount of ascites decreased particularly. The drain was removed in 20th day after the second CLAG. He had no symptoms of abdominal distention after drain removal and had been discharged after 37 postoperative days (PODs).

**Discussion:** Chylous ascites is an uncommon but potentially life-threatening complication following pancreaticoduodenectomy. Portal lymphatic plexus, which was often isolated and dissected especially with extended lymphadenectomy, is potentially damaged and caused resistant chylous leakage. Newly techniques are updated and applied in diagnosis and treatment for this difficult-to-treat complication, one of them is percutaneous transhepatic Conventional Lymphangiography (CLAG).

**Conclusion:** CLAG with percutaneous transhepatic access could be effective to identify and terminate the chylous fistula from portal lymphatic plexus after pancreaticoduodenectomy.

## 1. Background

Lymphatic complications are rare, but well-known condition, and have been described in many researches, especially after in thoracic and head-and-neck surgery [1]. In general, These complications can be divided into two types: lymphatic leakage and lymphatic stasis [2]. In lymphatic leakage complication, many subtypes are presented, owing to different consequences and characteristics. A review by Shulan Lv et al. categorized this complication into five forms: lymphatic ascites,

lymphocele, lymphatic fistula, lymphorrhoea and special forms (chylous ascites or chyloperitoneum, chyloretroperitoneum and chylothorax) [2].

Disruption of the cisterna chyli or one of its major lymphatic tributaries in surgeries is the most likely cause of postoperative intra-abdominal chyle leak [3,4]. With highly close anatomical proximity, hepatopancreatobiliary surgery, and especially oncological pancreatic resections with radical standard lymphadenectomy, leads to highly associated with an increased risk of chyle leak compared with other major abdominal surgeries [5,6]. Herein, we reported a case successful minimal invasive treatment of chylous ascites following

\* Corresponding author. Department of Surgeon, Hanoi Medical University No 40 Trang Thi Street, Hanoi, Viet Nam.

E-mail addresses: [khiemnguyenthanh@yahoo.com](mailto:khiemnguyenthanh@yahoo.com) (T.K. Nguyen), [Hiep1995hsgs@gmail.com](mailto:Hiep1995hsgs@gmail.com) (T.H. Luong), [cuongcdha@hmu.vn](mailto:cuongcdha@hmu.vn) (N.C. Nguyen), [nhh@bachmai.edu.vn](mailto:nhh@bachmai.edu.vn) (H.H. Nguyen), [nhh@bachmai.edu.vn](mailto:nhh@bachmai.edu.vn) (N.H. Nguyen), [thsonvd@yahoo.com](mailto:thsonvd@yahoo.com) (H.S. Trinh).

<https://doi.org/10.1016/j.amsu.2021.102451>

Received 28 April 2021; Received in revised form 18 May 2021; Accepted 23 May 2021

Available online 28 May 2021

2049-0801/© 2021 Published by Elsevier Ltd on behalf of IJS Publishing Group Ltd. This is an open access article under the CC BY license

(<http://creativecommons.org/licenses/by/4.0/>).

### Abbreviations

CA	Chylous ascites
CL	Chylous leakage
CLAG	Conventional Lymphangiography
LA	Lymphatic ascites
LD	Lymphadenectomy
LN	Lymph node
MCT	Medium-chain triglyceride
MRL	Magnetic Resonance Lymphangiography
PDAC	Pancreatic ductal adenocarcinoma
PD	Pancreaticoduodenectomy
PLL	Postoperative lymphatic leakage
POD	postoperative day
PV	Portal vein
SMV	Superior mesenteric vein
TPN	Total parenteral nutrition

pancreaticoduodenectomy. All our work has been reported in line with the SCARE criteria and guidelines [7].

#### 1.1. Case presentation

A 59-year-old man underwent Pancreaticoduodenectomy (PD) with extended lymphadenectomy and segmental Superior Mesenteric Vein (SMV) resection for pancreatic ductal adenocarcinoma (PDAC) with SMV involvement. On postoperative day (POD) 7, after starting refeeding, over 1000 mL of slightly milky ascites was discharged from the inserted drain. A low-fat, middle-chain triglyceride (MCT) diet was prescribed for him but there were no improvements in 20 PODs. After that, he has been discharged to another hospital for further diagnosis and treatment. The first Magnetic Resonance Lymphangiography (MRL) with the intranodal injection of gadolinium-based contrast material into the bilateral inguinal lymph nodes were conducted, and the result showed abdominal effusions but no extravasation from central abdominal lymphatic channels (Fig. 1). This result made a hypothesis that the chylous extravasation may be located from the portal lymph system, which was not identified in Magnetic Resonance Lymphangiography. The interventional radiology service – CLAG with percutaneous transhepatic access was consulted and performed on POD 24 (Fig. 2). Ultrasound guidance was used to access the right and left portal lymph nodes using 8mm Chiba needles. A contrast agent was injected directly into the

lymph nodes under intermittent fluoroscopic observation to confirm filling of lymphatic channels until the one feeding the leaking lymphatic channel was identified. A 1:3 mixture of Aetoxisclerol to air was formulated, and approximately 8 mL of this mixture was injected into the culprit lymph node to embolize the leaking lymphatic channels.

After the first embolization, drainage remained to approximately 1000–1500 mL of serous fluid per day in the following days. Thus, on the third day after the first invasion, a non-contrast post-lymphangiographic computed tomography (post-LAG CT) is recommended and conducted, which can be carried out easily after iodized oil-based LAG, to illustrate better anatomical details of the lymphatic system and CL with three-dimensional spatial resolution, and the result was abdominal effusions concentrated at pouch of Douglas and root of the Mesentery (Fig. 3). On the fourth day after the first invasion, the second CLAG with percutaneous transhepatic access was performed. After accessing the right portal lymph nodes and identifying the chylous extravasation's location, A 1:1 mixture of Aetoxisclerol to air was formulated, and approximately 2 mL of this mixture was injected (Fig. 4).

After the second embolization, A low-fat, middle-chain triglyceride (MCT) diet was prescribed for him and drainage decreased to approximately 150 mL of serous fluid in the following days. The drain output remained low, and after 5 weeks until the surgery, the drainage was <20 mL daily and all drains were removed. Follow-up ultrasound and Magnetic Resonance Lymphangiography (MRL) demonstrated no residual fluid collection (Fig. 5). The patient was followed monthly with clinical examinations and abdominal ultrasound with no recurrence in 6-month follow-up.

## 2. Discussion

### 2.1. Hepatic Lymphatic Vascular System

About 80% of hepatic lymph falls into portal lymph system, while the remainder drains through sub-lobular and capsular lymph system [8]. After draining toward the portal pedicle, much of hepatic lymphatic fluid goes through the celiac region (LNs group no.9) and then to nodes located between the aorta and inferior vena cava under the renal vein (LNs group no.16a2), before reaching the thoracic duct [9]. There are totally three main routes within the gastro-hepatic ligament that the lymphatic hepatobiliary drainage flows through, and all routes reach toward the para-aortic LNs according to the classification by Ito et al. [9]. First, the main and constant hepato-cholecystic-retropancreatic route runs from the right the gastro-hepatic ligament to the posterior surface of the pancreatic head. Second, the accessory hepato-cholecystic-celiac route courses from the left of the

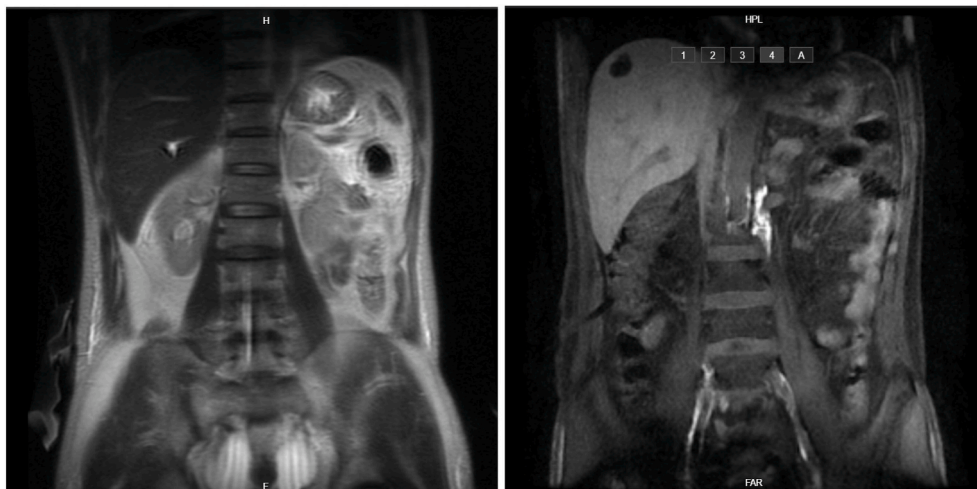
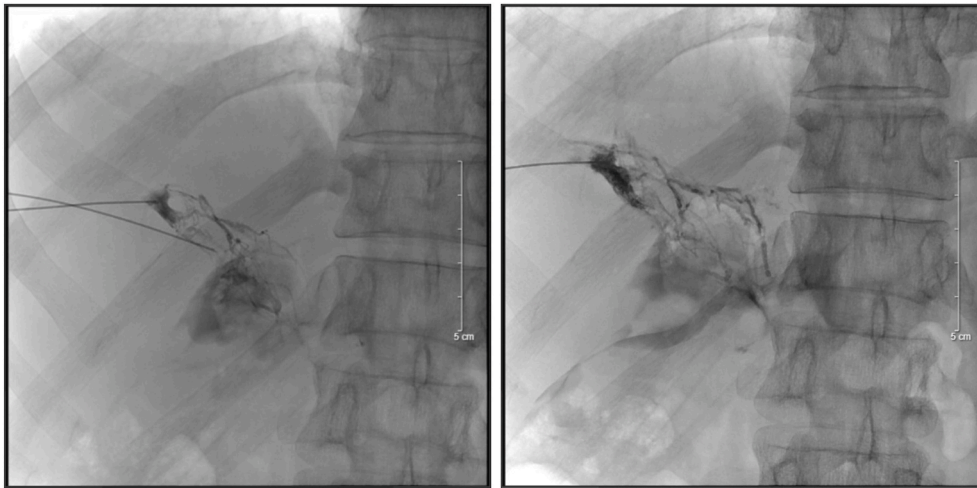
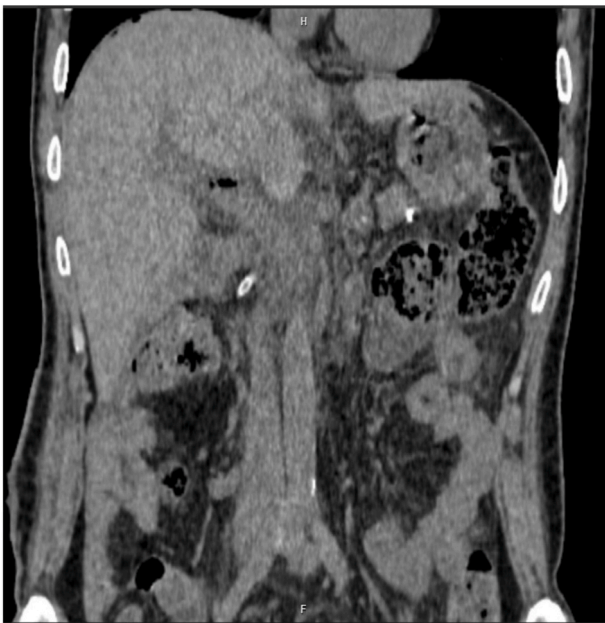
Fig. 1. The first Magnetic Resonance Lymphangiography (MRL) result showed abdominal effusions but no extravasation from central abdominal lymphatic channels.



**Fig. 2.** The first Conventional Lymphangiography. Ultrasound guidance was used to access the right and left portal lymph nodes using 8mm Chiba needles. After identifying the chylous extravasation's location, A 1:3 mixture of Aetoxisclerol to air was formulated, and approximately 8 mL of this mixture was injected.



**Fig. 3.** The post-lymphangiographic Computed tomography (post-LAG CT) result was abdominal effusions concentrated at pouch of Douglas and root of the Mesentery.

gastro-hepatic ligament to the common hepatic artery and celiac trunk. Third, the accessory hepato-cholecystic-mesenteric route starts from the anterior and left site of the portal trunk to the root of the superior mesenteric artery [9].

## 2.2. Definition and grading

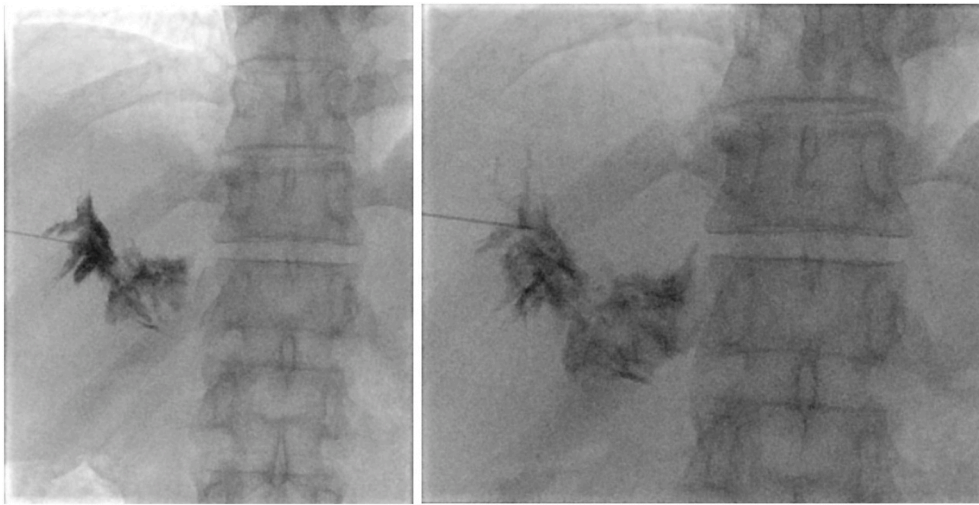
According the statement by the International Study Group on Pancreatic Surgery (ISGPS), Chyle leak (CL) was considered if there was an output of milky-colored fluid from a drain, drain site, or wound on or after POD 3, with a high content of triglyceride level ( $\geq 110$  mg/dL or  $\geq 1.2$  mmol/L) [10]. The cut-off values of volume of drainage range between  $\geq 100$  mL and  $>600$  mL per day. Following the severity as well as the management needed, there are three different grades were defined: grade A, which may be treated with oral dietary restrictions and no specific interventions; grade B, which may be lead to prolong of

hospital stay, and need more interventions such as nasoenteral nutrition with dietary restriction, total parenteral nutrition, octreotide, maintenance of surgical drains, or placement of new percutaneous drains; and grade C, with the need of other invasive treatments, intensive care unit admission, or mortality [10]. My patient has the volume of all intra-abdominal drainages ranged between 1000 mL and 1500 mL per day from POD 15. And this case was classified as grade C, patient had a fat – limited diet after surgery but it is failed to manage the symptoms. So that, more invasive therapies must proceed.

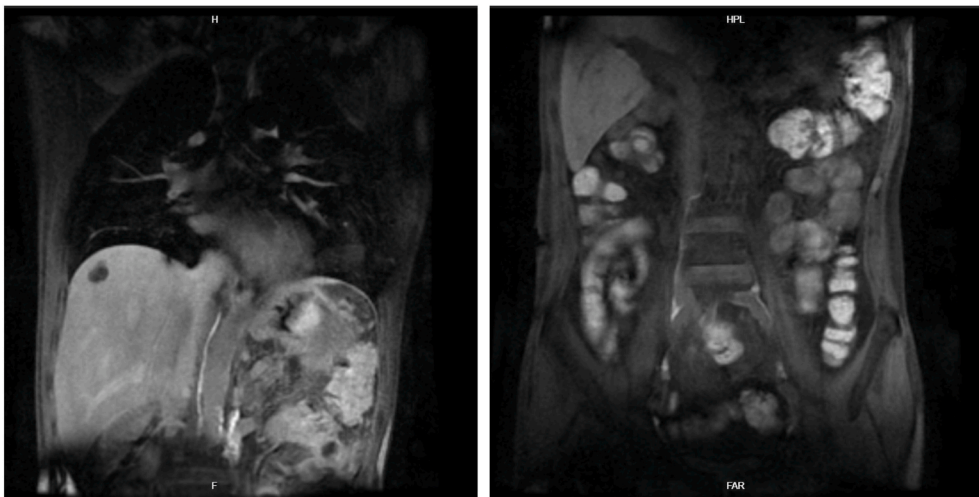
## 2.3. Incidence and independent risk factors

CL is an uncommon and potentially life-threatening complication following abdominal and retroperitoneal surgeries. A report by Singh H. et al. showed that the incidence of CL after pancreaticoduodenectomy was about 1.8–11.0% [11]. CL may be caused by several techniques like radical lymphadenectomy, concomitant vascular resection as well as associated with several complications like pancreatic fistula, and intra-abdominal abscess [12,13]. Assumpcao et al. suggested that the number of lymph nodes harvested, and vascular resection were independent risk factors for chylous ascites after pancreatic resection [14]. Two studies revealed that early enteral feeding was an independent risk factor for CL [15,16]. In other studies, dissection of the paraaortic area, as well as some factors such that the extent of lymph node dissection, the presence of retroperitoneal invasion, chronic pancreatitis, and total number of lymph nodes resected were identified as a risk factor for development of CL [14,16–19]. Surrounding inflammation induced by chronic pancreatitis was needed more extensive intervention, which was suggested with increasing the risk of CL [19]. A cohort study based in univariable analysis by O. Strobel et al. showed that preoperative diabetes was the only patient-related factor that tended to increase the risk of CL [12].

Few studies had mentioned about location of the lymphatic extravasation after pancreatic resection, especially after pancreaticoduodenectomy. A review by van der Gaag et al. resumed that the lymphatic extravasation and fistula were often located from intestinal lymphatics, cisterna chyli, and the peritoneal cavity due to the related anatomy with the pancreatic head [19]. Our research revealed another potential location of lymphatic fistula and leakage, that was portal lymphatic plexus, which was often isolated and dissected in pancreaticoduodenectomy, especially with extended lymphadenectomy. Moreover, from the technical aspect, using vessel sealing device instead of ligaturing lymphatic vessels, as well as early enteral feeding, should improve the risk of chylous fistulas in our patient.



**Fig. 4.** The second Conventional Lymphangiography. After accessing the right portal lymph nodes and identifying the chylous extravasation's location, A 1:1 mixture of Aetoxisclerol to air was formulated, and approximately 2 mL of this mixture was injected.



**Fig. 5.** The second Magnetic Resonance Lymphangiography (MRL) result demonstrated no residual fluid collection and no fistulas of the main lymphatic channels.

#### 2.4. Clinical and sub-clinical presentation

Clinical symptoms include abdominal distention (no pain), difficulty breathing (if the infusion is large). In the late stage, the disease can be understood as weight loss, weakness, and death. Vomiting and swelling of the scrotum (due to hydroceles) are common in young children. Anorexia and depression occur at any age. Chylous peritonitis is a rare cause of surgical abdomen. In the late stage, abdominal pain and local or spread abdominal tenderness is more observed. The disease can be misdiagnosed with appendicitis, cholecystitis, mesenteric embolism, or perforation of the hollow viscera. In these cases, exploratory surgery is required to make the diagnosis. The chylous fluid is painless, but the constriction of the retroperitoneal organs and the mesenteric serosa or infection will cause pain.

**Sampling peritoneal fluid** by paracentesis is gold standard for diagnosis of CL. In some different cases, a laboratory work-up is need for diagnosis as well as may alert the surgeon to the underlying cause. For instance, urine 5HIAA (serotonin) has been suggested as a quick and inexpensive screening test for neuroendocrine neoplasms, and ascitic hyaluronic acid's quantitation may be a routine screening test for mesothelioma. Hypoalbuminemia and lymphocytopenia may be suggested as a progressive condition and reflecting a poor prognosis. On **computed**

**tomography**, chylous fluid has a low attenuation, so that this imaging examination can be a useful tool to distinguished from acute hemorrhage. Meanwhile, **Lymphoscintigraphy** is a functional assessment of lymphatic system and become more and more popular for diagnosis and treatment, because of the ability to observe the leakage of chyle from disrupted lymph vessels or fistulas. Advantages of lymphoscintigraphy over lymphangiography include (1) no adverse effects, (2) no contraindications, and (3) the ability to perform repetitive studies [2]. Though, because of the rare implementation of lymphoscintigraphy, **lymphangiography** remains the gold standard in defining cases of lymphatic obstruction and fistula.

#### 2.5. Managements

**Conservative treatments.** Generally, there are three goals of conservative or noninvasive therapies for chyle leakage including: (1) maintaining and improving the patient's nutrition, (2) decreasing the formation of chylous fluid, and (3) adjusting the underlying disorder [20]. They are included:

- **Enteral therapy/Dietary therapy - Medium-chain triglyceride (MCT) diet.** MCT diet should be considered as the first therapy for the lymphatic

leakage. While MCTs pass directly into the portal system and couple to albumin, long-chain triglycerides will incorporate with fat-soluble vitamins in chylomicrons and then enter the intestinal lymphatic system [2]. So that, these treatment leads an especially decreasing of the bowel fat components' absorption [2]. Another dietary intake included a low-fat diet with restriction of long-chain triglycerides, and a fat – free diet [17].

- **Total parenteral nutrition (TPN).** TPN is an enhanced therapy compared with MCT diet, which totally allows bowel rest as well as decreases the production of lymph. Alongside this, the therapy supplies the absorption of proper proteins, vitamins, and electrolytes which promote protein synthesis, enhance plasma colloid osmotic pressure, and increase peritoneal effusion absorption [21]. Moreover, it can be used alone or combined with other therapies. A review by Shulan Lv. et al. revealed that TPN shows a optimistic effect while combined with somatostatin [2]. Though, TPN could be not always effective and maybe bring several complications or side effects such as infection, thrombosis, cholestasis, or mucosal integrity disorder compared with replacing enteral nutrition [11].
- **Somatostatin and its analogs.** The mechanism of somatostatin's effect in patients with high output lymphatic leakage is not clear. Some studies assumed that it may reduce the production of lymphatic fluid as well as concentrate the lymphatic vessels directly [22]. The somatostatin specific receptors may appear in some regions, including the pancreas, vascular tissue, and gastrointestinal tract, which induced the smooth muscle cells' contraction and inhibited the secretion and absorption of pancreatic, and gastrointestinal tract; as well as decrease lymphatic and splanchnic blood flow and decrease the hepatic venous pressure gradient by a direct action on lymphatic vessels [23]. Octreotide is one of the somatostatin analogs which has a much longer half-life. This allows octreotide is widely used in the treatment of lymphatic leakage with high effectation [24].

## 2.6. Invasive treatments

- **Paracentesis/drainage.** Drainage or paracentesis are therapies which relieve symptoms by decreasing the accumulation of chylous fluid. They are frequently effective in all forms of lymphatic complications, such as lymph ascites, lymphocele, chylous ascites, and chylothorax, especially following pelvic and paraaortic lymphadenectomy procedures [25]. However, it's still controversial with leaving a prophylactic drain after pancreaticoduodenectomy, with increasing the risk of infectious complications [19]. So that, abandoning drainage is not a standard practice.
- **Operative management.** Peritoneovenous shunt [26] and operation underdirect vision (with or without the use of special materials like fibrin glue) [27] are the most common surgical therapies to lymphatic leakage. Operations are only considered unless the failure of conservative treatment. Lijuan Xiu et al. summarized their recommendations for operations are: (1) leakage condition maintains for more than 2 weeks; (2) drainage volume reaches more than 1 L per day in one week postoperatively; (3) the patient experiences some metabolic complications [28]. The location of leakage could be detected with lymphangiography and concentration of high fat diet intake. Once it is identified, it can be cured with ligaturing, and suturing. Otherwise, if the leakage location cannot be detected, fibrin glue is widely used to coagulate the lymphatic channels adequately as a preventive measure.
- **Conventional Lymphangiography (CLAG).** Beside the use for diagnosis, lymphangiography is still considered as a novel therapeutic procedure and an alternative to conservative or surgical treatment of PLL. Recently, a systematic review by Sommer C.M. et al. summarized all data about CLAG for treatment performed up to September 2019 in the PubMed database. The results were optimistic, with the technical success rate is 75–100%, and the inability to inject the contrast material into the lymphatic system selectively is one of the

most reasons for technical failure [29]. Technically, there are two ways to access the lymphatic system for CLAG – transpedal and intranodal (groin, neck and axilla depending different institutes). In our case, we used a modified access for CLAG – percutaneous transhepatic. We used this access for some reasons below:

- The patient has the symptom of CL with high volume of chylous output through drainage and associated with the surgical process and the MRL results, we suggested the lymphatic extravasation source was from **Hepatic Lymphatic Vascular System**. So that, we chose a directed access to this system – through hepatic parenchyma to have an exact overlook as well as the higher successful rate for treatment.
- Our institute had an experience for CLAG through percutaneous transhepatic for diagnosis and treatment of CL after different surgical procedure.

## 2.7. Complications and outcome

Lymphangiography itself has several complications including the tissue necrosis, fat embolism and contrast agents' hypersensitivity relating to the volume and type [2]. Prolonged loss of chyle could lead to the condition of malnutrition and hypoproteinemia [2] and lymphocytopenia, which make patients to be more susceptible to infection-related complications [19]. A retrospective study by Mohammed A.H. et al. showed that CL was associated with a significantly increased incidence of portal or mesenteric venous thrombosis [17]. A prospective study by Lia Assumpcao et al. reported other associated complications of CL: abscess (4.3%), concomitant pancreatic fistula (4.3%), malnutrition (e. g., albumin <3.5 mg/dL) (91.5%), peritonitis (6.4%), and sepsis (12.8%) [14]. Hospital stay was considered as the main factor to assess the impact of CL on post – op result [12]. The grade A of isolated CL was not led to increase the length of hospital stay, while grade B or C on the other hand led to an increased hospital stay [19]. However, with coincidental CL, only grade C prolonged the hospital stay significantly [19].

In long – term outcome, few studies saw the significantly different results between groups of patients with or without CL complications [14]. The cohort study by O. Strobel et al. showed failure to manage the chyle leaks' condition in 14 days was associated with worse survival in patients who underwent palliative procedures significantly (in patients with failed treatment, the median OS was 5,2 months versus 16,4 months in patients whose chyle leak resolved,  $P = 0.016$ ), but not be significant in patients who had curative resections (median OS 20,5 versus 23,8 months respectively,  $P = 0.877$ ) [12]. So that, it is important to control this complication as soon as possible, especially in group of patients in advanced stage of malignancy diseases.

## 3. Conclusions

Chylous ascites is an uncommon but potentially life-threatening type of postoperative lymphatic leakage, especially following pancreaticoduodenectomy. Portal lymphatic plexus was a potential location of lymphatic fistula and leakage, due to the regularity of isolation and dissection in pancreaticoduodenectomy, especially with extended lymphadenectomy. CLAG with percutaneous transhepatic access is a relatively safe, effective, and reliable interventional method, which can identify lymphatic leakage and provides complete occlusion, especially with difficult-to-access lymphatic location such as the portal lymphatic vessels.

## Ethics approval

The study was approved by the Research Ethics Committee of Hanoi Medical University. The procedures used in this study adhere to the tenets of the Declarations of Helsinki.

## Funding

The authors declare no funding for this study.

## Author's contributions

Thanh Khiem NGUYEN: the main doctor conceived the original idea and operated the patients, wrote manuscript. Tuan Hiep LUONG: followed up, wrote manuscript. Ngoc Cuong NGUYEN: assessed the protocol, summed up, revised manuscript. Ham Hoi NGUYEN: operated the patients, summed up, revised manuscript. Ngoc Hung NGUYEN: operated the patients, summed up, revised manuscript. Hong Son TRINH: summed up, revised manuscript. All authors contributed to the interpretation of the results, discussed the results. All authors read and approved the final manuscript to submit.

## Consent

Written informed consent was obtained from the patient for publication of this case report and accompanying images. A copy of the written consent is available for review by the Editor-in-Chief of this journal on request.

## Registration of Research Studies

1. Name of the registry:
2. Unique Identifying number or registration ID:
3. Hyperlink to your specific registration (must be publicly accessible and will be checked):

## Guarantor

Thanh Khiem NGUYEN, MD. PhD  
Department of Gastrointestinal and Hepato-pancreato-biliary surgery, Bach Mai Hospital, Hanoi, Vietnam.  
Email: khiemnguyenthanh@yahoo.com

## Availability of data and materials

Data is available upon reasonable request and with permission of Hospital of Hanoi Medical University and Bach Mai Hospital.

All data generated or analyzed during this study are included in this published article.

## Declaration of competing interest

The authors declare that they have no conflicts of interests.

## References

- [1] P. Misthos, M.A. Kanakis, A.G. Lioulis, Chylothorax complicating thoracic surgery: conservative or early surgical management? *Updates Surg* 64 (2012) 5–11.
- [2] S. Lv, Q. Wang, W. Zhao, et al., A review of the postoperative lymphatic leakage, *Oncotarget* 8 (2017) 69062–69075.
- [3] J.G. Evans, P.E. Spiess, A.M. Kamat, et al., Chylous ascites after post-chemotherapy retroperitoneal lymph node dissection: review of the M. D. Anderson experience, *J. Urol.* 176 (2006) 1463–1467.
- [4] C.J. Ablan, F.N. Littooy, R.J. Freeark, Postoperative chylous ascites: diagnosis and treatment. A series report and literature review, *Arch. Surg.* 125 (1990) 270–273.
- [5] O. Strobel, U. Hinz, A. Gluth, et al., Pancreatic adenocarcinoma: number of positive nodes allows to distinguish several N categories, *Ann. Surg.* 261 (2015) 961–969.
- [6] J.A. Tol, D.J. Gouma, C. Bassi, et al., Definition of a standard lymphadenectomy in surgery for pancreatic ductal adenocarcinoma: a consensus statement by the International Study Group on Pancreatic Surgery (ISGPS), *Surgery* 156 (2014) 591–600.
- [7] R.A. Agha, T. Franchi, C. Sohrabi, G. Mathew, A. Kerwan, The SCARE 2020 guideline: updating consensus surgical CAse REport (SCARE) guidelines, *Int. J. Surg.* 84 (2020) 226–230.
- [8] O. Ohtani, Y. Ohtani, Lymph circulation in the liver, *Anat. Rec.* 291 (2008) 643–652.
- [9] D. Moszkowicz, F. Cauchy, S. Dokmak, J. Belghiti, Routine pedicular lymphadenectomy for colorectal liver metastases, *J. Am. Coll. Surg.* 214 (2012) e39–45.
- [10] M.G. Besselink, L.B. van Rijssen, C. Bassi, et al., Definition and classification of chyle leak after pancreatic operation: a consensus statement by the International Study Group on Pancreatic Surgery, *Surgery* 161 (2017) 365–372.
- [11] H. Singh, N. Pandit, G. Krishnamurthy, R. Gupta, G.R. Verma, R. Singh, Management of chylous ascites following pancreaticobiliary surgery, *JGH open : an open access journal of gastroenterology and hepatology* 3 (2019) 425–428.
- [12] O. Strobel, S. Brangs, U. Hinz, et al., Incidence, risk factors and clinical implications of chyle leak after pancreatic surgery, *Br. J. Surg.* 104 (2017) 108–117.
- [13] C. Koga, M. Murakami, J. Shimizu, et al., [A case of successful management of postoperative chylous ascites by combination therapy with octreotide and etilefrine], *Gan To Kagaku Ryoho* 45 (2018) 572–574.
- [14] L. Assumpcao, J.L. Cameron, C.L. Wolfgang, et al., Incidence and management of chyle leaks following pancreatic resection: a high volume single-center institutional experience, *J. Gastrointest. Surg.* 12 (2008) 1915–1923.
- [15] J.K. Kim, J.S. Park, H.K. Hwang, H.W. Shin, D.S. Yoon, Drainage volume After pancreaticoduodenectomy is a warning sign of chyle leakage that inversely correlates with a diagnosis of pancreatic fistula, *World J. Surg.* 37 (2013) 854–862.
- [16] S. Kuboki, H. Shimizu, H. Yoshidome, et al., Chylous ascites after hepatopancreatobiliary surgery, *Br. J. Surg.* 100 (2013) 522–527.
- [17] M. Abu Hilal, D.M. Layfield, F. Di Fabio, et al., Postoperative chyle leak after major pancreatic resections in patients who receive enteral feed: risk factors and management options, *World J. Surg.* 37 (2013) 2918–2926.
- [18] W. Pan, C. Yang, S.Y. Cai, et al., Incidence and risk factors of chylous ascites after pancreatic resection, *Int. J. Clin. Exp. Med.* 8 (2015) 4494–4500.
- [19] N.A. van der Gaag, A.C. Verhaar, E.B. Haverkort, O.R. Busch, T.M. van Gulik, D. J. Gouma, Chylous ascites after pancreaticoduodenectomy: introduction of a grading system, *J. Am. Coll. Surg.* 207 (2008) 751–757.
- [20] O.O. Aalami, D.B. Allen, C.H. Organ Jr., Chylous ascites: a collective review, *Surgery* 128 (2000) 761–778.
- [21] W. Ji, J. Wang, B. Song, et al., Cause analysis and therapeutic methods of chylous leakage after pancreaticoduodenectomy, *Saudi Med. J.* 35 (2014) 1396–1399.
- [22] E.A. Kim, H. Park, S.G. Jeong, C. Lee, J.M. Lee, C.T. Park, Octreotide therapy for the management of refractory chylous ascites after a staging operation for endometrial adenocarcinoma, *J. Obstet. Gynaecol. Res.* 40 (2014) 622–626.
- [23] S. Karaca, G. Gemayel, A. Kalangos, Somatostatin treatment of a persistent chyloperitoneum following abdominal aortic surgery, *J. Vasc. Surg.* 56 (2012) 1409–1412.
- [24] C. Yang, J. Zhang, S. Wang, C.C. Li, X.R. Kong, Z. Zhao, Successful management of chylous ascites with total parenteral nutrition and octreotide in children, *Nutr. Hosp.* 28 (2013) 2124–2127.
- [25] M.K. Frey, N.M. Ward, T.A. Caputo, J. Taylor, M.J. Worley Jr., B.M. Slomovitz, Lymphatic ascites following pelvic and paraaortic lymphadenectomy procedures for gynecologic malignancies, *Gynecol. Oncol.* 125 (2012) 48–53.
- [26] Y. Liu, C. Pan, J.Y. Tang, J. Chen, M. Zhou, Q.D. Ye, What is the result: chylous leakage following extensive radical surgery of neuroblastoma, *World journal of pediatrics : WJP* 8 (2012) 151–155.
- [27] M. Haraguchi, T. Kuroki, N. Tsuneoka, J. Furui, T. Kanematsu, Management of chylous leakage after axillary lymph node dissection in a patient undergoing breast surgery, *Breast* 15 (2006) 677–679.
- [28] L. Xiu, B. Yan, Z. Qin, et al., Chylous ascites treated by traditional Chinese herbal medicine: a case report and discussion, *Compl. Ther. Med.* 23 (2015) 63–67.
- [29] C.M. Sommer, C.C. Pieper, M. Itkin, et al., Conventional lymphangiography (CL) in the management of postoperative lymphatic leakage (PLL): a systematic review, *Röfo : Fortschritte dem Geb. Rontgenstrahlen Nukl.* 192 (2020) 1025–1035.