

Periodontal regeneration using bone morphogenetic protein 2 incorporated biomimetic calcium phosphate in conjunction with barrier membrane: A pre-clinical study in dogs

Lingfei Wei^{1,2}  | Fei Teng² | Liquan Deng³ | Gangfeng Liu⁴ | Mengyin Luan⁴ | Jie Jiang⁴ | Zhonghao Liu¹ | Yuelian Liu²

¹Department of Oral Implantology, Yantai Stomatological Hospital, Yantai, China

²Department of Oral Implantology and Prosthetic Dentistry, Academic Center for Dentistry Amsterdam (ACTA), Amsterdam, The Netherlands

³Key Laboratory of Stomatology, School of Stomatology, Zhejiang Chinese Medical University, Hangzhou, China

⁴Faculty of Stomatology, Binzhou Medical University, Yantai, China

Correspondence

Yuelian Liu, Department of Oral Implantology and Prosthetic Dentistry, Academic Center for Dentistry Amsterdam (ACTA), Amsterdam, The Netherlands.
Email: y.liu@acta.nl

Funding information

This project was supported by the Natural Science Foundation of Shandong Province (No.ZR2014HP019), Medical Science and Technology Development Plan of Shandong Province (No.2015WS0041) and Shandong Taishan Scholar Program to Dr. Yuelian Liu.

Abstract

Aim: To evaluate the effect of bone morphogenetic protein 2 (BMP-2) incorporated biomimetic calcium phosphate (BMP-2/BioCaP) in conjunction with barrier membrane on periodontal regeneration in chronic periodontitis experimental model.

Material and Methods: Chronic periodontitis experimental model with critical-sized supra-alveolar defects was created in 15 dogs' mandibles. After the initial periodontal therapy, the defects were randomly assigned to the following groups: (a) control; (b) barrier membrane; (c) deproteinized bovine bone mineral + barrier membrane; (d) BioCaP + barrier membrane and (e) BMP-2/BioCaP + barrier membrane (6 quadrants with 18 teeth per group). Eight weeks later, clinical examinations, micro-CT, and histomorphometric analyses were performed.

Results: Clinical examinations, including plaque index, bleeding index, and probing depth, were similar for all groups. In contrast, the clinical attachment loss was significantly lower in defects grafted with BMP-2/BioCaP and barrier membrane. The micro-CT results showed that the height of mineralized tissue in defects grafted with BMP-2/BioCaP and barrier membrane was significantly higher. For histometric analysis, the defects grafted with BMP-2/BioCaP and barrier membrane exhibited significantly more connective tissue height, new cementum height, new bone height and area, as well as less down-growth of junctional epithelium.

Conclusion: BMP-2/BioCaP could be a promising bone substitute for periodontal regeneration.

KEYWORDS

bone morphogenetic protein 2, bone substitute, periodontal tissue regeneration, supra-alveolar defect, tissue engineering

1 | INTRODUCTION

Periodontitis, one of the two common periodontal diseases, has historically been considered as a significant public health problem.

In the wake of the destructive process of periodontitis, the loss of connective tissue and bone comes up and leads to a reduced periodontium with various periodontal bone defects, such as intrabony defect, supra-alveolar defect, dehiscence defect, and so on (Larsson

This is an open access article under the terms of the Creative Commons Attribution-NonCommercial License, which permits use, distribution and reproduction in any medium, provided the original work is properly cited and is not used for commercial purposes.

© 2019 The Authors. *Journal of Clinical Periodontology* published by John Wiley & Sons Ltd

et al., 2016). Therefore, to repair and rebuild the reduced periodontium, regenerative periodontal therapy, in particular, bone regeneration, arises to meet the clinical need in improving the long-term prognosis for teeth. With the development of regenerative periodontal therapy, various regenerative approaches, including bone substitute materials, barrier membranes, root biomodifications, guided tissue regeneration, using biological factors or various combinations thereof, have been then implemented and demonstrated a variable extent of biological potential or evidence of periodontal regeneration (Ivanovski, Vaquette, Gronthos, Hutmacher, & Bartold, 2014; Sculean, Chapple, & Giannobile, 2015). Despite the considerable achievements in the periodontal regeneration of the deep, narrow intrabony and dehiscence defects, periodontal regeneration appears to be dramatically challenging and less predicting in the wide, shallow defects, for example, the supra-alveolar defect (Sculean, Nikolidakis, et al., 2015). Due to the compromised blood supply and mechanical support in these defects, it gives a higher demand for the characteristics of treatment components to achieve sufficient periodontal regeneration (Cortellini & Tonetti, 2015). Specific to the bone substitute materials, they may possess both osteoconductive and osteoinductive characteristics (Larsson et al., 2016; Miron & Zhang, 2012).

The superior osteoinductivity of bone morphogenetic protein 2 (BMP-2) has been well documented in recent decades. Moreover, recombinant human BMP-2 (rhBMP-2) delivered on an absorbable collagen sponge has been approved for clinical use in the field of orthopaedic and oral/maxillofacial surgery, including localized alveolar ridge augmentation and sinus augmentation. Several pre-clinical studies (Chen et al., 2007; King, King, Cruchley, Wozney, & Hughes, 1997; Miyaji et al., 2010; Saito, Saito, & Kawanami, 2003; Sigurdsson et al., 1995) have reported that BMP-2 in conjunction with various carriers have the potential to induce both bone and cementum formation. Despite the promising clinical potential of these products, there are emerging concerns on the high-dosage BMP-2 related side effects, which may result from its burst release and excessive proteolytic consumption (Chrastil, Low, Whang, & Patel, 2013; Tannoury & An, 2014; Wikesjo et al., 2003). Therefore, alternative safe, controlled and sustained delivery systems are urgently required.

Previously, our team developed a novel bone substitute material, bone morphogenetic protein 2 incorporated biomimetic calcium phosphate (BMP-2/BioCaP) (Zheng et al., 2014). Our previous studies (Liu et al., 2014, 2017) demonstrated that BMP-2/BioCaP was osteoinductive and could induce bone formation at both orthotopic and ectopic sites. Moreover, it showed superior properties of the local, limited and sustained release of BMP-2 in a cell-mediated manner, which partially mimics the principles of natural bone remodeling (Liu et al., 2014). Talwar R et al. (Talwar, Silvio, Hughes, & King, 2001) suggested that the release kinetics of BMP-2 could affect the outcome of BMP-2 induced periodontal regeneration, and the slow-released BMP-2 could promote cementum regeneration. Chen et al. (2007) found that the sustained released BMP-2 by microsphere improved bone and periodontal ligaments regeneration significantly.

Clinical Relevance

Scientific rationale for the study: Bone morphogenetic protein 2 (BMP-2) in conjunction with various carriers demonstrated to enhance the repair of periodontal defects. This study aimed to clinically and histologically verify the effect of a BMP-2 sustained and slow-released system (BMP-2/BioCaP) on periodontal regeneration in chronic periodontitis experimental models.

Principal findings: Clinically, BMP-2/BioCa, in conjunction with barrier membrane, reduced the clinical attachment loss. Histologically, BMP-2/BioCaP, in conjunction with barrier membrane, reduced the down-growth of junctional epithelium and enhanced the periodontal tissue regeneration, including the cement, the alveolar bone and the periodontal connective tissue.

Practical implications: BMP-2/BioCaP could be a promising bone substitute material for periodontal regeneration in clinical situations. Further clinical trials should be performed to confirm our findings and assumptions.

As an osteoinductive and sustained delivery system, BMP-2/BioCaP may have great potential for periodontal regenerations. This study aims to evaluate the effect of BMP-2/BioCaP in conjunction with barrier membrane on periodontal regeneration in chronic periodontitis experimental models with critical-sized supra-alveolar defects in dogs.

2 | MATERIAL AND METHODS

2.1 | Preparation of BioCaP and BMP-2/BioCaP granules

We produced the BioCaP and BMP-2/BioCaP granules according to a well-established protocol (Zheng et al., 2014). Briefly, amorphous calcium phosphate particles (the core of granules) were deposited by 5-fold-concentrated simulated body fluid (684 mM NaCl, 12.5 mM $\text{CaCl}_2 \cdot 2\text{H}_2\text{O}$, 5 mM $\text{Na}_2\text{HPO}_4 \cdot 2\text{H}_2\text{O}$, 21 mM NaHCO_3 , 7.5 mM $\text{MgCl}_2 \cdot 6\text{H}_2\text{O}$) for 24 hr at 37°C. Subsequently, to deposit crystalline calcium phosphate on the surface of particles, a supersaturated calcium phosphate solution was made (40 mM HCl, 4 mM $\text{CaCl}_2 \cdot 2\text{H}_2\text{O}$, 2 mM $\text{Na}_2\text{HPO}_4 \cdot 2\text{H}_2\text{O}$) for 48 hr at 37°C. To obtain the BioCaP granules, the amorphous calcium phosphate and crystalline calcium phosphate were then assembled alternately layer-by-layer in three cycles. To make BMP-2/BioCaP, BMP-2 (INFUSE® Bone Graft, Medtronic) was added to the solution of the last crystalline layer at a concentration of 2 µg/ml. The granules were ground to 0.25–1 mm diameter. As in our previous study (Zheng et al., 2014), the loading of BMP-2 in BMP-2/BioCaP granules was 182.6 ± 34.6 µg/g. Our previous studies (Liu et al., 2014, 2017; Wang et al., 2017; Zheng et al., 2014) had demonstrated that BioCaP functionalized by BMP-2

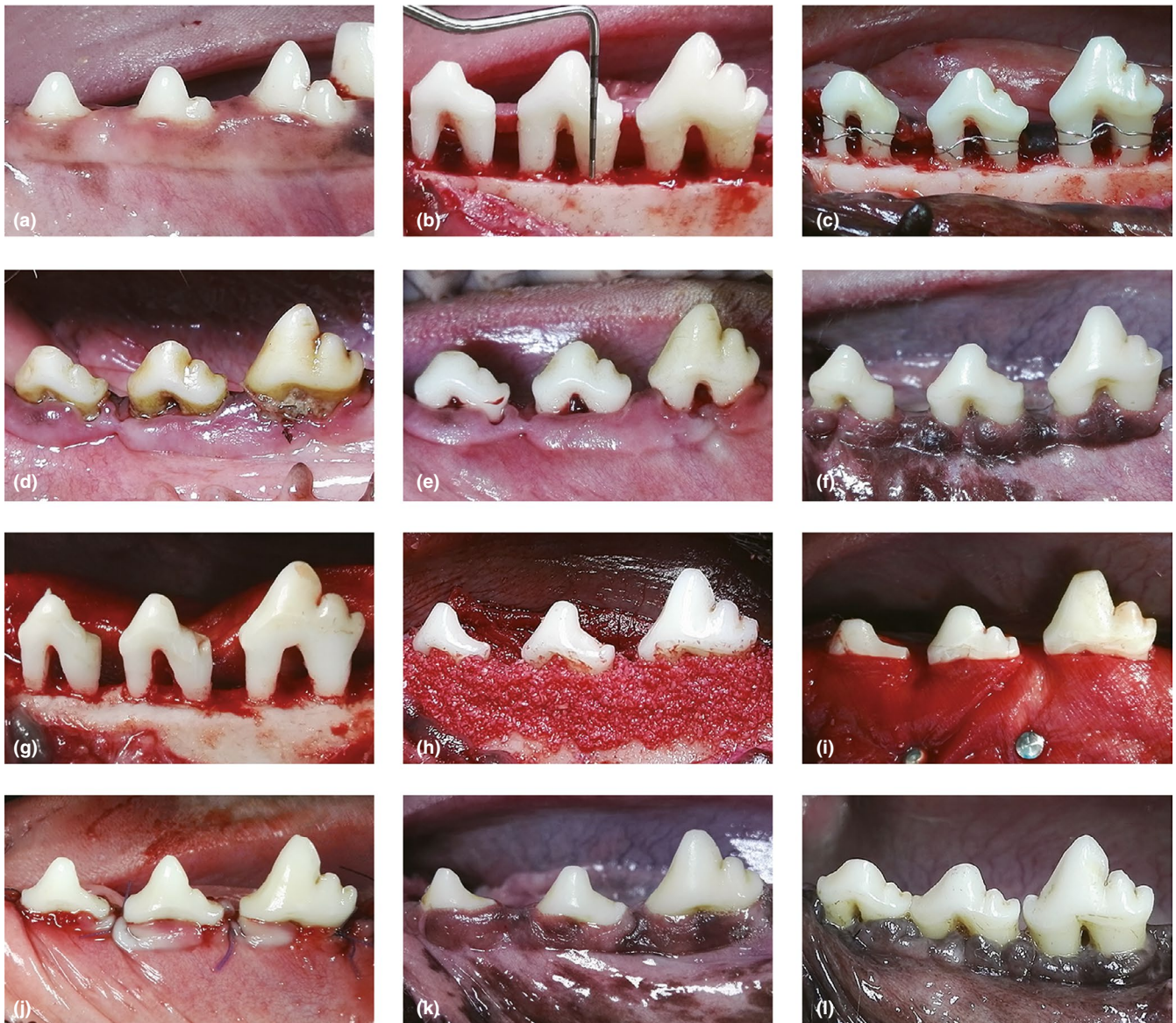

FIGURE 1 The experimental procedures in the mandibular teeth (the second, third, and fourth mandibular premolar). (a) preoperative observation; (b) the surgically created supra-alveolar periodontal defect; (c) the root was ligatured with wire to prevent spontaneous healing and enhance plaque accumulation; (d) chronic periodontitis 8 weeks after ligation; (e) initial periodontal therapy including scaling and daily plaque control; (f) clinically healthy gingiva after four weeks' stabilization period; (g) before bone augmentation; (h) application of bone grafts; (i) placement of barrier membrane; (j) sutured coronal to the cementum-enamel junction; (k) clinical observation in the BMP-2/BioCaP + barrier membrane group 8 weeks after the reconstructive surgery; (l) clinical observation in the BioCaP + barrier membrane group eight weeks after the reconstructive surgery

in this dosage had superexcellent osteogenic capability when they were filled in all kinds of bone defects. All these procedures were conducted under sterile conditions.

2.2 | Animals and surgical protocol

The experiment for this study was approved by the Committee of Ethics at Yantai Stomatological Hospital (permission no. 201611) and conformed to the ARRIVE Guidelines. We used 15 healthy male beagle dogs aged 18–24 months with an average weight of 12 kg. During the study, the dogs were housed in separate cage and fed with soft

diet. From the beginning of initial periodontal therapy to the end, the dogs received plaque control by brushing twice weekly and using a 0.5% chlorhexidine gluconate rinse daily.

Surgery was performed under general anaesthesia by sodium pentobarbital (intravenous, 20–30 mg/kg). Local infiltration anaesthesia (articaine hydrochloride with 1/100,000 epinephrine) was used in the mandible. For short-term procedures, such as taking out stitches, we used intravenous sodium thiopental anaesthesia (20–25 mg/kg). To control postoperative pain, ibuprofen was administered orally (10 mg/kg every 12 hr for 48 hr), and a broad spectrum antibiotic was administered daily for 7 days after surgery.

2.3 | Defect induction

Experimental procedures of establishing the chronic periodontitis experimental models were shown in the Figure 1. Supra-alveolar periodontal defects were surgically created in the mandibular teeth (the second, third and fourth premolar) as described by Wikesjo, Selvig, Zimmerman, and Nilveus (1991). Briefly, sulcular incisions and vertical releasing incisions were made on the buccal side, and buccal and lingual full-thickness flaps were elevated from the distal side of the canine tooth to the mesial side of the second molar. Then, under sterile saline irrigation, we used hand instruments and rotating burs to remove the full circumference of the designated premolar, involving the alveolar bone, the periodontal ligament and the cementum. Defect preparation further included extraction of the first premolar and amputation of the first molar to the crest of the reduced alveolar bone using water-cooled fissure bur. The pulpal tissue of the first molar was removed, and the root canals were filled with gutta-percha and calcium hydroxide paste. The supra-alveolar defect height from the cementum-enamel junction (CEJ) to the reduced alveolar bone was standardized at 5mm (Figure 1b).

To prevent spontaneous healing and to enhance plaque accumulation, we used wire encircling the tooth and bending into the defect to ligated the exposed root surfaces (Figure 1c). Subsequently, the flaps were restored to preoperative levels and sutured with 5-0 silk sutures. Ligature-induced chronic periodontitis (Figure 1d) was then allowed to develop for 8 weeks.

The wires were then removed and subjected to the initial periodontal therapy (Figure 1e), which included scaling and daily plaque control. After four weeks' stabilization period, the gingiva was clinically healthy (Figure 1f).

2.4 | Reconstructive surgery

After root planning to remove necrotic cementum and root conditioning by ethylenediaminetetraacetic acid (EDTA, 10% with pH 4.7), a notch was labelled at the most apical level of the defect as a reference for subsequent radiographic and histological measurements (Figure 1g). The supra-alveolar defects (30 mandibular jaw quadrants in total) were then randomly assigned to the following groups: (a) without grafts (control group); (b) covered with barrier membrane (Bio-Gide[®], Geistlich Pharma AG); (c) grafted with deproteinized bovine bone mineral (DBBM, Bio-Oss[®], Geistlich Pharma AG) and covered with barrier membrane; (d) grafted with BioCaP and covered with barrier membrane and (e) grafted with BMP-2/BioCaP and covered with barrier membrane (Figure 1h, 1.5 g bone substitute per mandibular jaw quadrant, 6 quadrants in 6 separate dogs with 18 teeth per group). The random assignment was determined by drawing lots and avoided allocating the same treatment to both of the two quadrants of one dog. To cover the grafted material entirely, barrier membrane was positioned and fixed on the apical alveolar bone (Figure 1i). Then, the mucoperiosteal flaps were

stretched and sutured slightly coronal to the cementum-enamel junction (Figure 1j).

2.5 | Clinical observations and analyses

Eight weeks after the reconstructive surgery, the plaque index was evaluated on one side of the teeth, and William's periodontal probe was used to evaluate the bleeding index on four sites of the teeth and to measure the probing depth and gingival recession on six sites. Clinical attachment loss was calculated by the probing depth and gingival recession.

2.6 | Radiographic observations and analyses

Eight weeks after the reconstructive surgery, animals were sacrificed by euthanasia. Tissue blocks were removed, rinsed and fixed in 10% buffered formalin. After 3 days of formalin fixation, the tissue blocks were rinsed overnight in cold tap water.

The tissue blocks were then scanned using a micro-CT imaging system (SkyScan1176, Bruker micro-CT). The scanner was set at a voltage of 90 kV, a current of 270 μ A and a resolution of 17.4 μ m per pixel. The samples were segmented for three-dimensional reconstruction, and representative sections were cut out using the built-in software. The defect height and mineralized tissue height (the central of root, the furcation and the interproximal space) were measured through pixel grey value differences.

2.7 | Histological observations and histometric analyses

The tissue blocks were then dehydrated in ethanol and embedded in methylmethacrylate, as previously described. Each block was cut into sections, at a fixed interval of 1,000 μ m in a buccolingual direction. The sections were mounted on plexiglass holders, polished down to a thickness of 50 μ m. The sections were stained with basic fuchsin, Toluidine Blue O and McNeal's Tetrachrome. The most central sections of the root were then selected for histomorphometric analyses (Koo, Polimeni, Albandar, & Wikesjo, 2004a), including the defect height, down-growth of junctional epithelium, connective tissue height, new cementum height, new bone height, new bone area and residual material area.

2.8 | Statistical analyses

The primary outcome was based on the periodontal bone regeneration (new bone height and area) following the reconstructive surgery. Data were collected at tooth level ($N = 17$ for the control group and $N = 18$ for the other four groups) and presented as mean and standard deviation. The significance of differences was analysed using one-way analysis of variance (ANOVA) followed by the SNK test. All data analysis was performed using SPSS 17.0 software, and a value of $p < .05$ was considered statistically significant.

TABLE 1 Summary of the clinical examination parameters 8 weeks after the reconstructive surgery. Plaque index, bleeding index and probing depth were similar for all groups. The clinical attachment loss was significantly lower in defects implanted with BMP-2/BioCaP and barrier membrane. If none of the letters labelled in the top right corner is the same, there would be a significant difference ($p < .05$)

	Control (n = 17)	Barrier mem- brane (n = 18)	DBBM + barrier mem- brane (n = 18)	BioCaP + barrier mem- brane (n = 18)	BMP-2/BioCaP + barrier membrane (n = 18)
Plaque index	1.24 (0.44) ^a	1.33 (0.49) ^a	1.39 (0.5) ^a	1.11 (0.47) ^a	1.06 (0.54) ^a
Bleeding index	1.61 (0.45) ^a	1.74 (0.68) ^a	1.96 (0.65) ^a	1.52 (0.64) ^a	1.42 (0.75) ^a
Probing depth (mm)	2.13 (0.27) ^a	2.11 (0.25) ^a	2.29 (0.3) ^a	2.15 (0.23) ^a	2.19 (0.52) ^a
Clinical attach- ment loss (mm)	3.73 (0.66) ^a	3.83 (1.09) ^a	3.4 (0.6) ^a	3.43 (0.84) ^a	2.36 (1.24) ^b

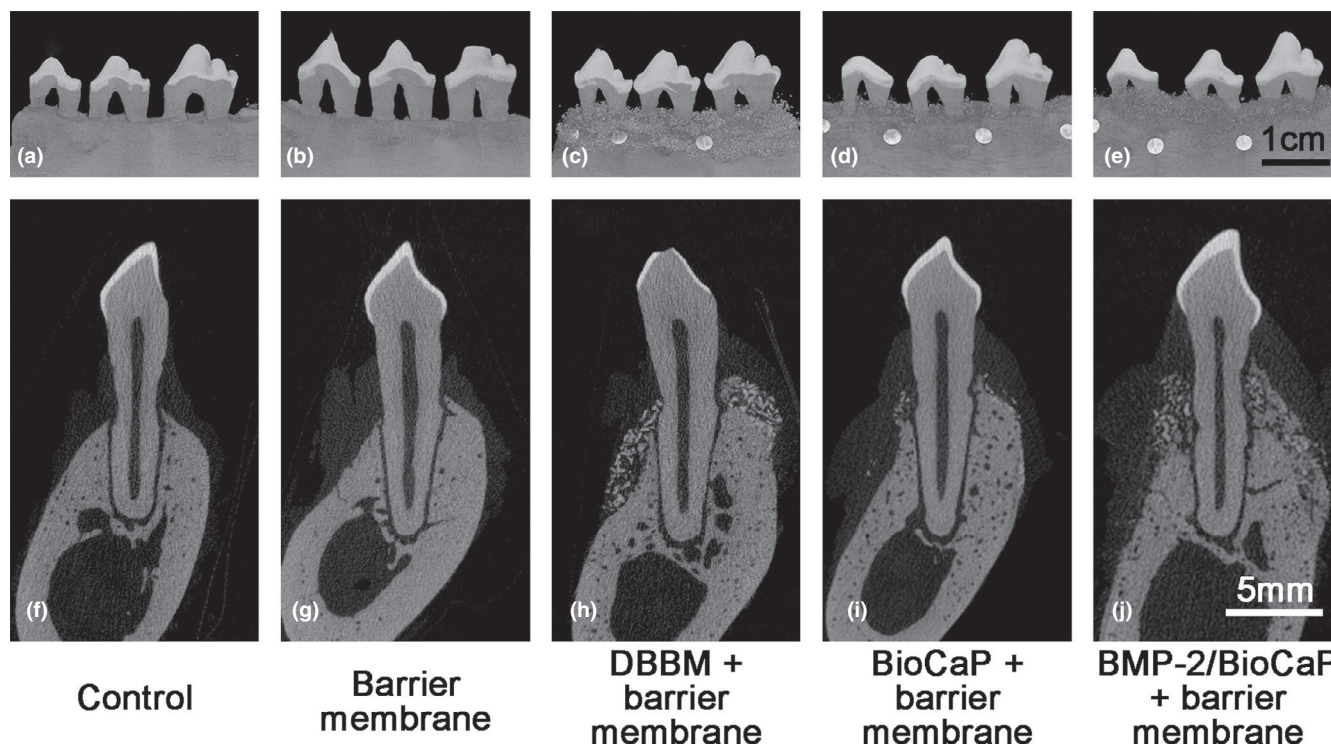


FIGURE 2 Radiographic observations 8 weeks after the reconstructive surgery. In sites of the control group (a, f) and the barrier membrane only group (b, g), there was little or no radiographic evidence of bone formation. Radiopacity compatible with the incompact and granular particles was observed in the DBBM + barrier membrane group (c, h). The density of the newly formed bone in the BioCaP + barrier membrane group (d, i) and BMP-2/BioCaP + barrier membrane group (e, j) was lower than that of the indigenous alveolar bone and the residual grafting materials. The BMP-2/BioCaP + barrier membrane group showed the most mineralized structure among all groups

3 | RESULTS

3.1 | Clinical observations and analyses

Wound closure was uneventful, and there was no intense inflammation throughout the healing sequence. One of the second premolars in the control group had root fracture; the tooth was extracted and excluded from the experiment.

Considerable periodontal tissue regeneration was observed eight weeks after the reconstructive surgery. The gingiva covered most of the root surface in BMP-2/BioCaP + barrier membrane group (Figure 1k). However, the other groups (Figure 1l) with exposed root had changed little. In the BMP-2/BioCaP + barrier

membrane group, the gingival recession was less serious than in the other groups. Clinical examination parameters including plaque index, bleeding index and probing depth were similar for all groups (Table 1). In contrast, the clinical attachment loss was significantly lower in defects that had BMP-2/BioCaP + barrier membrane.

3.2 | Radiographic observations and analyses

Eight weeks after the reconstructive surgery, there was high variability in the three-dimensional reconstructed images of the different groups. In sites of the control group (Figure 2a,f) and the barrier membrane only group (Figure 2b,g), there was little or no

TABLE 2 Summary of the radiographic analyses. The defect height among all groups showed no significant differences. In all sites (centre, furcation and interproximal space) of the root, the height of the mineralized tissue in the BMP-2/BioCaP + barrier membrane group was significantly larger than that in all other groups. If none of the letters labelled in the top right corner is the same, there would be a significant difference ($p < .05$)

	Control (n = 17)	Barrier mem- brane (n = 18)	DBBM + barrier mem- brane (n = 18)	BioCaP + barrier mem- brane (n = 18)	BMP-2/BioCaP + barrier membrane (n = 18)
Defect height (mm)	5.32 (0.38) ^a	5.49 (0.47) ^a	5.43 (0.3) ^a	5.53 (0.33) ^a	5.48 (0.27) ^a
Mineralized tissue height in the central of root (mm)	0.51 (0.34) ^c	0.51 (0.57) ^c	1.11 (0.81) ^b	1.09 (0.61) ^b	2.68 (0.85) ^a
Mineralized tissue height in the furca- tion (mm)	0.4 (0.32) ^b	0.42 (0.44) ^b	0.99 (0.66) ^b	0.79 (0.59) ^b	2.43 (1.08) ^a
Mineralized tissue height in the inter- proximal space (mm)	0.16 (0.2) ^c	0.17 (0.22) ^c	0.83 (0.46) ^b	0.98 (0.75) ^b	2.68 (1.06) ^a

radiographic evidence of bone formation. Radiopacity compatible with the incompact and granular particles was observed in the DBBM + barrier membrane group (Figure 2c,h), suggesting that significant numbers of particles remained at 8 weeks after the reconstructive surgery. The density of the newly formed bone in the BioCaP + barrier membrane group (Figure 2d,i) and BMP-2/BioCaP + barrier membrane group (Figure 2e,j) was lower than that of the indigenous alveolar bone and the residual grafting materials. The BioCaP + barrier membrane group exhibited a moderate amount of mineralized tissue that filled about 20% of the defect height. In comparison, the BMP-2/BioCaP + barrier membrane group showed a more mineralized structure with lamellar osteoid

that filled approximately 50% of the defect height. Radiographic evidence of root resorption, seroma formation and ankylosis was not noted in any of groups.

The results of the radiographic analyses were shown in Table 2. There were no significant differences in defect height among all groups, which demonstrated high consistency and repeatability in the chronic experimental periodontitis model with supra-alveolar defects. In all sites (centre, furcation and interproximal space) of the root, the mineralized tissue height of the BMP-2/BioCaP + barrier membrane group was significantly higher than that in all other groups. Although the mineralized tissue heights in the DBBM + barrier membrane group and the BioCaP + barrier

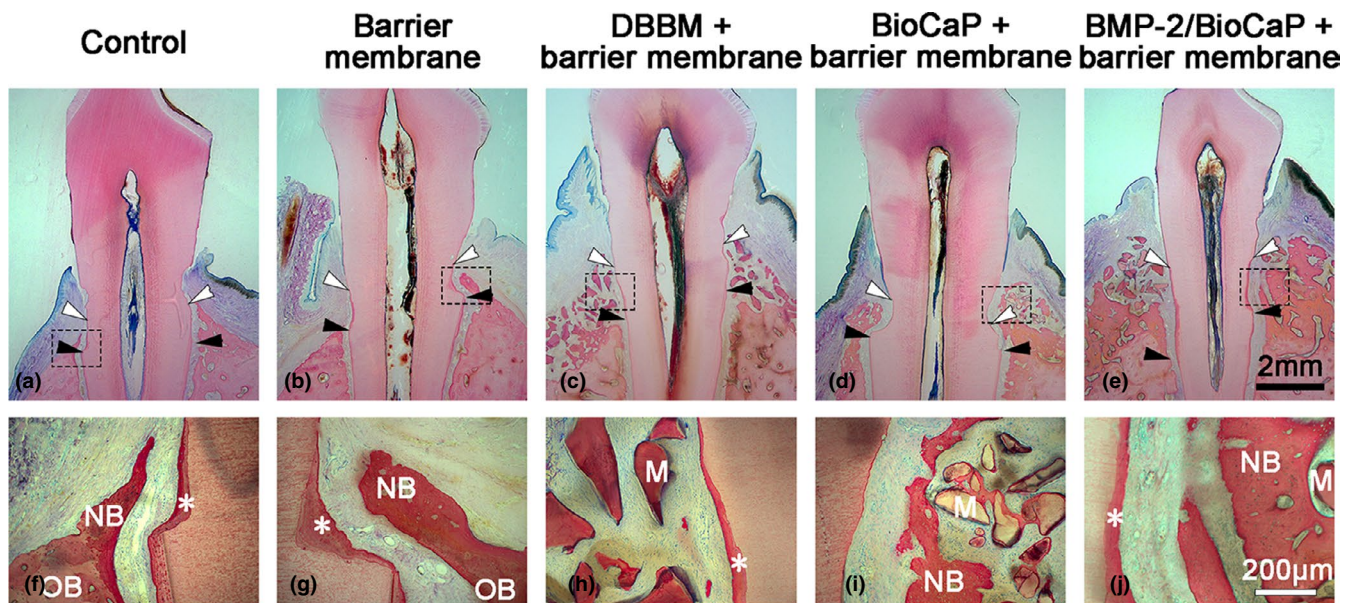


FIGURE 3 Representative histological observations eight weeks after the reconstructive surgery. In the control group (a, f) and the barrier membrane group (b, g), there was limited cementum and bone regeneration. In the DBBM + barrier membrane group (c, h), periodontal healing was moderate, and the remained DBBM granules were always immersed in connective tissue. In the BioCaP + barrier membrane group (d, i), periodontal regeneration was confined to the apical half of the defects. In the BMP-2/BioCaP + barrier membrane group (e, j), most of the defects were covered with regenerated periodontal tissue. White arrow: the coronal extension of newly formed cementum; black arrow: the apical extension of the root planning; *, new cementum; M, remained material; NB, new bone; OB, old bone

TABLE 3 Summary of the histometric analyses. There were no significant differences in defect height among these five groups. Significant differences were observed in the down-growth of junctional epithelium, connective tissue height, new cementum height, new bone height, new bone area between the BMP-2/BioCaP + barrier membrane group and the other four groups. Moreover, there is a significant difference in residual material area between the BMP-2/BioCaP + barrier membrane group and the BioCaP + barrier membrane group. If none of the letters labelled in the top right corner is the same, there would be a significant difference ($p < .05$)

	Control (n = 17)	Barrier mem- brane (n = 18)	DBBM + barrier mem- brane (n = 18)	BioCaP + barrier mem- brane (n = 18)	BMP-2/BioCaP + barrier membrane (n = 18)
Defect height (mm)	5.37 (0.41) ^a	5.23 (0.47) ^a	5.37 (0.5) ^a	5.45 (0.37) ^a	5.62 (0.4) ^a
Down-growth of junctional epithelium (mm)	3.46 (0.8) ^a	3.29 (0.75) ^a	2.97 (0.83) ^a	3.19 (0.56) ^a	2.25 (0.75) ^b
Connective tissue height (mm)	1.9 (0.58) ^b	1.94 (0.45) ^b	2.4 (0.64) ^b	2.25 (0.52) ^b	3.39 (0.82) ^a
New cementum height (mm)	0.65 (0.3) ^c	1.17 (0.35) ^b	1.19 (0.47) ^b	1.43 (0.4) ^b	1.78 (0.4) ^a
New bone height (mm)	0.51 (0.33) ^c	0.51 (0.54) ^c	0.7 (0.55) ^c	1.12 (0.61) ^b	2.48 (0.72) ^a
New bone area (mm ²)	0.86 (0.51) ^c	1.35 (1.59) ^{bc}	1.65 (1.46) ^{bc}	2.79 (1.85) ^b	9.78 (3.21) ^a
Residual material area (mm ²)	/	/	2.22 (1.78) ^a	0.47 (0.48) ^b	2.05 (1.26) ^a

membrane group were higher than those in the control group and the barrier membrane group in all sites of the root, the differences of these heights were not statistically significant in the root furcation.

3.3 | Histological observations and histometric analyses

Figure 3 showed representative histological photomicrographs of the centre of root in all groups. All groups exhibited limited inflammatory cell infiltration. As well as down-growth of junctional epithelium, all groups also exhibited connective tissue repair and newly formed bone and cementum. Root resorption and ankylosis were rarely noted in any of the groups.

In the control group (Figure 3a,f) and the barrier membrane group (Figure 3b,g), we observed little or no regeneration. When present, cementum and bone regeneration were observed in the very apical extension of the defects. The junctional epithelium had also migrated to the apical third.

Periodontal healing in the DBBM + barrier membrane group was moderate (Figure 3c,h) and was similar to that in the BioCaP + barrier membrane group. Different levels of cementum and bone regeneration were observed in different specimens. In contrast, DBBM granules were always immersed in connective tissue and remained unabsorbed.

In the BioCaP + barrier membrane group (Figure 3d,i), periodontal regeneration was confined to the apical half of the defects. Some specimens had irregularities in cementum regeneration that ranged from negative to encompass nearly half of the root surface. Newly formed bone was observed between the grafted BioCaP material and the root at the base of the defect. Bone-material contact was moderate, with some material being encapsulated by connective

tissue. Resorption lacunas were also observed on the surface of particles and new bone.

In the BMP-2/BioCaP + barrier membrane group, most of the defect height were covered with regenerated periodontal tissue (Figure 3e,j). In nearly half of the root surface, we identified a mass of cementum and functionally oriented periodontal ligament. The newly formed bone, including the woven- and parallel-fibred bone, extended from both the indigenous alveolar bone and the grafted BMP-2/BioCaP particles. While the majority of residual particles were completely entrapped within the new bone or were in close contact with it, a minority were encapsulated by connective tissue only in the coronal part of the defects. Multinucleated cells were observed on the surface of particles, which were resorbable and had been replaced by new bone.

Histometric analyses (Table 3) showed no significant differences in defect height among these five groups. These results were consistent with the radiographic analysis. Down-growth of junctional epithelium was significantly less in the BMP-2/BioCaP + barrier membrane group than in the other groups. Significantly more connective tissue repair was observed in the BMP-2/BioCaP + barrier membrane group than in the other groups. Cementum regeneration was significantly enhanced in the BMP-2/BioCaP + barrier membrane group than in the other groups. It was also significantly greater in the four groups with barrier membrane than in the control group. New bone height was significantly greater in the BMP-2/BioCaP + barrier membrane group (2.48 ± 0.72 mm) than in the BioCaP + barrier membrane group (1.12 ± 0.61 mm). The new bone area was 3.5-fold greater in the BMP-2/BioCaP + barrier membrane group (9.78 ± 3.21 mm²) than in the BioCaP + barrier membrane group (2.79 ± 1.85 mm², $p < .05$). Notably, there was a statistical significance in the residual material area between the BMP-2/BioCaP + barrier membrane group and the BioCaP + barrier membrane group.

4 | DISCUSSION

In the present study, we investigated the periodontal regeneration following the reconstructive surgery using different bone substitute materials in the chronic periodontitis experimental models. Our study demonstrated that BMP-2/BioCaP in conjunction with barrier membrane not only reduced the clinical attachment loss and the down-growth of junctional epithelium but also enhanced the periodontal tissue regeneration, including the cement, the alveolar bone and the periodontal connective tissue.

This study used a canine model system including the surgical created supra-alveolar periodontal defects, the induced experimental periodontitis and the initial periodontal therapy before the reconstructive surgery. Due to their specific dimensions and morphology, the supra-alveolar periodontal defects have been considering the "litmus test" for the potential candidate protocols, barrier membranes, bone substitute materials and biological agents aimed to achieve periodontal regeneration (Pellegrini, Seol, Gruber, & Giannobile, 2009; Wikesjo & Selvig, 1999). They are critical-sized defects, which will not spontaneously heal completely and can evaluate the efficiency of clinically relevant bone regeneration enhanced by the implantation materials (Schmitz & Hollinger, 1986). In our study, periodontal regeneration, particularly the newly formed alveolar bone and cementum, was shown to be limited 8 weeks after the reconstructive surgery in the control group. Meanwhile, comparative advantages in periodontal regeneration were observed in the other groups. Considering the real condition in the chronic periodontitis, we modified the model and induced experimental periodontitis by wire ligation as described by Saito et al. (Saito, Saito, Handa, Honma, & Kawanami, 2009; Saito et al., 2003). The deposit of plaque, inflammation of gingival, formation of deep pocket and loss of attachment were observed 8 weeks after ligation, and they confirmed to the clinical features of chronic periodontitis. In contrast to the previous studies, we performed the initial periodontal therapy before the reconstructive surgery to further simulate the normalized clinical treatment. About the consistency and repeatability of the supra-alveolar periodontal defects, they have been well documented by using the most central section for histometric analyses (Koo et al., 2004a; Koo, Polimeni, Albandar, & Wikesjo, 2004b). In our study, we used micro-CT to measure the defect height from the central of root and analysed mineralized tissue height from the central of the root, furcation and the interproximal. Then we analysed the height values by both micro-CT and histometric analyses from the central of the root. The two methods demonstrated similar results and further verified our conclusion.

Our study demonstrated 2-fold and 3-fold statistic differences in bone height (2.48 mm vs. 1.12 mm, or 44% vs. 21%) and area (9.78 mm² vs. 2.79 mm²) between the BMP-2/BioCaP + barrier membrane group and the BioCaP + barrier membrane group. Meanwhile, there were significant differences in bone height between the BioCaP + barrier membrane group and the other three groups (the control, barrier membrane and DBBM + barrier membrane group). Several pre-clinical studies (Kinoshita, Oda, Takahashi, Yokota, &

Ishikawa, 1997; Saito et al., 2003; Sorensen, Wikesjo, Kinoshita, & Wozney, 2004; Wikesjo et al., 1999) have reported that BMP-2 induced greater degree of periodontal bone regeneration in supra-alveolar periodontal defects when applied by single with various of carriers, including absorbable collagen sponge, polylactic acid polyglycolic acid copolymer and gelatine sponge, calcium phosphate cement and polymer-coated gelatine sponge. What is noteworthy is that two studies (Sorensen et al., 2004; Wikesjo et al., 1999) using BMP-2 in the surgical created and submerged defects reported extensive bone regeneration comprising over 80% of the defect height. In contrast, the other two studies (Kinoshita et al., 1997; Saito et al., 2003) using BMP-2 in the chronic and non-submerged defects reported modest bone regeneration comprising about 20% of the defect height. The reduced efficacy of BMP-2 maybe resulted in the inflammation in the chronic and non-submerged defects. When ruled out the interferences of the animal model, we find that BMP-2/BioCaP was an optimal carrier of BMP-2 and demonstrated excellent periodontal bone regeneration properties.

Apart from the superior bone regeneration, the BMP-2/BioCaP + barrier membrane group also demonstrated much more cementum regeneration than the other groups. Besides, all groups employing the barrier membrane indicated more cementum regeneration than the control group. These findings were consistent with the previous studies (Miyaji et al., 2010; Ribeiro et al., 2015). Notably, the height of cementum was lower than the height of the bone in the BMP-2/BioCaP + barrier membrane group. In contrast, the height of cementum was higher than the height of the bone in the other four groups. Although the sustained and slow-released BMP-2 could promote cementum regeneration (Talwar et al., 2001), our findings suggested that BMP-2 had a superior impact on osteogenesis than cementogenesis. As described in our previous study (Liu et al., 2018), only 50% of BMP-2 was released after 5 weeks. We can speculate that there would be more regenerated cementum if we extended the experimental period.

Also, different from some studies (Wikesjo et al., 1999, 2003), ankylosis was rarely noted when using BMP-2. One possible explanation is that there are remained periosteum under the mucoperiosteal flap when they are using the surgical created and submerged defects (King & Cochran, 2002). Moreover, the other one might be that BMP-2 is slowly released with low concentration from BMP-2/BioCaP.

One of the shortcomings of this study was the study design, which lacked a representative positive control group. That is because there was no standard treatment or commercially available product recommended for such defects. In this study, the use of DBBM, which was one of the most used bone substitutes in the market, was a kind of fallback solution. Besides, we have reported for several times that bone substitutes bearing the absorbed BMP-2 when used the same dose with the incorporated pattern showed similar osteogenic capability with the bone substitutes themselves and significantly lower new bone formation than the bone substitutes bearing the incorporated BMP-2 (Liu et al., 2014; Wu, Hunziker, Zheng, Wismeijer, & Liu, 2011; Wu, Liu, Iizuka, & Hunziker, 2010; Zheng et al., 2014). Therefore, in

this study, BioCaP with absorbed BMP-2 was not included as a control. One of the other claims is the scientific novelty and the practical implications using BMP-2/BioCaP in conjunction with barrier membrane for periodontal regeneration. Although the indications of those commercially available BMP-2 products do not contain periodontal treatment, BMP-2 has shown advantages in periodontal bone regeneration in pre-clinical studies (King et al., 1997; Kinoshita et al., 1997; Wikesjo et al., 1999). Besides, BMP-2 was traditionally considered to promote bone formation rather than periodontal regeneration, and this phenomenon may result from the burst release of BMP-2 (Chen et al., 2007; Talwar et al., 2001). We prepared BMP-2/BioCaP, and of which the BMP-2 was delivered in very low dosage (10-fold lower than the traditional method) and released locally and slowly. In our previous studies (Liu et al., 2017; Zheng et al., 2014), BMP-2/BioCaP has shown excellent bone regeneration properties. In this study, the BMP-2/BioCaP filled group displayed better results than the other groups not only in bone regeneration but also in cementum regeneration. Furthermore, there is a high probability of preferable periodontal regeneration by optimization of the dose of BMP-2, improvement of the barrier membrane, modification of surgery, extending of follow-up observation and the like. Moreover, of course, further pre-clinical and clinical studies should be performed to confirm our findings and assumptions.

5 | CONCLUSION

BMP-2/BioCaP in conjunction with barrier membrane can enhance periodontal tissue regeneration, and BMP-2/BioCaP could be a promising bone substitute for periodontal regeneration in clinical situations.

ACKNOWLEDGEMENTS

The authors also gave appreciate to Geistlich Pharma AG for the free-issue materials, including barrier membrane and deproteinized bovine bone mineral.

CONFLICTS OF INTEREST

The authors declare no potential conflicts of interest concerning the authorship and/or publication of this article.

ORCID

Lingfei Wei  <https://orcid.org/0000-0001-5035-4817>

REFERENCES

Chen, F. M., Zhao, Y. M., Zhang, R., Jin, T., Sun, H. H., Wu, Z. F., & Jin, Y. (2007). Periodontal regeneration using novel glycidyl methacrylated dextran (Dex-GMA)/gelatin scaffolds containing

- microspheres loaded with bone morphogenetic proteins. *Journal of Controlled Release*, 121, 81–90. <https://doi.org/10.1016/j.jconrel.2007.05.023>
- Chrastil, J., Low, J. B., Whang, P. G., & Patel, A. A. (2013). Complications associated with the use of the recombinant human bone morphogenetic proteins for posterior interbody fusions of the lumbar spine. *Spine (Phila Pa, 1976)*, 38, E1020–1027. <https://doi.org/10.1097/BRS.0b013e3182982f8e>
- Cortellini, P., & Tonetti, M. S. (2015). Clinical concepts for regenerative therapy in intrabony defects. *Periodontology 2000*, 68, 282–307. <https://doi.org/10.1111/prd.12048>
- Ivanovski, S., Vaquette, C., Gronthos, S., Huttmacher, D. W., & Bartold, P. M. (2014). Multiphasic scaffolds for periodontal tissue engineering. *Journal of Dental Research*, 93, 1212–1221. <https://doi.org/10.1177/0022034514544301>
- King, G. N., & Cochran, D. L. (2002). Factors that modulate the effects of bone morphogenetic protein-induced periodontal regeneration: A critical review. *Journal of Periodontology*, 73, 925–936. <https://doi.org/10.1902/jop.2002.73.8.925>
- King, G. N., King, N., Cruchley, A. T., Wozney, J. M., & Hughes, F. J. (1997). Recombinant human bone morphogenetic protein-2 promotes wound healing in rat periodontal fenestration defects. *Journal of Dental Research*, 76, 1460–1470. <https://doi.org/10.1177/00220345970760080801>
- Kinoshita, A., Oda, S., Takahashi, K., Yokota, S., & Ishikawa, I. (1997). Periodontal regeneration by application of recombinant human bone morphogenetic protein-2 to horizontal circumferential defects created by experimental periodontitis in beagle dogs. *Journal of Periodontology*, 68, 103–109. <https://doi.org/10.1902/jop.1997.68.2.103>
- Koo, K. T., Polimeni, G., Albandar, J. M., & Wikesjo, U. M. (2004a). Periodontal repair in dogs: Analysis of histometric assessments in the supraalveolar periodontal defect model. *Journal of Periodontology*, 75, 1688–1693. <https://doi.org/10.1902/jop.2004.75.12.1688>
- Koo, K. T., Polimeni, G., Albandar, J. M., & Wikesjo, U. M. (2004b). Periodontal repair in dogs: Examiner reproducibility in the supraalveolar periodontal defect model. *Journal of Clinical Periodontology*, 31, 439–442. <https://doi.org/10.1111/j.1600-051X.2004.00508.x>
- Larsson, L., Decker, A. M., Nibali, L., Pilipchuk, S. P., Berglundh, T., & Giannobile, W. V. (2016). Regenerative medicine for periodontal and peri-implant diseases. *Journal of Dental Research*, 95, 255–266. <https://doi.org/10.1177/0022034515618887>
- Liu, T., Wu, G., Zheng, Y., Wismeijer, D., Everts, V., & Liu, Y. (2014). Cell-mediated BMP-2 release from a novel dual-drug delivery system promotes bone formation. *Clinical Oral Implants Research*, 25, 1412–1421. <https://doi.org/10.1111/clr.12283>
- Liu, T., Zheng, Y., Wu, G., Wismeijer, D., Pathak, J. L., & Liu, Y. (2017). BMP2-coprecipitated calcium phosphate granules enhance osteoinductivity of deproteinized bovine bone, and bone formation during critical-sized bone defect healing. *Scientific Reports*, 7, 41800. <https://doi.org/10.1038/srep41800>
- Liu, Y., Schouten, C., Boerman, O., Wu, G., Jansen, J. A., & Hunziker, E. B. (2018). The kinetics and mechanism of bone morphogenetic protein 2 release from calcium phosphate-based implant-coatings. *Journal of Biomedical Materials Research Part A*, 106, 2363–2371. <https://doi.org/10.1002/jbm.a.36398>
- Miron, R. J., & Zhang, Y. F. (2012). Osteoinduction: A review of old concepts with new standards. *Journal of Dental Research*, 91, 736–744. <https://doi.org/10.1177/0022034511435260>
- Miyaji, H., Sugaya, T., Ibe, K., Ishizuka, R., Tokunaga, K., & Kawanami, M. (2010). Root surface conditioning with bone morphogenetic protein-2 facilitates cementum-like tissue deposition in beagle dogs. *Journal of Periodontal Research*, 45, 658–663. <https://doi.org/10.1111/j.1600-0765.2010.01281.x>

- Pellegrini, G., Seol, Y. J., Gruber, R., & Giannobile, W. V. (2009). Pre-clinical models for oral and periodontal reconstructive therapies. *Journal of Dental Research*, 88, 1065–1076. <https://doi.org/10.1177/0022034509349748>
- Ribeiro, F. S., Pontes, A. E., Zuza, E. P., da Silva, V. C., Lia, R. C., & Marcantonio Junior, E. (2015). Connective tissue graft as a biological barrier for guided tissue regeneration in intrabony defects: A histological study in dogs. *Clinical Oral Investigations*, 19, 997–1004. <https://doi.org/10.1007/s00784-014-1323-1>
- Saito, A., Saito, E., Handa, R., Honma, Y., & Kawanami, M. (2009). Influence of residual bone on recombinant human bone morphogenetic protein-2-induced periodontal regeneration in experimental periodontitis in dogs. *Journal of Periodontology*, 80, 961–968. <https://doi.org/10.1902/jop.2009.080568>
- Saito, E., Saito, A., & Kawanami, M. (2003). Favorable healing following space creation in rhBMP-2-induced periodontal regeneration of horizontal circumferential defects in dogs with experimental periodontitis. *Journal of Periodontology*, 74, 1808–1815. <https://doi.org/10.1902/jop.2003.74.12.1808>
- Schmitz, J. P., & Hollinger, J. O. (1986). The critical size defect as an experimental model for craniomandibulofacial nonunions. *Clinical Orthopaedics and Related Research*, 299–308. <https://doi.org/10.1097/00003086-198604000-00036>
- Sculean, A., Chapple, I. L., & Giannobile, W. V. (2015). Wound models for periodontal and bone regeneration: The role of biologic research. *Periodontology 2000*, 68, 7–20. <https://doi.org/10.1111/prd.12091>
- Sculean, A., Nikolidakis, D., Nikou, G., Ivanovic, A., Chapple, I. L., & Stavropoulos, A. (2015). Biomaterials for promoting periodontal regeneration in human intrabony defects: A systematic review. *Periodontology 2000*, 68, 182–216. <https://doi.org/10.1111/prd.12086>
- Sigurdsson, T. J., Lee, M. B., Kubota, K., Turek, T. J., Wozney, J. M., & Wikesjo, U. M. (1995). Periodontal repair in dogs: Recombinant human bone morphogenetic protein-2 significantly enhances periodontal regeneration. *Journal of Periodontology*, 66, 131–138. <https://doi.org/10.1902/jop.1995.66.2.131>
- Sorensen, R. G., Wikesjo, U. M., Kinoshita, A., & Wozney, J. M. (2004). Periodontal repair in dogs: Evaluation of a bioresorbable calcium phosphate cement (Ceredex) as a carrier for rhBMP-2. *Journal of Clinical Periodontology*, 31, 796–804. <https://doi.org/10.1111/j.1600-051X.2004.00544.x>
- Talwar, R., Di Silvio, L., Hughes, F. J., & King, G. N. (2001). Effects of carrier release kinetics on bone morphogenetic protein-2-induced periodontal regeneration in vivo. *Journal of Clinical Periodontology*, 28, 340–347. <https://doi.org/10.1034/j.1600-051x.2001.028004340.x>
- Tannoury, C. A., & An, H. S. (2014). Complications with the use of bone morphogenetic protein 2 (BMP-2) in spine surgery. *Spine Journal*, 14, 552–559. <https://doi.org/10.1016/j.spinee.2013.08.060>
- Wang, D., Tabassum, A., Wu, G., Deng, L., Wismeijer, D., & Liu, Y. (2017). Bone regeneration in critical-sized bone defect enhanced by introducing osteoinductivity to biphasic calcium phosphate granules. *Clinical Oral Implants Research*, 28, 251–260. <https://doi.org/10.1111/clr.12791>
- Wikesjo, U. M., Guglielmoni, P., Promsudthi, A., Cho, K. S., Trombelli, L., Selvig, K. A., ... Wozney, J. M. (1999). Periodontal repair in dogs: Effect of rhBMP-2 concentration on regeneration of alveolar bone and periodontal attachment. *Journal of Clinical Periodontology*, 26, 392–400. <https://doi.org/10.1034/j.1600-051X.1999.260610.x>
- Wikesjo, U. M., & Selvig, K. A. (1999). Periodontal wound healing and regeneration. *Periodontology 2000*, 2000(19), 21–39. <https://doi.org/10.1111/j.1600-0757.1999.tb00145.x>
- Wikesjo, U. M., Selvig, K. A., Zimmerman, G., & Nilveus, R. (1991). Periodontal repair in dogs: Healing in experimentally created chronic periodontal defects. *Journal of Periodontology*, 62, 258–263. <https://doi.org/10.1902/jop.1991.62.4.258>
- Wikesjo, U. M., Xiropaidis, A. V., Thomson, R. C., Cook, A. D., Selvig, K. A., & Hardwick, W. R. (2003). Periodontal repair in dogs: Space-providing ePTFE devices increase rhBMP-2/ACS-induced bone formation. *Journal of Clinical Periodontology*, 30, 715–725. <https://doi.org/10.1034/j.1600-051X.2003.00364.x>
- Wu, G., Hunziker, E. B., Zheng, Y., Wismeijer, D., & Liu, Y. (2011). Functionalization of deproteinized bovine bone with a coating-incorporated depot of BMP-2 renders the material efficiently osteoinductive and suppresses foreign-body reactivity. *Bone*, 49, 1323–1330. <https://doi.org/10.1016/j.bone.2011.09.046>
- Wu, G., Liu, Y., Iizuka, T., & Hunziker, E. B. (2010). The effect of a slow mode of BMP-2 delivery on the inflammatory response provoked by bone-defect-filling polymeric scaffolds. *Biomaterials*, 31, 7485–7493. <https://doi.org/10.1016/j.biomaterials.2010.06.037>
- Zheng, Y., Wu, G., Liu, T., Liu, Y., Wismeijer, D., & Liu, Y. (2014). A novel BMP2-coprecipitated, layer-by-layer assembled biomimetic calcium phosphate particle: A biodegradable and highly efficient osteoinducer. *Clinical Implant Dentistry and Related Research*, 16, 643–654. <https://doi.org/10.1111/cid.12050>

How to cite this article: Wei L, Teng F, Deng L, et al.

Periodontal regeneration using bone morphogenetic protein 2 incorporated biomimetic calcium phosphate in conjunction with barrier membrane: A pre-clinical study in dogs. *J Clin Periodontol*. 2019;46:1254–1263. <https://doi.org/10.1111/jcpe.13195>