

# Clinical Results of Dual SC Screw: A Mini-Sliding Hip Screw with an Anti-rotating Screw for Femoral Neck Fractures

Takafumi Hiranaka, MD, Toshikazu Tanaka, MD, Kenjiro Okumura, MD, Takaaki Fujishiro, MD, Rika Shigemoto, MD, Shotaro Araki, MD, Ryo Okada, MD, Ryohei Nako, MD, Koji Okamoto, MD

*Department of Orthopaedic Surgery and Joint Surgery Centre, Takatsuki General Hospital, Takatsuki, Japan*

**Background:** Dual SC screw (DSCS) is a unique concept internal fixation device consisting of a sliding screw and barrel assembly that enables compression force to be applied to the femoral neck fracture side. There are two types of barrels: a thread barrel and a plate barrel that has a one-holed side plate to prevent varus deformity. We report clinical results of the application of a DSCS with combined use of a thread barrel screw as an anti-rotational screw and a plate barrel screw as a compression hip screw.

**Methods:** We used DSCS for femoral neck fractures in 196 hip joints of 190 patients between November 2005 and June 2017. Among them, 70 hips in 66 patients (13 men and 53 women; mean age, 73.2 years) were followed up for at least 24 months. There were 53 nondisplaced fractures (Garden's classification stage 1 or 2) and 17 displaced fractures (stage 3 or 4). We evaluated the postoperative walking ability of the patients who were followed up for at least 24 months and examined details of all complications.

**Results:** The mean follow-up period was 37.4 months (range, 24–144 months). Forty-two (64%) out of the 66 patients who were followed up for at least 2 years were able to walk independently with or without a cane. The incidence of complications was 11.5% in nondisplaced fractures and 17.5% in displaced fractures, and arthroplasty was required in 5.8% and 5.0%, respectively. The most frequent complication was secondary displacement including cutout and shortening of the femoral neck, but no implants showed varus displacement.

**Conclusions:** The application of DSCS for the treatment of femoral neck fractures had satisfactory results. The complication rate was low, and there was no postoperative varus displacement of DSCS in either displaced or nondisplaced fractures. We suggest DSCS is a reliable option for both displaced and nondisplaced femoral neck fractures.

**Keywords:** *Femoral neck fracture, Treatment, Operation, Screw, Complication*

In surgical treatment of femoral neck fractures, arthroplasty (AR) allows for low complication rates and high postoperative functional improvement and is thus preferred to internal fixation (IF).<sup>1)</sup> Conversely, IF has been

reported to cause comparatively minor damage to soft tissue, require shorter operation times, and result in less intraoperative blood loss than AR.<sup>2)</sup> In the IF technique, fixation is typically performed using multiple screws (MS)<sup>3)</sup> or compression hip screws (CHS). Hanson pins<sup>4)</sup> are often used instead of MS in Sweden and Japan. Compared to CHS, the MS technique has advantages (less invasiveness and less blood loss), but its stability is dependent on the three-point theory.<sup>5)</sup> The reoperation rate when using CHS is, therefore, lower than that when using MS, and many reports recommend the use of CHS.<sup>3,6)</sup>

Received August 17, 2020; Revised February 15, 2021;

Accepted February 15, 2021

Correspondence to: Takafumi Hiranaka, MD

Department of Orthopaedic Surgery and Joint Surgery Centre, Takatsuki General Hospital, 1-3-13, Kosobe, Takatsuki, Osaka 569-1192, Japan

Tel: +81-72-681-3801, Fax: +81-72-682-3834

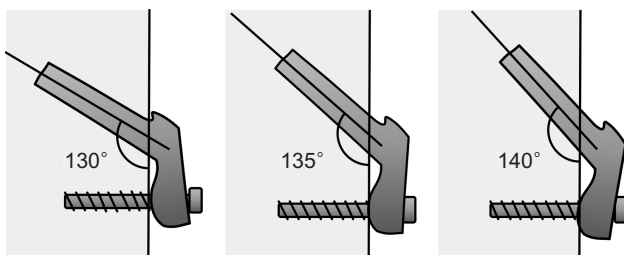
E-mail: takafumi.hiranaka@gmail.com

A meta-analysis by Zhang et al.<sup>7)</sup> showed that fixation with CHS resulted in fewer postoperative complications than with multiple cannulated screws. It could therefore be recommended, even for elderly patients. CHS have also been shown to provide more secure stability than multiple cannulated screws in mechanical research.<sup>8)</sup> Meanwhile, CHS have a tendency to cause femoral head rotation during lag screw insertion,<sup>9)</sup> and maintaining postoperative rotational stability of the femoral head can be difficult.<sup>10)</sup>

The dual SC screw (DSCS; KiSCO, Kobe, Hyogo, Japan) was developed as an implant with the advantages of both the MS and CHS devices<sup>11)</sup> (Fig. 1). It comprises a screw and a barrel, a two-piece structure. The screw can slide within the barrel, and by advancing the screw only



**Fig. 1.** A dual SC screw comprises a slidable screw and a barrel with a thread (thread-barrel) or with a one-hole plate (plate-barrel). The anatomical angle of the plate and the screw of the plate barrel is set at 135°.

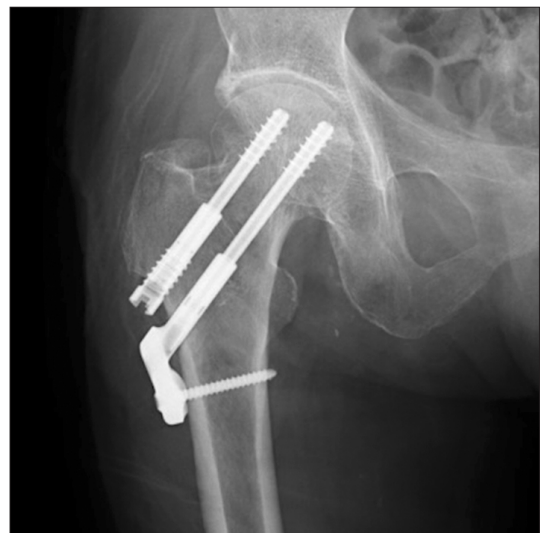

**Fig. 2.** Characteristics of the side plate of the dual SC screw. The plate has a round shape to ensure a secure contact on the bone cortex with 135° ± 5° of acceptable range. Notably, the base of the barrel never touches the bone surface if the screw is inserted steeper than 135°.

into the femoral head with respect to the barrel fixed to the lateral bone cortex of the femoral shaft, intraoperative compression force can be applied between the fragments. The sliding mechanism also enables application of compression to the fracture site by loading. As the screw slides inside the barrel, the end of the screw is unlikely to back out. Two types of barrels are available: a thread-barrel has a thread and a plate-barrel has a one-hole plate. The angle of the plate and the screw of the plate barrel is set at an anatomical angle of 135°. The plate has a unique round shape to achieve a secure contact with the bone cortex with ± 5° of acceptable range (Fig. 2). Using two thread-barrels in parallel is possible, but the recommended method is to use one plate barrel and one thread barrel, such as a mini CHS with an anti-rotation screw (Fig. 3).<sup>11)</sup> The DSCS is considered to have the benefits of both CHS and MS, so we hypothesized that IF of femoral neck fractures using a DSCS could reduce complications. Here, we retrospectively examine cases treated with a DSCS at an independent institution over more than a 10-year period.

## METHODS

This study was approved by the Institutional Review Board of the authors' affiliated institution (IRB No. 2018-13). DSCS was used for femoral neck fractures in 196 hip joints (190 patients) at our hospital between November 2005 and June 2017. As this study is retrospective, patients were not required to give written informed consent to the study. We also applied the opt-out method to obtain consent on this



**Fig. 3.** Postoperative X-ray image of a dual SC screw. The plate barrel was used as a mini-compression hip screw along with a thread barrel used as an anti-rotation screw.

study. IF was carried out in all nondisplaced fractures (156 hips) and in the displaced type fractures (40 hips) where IF was considered to be beneficial, such as in young patients or in high-risk elderly patients requiring minimally invasive surgery.

The combined use of one plate barrel screw and one thread barrel screw was applied in all cases. Physical therapy was started from the day after the operation. Early mobilization was encouraged in all patients as long as the medical condition was tolerable. The immediate bearing of full-weight was encouraged for all patients except for younger patients with displaced fractures (typically < 70 years of age). Six weeks without weight-bearing was instead recommended for such patients. Of these, 17 patients (17 hips) died within 24 months, 25 hips in 24 patients had complications within 24 months, and 84 hips in 83 patients could not be followed up for more than 24 months. We followed the remaining 70 hips in 66 patients without complications for at least 24 months (mean, 39.4 months; range, 24–144 months). This included 53 nondisplaced fractures (8 men and 42 women; mean age, 74.2 years) and 17 displaced fractures (4 men and 13 women; mean age, 66.3 years) (Fig. 4). One female patient had bilateral fractures, displaced on one side and nondisplaced on the other side. We assessed the patient's walking ability and radiographic findings, such as shortening of the femoral neck, perforation of the screw, and cutout. Shortening of the fracture was considered to exist when the shortening was more than 10 mm. This can appear on radiography as a protrusion of the screw end from the barrel, as the ac-

ceptable sliding length of the screw within the barrel is 10 mm. We also examined details of any complications.

## RESULTS

The mean follow-up period was 37.4 months (range, 24–144 months). Thirty-two out of 49 patients with nondisplaced fractures and 10 out of 17 patients with displaced fractures (64% of overall patients) were able to walk independently with or without a cane. Seven patients (4 nondisplaced and 3 displaced) died within 2-year follow-up. All fractures eventually achieved radiographic union.

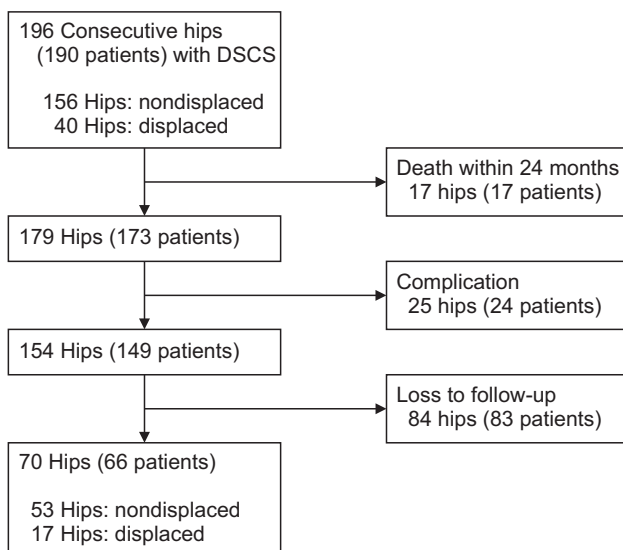
Table 1 shows all complications. Complications occurred in 25 hip joints in 24 patients (12.8%), of which 18 were the nondisplaced type (11.5%), and the remaining 7 were the displaced type (17.5%). Ten hips were treated conservatively and eventually healed. The remaining 15 hips (7.6%), comprising 12 nondisplaced (7.6%) and 3 displaced (7.5%), underwent reoperation. Among them, 11 hips (5.6%), 9 nondisplaced hips (5.8%) and 2 displaced hips (5.0%), required AR.

The most frequent complication was secondary displacement of the femoral head, which occurred in 13 hips (6.6%). Three of them resulted in cutout, and 4 caused shortening of the femoral neck, requiring hip AR. On the other hand, in the remaining 6 hips, although shortening occurred, bone fusion was eventually obtained. No loss of parallelism of the screws was found, except for 1 case, and no varus displacement of the implant occurred in any cases.

Avascular osteonecrosis was found in 6 patients (3.1%), 5 of whom underwent artificial joint replacement. All but 1 of the cases were nondisplaced fractures. Subtrochanteric fractures occurred in 3 patients (1.5%); however, they were concentrated within a restricted period and with specific operators, suggesting technical problems. Two patients underwent operation (IF with a plate and an intramedullary nail) and the other patient was treated conservatively.

## DISCUSSION

The rate of complications requiring AR after IF for femoral neck fractures using a DSCS was 5.6%. Previous studies have reported failure rates of 8%–24% in nondisplaced and 35%–62% in displaced fractures.<sup>12</sup> Notably, there was no difference in the failure rate between the nondisplaced type and the displaced type in the current study. The results were satisfactory, although there is a possibility of selection bias because IF was not performed for all displaced



**Fig. 4.** Patient recruitment flow diagram. DSCS: dual SC screw.

**Table 1.** List of Complications

No.	Age (yr)	Sex	Garden's classification stage	Complication	Treatment
1	87	Female	1	Screw perforation	Screw removal & artificial bone filling
2	65	Female	1	Cutout	Total hip arthroplasty
3	84	Female	1	Avascular necrosis	Hemiarthroplasty
4	84	Female	1	Avascular necrosis	Total hip arthroplasty
5	80	Female	1	Femoral neck shortening, nonunion	Hemiarthroplasty
6	67	Female	1	Femoral neck shortening, nonunion	Hemiarthroplasty
7	87	Male	1	Femoral neck shortening	Conservative
8	84	Female	1	Femoral neck shortening	Conservative
9	78	Female	1	Femoral neck shortening	Conservative
10	65	Female	1	Extrasosseous insertion	Conservative
11	70	Female	2	Cutout	Hemiarthroplasty
12	74	Female	2	Avascular necrosis	Conservative
13	88	Female	2	Avascular necrosis	Hemiarthroplasty
14	82	Female	2	Subtrochanteric fracture	Osteosynthesis (plate)
15	77	Female	2	Femoral neck shortening, nonunion	Hemiarthroplasty
16	63	Female	2	Femoral neck shortening, nonunion	Hemiarthroplasty
17	63	Female	2	Femoral neck shortening	Conservative
18	86	Female	2	Subtrochanteric fracture	Osteosynthesis (intramedullary nailing)
19	89	Female	3	Femoral neck shortening	Conservative
20	80	Female	3	Subtrochanteric fracture	Conservative
21	69	Male	3	Extrasosseous insertion	Conservative
22	76	Female	3	Avascular necrosis	Hemiarthroplasty
23	63	Female	3	Femoral neck shortening	Conservative
24	52	Male	4	Cutout	Hemiarthroplasty
25	60	Female	4	Screw perforation, avascular necrosis	Screw removal & artificial bone filling

**Table 2.** Cross-sectional Areas of Various Implants

Variable	Diameter (mm)	No. of usage	Cross-sectional area (mm <sup>2</sup> )
DHS (DePuy Synthes, Solothurn, Switzerland)	8.0	1	50.3
Cannulated screw	6.5	3	99.5
Hansson pin (Swemac, Linköping, Sweden)	6.5	2	66.4
Dual SC screw (KISCO, Kobe, Japan)	5.0	2	39.3

DHS: dynamic compression hip screw.

fractures. Moreover, similar satisfactory results were observed even in those patients who were followed up for more than 2 years. We propose reasons for such satisfactory results. Firstly, the addition of the side plate, despite being short and only one-holed, achieved sufficient angular stability. By contrast, when MS are used, it is necessary for the distal screw to fully contact the calcar femorale due to the three-point theory.<sup>5)</sup> However, reliably inserting the screw at this site is technically difficult. Secondly, despite the acquisition of angular stability, the cross section of the device itself is small; the screw diameter is 5 mm, and the total sectional area is smaller than that of other devices, as shown in Table 2. This enables preservation of the bone volume and securing of the bone contact area. These attributes seem to be beneficial for both bony fusion and intraosseous blood flow.

The most frequent postoperative displacement of a DSCS resulted in shortening of the femoral neck. Reoperation was selected in cases of remarkable shortening, but eventual bony fusion could be achieved even in such cases of neck shortening. However, threads extended from the screw tip by a length of 20 mm. If the thread hits the fracture lines by sliding, further sliding will be inhibited and compression between the fragments may not be applied, resulting in increased risks of nonunion and cutout. A shorter thread screw may be preferable. On the other hand, none of the implants showed varus deformity. The parallelism of two screws was compromised in one case, but all plate barrel screws were stable due to the angular stability in the same way as CHS. Varus deformity with rotation of the femoral head occurred in the cutout case. This may be inevitable because the stability between the bone and the screw mainly relies on the bone quality; it would be fragile in patients with femoral neck fractures. Nevertheless, DSCS is thought to be valuable because of the excellent angular stability of the implant that will minimize the risk of the complication.

Subtrochanteric fractures after insertion of MS occurred at the screw insertion site in 2%–3% of reported cases.<sup>13,14)</sup> Suggested reasons for the fractures have been too distal screw insertion<sup>15)</sup> and repeated insertion of guide wires.<sup>13)</sup> Due to such risks of fracture, Jansen et al.<sup>16)</sup> reported that the use of screws alone should be avoided in elderly people with osteoporosis. It is thought to be possible, however, to avoid stress concentration at the screw insertion site by using the plate. Noda et al.<sup>17)</sup> compared the stress distribution around insertion sites between the Hanson pin and the DSCS using a finite element analysis method. They concluded that dispersion of the stress was apparent with the use of a DSCS. This suggests that side

plates are effective in dispersing the stress. Nevertheless, a trochanteric fracture after insertion of a DSCS occurred in three cases. The reasons for these fractures in DSCS remain unclear, but a possible cause might be a deeper insertion of the barrel into the bone hole because the barrel end never touches the bone if the screw is inserted steeper than 135°, as shown in Fig. 2. Moreover, the base of the barrel is flared. The insertion should be stopped once the plate touches the bone, and then fixation should be done with a cortical screw. These cases were concentrated within a specific period and operations were carried out by inexperienced surgeons. The problems were probably due to a technical error, such as overtightening of the cortical screw rather than mechanical weakness of the DSCS.

We encountered osteonecrosis in 6 cases (3.1%), fewer than the previously reported incidence of 15%–25%.<sup>18–21)</sup> MRI was not performed for all cases, so there may be symptomatic necrosis without X-ray abnormality. Various factors are involved in the occurrence of osteonecrosis. Madsen et al.<sup>22)</sup> stated that a smaller diameter maintains blood flow in the fracture area and is advantageous in preventing osteonecrosis. DSCS has the smallest cross-sectional area of an implant (Table 2), so retention of bone volume must be considered as a reason for the lower incidence of osteonecrosis. Also, adequate stability achieved by the use of a side plate will probably have a positive effect on the occurrence of osteonecrosis.

New concept implants have been used recently; Targon FN (B-Braun AG, Melsungen, Germany) has four tele-screws to fix the femoral head and a two-holed side plate, and good results have been reported.<sup>23–25)</sup> Brandt and Verdonschot<sup>26)</sup> studied the mechanical properties of CHS, MS, and the Targon FN in their cadaveric biomechanical analysis and showed that the load-to-failure for the Targon FN was greater than for MS. Proper insertion of the implant is, however, technically difficult,<sup>27)</sup> and the four tele-screws are arranged in a rectangular shape. According to a recent study by Nakanishi et al.,<sup>28)</sup> the cross section of the femoral neck is not a rectangle, but rather a reverse right triangle. Insertion of the four screws into the femoral neck might therefore be difficult. On the other hand, the DSCS has the advantage of flexibility in the arrangement of the screw (with 135° ± 5° of acceptable angle range).

There are several limitations of this study, including the selection of cases. IF was carried out in most non-displaced fractures, but it was only performed in a small number of cases of displaced fractures. We are also aware of the bias in the selection of the IF using DSCS for displaced fractures. It was only used in limited cases, such as in young patients (typically ≤ 70 years of age, and those



with a severe systemic disease). Otherwise, we selected hemiarthroplasty. We do not recommend the routine use of DSCS in all displaced fracture cases, but for the limited patients who should avoid AR, DSCS can be considered a reasonable option. Despite the small number of displaced type fractures, the incidence of complications was similar. A second limitation of this study is that a high proportion of cases were lost to follow-up; approximately half of the cases could not be followed up for 2 years. Most were transferred to other institutions and did not return for their follow-up visits. The incidences of complications we calculated were based on all patients, so it is possible that the complications from this treatment are actually higher than the reported results. Although the majority of patients with complications tend to return to the hospital where the original operation was performed, the actual complication rate is still unknown. Further prospective study is needed to clarify this. A third limitation is that there were no control patients who were treated with other implants. Our hospital used DSCS fixation in all cases when IF was required, so there was no control population. However, despite the inclusion of approximately 20% of displaced fractures, the incidence of complications was comparable to that of past reports.<sup>12)</sup> Lastly, a precise radiographic evaluation was not performed and radiographic analyses of the screw insertion sites, fracture displacement, and avascular necrosis would be beneficial to clarify the mechanical merit of the DSCS. This study

was retrospective and focused on the characteristics of the DSCS and its complications, but further prospective study focusing on radiographic analysis is needed. Despite these limitations, we suggest DSCS is beneficial for both displaced and nondisplaced fractures, providing angular stability with the use of a side plate.

Fixation with a DSCS for femoral neck fractures had satisfactory results. Resistance to varus deformity was improved by adding a plate, and there were few cases of reoperation. A comparison study with other devices is needed to evaluate the benefits of the DSCS.

## CONFLICT OF INTEREST

No potential conflict of interest relevant to this article was reported.

## ORCID

Takafumi Hiranaka <https://orcid.org/0000-0003-4916-6071>  
 Toshikazu Tanaka <https://orcid.org/0000-0001-8846-8027>  
 Kenjiro Okumura <https://orcid.org/0000-0003-1267-6625>  
 Takaaki Fujishiro <https://orcid.org/0000-0002-9317-5883>  
 Rika Shigemoto <https://orcid.org/0000-0002-3305-203X>  
 Shotaro Araki <https://orcid.org/0000-0002-6882-5290>  
 Ryo Okada <https://orcid.org/0000-0002-2563-6502>  
 Ryohei Nako <https://orcid.org/0000-0002-3025-2562>  
 Koji Okamoto <https://orcid.org/0000-0003-2098-3238>

## REFERENCES

- Blomfeldt R, Tornkvist H, Ponzer S, Soderqvist A, Tide-  
mark J. Comparison of internal fixation with total hip  
replacement for displaced femoral neck fractures: random-  
ized, controlled trial performed at four years. *J Bone Joint  
Surg Am.* 2005;87(8):1680-8.
- Parker MJ, Palmer CR. A new mobility score for predict-  
ing mortality after hip fracture. *J Bone Joint Surg Br.*  
1993;75(5):797-8.
- Lee YS, Chen SH, Tsuang YH, Huang HL, Lo TY, Huang  
CR. Internal fixation of undisplaced femoral neck fractures  
in the elderly: a retrospective comparison of fixation meth-  
ods. *J Trauma.* 2008;64(1):155-62.
- Stromqvist B, Hansson LL, Nilsson LT, Thorngren KG. Hook-  
pin fixation in femoral neck fractures: a two-year follow-up  
study of 300 cases. *Clin Orthop Relat Res.* 1987;(218):58-62.
- Bout CA, Cannegieter DM, Juttman JW. Percutaneous  
cannulated screw fixation of femoral neck fractures: the  
three point principle. *Injury.* 1997;28(2):135-9.
- Ma JX, Kuang MJ, Xing F, et al. Sliding hip screw versus can-  
nulated cancellous screws for fixation of femoral neck frac-  
ture in adults: a systematic review. *Int J Surg.* 2018;52:89-97.
- Zhang LL, Zhang Y, Ma X, Liu Y. Multiple cannulated  
screws vs. dynamic hip screws for femoral neck fractures: a  
meta-analysis. *Orthopade.* 2017;46(11):954-62.
- Baitner AC, Maurer SG, Hickey DG, et al. Vertical shear  
fractures of the femoral neck: a biomechanical study. *Clin  
Orthop Relat Res.* 1999;(367):300-5.
- Gupta M, Arya RK, Kumar S, Jain VK, Sinha S, Naik AK.  
Comparative study of multiple cancellous screws versus  
sliding hip screws in femoral neck fractures of young adults.  
*Chin J Traumatol.* 2016;19(4):209-12.
- Rau FD, Manoli A 2nd, Morawa LG. Treatment of femoral  
neck fractures with the sliding compression screw. *Clin Or-  
thop Relat Res.* 1982;(163):137-40.
- Hiranaka T, Tsuji M, Uemoto H, Hida Y, Fujibayash I, Iwasa

- K. Dual SC screw system for the femoral neck fractures. *J Jpn Soc Fract Repair*. 2008;30(2):315-8.
12. Hoelsbrekken SE, Opsahl JH, Stiris M, Paulsrud O, Stromsoe K. Failed internal fixation of femoral neck fractures. *Tidsskr Nor Laegeforen*. 2012;132(11):1343-7.
13. Howard CB, Davies RM. Subtrochanteric fracture after Garden screw fixation of subcapital fractures. *J Bone Joint Surg Br*. 1982;64(5):565-7.
14. Andrew TA, Thorogood M. Subtrochanteric fracture after Garden screw fixation: a review of predisposing factors and management in nine cases. *Injury*. 1984;16(3):169-77.
15. Neumann L. Subtrochanteric fractures following Gouffon pinning of subcapital femoral fractures. *Injury*. 1990;21(6):366-8.
16. Jansen H, Frey SP, Meffert RH. Subtrochanteric fracture: a rare but severe complication after screw fixation of femoral neck fractures in the elderly. *Acta Orthop Belg*. 2010;76(6):778-84.
17. Noda M, Takahashi M, Miyazaki K, Tezuka D, Naoi K, Adachi K. Computer simulated comparative study between Hansson pins and Dual SC screws in femoral neck fracture analyzed with finite element method. *J Jpn Soc Fract Repair*. 2015;37(2):505-8.
18. Nikolopoulos KE, Papadakis SA, Kateros KT, et al. Long-term outcome of patients with avascular necrosis, after internal fixation of femoral neck fractures. *Injury*. 2003;34(7):525-8.
19. Asnis SE, Wanek-Sgaglione L. Intracapsular fractures of the femoral neck: results of cannulated screw fixation. *J Bone Joint Surg Am*. 1994;76(12):1793-803.
20. Lu-Yao GL, Keller RB, Littenberg B, Wennberg JE. Outcomes after displaced fractures of the femoral neck: a meta-analysis of one hundred and six published reports. *J Bone Joint Surg Am*. 1994;76(1):15-25.
21. Xu DF, Bi FG, Ma CY, Wen ZF, Cai XZ. A systematic review of undisplaced femoral neck fracture treatments for patients over 65 years of age, with a focus on union rates and avascular necrosis. *J Orthop Surg Res*. 2017;12(1):28.
22. Madsen F, Linde F, Andersen E, Birke H, Hvass I, Poulsen TD. Fixation of displaced femoral neck fractures: a comparison between sliding screw plate and four cancellous bone screws. *Acta Orthop Scand*. 1987;58(3):212-6.
23. Parker MJ, Stedtfeld HW. Internal fixation of intracapsular hip fractures with a dynamic locking plate: initial experience and results for 83 patients treated with a new implant. *Injury*. 2010;41(4):348-51.
24. Osarumwense D, Tissingh E, Wartenberg K, et al. The Targon FN system for the management of intracapsular neck of femur fractures: minimum 2-year experience and outcome in an independent hospital. *Clin Orthop Surg*. 2015;7(1):22-8.
25. Takigawa N, Yasui K, Eshiro H, et al. Clinical results of surgical treatment for femoral neck fractures with the Targon® FN. *Injury*. 2016;47 Suppl 7:S44-8.
26. Brandt E, Verdonschot N. Biomechanical analysis of the sliding hip screw, cannulated screws and Targon1 FN in intracapsular hip fractures in cadaver femora. *Injury*. 2011;42(2):183-7.
27. Korver RJ, Wieland AW, Kaarsemaker S, Nieuwenhuis JJ, Janzing HM. Clinical experience, primary results and pitfalls in the treatment of intracapsular hip fractures with the Targon® FN locking plate. *Injury*. 2013;44(12):1926-9.
28. Nakanishi Y, Hiranaka T, Shirahama M, et al. Ideal screw positions for multiple screw fixation in femoral neck fractures: study of proximal femur morphology in a Japanese population. *J Orthop Sci*. 2018;23(3):521-4.