



The Vital Role of ^{131}I -MIBG in Localization of Paraganglioma at Unusual Sites

Tejasvini Singhal¹ Parneet Singh¹ Hardik Veerwal¹ Manishi L Narayan¹

¹Department of Nuclear Medicine, All India Institute of Medical Sciences, Rishikesh, Uttarakhand, India

Address for correspondence Manishi L. Narayan, MBBS, MD, Department of Nuclear Medicine, All India Institute of Medical Sciences, Rishikesh, Uttarakhand, 249203, India (e-mail: manishi.Ln@gmail.com).

World J Nuclear Med 2022;21:251–254.

Abstract

Paragangliomas (PGLs) are extra-adrenal neuroendocrine tumors. PGL of the urinary bladder are very rare and commonly present with features of hypertensive crisis, headache, syncope, and other symptoms of sympathetic excess. A few of these tumors are silent at the presentation. Here, we report a case of a urinary bladder PGL, presenting with lower abdominal pain.

Keywords

- ▶ bladder PGL
- ▶ ^{131}I MIBG
- ▶ neuroendocrine tumor
- ▶ paraganglioma
- ▶ urinary bladder

Introduction

Pheochromocytomas are chromaffin cell-derived neuroendocrine tumors (NET) occurring in the adrenal medulla. Such tumors occurring at extra-adrenal sites are referred to as paraganglioma (PGL). Paragangliomas of urinary bladder are rare.^{1,2} Here, we are reporting a rare case of PGL of urinary bladder who presented with lower abdominal pain.

Case Summary

A 55-year-old female presented with the complaint of lower abdominal pain for 6 years. Pain was more on micturition. Her physical examination was unremarkable. There was no other comorbidity. Patient underwent contrast-enhanced computed tomography abdomen, which revealed 4.1 × 3.4 cm size, exophytic, well-defined mass lesion, arising from the neck of the urinary bladder and bulging into the bladder lumen. On laboratory evaluation, there was marked elevation of plasma normetanephrines, 2,260 ng/L (20–135.4 ng/L) and plasma metanephrines were also signifi-

cantly raised, 166 ng/L (7.9–88.7). Magnetic resonance imaging (MRI) pelvis revealed well-defined lobulated, intensely enhancing submucosal urinary bladder mass lesion. Considering clinical and radiological findings, likely possibility of PGL, rhabdomyosarcoma and carcinoma urinary bladder were considered. Subsequently, patient was referred to Nuclear Medicine Department and iodine-131 meta-iodobenzylguanidine (^{131}I MIBG) scan was performed after intravenous injection of 27.75 MBq (0.75 mCi) of ^{131}I MIBG. Whole body planar images (–Fig. 1) were acquired 24 and 48 hours after the injection, which showed MIBG avid lesion in pelvic region. Single-photon emission computed tomography/computed tomography (SPECT/CT) pelvis (–Fig. 2) was acquired at 48 hours, which revealed a discrete MIBG avid lesion, involving right lateral wall of urinary bladder, which is congruent with the site of an intraluminal, exophytic soft tissue density, mass lesion seen near the neck of urinary bladder. No significant background urinary tracer activity seen in the bladder at 48 hours. Also, no other ^{131}I MIBG avid lesion was seen in rest of the body to suggest multiplicity or metastatic disease. There was no concomitant

DOI <https://doi.org/10.1055/s-0042-1751054>.
ISSN 1450-1147.

© 2022. World Association of Radiopharmaceutical and Molecular Therapy (WARMTH). All rights reserved.

This is an open access article published by Thieme under the terms of the Creative Commons Attribution-NonDerivative-NonCommercial-License, permitting copying and reproduction so long as the original work is given appropriate credit. Contents may not be used for commercial purposes, or adapted, remixed, transformed or built upon. (<https://creativecommons.org/licenses/by-nc-nd/4.0/>)

Thieme Medical and Scientific Publishers Pvt. Ltd., A-12, 2nd Floor, Sector 2, Noida-201301 UP, India

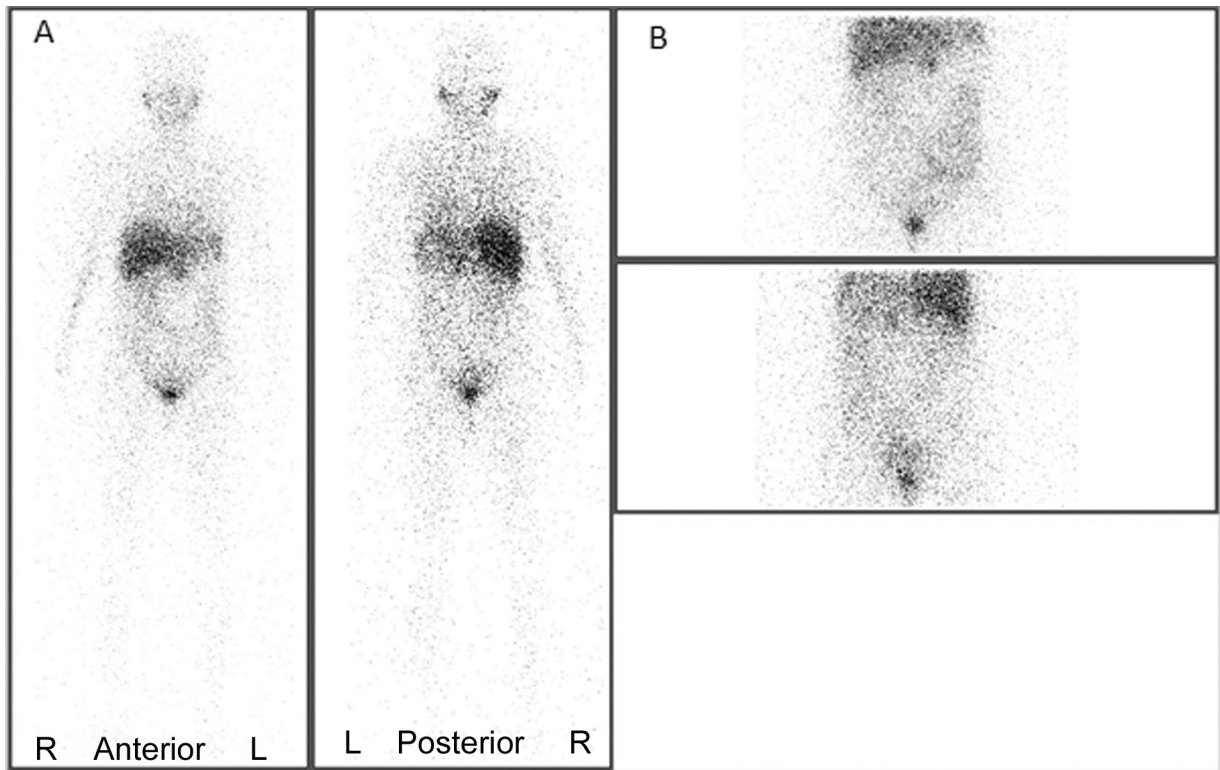


Fig. 1 ^{131}I MIBG Scintigraphy reveal discrete MIBG avid lesion, in the urinary bladder region. (A) Whole body images in anterior and posterior views. (B) Spot images of abdomen acquired at 48 hours, postinjection. Focal tracer activity seen in epigastric region is due to physiological uptake in enlarged left hepatic lobe.

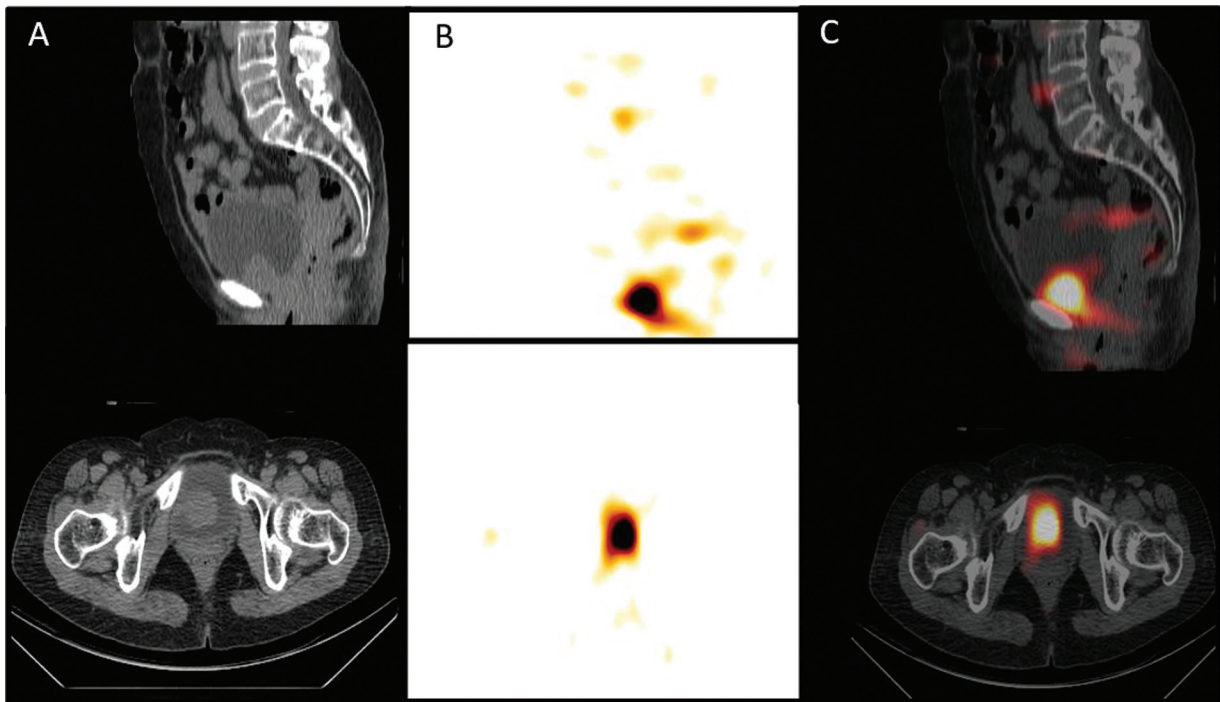


Fig. 2 Iodine-131 meta-iodobenzylguanidine single-photon emission computed tomography (^{131}I MIBG SPECT/CT) images of pelvis showing MIBG avid discrete, soft tissue density intraluminal exophytic mass lesion arising from right lateral wall, near the neck of urinary bladder and extending into bladder lumen, measuring 4.1×3.4 cm in size. Marked clearance of background tracer activity seen in the urinary bladder at 48 hours. (A) Sagittal and axial section CT images, (B) functional images, and (C) fused SPECT/CT images.

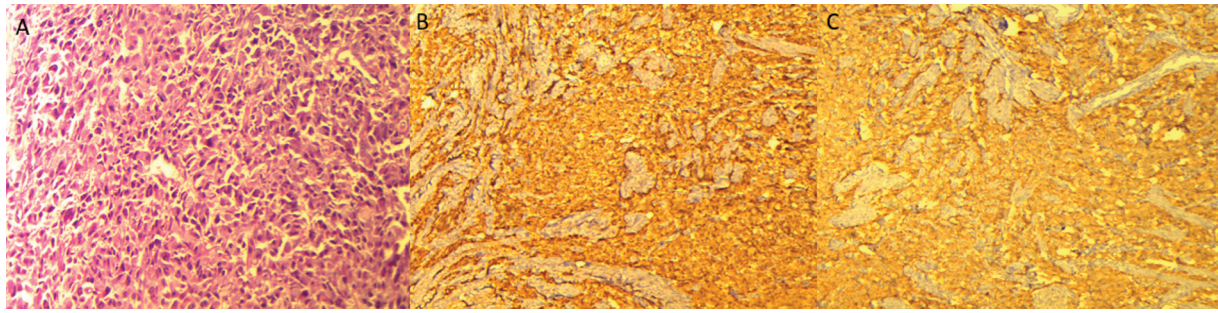


Fig. 3 Histopathological examination of biopsy specimen (A) hematoxylin and eosin stain (20 \times), showing large polygonal to spindle shaped cells arranged in Zellballen pattern with (B) chromogranin A and (C) synaptophysin, positivity on immunohistochemistry, suggestive of paraganglioma.

endocrinopathy or dermatopathy on clinical evaluation to suggest familial or syndromic etiology.

Following initial evaluation, the patient underwent robotic-assisted resection of vesical PGL. Postoperative histopathological report confirmed the diagnosis of well-differentiated PGL. Immunohistochemistry (IHC) markers including chromogranin A, synaptophysin, and S-100 were positive, while cytokeratin 7 and 20 was negative (**Fig. 3**). On clinical follow-up, patient's symptoms were relieved and there was no other complaint, up to 1.5 years postresection.

Discussion

Urinary bladder PGLs are rare tumors, arise from chromaffin tissue of the sympathetic nervous system within the layers of the bladder wall and constitute approximately 0.06% of all bladder tumors.^{1,3-7} Bladder PGL occur most commonly in second to fourth decade of life, are more common in females than males (3:1).^{1,5} These may be sporadic or associated with germline mutations. Up to 50% are known to be associated with germline mutations such as VHL, MEN2, NF1, RET, SDH; these patients are ideal candidates for genetic counseling and family screening.²

Most of the bladder PGLs are functional tumors and present with symptoms of sympathetic excess such as hypertension, palpitation, headache, and syncope. Symptoms of sympathetic excess characteristically occur during micturition, hence called as micturition crisis,³ which is due to compression of tumor during micturition. These symptoms can also be seen with defecation, sexual activity, or bladder instrumentation. About 17% of nonfunctional tumors may present incidentally or with symptoms such as hematuria, features of lower urinary tract symptom such as frequency, urgency, and obstruction of outflow tract, if present at the neck of the bladder.¹ Hematuria is most common presentation and occurs in approximately 50 to 60% of patients overall.¹

Bladder PGLs are usually well-defined, solid, ovoid, vascular lesion located in submucosa with 10% having peripheral calcification. On ultrasonography, these appear as echogenic masses with Doppler showing hypervascularity with low impedance flow. CT usually reveal nonspecific features such as soft tissue attenuation with homogenous enhancement.^{8,9} MRI constitutes the most sensitive modality for diagnosis but

is less specific. T1-weighted images show minimal hyperintensity compared with muscle, but it is slightly hyperintense on T2W images and characteristically show salt and pepper appearance.^{6,8,9}

MIBG is a guanethidine analogue functionally similar to noradrenaline, transported into cells by reuptake pathway of adrenergic presynaptic neurons; within the cells MIBG is transported into catecholamine storing granules and it is not metabolized.¹⁰ Functional imaging with radioiodine labeled MIBG is not only highly specific for diagnosis of PGL but also helps in localization of metastasis. SPECT/CT further increases its diagnostic value.⁷ MIBG can be labeled with both ^{123}I and ^{131}I . ^{123}I is better suited for imaging due to 159 keV gamma emission, while ^{131}I is a theragnostic agent with both β and high energy of 364 keV gamma emissions. But ^{123}I is not available in India; hence, ^{131}I MIBG is commonly used.

However, most of neuroendocrine neoplasias (NENs) express somatostatin receptors (SSTR), which can be used as targets for radionuclide imaging and therapy. Kroiss et al reported that ^{68}Ga -DOTA PET/CT targeting the SSTR of NEN has superior performance to ^{123}I MIBG-SPECT/CT in diagnosis and staging of pheochromocytoma and PGL.¹¹ Although all PGL may not show SSTR positivity, it can be missed on SSTR scan. Most recent publications by Parra et al and Kroiss et al have also reported lack of SSTR expression in urinary bladder PGL on ^{68}Ga -DOTATOC scan and proposed that ^{131}I MIBG may be more specific in urinary bladder PGL.^{12,13} PET/CT imaging with ^{18}F -DOPA is currently the preferred functional modality for diagnosing abdominal and pelvic PGL.¹⁴ However, ^{131}I MIBG SPECT/CT remains an indispensable tool for tumor characterization of NET at centers, where PET facility is not available.

Bladder PGLs are difficult to distinguish from other bladder tumors on imaging² thus, its diagnosis should be confirmed with histopathological examination and IHC. Histologically, they show Zellballen pattern, where tumor cells are arranged in nests, and have fibrovascular stroma and eosinophilic cytoplasm, which can also mimic high-grade urothelial carcinoma. In these tumors, if IHC is positive for neuron-specific enolase, chromogranin A, and synaptophysin but negative for cytokeratin, it confirms the diagnosis.^{3,4,15}

For localized tumors, surgical resection is treatment of choice. Complete removal of tumor is confirmed by normalization of 24-hour urinary catecholamine levels

done postsurgery.^{2,8} Bladder PGLs are mostly benign and approximately 10 to 20% can be malignant. High-risk features for malignant lesion include mitotic rate more than 3/30 high-power field, capsular invasion, large nest with central degeneration, spindle cell pattern, and positive SDHB mutation. For metastatic disease, complete cystectomy with pelvic lymph node dissection with or without chemoradiotherapy is the preferred treatment.^{2,4}

Conclusion

Bladder PGLs are very rare tumors, which can mimic urothelial neoplasms on cystoscopy, imaging, and histopathological examination. For optimal management of these tumors, and to avoid surgical misadventure due to erroneous diagnosis as urothelial neoplasm, a high clinical suspicion on laboratory findings and histopathology along with IHC evaluation are important. Conventional functional radionuclide imaging technique with ¹³¹I MIBG SPECT/CT has indispensable role not only in initial lesion characterization of urinary PGL as it has high positivity rate on MIBG, but it is also useful for follow-up of PGL, as it may have high recurrence rate.

Funding

None.

Conflict of Interest

None declared.

Authors' Contribution

M.L.N. contributed to the concept, design, definition of intellectual content, literature research, clinical studies, data acquisition, and manuscript preparation, editing, and review. T.S. contributed to the clinical studies. P.S., T.S., and H.V. contributed to the design, definition of intellectual content, literature research, data acquisition, and manuscript preparation, editing, and review. T.S. and M. L.N. are both guarantors for this paper.

References

- Priyadarshi V, Pal DK. Paraganglioma of urinary bladder. *Urol Ann* 2015;7(03):402–404. Available at: <https://www.urologyannals.com/article.asp?issn=0974-7796;year=2015;volume=7;issue=3;spage=402;epage=404;aulast=Priyadarshi>
- Ranaweera M, Chung E. Bladder paraganglioma: a report of case series and critical review of current literature. *World J Clin Cases* 2014;2(10):591–595
- Menon S, Goyal P, Suryawanshi P, et al. Paraganglioma of the urinary bladder: a clinicopathologic spectrum of a series of 14 cases emphasizing diagnostic dilemmas. *Indian J Pathol Microbiol* 2014;57(01):19–23. Available at: <http://www.ijpmonline.org/text.asp?2014/57/1/19/130873>
- Malignant paraganglioma of the urinary bladder in a 45-year-old woman - PubMed [Internet]. [cited 2021 Mar 1]. Accessed May 29, 2022, from: <https://pubmed.ncbi.nlm.nih.gov/23271358/>
- Chang YK, Chiang IN, Chen CH, et al. Paragangliomas of the urinary bladder: a report of 6 cases and review of the literature. *Urol Sci* 2015;26(02):111–114
- Iwamoto G, Kawahara T, Tanabe M, Ninomiya S, Takamoto D, Mochizuki T, et al. Paraganglioma in the bladder: A case report. *J Med Case Rep* [Internet]. 2017; 11(1). Available at: </pmc/articles/PMC5663097/?report=abstract>.
- Bosserman AJ, Dai D, Lu Y. Imaging characteristics of a bladder wall paraganglioma. *Clin Nucl Med* 2019;44(01):66–67. Available at: <https://journals.lww.com/00003072-201901000-00019>
- Article - Urinary bladder paraganglioma [Internet]. [cited 2020 Aug 9]. Accessed May 29, 2022 from: <https://www.appliedradiology.com/Communities/Artificial-Intelligence/urinary-bladder-paraganglioma>
- Haaga JR, Boll D. CT and MRI of the whole body. 6th ed. Philadelphia. PA: Elsevier - Health Sciences Division 2016;1:638
- Elgazzar AH, ed. The pathophysiologic basis of nuclear medicine. 3rd ed. Cham, Switzerland: Springer International Publishing;2014:61
- Kroiss A, Shulkin BL, Uprimny C, et al. (68)Ga-DOTATOC PET/CT provides accurate tumour extent in patients with extraadrenal paraganglioma compared to (123)I-MIBG SPECT/CT. *Eur J Nucl Med Mol Imaging* 2015;42(01):33–41. Available at: <https://link.springer.com/article/10.1007/s00259-014-2892-6>
- Parra LA, Swanson SK, Salomao MA, Yang M. Multifocal urinary bladder paragangliomas with negative 68Ga-DOTATATE uptake and positive 123I-MIBG uptake. *Clin Nucl Med* 2020;45(03):e156–e157
- Kroiss AS, Uprimny C, Pichler R, Gasser RW, Virgolini IJ. A rare case of a ¹²³I-MIBG SPECT/CT positive, but ⁶⁸Ga-DOTA-TOC PET/CT negative pheochromocytoma of the bladder. *Rev Esp Med Nucl Imagen Mol (Engl Ed)* 2018;37(05):315–317. Available at: <https://pubmed.ncbi.nlm.nih.gov/30042056/>
- Kuzminski SJ, Sosa JA, Hoang JK. Update in parathyroid imaging. *Magn Reson Imaging Clin N Am* 2018;26(01):151–166
- India E, Kumar VA. Robbins and Cotran Pathologic Basis of Disease: South Asia Edition [Internet]. Elsevier India; 2014. Available at: <https://books.google.co.in/books?id=ee7urQEACAAJ>