

Postnatal management of bilateral Grade 3–4 ureteropelvic junction obstruction

Ramesh Babu*, Ashay Rajnikant Suryawanshi, Utsav Shailesh Shah, Ashitha K. Unny

Department of Pediatric Urology, Sri Ramachandra Institute of Higher Education and Research, Chennai, Tamil Nadu, India

*E-mail: drrameshbabu1@gmail.com

ABSTRACT

Introduction: Bilateral hydronephrosis on prenatal ultrasound can be managed expectantly or with surgical intervention. The treatment strategies and outcomes are not clearly defined.

Methods: We conducted a retrospectively audit of outcomes of management of prenatally detected severe bilateral ureteropelvic junction obstruction (UPJO) in our institution. Patients with bilateral Grade 3–4 hydronephrosis were included. Those with complications like rupture, underwent bilateral intervention within 4 weeks; in the remaining, unilateral pyeloplasty was performed at 4–12 weeks. The contralateral renal unit was re-evaluated at a later date for further improvement or deterioration. All the patients were followed up with ultrasonography and renogram at 3 months, 6 months, and 1-year post operatively. The case records were analyzed for the resolution of antero-posterior diameter (APD) or the improvement in single-kidney glomerular filtration rate (s-GFR) in the operated units.

Results: Over 15 years, 28 patients (56 renal units) had bilateral UPJO (male-to-female ratio = 13:1). Twelve units underwent neonatal intervention to tackle the complications (6 bilateral pyeloplasty), 17 units underwent early pyeloplasty, and 15 underwent late pyeloplasty. Twelve of the twenty-two (54%) contralateral units, which were stented/observed, resolved spontaneously. Receiver operating characteristics analysis revealed that those with initial APD <25 mm and initial s-GFR >35 ml/m were more likely to improve during the observation. Ten of the forty-four operated units (22%) failed to show an improvement. Units with initial s-GFR <10 ml/m had poor chance of postoperative functional recovery.

Conclusions: In neonates with bilateral UPJO, the worse affected kidney is operated first, as it still has the potential to recover. The contralateral milder UPJO unit is known to recover spontaneously following unilateral pyeloplasty. In those with bilateral Grade 4 UPJO and mass, bilateral pyeloplasty is feasible. Alternatively, unilateral pyeloplasty + contralateral cystoscopic retrograde stenting may prevent rupture or functional deterioration in the opposite kidney.

INTRODUCTION

With the advent of routine antenatal ultrasonography, the incidence of fetal hydronephrosis has increased many folds.^[1-3] While a majority of these are transient, ureteropelvic junction obstruction (UPJO) is a common cause in those with persistent hydronephrosis.^[3,4] In the vast majority of the patients with unilateral UPJO, the initial management is conservative with the surgical intervention being reserved for those with a significant deterioration in the differential renal function (DRF) on the follow-up.^[5-8] In 2%–5%

of the cases, UPJO is bilateral and as of today, there is no fixed protocol for neonatal management of bilateral severe UPJO diagnosed antenatally.

Even in cases with bilateral UPJO, pyeloplasty on one side may lead to recovery of the contralateral less affected kidney on serial follow-ups.^[9-13] However, controversy and disagreement exist among the authors about the management protocols in those with bilateral severe UPJO. We retrospectively audited our single-center experience

Access this article online	
Quick Response Code:	Website: www.indianjurol.com
	DOI: 10.4103/iju.IJU_231_20

This is an open access journal, and articles are distributed under the terms of the Creative Commons Attribution-NonCommercial-ShareAlike 4.0 License, which allows others to remix, tweak, and build upon the work non-commercially, as long as appropriate credit is given and the new creations are licensed under the identical terms.

For reprints contact: reprints@medknow.com

Received: 30.04.2020, **Revised:** 29.06.2020

Accepted: 06.08.2020, **Published:** 01.10.2020

Financial support and sponsorship: Nil.

Conflicts of interest: There are no conflicts of interest.

of managing prenatally detected severe bilateral UPJO and report herewith the outcomes with a view to discuss a pragmatic management for this uncommon situation.

MATERIALS AND METHODS

This retrospective audit was performed by analyzing the records of patients managed over a period of 15 years (January 2004 to December 2018). Among the patients with antenatally diagnosed hydronephrosis, those with Grade 3–4 Society of Fetal Urology (SFU) grade^[8] hydronephrosis on postnatal ultrasound at 48–72 h of birth were included. Those with unilateral Grade 3–4 and contralateral Grade 1–2 hydronephrosis were not included in the study. All patients underwent voiding cystourethrogram (VCUG) in the neonatal period to identify associated vesicoureteric reflux (VUR) and exclude a posterior urethral valve (PUV). Within 4 weeks after birth, the ultrasonography was repeated for reassessment of hydronephrosis with a particular view to measure the renal anteroposterior diameter (APD) and the progression of SFU grade. The radiologist reported presence or absence of parenchymal thinning to report Grade 4 SFU grade (parenchymal measurements were not uniformly reported or analyzed). A well-tempered diuretic renogram, ^{99m}Tc-diethylenetriaminepentaacetic acid (^{99m}Tc-DTPA) renal scan with an indwelling urinary catheter to prevent reflux, using the standard intravenous furosemide protocol was performed,^[14] for evaluating the function and diuretic drainage characteristics. Since the DRF may have been influenced by the bilateral disease, single-kidney glomerular filtration rate (s-GFR) was used to compare pre- and post-operative outcomes.

Patients with bilateral Grade 4 hydronephrosis and complications such as rupture, respiratory distress due to large mass, or sepsis underwent bilateral intervention in the form of percutaneous nephrostomy (using 6 F pigtail catheter insertion under ultrasound guidance for a week to stabilize)/pyeloplasty/contralateral double J [DJ] stenting). For bilateral pyeloplasty, the patient was kept supine and an anterior transverse extraperitoneal approach was used, with only the surgeon changing sides. In all the bilateral pyeloplasties, antegrade DJ stenting + nephrostomy was performed during the procedure; the nephrostomy was removed before discharge while the stent was removed after 4–6 weeks. When a contralateral cystoscopy/retrograde stenting was possible, unilateral pyeloplasty was performed at <4 weeks, and stent removal + contralateral pyeloplasty was performed together at 8–12 weeks. Table 1 describes the exact course of management.

In patients with uncomplicated but bilateral Grade 4 hydronephrosis, unilateral pyeloplasty plus contralateral retrograde stenting was performed at 4–8 weeks of age. The contralateral stenting was essentially performed due to a fear of rupture or loss of function during the waiting period.

Stent removal and an immediate contralateral reevaluation with a renogram were performed after 4 weeks. If there was no improvement in the contralateral unit, a contralateral pyeloplasty was performed at 12–16 weeks to prevent an imminent rupture or functional deterioration [Table 1].

In those with one side Grade 4 and contralateral Grade 3 UPJO, unilateral open pyeloplasty was performed on the worse side at 8–12 weeks of age. The stent was removed after a period of 4 weeks. The contralateral renal unit was simply evaluated later for further improvement or deterioration. On the nonoperated units, a 10% worsening of APD or s-GFR prompted pyeloplasty sooner or later. Neonates and infants underwent standard open dismembered pyeloplasty (supine position/anterior extraperitoneal approach) with a reduction of the pelvis using 6-0 Vicryl by the same surgeon (RB). In neonates, a 2.5/3 F DJ stent of 10 cm length was used, while in older children, a 3 F and 12–14 cm stent was used. We did not encounter any difficulty in antegrade stenting during pyeloplasty. Prompt input/output chart was maintained to manage the postoperative diuresis. Fluid balance and serum electrolytes were monitored and replaced if required in the immediate postoperative period. All the patients were followed up with ultrasonography and renogram at 3 and 6 months and 1-year follow-up.

Those with a late deterioration during the follow-up (age: 1–3 years) underwent a laparoscopic transperitoneal dismembered pyeloplasty. The case records were analyzed for the resolution of APD or an improvement in s-GFR in the operated units. An improvement by 10% in the APD or the s-GFR during the postoperative follow-up was considered as a successful outcome. Medians of two different groups were compared by the Kruskal–Wallis H-test when comparing more than three groups. Receiver operating characteristics (ROC) analysis was performed to identify the cutoff values of initial APD and s-GFR for success/failure.

Statistical analysis was performed using the Statistical Package for the Social Sciences, version 12.0 (SPSS, Chicago, IL, USA), and a probability of <0.05 was considered statistically significant. The retrospective audit was approved by The Institutional Ethics Committee (CSP-MED/17/NOV/40/146). Informed consent was not required as this was a noninterventional retrospective study and patient confidentiality was maintained as per the ethical guidelines by the Declaration of Helsinki and its amendments.

RESULTS

Over a period of 15 years, 1410 patients were referred with antenatal hydronephrosis. Of these, 224 (15%) patients were diagnosed with UPJO. Twenty-eight patients (56 renal units) had bilateral Grade 3–4 hydronephrosis (male-to-female ratio = 13:1), which amounted to 2% of all the ANH. Among those included, 8/28 patients (28%) had associated VUR

Table 1: Presentations, management, and outcome of antenatally diagnosed bilateral ureteropelvic junction obstruction

Total (28 patients) (n=56 units)	Initial presentation	Initial management	Further management	Later management	Total operated units	APD (mm), median (IQR)		s-GFR (ml/mt), median (IQR)		Contralateral units that improved after unilateral pyeloplasty (%)	Units failed to improve post pyeloplasty at long term follow-up (%)
						Initial	At 1 year follow-up	Initial	At 1 year follow-up		
Complicated Bilateral Grade 4 UPJO mass palpable (6 patients) (n=12 units)	Rupture during delivery (n=1) Respiratory distress due to mass (n=2) Urinary infection (n=3)	Initial bilateral nephrostomy IV antibiotics	Bilateral pyeloplasty <4 weeks of age (n=6 units) Unilateral pyeloplasty at <4 weeks of age + contralateral stenting (n=3 units)	Bilateral stent removal Stent removal and contra lateral pyeloplasty at 8-12 weeks (n=3 units)	n=12	63.5 (60-65)	33.5 (30-34)	23.0 (17-24)	28.5 (25-30)	0	4/12 (33.3)
Uncomplicated Bilateral Grade 4 UPJO (10 patients) (n=20 units)	Hydronephrosis on postnatal USG	Unilateral pyeloplasty at 4-8 weeks of age + stenting of contralateral unit* (n=10 units)	Stent removal and immediate re-evaluation of contra lateral side after 4 weeks 3 improved 7 worsened	Contra lateral pyeloplasty at 12-16 weeks of age (n=7 units)	n=17	53.0 (50-54)	31.0 (28-33)	32.0 (19-33)	40.5 (38-44)	3/10 (30)	3/17 (17.6)
Bilateral UPJO Grade 4 one side Grade 3 opposite side (12 patients) (n=24 units)	Hydronephrosis on postnatal USG	Unilateral pyeloplasty on worse side at 8-12 weeks age (n=12 units)	Milder side simply observed: 9 improved; 3 worsened	Contra lateral pyeloplasty at 1-3 years (n=3 units)	n=15	46.0 (45-48)	27.5 (26-29)	33.5 (29-36)	44.5 (42-46)	9/12 (75)	3/15 (20)
Outcomes in those who improved without pyeloplasty Outcomes in those who failed to improve postpyeloplasty at long term follow-up						24.0 (23-28) 62.5 (54-64)	13.5 (11-16) 38.0 (35-39)	40.5 (38-42) 10.5 (9-11)	46.0 (44-48) 11.0 (9-13)	12/22 (54.5)	10/44 (22.7)

*The contralateral stenting was essentially due to a fear of rupture or loss of function during the waiting period. APD = Anteroposterior diameter, UPJO = Ureteropelvic junction obstruction, USG = Ultrasonography, IV = Intravenous, s-GFR = Single-kidney glomerular filtration rate, IQR = Interquartile range

(3 unilateral Grade II; 3 bilateral Grade III, and 2 bilateral Grade IV). Among these, seven of the eight resolved on conservative treatment with antibiotic prophylaxis over a period of 1–2 years; one with bilateral Grade IV VUR warranted a late reimplantation due to recurrent urinary infections. Despite bilateral UPJO, the serum creatinine was within the normal range for their age group in all the patients. Table 1 summarizes the presentations of UPJO and their respective management.

In six patients, gross hydronephrosis with complications warranted evaluation and intervention in the neonatal period. Three patients underwent bilateral ultrasound-guided nephrostomy (6 F pigtail catheter) followed by bilateral open pyeloplasty ($n = 6$ units); one patient had sustained a rupture in the renal pelvis during the delivery with a urinoma formation, confirmed on the magnetic resonance imaging scan [Figure 1]; and two patients had respiratory distress due to bilateral large masses. Postoperative diuresis and minor electrolyte disturbances (encountered in 6 patients) were tackled with appropriate replacement. No major untoward incidents were encountered. In three patients, cystoscopic stenting could be performed on one side ($n = 3$ units); hence, unilateral pyeloplasty ($n = 3$ units) was performed on the other side.

In 10 patients with bilateral Grade 4 hydronephrosis, unilateral open pyeloplasty ($n = 10$ units) with contralateral stenting ($n = 10$ units) was performed at 4–8 weeks of age. Among the 10 contralateral units re-evaluated following stent removal, 3 units (30%) improved, while 7 worsened to warrant a contralateral pyeloplasty [Table 1].

In 12 patients, there was unilateral Grade 4 hydronephrosis with contralateral Grade 3 hydronephrosis. Only the worse side ($n = 12$ units) underwent open pyeloplasty at 8–12 weeks of age, while the sides with Grade 3 hydronephrosis ($n = 12$

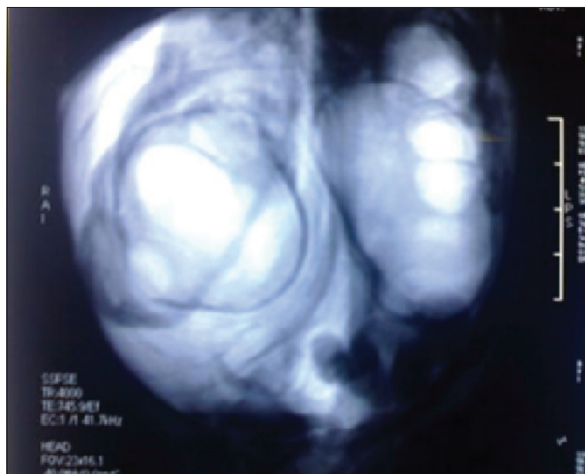


Figure 1: Magnetic resonance urogram showing urinoma in a patient with bilateral uretero pelvic junction obstruction which ruptured during delivery. Neonatal intervention was bilateral nephrostomy followed by pyeloplasty

units) were simply observed without stenting. Among the 12 units followed up, 9 units improved, while in three, there was a worsening of the APD or s-GFR during the follow-up warranting a late laparoscopic pyeloplasty (age range: 1–3 years). Table 1 summarizes the outcomes of all the three groups.

Twelve units with bilateral UPJO did not warrant pyeloplasty in this series. This amounts to 12/22 (54%) units which were stented/electively observed for resolution. Figure 2 compares the initial APD and s-GFR outcomes between the three operated groups and those which improved spontaneously. The median initial APD was significantly shorter at 24.0 (+/-4.5) mm, while the median initial s-GFR was significantly higher at 40.5 (+/-3.25) ml/mt in the units that recovered spontaneously (Kruskal–Wallis test) as compared to the first three groups that underwent surgery ($P = 0.01$). ROC analysis of all the observed units ($n = 22$) revealed that those with an initial APD < 25 mm (sensitivity 75%; specificity 92%) and an initial s-GFR > 35 ml/mt (sensitivity 80%; specificity 80%) were more likely to improve with observation [Figure 3].

Considering a 10% improvement in s-GFR/APD as a good improvement, outcomes among the operated units ($n = 44$)

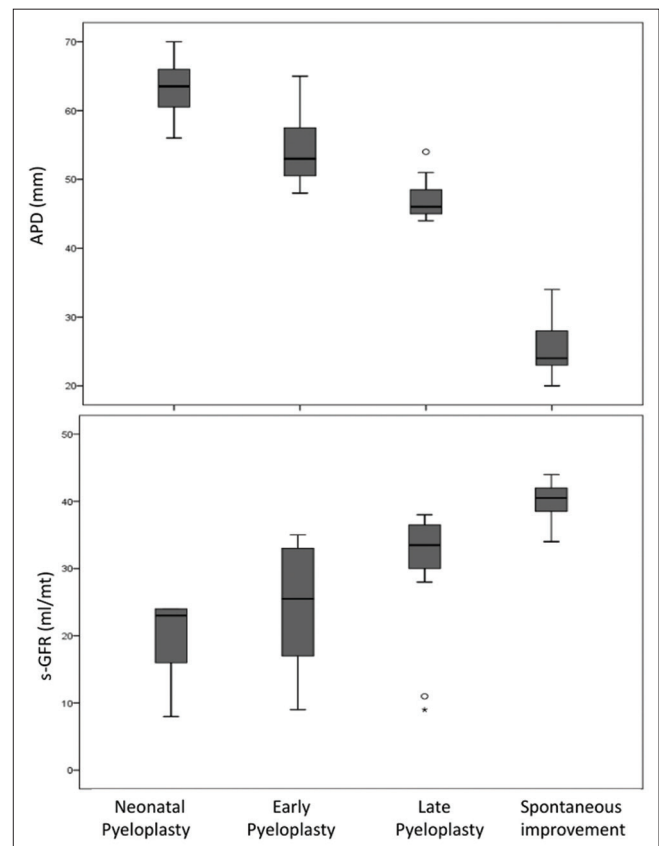


Figure 2: The median initial anteroposterior diameter was significantly shorter at 24.0 mm and the initial single kidney glomerular filtration rate significantly higher at 40.5 ml/m in the units that recovered spontaneously (last box plot). The difference was significant (Kruskal–Wallis test) between last group and the first three groups ($P = 0.01$)

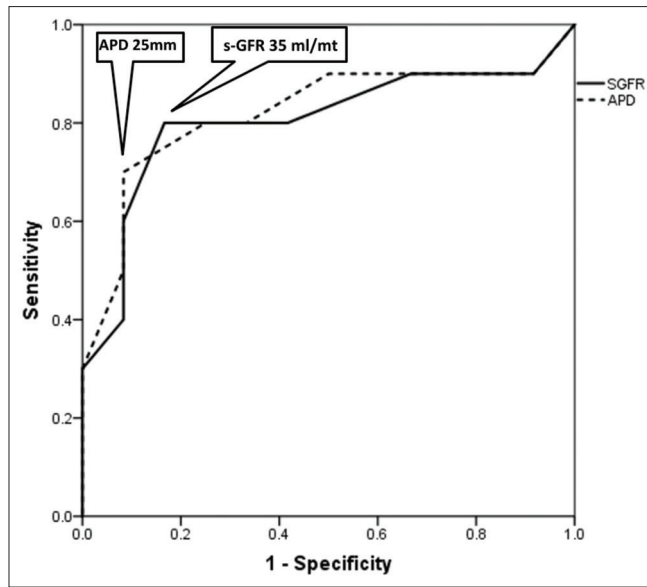


Figure 3: Receiver operating characteristics analysis of all the observed units ($n = 22$): Those with initial anteroposterior diameter <25 mm and initial single kidney glomerular filtration rate >35 ml/mt were more likely to improve with observation

were compared. Overall, 10/44 operated units (22%) failed to show an improvement. Two of the ten were symptomatic (pain) and underwent redo-pyeloplasty. The remaining patients are under follow up, as they are asymptomatic. ROC analysis of all the operated units ($n = 44$) revealed that the units with initial s-GFR <10 ml/mt (sensitivity: 88% and specificity: 80%) had a poor chance of postoperative functional recovery.

DISCUSSION

UPJO is the most common cause of hydronephrosis detected antenatally.^[1-8,14] There are very few reports on the optimal mode of treatment of antenatally detected bilateral UPJO with regard to the timing of pyeloplasty.^[9-12] Irrespective of the initial DRF, early pyeloplasty in prenatally diagnosed unilateral SFU Grade 3–4 UPJO has been shown to result in a significant improvement of DRF, while delayed pyeloplasty is reported to result in a marginal but significant loss.^[7] In those with bilateral UPJO, DRF is unable to help in the surgical decision making process^[9,14] and the loss of function is likely to go undetected for a long time. In this study, we have reported our single-center experience of management of bilateral Grade 3–4 UPJO detected antenatally.

Renogram

While the renogram in the neonates can be difficult to interpret due to poor renal maturity, Gordon^[14] supported its use in the early neonatal period in exceptional situations like bilateral UPJO. Josephson *et al.*^[9] used s-GFR as the parameter in their study on bilateral UPJO, as the DRF becomes meaningless when both kidneys are involved. In the present study also, we used s-GFR as a marker of

recovery in those managed conservatively. We found that units with initial s-GFR <10 ml/m had a poor chance of postoperative functional recovery. This information can be used to warn the patients during counseling. Contralateral units with initial s-GFR >35 ml/mt were more likely to improve spontaneously and are possible candidates for observation.

Anteroposterior diameter

Renal APD has been shown to be a useful parameter to define the severity of hydronephrosis.^[9-12] Jiang *et al.*^[11] reported that contralateral units with an APD of ≥ 20 mm and a calyceal diameter of >10 mm were more likely to require surgery during observation. In our study, we found that contralateral units with an APD of <25 mm were more likely to improve with observation. However, these children still need a close follow-up to detect late deterioration.

Bilateral pyeloplasty

In neonates with Grade 4 UPJO and palpable mass, there is a huge parental anxiety regarding rupture while handling the child. In many studies, the contralateral unit had an SFU Grade 3 or less hydronephrosis, a mild form that does not warrant an urgent surgery.^[13] However, when both the units have gross hydronephrosis, some authors have advocated bilateral pyeloplasty. Eckstein and Drake reported the feasibility of concurrent bilateral open pyeloplasty,^[15] and Schwab and Casale performed successful concurrent bilateral laparoscopic pyeloplasties with favorable results.^[16] In our study, three patients warranted bilateral pyeloplasty in the neonatal period in view of rupture/respiratory distress due to the mass effect. In all these units, a nephrostomy tube was placed prior to the surgery to stabilize the patient.

The role of contralateral stenting

While the bilateral pyeloplasty is feasible in this era, a unilateral pyeloplasty with contralateral stenting can be performed in those with uncomplicated severe bilateral Grade 4 UPJO. It may theoretically prevent deterioration of the un-operated unit, may help some units to recover without surgery, and may be adopted when there is a concern regarding an impending rupture. One however has to warn the parents that UPJO is an adynamic narrow segment and a stent can be passed across. Therefore, stenting alone may not cure the problem and UPJO may re-manifest poststent removal, warranting a surgery at a later date. Nasser *et al.*^[17] advocated external Nephrostent for pyeloplasties, while the authors prefer an internal DJ stent, as it can be kept for a longer period than a Nephrostent and handling of the baby is easier for the parents.

Spontaneous recovery of contralateral units

The resolution of hydronephrosis in the contralateral kidney, following unilateral pyeloplasty in bilateral UPJO, was reported by Kim *et al.* and Jiang *et al.*^[11,12] Recovery due to a reduction in hyperfiltration is one of the possible

theories of this phenomenon. In our study, if Grade 4 hydronephrosis was seen in contralateral unit, 3/10 (30%) improved, while if Grade 3 hydronephrosis was seen, 9/12 (75%) improved. This is similar to that reported by Bajpai and Chandrasekharam.^[13] We found that contralateral units with initial s-GFR >35 ml/mt were more likely to improve spontaneously.

The role of voiding cystourethrogram in those with ureteropelvic junction obstruction

The role of VCUG in asymptomatic unilateral isolated prenatally diagnosed UPJO is questionable and several authors have not favored performing a VCUG to identify concomitant VUR, reserving it only for children presenting with UTI.^[18] However, in children with antenatally diagnosed bilateral hydronephrosis, a VCUG becomes mandatory to exclude bladder outlet obstruction in the form of PUV.^[19]

Although our study has limitations due to small numbers, this is still one of the largest series reported so far on this rare problem of bilateral UPJO. Further limitations could be inter-observer variation of APD measurement

by ultrasonography during the follow-up. We have not measured and analyzed paranchymal thickness in all the patients, as it was not uniformly measured and reported by the radiologist. MAG3 renogram has been shown to be superior in the assessment of neonatal renal function because of its better extraction. We have used ^{99m}Tc-DTPA renogram in this group, particularly because it offered s-GFR, which is more useful predictor in bilateral UPJO. Despite these limitations, the findings from this study could be useful for surgeons who deal with antenatally diagnosed bilateral UPJO. Figure 4 depicts the management protocol proposed by the authors for neonates with bilateral UPJO.

CONCLUSIONS

In an asymptomatic neonate with antenatally diagnosed bilateral UPJO, the worse affected kidney is operated first, as it still has the potential of recovery. The contralateral milder UPJO unit has been shown to recover spontaneously following unilateral pyeloplasty in this and previous studies. In those with bilateral Grade 4 UPJO and mass, bilateral pyeloplasty is feasible. Alternatively, unilateral pyeloplasty/

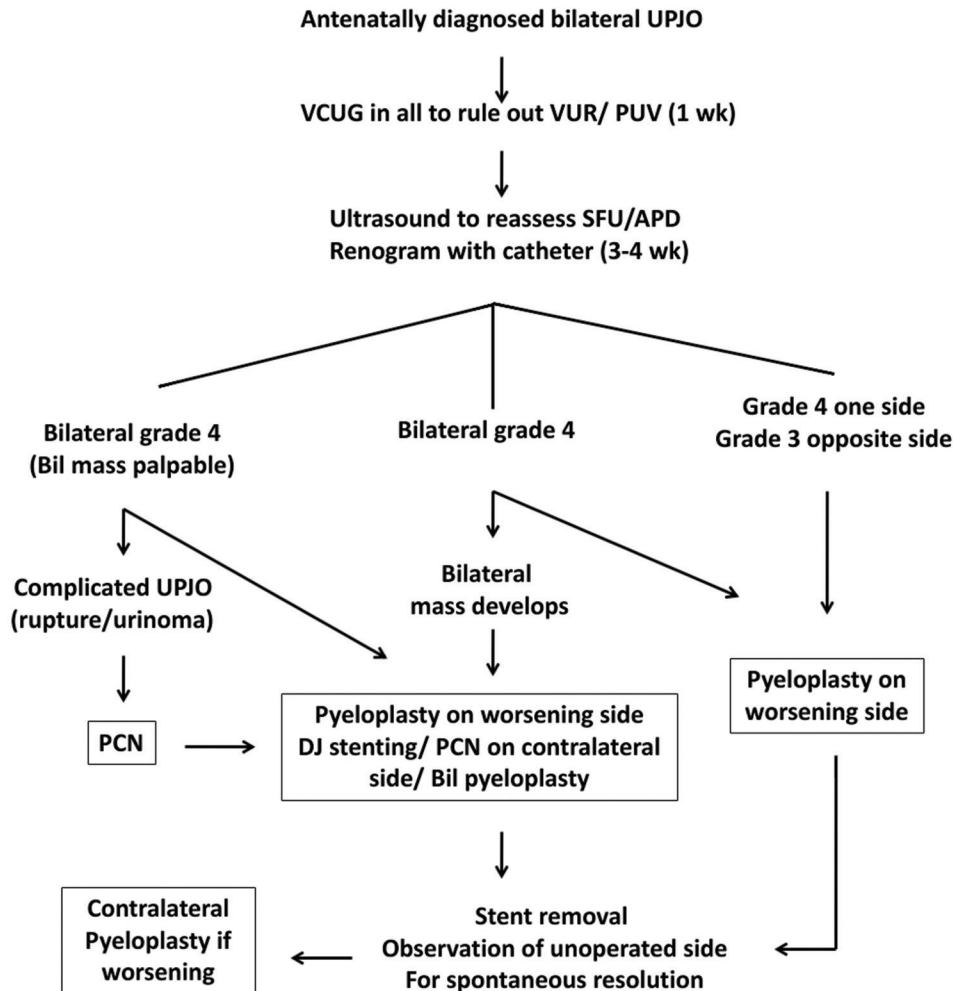


Figure 4: Management protocol for antenatally diagnosed bilateral uretero pelvic junction obstruction

cystoscopic retrograde stenting of the contra lateral side may safeguard the contralateral unit from rupture or renal function deterioration during the waiting period.

REFERENCES

1. Woodward M, Frank D. Postnatal management of antenatal hydronephrosis. *BJU Int* 2002;89:149-56.
2. Kumar M, Gupta U, Thakur S, Aggrawal S, Meena J, Sharma S, *et al.* Prenatal sonographic evaluation and postnatal outcome of renal anomalies. *Indian J Hum Genet* 2012;18:75-82.
3. Damen-Elias HA, De Jong TP, Stigter RH, Visser GH, Stoutenbeek PH. Congenital renal tract anomalies: Outcome and follow-up of 402 cases detected antenatally between 1986 and 2001. *Ultrasound Obstet Gynecol* 2005;25:134-43.
4. Jiang D, Tang B, Xu M, Lin H, Jin L, He L, *et al.* Functional and Morphological Outcomes of Pyeloplasty at Different Ages in Prenatally Diagnosed Society of Fetal Urology Grades 3-4 Ureteropelvic Junction Obstruction: Is It Safe to Wait? *Urology* 2017;101:45-9.
5. Ransley PG, Dhillon HK, Gordon I, Duffy PG, Dillon MJ, Barratt TM. The postnatal management of hydronephrosis diagnosed by prenatal ultrasound. *J Urol* 1990;144:584-7.
6. Cartwright PC, Duckett JW, Keating MA, Snyder HM 3rd, Escala J, Blyth B, *et al.* Managing apparent ureteropelvic junction obstruction in the newborn. *J Urol* 1992;148:1224-8.
7. Babu R, Rathish VR, Sai V. Functional outcomes of early versus delayed pyeloplasty in prenatally diagnosed pelvi-ureteric junction obstruction. *J Pediatr Urol* 2015;11:63.e1-5.
8. Fernbach SK, Maizels M, Conway JJ. Ultrasound grading of hydronephrosis: Introduction to the system used by the Society for Fetal Urology. *Pediatr Radiol* 1993;23:478-80.
9. Josephson S, Dhillon HK, Ransley PG. Post-natal management of antenatally detected, bilateral hydronephrosis. *Urol Int* 1993;51:79-84.
10. Onen A, Jayanthi VR, Koff SA. Long-term followup of prenatally detected severe bilateral newborn hydronephrosis initially managed nonoperatively. *J Urol* 2002;168:1118-20.
11. Jiang D, Chen Z, Lin H, Xu M, Geng H. Predictive factors of contralateral operation after initial pyeloplasty in children with antenatally detected bilateral hydronephrosis due to ureteropelvic junction obstruction. *Urol Int* 2018;100:322-6.
12. Kim J, Hong S, Park CH, Park H, Kim KS. Management of severe bilateral ureteropelvic junction obstruction in neonates with prenatally diagnosed bilateral hydronephrosis. *Korean J Urol* 2010;51:653-6.
13. Bajpai M, Chandrasekharam VV. Nonoperative management of neonatal moderate to severe bilateral hydronephrosis. *J Urol* 2002;167:662-5.
14. Gordon I, Piepsz A, Sixt R, Auspices of Paediatric Committee of European Association of Nuclear Medicine. Guidelines for standard and diuretic renogram in children. *Eur J Nucl Med Mol Imaging* 2011;38:1175-88.
15. Eckstein HB, Drake DP. Simultaneous bilateral pyeloplasties. *Proc R Soc Med* 1976;69:664-5.
16. Schwab CW 2nd, Casale P. Bilateral dismembered laparoscopic pediatric pyeloplasty via a transperitoneal 4-port approach. *J Urol* 2005;174:1091-3.
17. Nasser FM, Shouman AM, ElSheemy MS, Lotfi MA, Aboulela W, El Ghoneimy M, *et al.* Dismembered pyeloplasty in infants 6 months old or younger with and without external trans-anastomotic nephrostent: A prospective randomized study. *Urology* 2017;101:38-44.
18. ElSheemy MS, Ghoneima W, Abdelwahhab M, Aboulela W, Daw K, Shouman AM, *et al.* The role of voiding cystourethrography in asymptomatic unilateral isolated ureteropelvic junction obstruction: A retrospective study. *J Pediatr Urol* 2017;13:206.e1-000000.
19. Sinha A, Bagga A, Krishna A, Bajpai M, Srinivas M, Uppal R, *et al.* Revised guidelines on management of antenatal hydronephrosis. *Indian J Nephrol* 2013;23:83-97.

How to cite this article: Babu R, Suryawanshi AR, Shah US, Unny AK. Postnatal management of bilateral Grade 3–4 ureteropelvic junction obstruction. *Indian J Urol* 2020;36:288-94.