

Bail-out unexpanded stent implantation in acute left main dissection treated with intra coronary lithotripsy: a case report

Gabriele Tumminello *, **Chiara Cavallino**, **Andrea Demarchi** , and **Francesco Rametta**

Division of Cardiology, S. Andrea Hospital, Corso Mario Abbiate 21, 13100 Vercelli, Italy

Received 8 April 2019; first decision 4 June 2019; accepted 12 September 2019; online publish-ahead-of-print 8 October 2019

Background

The percutaneous treatment of heavily calcified coronary lesions is challenging and presents high rate of complications. Unexpandable stent is one of the most serious complication. Both of these conditions may benefit from the intracoronary lithotripsy (ICL-Shockwave[®]), a new coronary percutaneous technique.

Case summary

This case report describes a man treated with percutaneous coronary intervention (PCI) for a left main (LM) severe calcified lesion. The PCI was complicated by a huge dissection of LM in a not completely expandable lesion. A bail-out stent implantation was performed with residual unexpansion. The ICL permitted to expand acutely the stent and obtain an optimal final result.

Discussion

Familiarity with dedicated techniques and devices to treat calcified coronary lesions is fundamental to perform high-risk complex PCI. This case emphasizes the potential usefulness of the new ICL technique to treat calcified lesions or related complications like unexpandable stent.

Keywords

Calcified lesion • Intracoronary lithotripsy PCI • Unexpandable stent • Case report

Learning points

- The correct percutaneous treatment of calcified coronary lesions expects the use of several dedicated techniques to prepare the lesion. One of the newest is intracoronary lithotripsy, a technique which selectively breaks the intimal and medial calcium within the vessel wall through the generation of sonic pressure waves. Calcium modulation permits to dilate the lesion at low pressure in order to maximize luminal gain and minimize trauma of the vessel wall.
- Intracoronary lithotripsy percutaneous coronary intervention is a useful technique to prepare a calcified lesion but has a wider application setting such as the treatment of a serious complication like unexpandable stent.

* Corresponding author. Tel: +39 3349256132, Email: tumminellogabriele@gmail.com

Handling Editor: Gabor G. Toth

Peer-reviewers: Kyriakos Dimitriadis, Rafael Vidal-Perez, and John Kanakakis

Compliance Editor: Mohammed Majid Akhtar

Supplementary Material Editor: Vishal Shahil Mehta

© The Author(s) 2019. Published by Oxford University Press on behalf of the European Society of Cardiology.

This is an Open Access article distributed under the terms of the Creative Commons Attribution Non-Commercial License (<http://creativecommons.org/licenses/by-nc/4.0/>), which permits non-commercial re-use, distribution, and reproduction in any medium, provided the original work is properly cited. For commercial re-use, please contact journals.permissions@oup.com

Introduction

The percutaneous treatment of coronary artery stenosis has a long and successful history but the treatment of heavily calcified lesions results in high rate of complications and long-term adverse events.^{1,2} Several tools and techniques with different kinds of mechanisms have been developed to facilitate the revascularization in this scenario: cutting and scoring balloon, super high pressure (OPN NC) balloon, and rotational atherectomy.³ A new promising technique is represented by intracoronary lithotripsy (ICL).^{4,5} Lithotripsy is a well-characterized treatment adopted for calcified renal calculi in which calcification are fragmented by high-power acoustic shockwaves. Intracoronary lithotripsy using a dedicated coronary balloon brings the same concept to high calcified coronary lesions. A common point of all these techniques is that they are designed to prepare the lesion and not to be applied after stent implantation.

We present the case of a patient with a very calcified lesion needed for bail-out stent implantation due to a huge dissection; ICL was successfully used to optimize stent's under expansion and percutaneous coronary intervention (PCI) final result.

Timeline

Timeline (hours after arrival)

Emergency Department (0)	Patient with hypertension, diabetes mellitus, hyperlipidaemia, obesity, active smoke, previous aortic bypass revascularization [left internal mammary artery—LIMA for left anterior descending (LAD), saphenous vein graft—SVG for right coronary artery (RCA) and SVG for intermediate ramus (IR) and obtuse marginal (OM)] presents with central chest pain and left arm numbness. Electrocardiogram reveals inferior ST-segment elevations in D2, D3, and aVR; Troponin-I elevated 0, 73 ng/mL. With concern to ST-myocardial infarction, he was taken for emergent cardiac catheterization.
Cardiac Catheterization Lab (1)	Coronary angiogram reveals critical stenosis of predivisional left main (LM), LAD with proximal critical stenosis and subsequent occlusion, left circumflex (LC) with critical mid stenosis and IR occluded; RCA occluded at mid-portion; LIMA for LAD without stenosis; SVG for IR and OM chronically occluded; SVG for RCA with thrombotic acute occlusion (culprit lesion). The SVG for RCA was treated with a direct implant of a drug everolimus-eluting stent with a good acute result. Revascularization of LM-LAD-LC was planned.

Continued

Continued

Timeline (hours after arrival)

Cardiac Catheterization Lab for planned revascularization (85)	A planned revascularization of LM, LAD, and LC was performed with a percutaneous coronary intervention (PCI) complicated by a huge dissection of LM needing a bail-out implant of a zotarolimus-eluting stent LM-LAD which remained unexpanded and was treated with the use of intracoronary lithotripsy. The procedure was finalized with PCI and implant of other two zotarolimus-eluting stents LM-LC (culotte technique) with an optimal angiographic and intravascular ultrasound result.
Discharge (200)	The patient remained asymptomatic and was discharged with optimal medical therapy, left ventricular function was moderately reduced with infero-postero akinesia.

Case presentation

A 68-year-old man with hypertension, diabetes mellitus, dyslipidaemia, obesity, and active smoker presented to our Emergency Department with continuous chest pain.

Eight years before, symptomatic for stable angina, he was treated with aortic bypass revascularization: left internal mammary artery (LIMA) for left anterior descending (LAD), saphenous vein graft (SVG) for right coronary artery (RCA) and SVG for intermediate ramus (IR) and obtuse marginal (OM). He was haemodynamically stable with a normal arterial pressure (140/90 mmHg) and a Killip Class 1. Electrocardiogram reveals inferior ST-segment elevation.

Urgent coronary angiogram revealed 90% stenosis of predivisional left main (LM), LAD with proximal 85% stenosis and subsequent occlusion, left circumflex (LC) with a 80% mid stenosis and IR occluded (*Figure 1*); RCA occluded at mid-portion; LIMA for LAD without stenosis; SVG for IR and OM chronically occluded; and SVG for RCA with thrombotic acute occlusion.

The SVG for RCA was treated with a direct everolimus-eluting stent implantation with a good result. Because of the chronic occlusion for the SVG for IR-OM and the presence of a severe critical stenosis of LM, revascularization of LM-LAD-LC was planned 3 days after primary PCI with a two stents Culotte Technique scheduled. Rotablator was excluded for the high angulation between the LM and LC and the relative risk of burr entrapment.

The technical setting was left radial access with a 6/7-Fr *Glidesheat Slender Introducer* and a guiding catheter EBU4.0 7 Fr was placed in LM. Balance Middleweight Guides (Abbot) wires were placed in mid LAD and LC. After predilatation of LC and distal LM with 2.5 mm semi-compliant balloon (*Figure 2A and B*) up to 14 atmosphere (atm) the wire resulted stuck into the calcium of LM and we were no able to bring any balloon or material into the LC even increasing the support with anchoring balloon in proximal LAD. In order to free the wire, a dilatation LM-LAD with a non-compliant (NC) balloon 3.0/

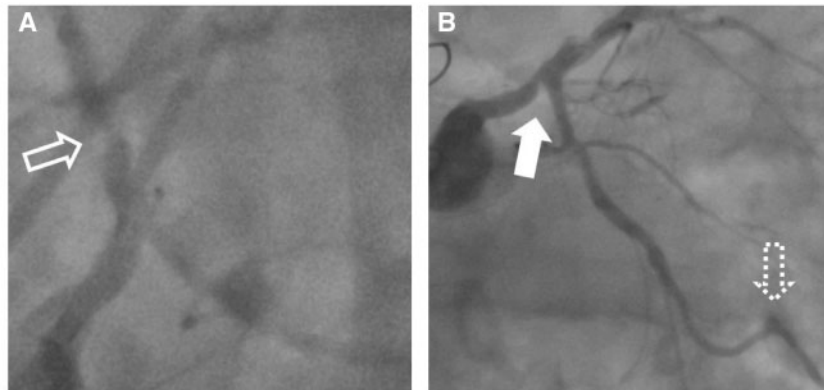


Figure 1 (A) Basal caudal-left view; (B) basal caudal view. Dotted arrow, occluded saphenous vein graft anastomosis; empty arrow, left anterior descending stenosis; full arrow, left main stenosis.

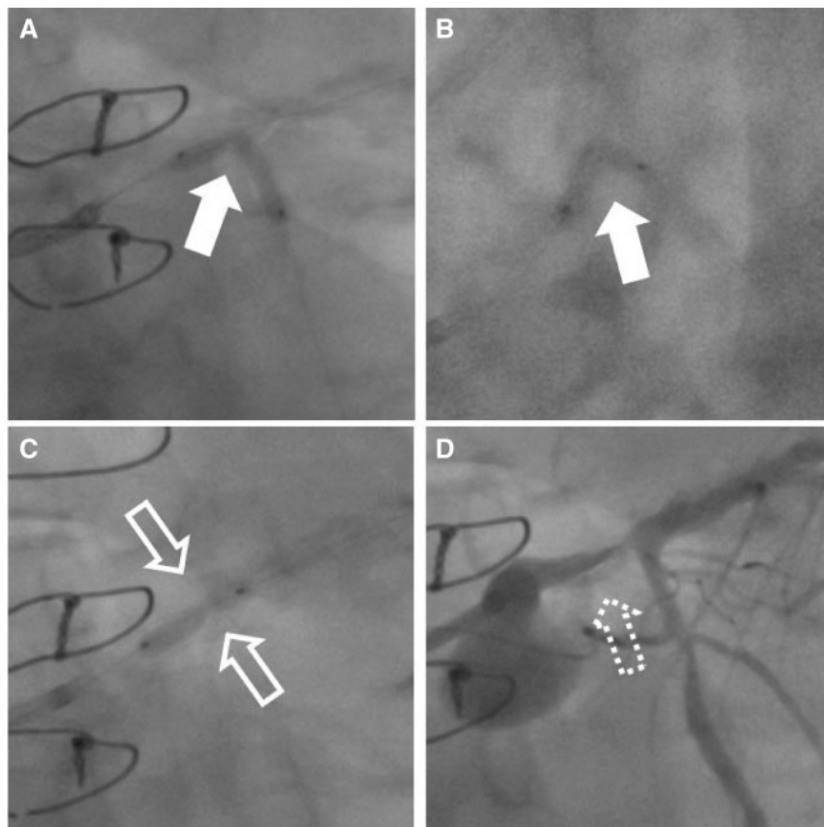


Figure 2 (A and B) Percutaneous coronary intervention with semi-compliant balloon in caudal and left-caudal view (full arrows); (C) percutaneous coronary intervention with non-compliant balloon at high atmosphere remaining unexpanded (empty arrows); (D) consequent huge dissection of the left main (dotted arrow).

15 mm at 18 atm was performed unsuccessfully and the lesion remained unexpanded. We decided to perform a ICL but only an undersized balloon was available (2.5/12 mm); therefore we dilated the lesion with a undersized NC balloon 2.5/15 mm at very high pressure (30 atm) (Figure 2C). The balloon remained partially unexpanded

but induced a huge dissection of LM with consequent hemodynamically instability (Figure 2D and [Supplementary material online, Video S1](#)).

To fix the dissection we implanted a zotarolimus-eluting stent (ZES) (3.5/26 mm) from LM to proximal LAD which remained

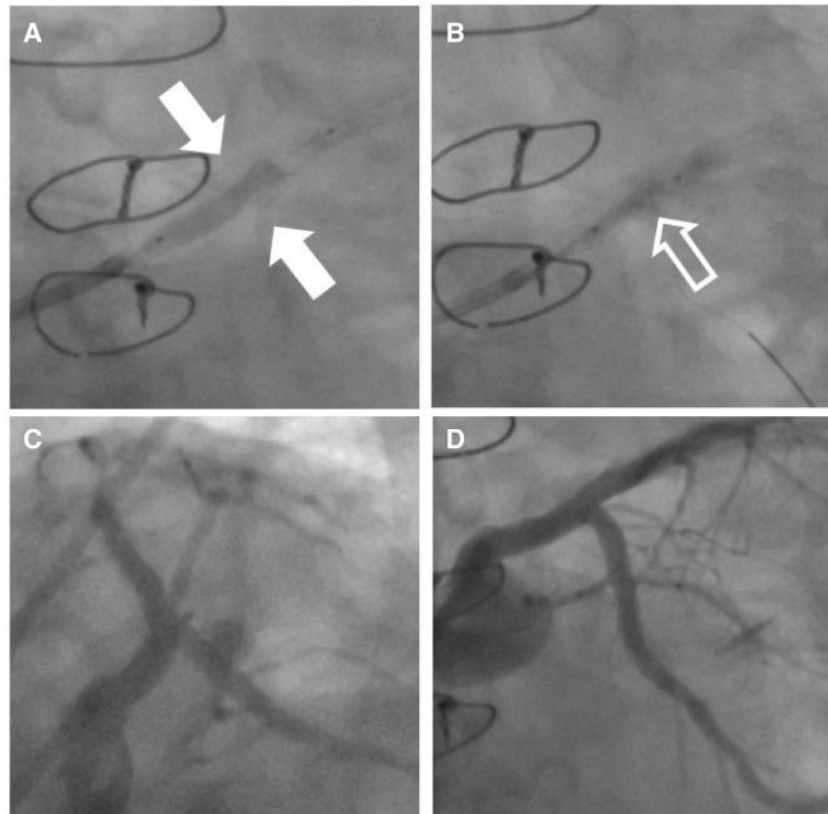


Figure 3 (A) Stent implanted and remained unexpanded (full arrow); (B) percutaneous coronary intervention with shockwaves balloon and lithotripsy (empty arrow); (C and D) final result in left-caudal and caudal views.

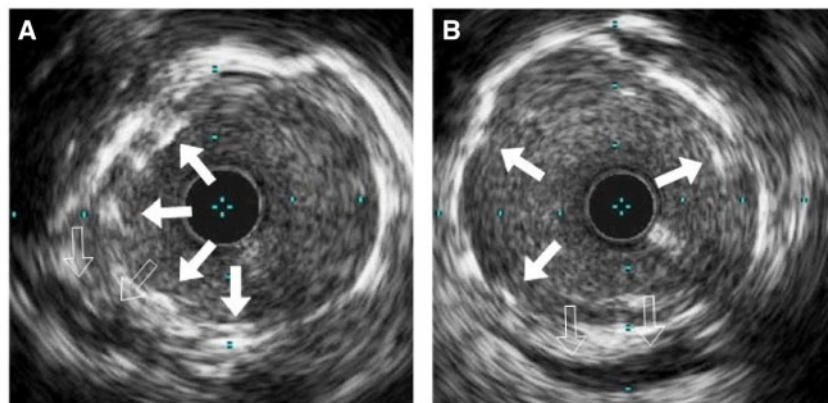


Figure 4 Final intravascular ultrasound registration of distal (A) and proximal (B) left main with a good expansion of the stent (full arrows) healing the huge dissection (empty arrows).

unexpanded in the mid-portion (Figure 3A and [Supplementary material online, Videos S2 and S3](#)).

We performed several unsuccessful post dilatation with NC balloon 3.5/15 up to 28 atm. As a bail-out strategy, we performed three cycles of 10 impulses of ICL inside the stent with the only available shockwaves

balloon (Figure 3B). After the treatment, we were able to expand correctly the stent with a NC 3.5/15 balloon going up to 14 atm.

The procedure was completed recrossing the stent to the LC with the implantation of two ZES in mid LC and LM-Proximal LC (Coulotte Technique), partially overlapped (Figure 3C and D).

Intravascular ultrasound confirmed the good final result and the good expansion of the stents (Figure 4).

The patient was discharged after 5 days with a moderate depression of the ejection fraction (45%), due to an hypokinesia of the inferior wall, on aspirin, ticagrelor, high-dose statin, beta-blocker, and angiotensin-converting enzyme inhibitor. At 1-month follow-up, the patient is still asymptomatic conducting a normal activity life.

Discussion

The percutaneous treatment of calcified coronary lesions is challenging and it is based on the concept of an optimal lesion preparation with plaque modification before stent implantation. Multiple adjunctive procedural devices have been introduced to improve the success rate in this particular scenario. Cutting and scoring balloons act through a direct fracture of the luminal calcium using for the first real blades applied on a balloon and for the seconds several kinds of stiff and sharp elements applied on a balloon.

Super high pressure balloon is a twin layer balloon designed to provide high rated burst pressure. These kinds of techniques are easy to use but determine a limited plaque modification.

Atherectomy is a strategy based on the concept of plaque-debulking through changing plaque morphology and compliance creating fractures in calcium: rotational atherectomy is one of the most used system based on this concept.

Rotational atherectomy is a complex system using a diamond-tipped burr available in several diameters. The high speed rotation of the burr determine a debulking of the plaque acting selectively on calcified tissue due to the different ability of the elasting and inelastic tissue to deflect under its action. The system is really effective in fracturing the plaque calcium.

The real limiting factor of rotational atherectomy is the complexity in preparing and using the system respect to cutting, scoring or super high pressure balloons. Moreover, distal embolization and the no-reflow phenomenon are not so uncommon complications.

Intracoronary lithotripsy is a novel technique based on a balloon that releases high-power acoustic shockwaves to disrupt calcified lesions using a technology similar to lithotripsy for kidney stones.

The system is really promising due to its feasibility, the ability to act on superficial and deep calcium, the reduced distal embolization due to the entrapment of fractured calcium into the vessel wall. The conceptual and procedural common point of all these techniques is the fact that they need to be applied before stent implantation; the only exception is the ICL whose mechanism of action is based on ultrasounds which are not blocked by the presence of a stent and may act on the calcium below the stent struts.

Our case report highlights the efficacy in this rare condition of the ICL: an unexpandable lesion, where a bail-out stent was implanted, has been effectively treated with this technology. Application of ICL permitted the expansion of a stent implanted obtaining an optimal final result.

Lead author biography



Gabriele Tumminello, MD, was born on 4 May 1976 in Italy. He completed his School of Medicine at University of Milan, Italy from 1995 to 2001, specialization in Cardiology at University of Milan, Italy from 2001 to 2005, and received scholarships for training abroad at University of Milan, Italy from 2005 to 2006. He was an MD at the Cardiology Hospital of Lodi starting his activity in invasive cardiology in

2007; MD at the Cardiology of Cardinal Massaia of Asti as interventional cardiologist in 2008; MD at the Cardiology of S. Andrea Hospital Vercelli as interventional cardiologist with particular regard to CTO procedures and left atrial appendage closure in 2016. At present, he is an MD at the Cardiology unit of ASST Santi Paolo e Carlo, Milan, Italy.

Supplementary material

Supplementary material is available at *European Heart Journal - Case Reports* online.

Slide sets: A fully edited slide set detailing this case and suitable for local presentation is available online as [Supplementary data](#).

Consent: The author/s confirm that written consent for submission and publication of this case report including image(s) and associated text has been obtained from the patient in line with COPE guidance.

Conflict of interest: none declared.

References

1. Grüntzig AR, Senning Å, Siegenthaler WE. Nonoperative dilatation of coronary-artery stenosis: percutaneous transluminal coronary angioplasty. *N Engl J Med* 1979;**301**:61–68.
2. Généreux P, Madhavan MV, Mintz GS, Maehara A, Palmerini T, LaSalle L, Xu K, McAndrew T, Kirtane A, Lansky AJ, Brener SJ, Mehran R, Stone GW. Ischemic outcomes after coronary intervention of calcified vessels in acute coronary syndromes. Pooled analysis from the HORIZONS-AMI (Harmonizing Outcomes With Revascularization and Stents in Acute Myocardial Infarction) and ACUITY (Acute Catheterization and Urgent Intervention Triage Strategy) TRIALS. *J Am Coll Cardiol* 2014;**63**:1845–1854.
3. Barbato E, Shlofmitz E, Milkas A, Shlofmitz R, Azzalini L, Colombo A. State of the art: evolving concepts in the treatment of heavily calcified and undilatable coronary stenoses—from debulking to plaque modification, a 40-year-long journey. *EuroIntervention* 2017;**13**:696–705.
4. Brinton TJ, Ali ZA, Hill JM, Meredith IT, Maehara A, Illindala U, Lansky A, Göteborg M, Van Mieghem NM, Whitbourn R, Fajadet J, Di Mario C. Feasibility of shock-wave coronary intravascular lithotripsy for the treatment of calcified coronary stenoses (Disrupt CAD I study). *Circulation* 2019;**139**:834–836.
5. Wong B, El-Jack S, Newcombe R, Glenie T, Armstrong G, Khan A. Shockwave intravascular lithotripsy for calcified coronary lesions: first real-world experience. *J Invasive Cardiol* 2019;**31**:46–48.