

Premature Coronary Artery Disease and ST-Elevation Myocardial Infarction in a 24-Year-Old Man With Perinatally Acquired Human Immunodeficiency Virus: A Case Report

David C. Griffith,^{1,2} Konstantinos N. Aronis,¹ Angela M. Orozco,^{1,2} Thomas A. Traill,¹ Yukari C. Manabe,¹ and Allison L. Agwu^{1,2}

Departments of ¹Medicine and ²Pediatrics, Johns Hopkins University, Baltimore, Maryland

Patients with human immunodeficiency virus (HIV) have increased risk of cardiovascular disease. Although evidence of subclinical atherosclerosis in perinatally acquired HIV (PHIV) is available, myocardial infarction has not been described in this population. We report a case of myocardial infarction in a patient with PHIV with a brief literature review.

Keywords. cardiovascular disease; HIV; myocardial infarction; perinatal.

CASE PRESENTATION

Our patient is a 24-year-old man with perinatally acquired human immunodeficiency virus (PHIV) who presented to his first visit at our hospital-based adult outpatient HIV clinic reporting fatigue and severe weight loss with worsening shortness of breath. Diagnosed with HIV shortly after birth, he initiated antiretroviral therapy at 5 years of age. His combination antiretroviral therapy (cART) history included multiple nucleoside reverse-transcriptase inhibitors (stavudine, lamivudine, didanosine, zidovudine, abacavir, emtricitabine), nonnucleoside reverse-transcriptase inhibitor (efavirenz), and protease inhibitors (nelfinavir, lopinavir, ritonavir, atazanvir), combined initially in dual and subsequently 3-drug regimens. He had periods of viral suppression from the age of 10 to 19, at which point he transferred care from the pediatric HIV program at our institution to another institution (see Supplementary data for treatment history). The patient reported difficulty engaging with the adult clinic and provider, had challenges with unstable

housing, intermittent employment, and minimal family support. He therefore self-discontinued cART and had fallen out of care.

His interval medical history is significant for pneumocystis pneumonia and cryptococcal meningitis 2 years prior. He had been hospitalized at an outside hospital twice in the prior month for weakness in the setting of hypokalemia. He smoked approximately a half a pack of cigarettes daily for the past 8 years and has occasional marijuana use. From the age of 9–19 years, his calculated low-density lipoprotein (LDL-C) range was 79–136 mg/dL, triglyceride range was 76–255 mg/dL, and high-density lipoprotein (HDL) range was 29–82 mg/dL. He denied any other illicit drug use. He reported no known family history of diabetes, cardiovascular disease (CVD), or early cardiac death.

His initial vital signs were as follows: blood pressure 90/64 mmHg, heart rate 55 beats/minute, temperature 35.9°C, respiratory rate 18 breaths/minute, and body mass index 12.9 kg/m². On exam, he was noted to be cachectic and frail, with the remainder of his exam normal, including heart with regular rate and rhythm without murmur, rub, or gallops. His initial laboratory tests were notable for hyponatremia (128 mEq/L), hypokalemia (2.3 mEq/L), hypophosphatemia (0.4 mg/dL), and a nonanion gap metabolic acidosis. Urine toxicology was negative. His CD4 count was 1 cell/mm³, and HIV-1 ribonucleic acid viral load was 43 642 copies/mL. Upon presentation, his electrocardiogram (ECG) showed normal sinus rhythm with left ventricular hypertrophy and prominent U waves in the precordial leads consistent with hypokalemia. His chest radiograph was normal.

He was admitted to our inpatient medicine ward for evaluation and management of his electrolyte derangements as well as nutritional assessment. His electrolyte abnormalities resolved; however, on hospital day 2, he suddenly developed new onset pressure-like chest pain that lasted for 20 minutes. The pain was severe in intensity, constant, and nonradiating. On exam, he was afebrile with a blood pressure of 94/62 mmHg and heart rate of 80 beats/minute. He was diaphoretic and mildly uncomfortable, but otherwise his physical examination was unchanged. An ECG showed prominent ST elevations in the anterior leads consistent with anterior wall ST elevation myocardial infarction (Figure 1a). Standard acute coronary syndrome treatment was promptly initiated. A transthoracic echocardiogram showed moderately reduced left ventricular systolic function with an ejection fraction of 30%–35% with severe hypokinesis of the mid anterior and anteroseptal wall as well as of the entire apex, consistent with ischemia in the left anterior descending (LAD) supply territory. His troponin I levels at the time of this event were 0.76 ng/mL (normal <0.04 ng/mL).

He underwent emergent coronary angiography, which showed a long, hazy 95% stenosis at the mid segment of the LAD with thrombolysis in myocardial infarction (TIMI)-2 flow distally.

Received 30 September 2016; editorial decision 22 November 2016; accepted 09 January 2017.

Correspondence: D. C. Griffith, MD, 200 North Wolfe Street, Room 3150, Baltimore MD, 21287 (dgriff50@jhmi.edu).

Open Forum Infectious Diseases®

© The Author 2017. Published by Oxford University Press on behalf of Infectious Diseases Society of America. This is an Open Access article distributed under the terms of the Creative Commons Attribution-NonCommercial-NoDerivs licence (<http://creativecommons.org/licenses/by-nc-nd/4.0/>), which permits non-commercial reproduction and distribution of the work, in any medium, provided the original work is not altered or transformed in any way, and that the work is properly cited. For commercial re-use, please contact journals.permissions@oup.com
DOI:

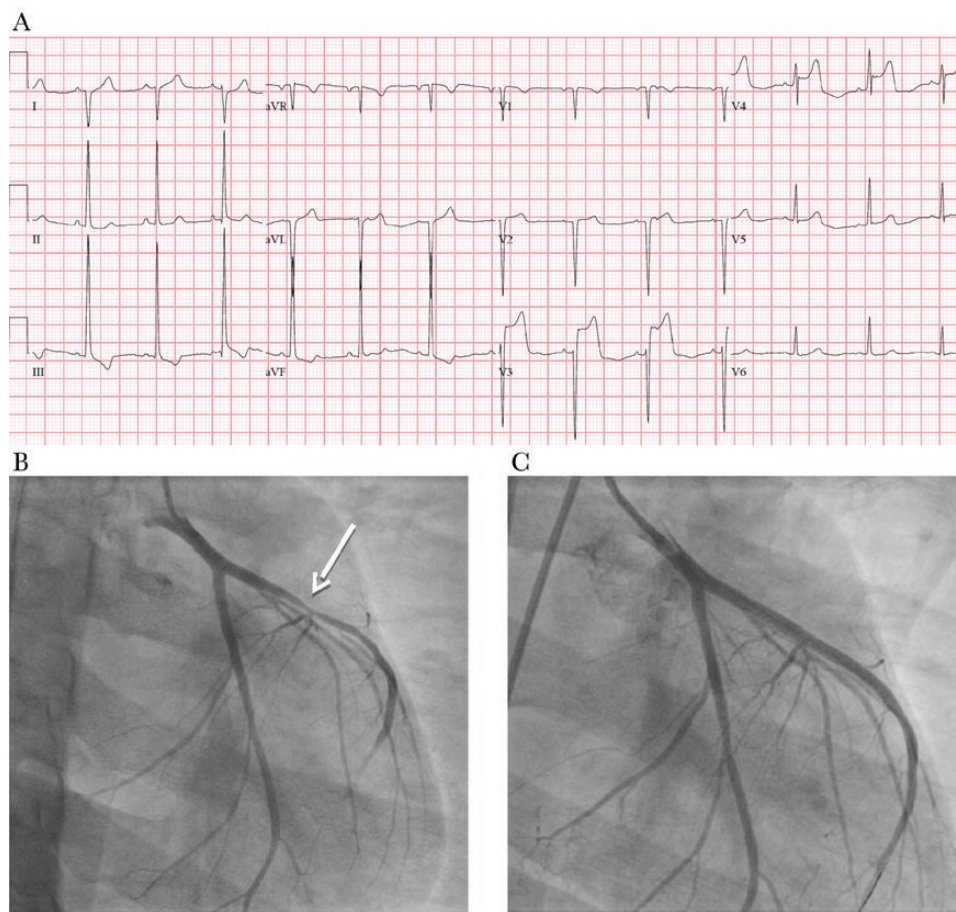


Figure 1. (a) Electrocardiogram (ECG) during episode of chest pain showing prominent ST elevations in the anterior leads (8 mm in lead V3 and 5 mm in lead V4). The rhythm is normal sinus at a rate of 78 beats per minute. The right axis deviation and the left ventricular hypertrophy by voltage criteria are unchanged from the presenting ECG. Prominent U waves seen on initial ECG are no longer present. (b) Initial coronary angiogram: right anterior oblique caudal view of the left anterior descending coronary artery (LAD) showing a 95% long and hazy stenosis of the mid-LAD segment (arrow). The incomplete filling of the LAD on this static frame is due to thrombolysis in myocardial infarction (TIMI)-2 flow observed on cine. A 30%–40% stenosis of the left circumflex first obtuse marginal branch is also visualized. (c) Post-percutaneous coronary intervention coronary angiogram: the 95% mid-LAD stenosis is now converted to a 0% and TIMI-3 flow is restored.

The LAD first diagonal branch had a 40% proximal stenosis, the left circumflex obtuse marginal branch had a 30%–40% stenosis in the mid segment, and the dominant right coronary artery had a 30% stenosis in the mid segment. Notably, there were no significant coronary calcifications visualized on the angiogram. He underwent successful percutaneous coronary intervention of the proximal and mid LAD segments with 2 overlapping Vision bare metal stents converting the hazy 95% stenosis to 0% and restoring TIMI-3 antegrade flow (Figure 1b and c).

He was subsequently transferred to the cardiac care unit for observation. His ST elevations resolved. His troponin I levels peaked at 9.85 ng/mL, approximately 17 hours after the onset of his symptoms. The remainder of his laboratory tests revealed the following: total cholesterol 52 mg/dL, triglycerides 48 mg/dL, HDL 27 mg/dL, LDL-C 17 mg/dL, lipoprotein(a) levels <10 nmol/L, and C-reactive protein (CRP) <0.1 mg/dL. He was discharged on 81 mg of aspirin and 75 mg of clopidogrel.

He was not prescribed a beta blocker because of hypotension. He was also restarted on cART.

DISCUSSION

This case illustrates the development of premature atherosclerosis resulting in an acute coronary event in a young patient with PHIV. Cardiovascular disease is a major source of morbidity and mortality in patients with HIV with an estimated rate of 0.49 CVD events per 100 person years for virally suppressed patients and an adjusted hazard ratio of 2.1 (95% confidence interval, 1.7–2.6) for CVD event for every 10-year increase in age [1]. Large cohort studies have shown increased risk of acute myocardial infarction in HIV-infected adults, even after accounting for traditional CVD risk factors [2]. However, rates among individuals with PHIV are not captured or described in these studies, and as of yet there are no reports of myocardial infarction in PHIV.

Although there are limited data on CVD events in youth, subclinical atherosclerosis has been described in HIV-infected youth

through multiple imaging modalities. Ultrasound assessments of carotid artery intima media thickness (CIMT) was used in a multicohort study of HIV-infected patients and controls aged 6–75 years [3]. HIV-infected participants aged 6–29 years ($n = 279$) had increased CIMT compared with HIV-uninfected controls ($n = 58$) after adjusting for traditional CVD risk factors with strengthening of the association when the analysis was limited to PHIV. This difference was not seen in patients aged 30–49 ($n = 738$) and 50–75 years ($n = 730$), which suggests that in youth, HIV itself increases the risk of artery thickening, with an increasing role of traditional risk factors as patients age. Additional cohort studies support these findings with 1 cohort showing both cART-naive and virally suppressed HIV-infected children have increased CIMT compared with HIV-uninfected children [4]. Youth with early-acquired or PHIV (15–29 years old) had increased right coronary artery wall thickness, compared with HIV-uninfected controls in a study using coronary magnetic resonance imaging [5]. All identified plaques were noncalcified and not associated with significant luminal narrowing. These studies highlight that youth with PHIV have subclinical atherosclerosis, although there is lack of data that relates subclinical atherosclerosis to adverse clinical outcomes.

The increased risk of atherosclerosis in HIV-infected individuals is likely caused by several factors, including HIV-induced immune activation and monocyte/macrophage-mediated inflammation (regardless of cART use), direct vascular effects of HIV, and the adverse metabolic effects of antiretroviral therapy, in addition to traditional CVD risk factors [6]. Multivariable analysis of several cohorts of children and adolescents have shown that compared with controls, PHIV is associated with elevated markers of endothelial dysfunction, in particular soluble vascular cell adhesion molecule 1 (sVCAM) and soluble intracellular adhesion molecule 1 (sICAM) and markers of immune activation and inflammation, including monocyte chemoattractant protein-1 (MCP-1), interleukin-6, soluble CD14 (sCD14) and CRP, as well as fibrinogen, a marker of coagulant dysfunction [7, 8]. Higher HIV viral loads are associated with markers of inflammation (MCP-1 and CRP) and endothelial dysfunction (sICAM and sVCAM) [8]. However, sCD14 and sVCAM have been shown to be increased even in the setting of viral suppression [7]. Although based on small cohorts, these studies highlight the impact on early-acquired HIV on biomarkers associated with CVD.

Exposure to cART, in particular older protease inhibitor (PI) agents lopinavir and indinavir and potentially abacavir, has been associated with myocardial infarction; however, the data are not definitive [9]. More importantly, continuous cART has been shown to decrease the rate of CVD events compared with cART with treatment interruptions [10]. In children with PHIV, adverse structural and functional vascular changes (as measured by CIMT artery flow-mediated dilatation) have been associated with PI exposure [11]. Children and adolescents

with PHIV have been shown to have higher rates of dyslipidemia compared with uninfected controls, with PI use being the strongest associated risk factor [12].

Our patient's CVD risk factors include prolonged periods of uncontrolled viral replication during the first 5 years of his life before he was started on cART and for the last 5 years when he was not taking cART. Moreover, he has a long history of cART, with exposure to agents potentially associated with CVD (lopinavir/ritonavir and abacavir). Finally, he is actively smoking, although with a limited pack-year history. He does not have a history of sustained hyperlipidemia, although his HDL was very low at the time of presentation.

CONCLUSIONS

As shown in this case, an increased index of suspicion for CVD may be warranted in individuals with PHIV. Future studies on CVD risk assessment and optimization are needed, because there are currently no guidelines on CVD risk management in these patients. The role of statins is unclear, and individuals with PHIV do not meet the age inclusion criteria for the ongoing randomized trial to prevent vascular events in HIV (REPRIEVE) [13]. This case also highlights the importance of successful transition from pediatric to adult providers to minimize serious complications caused by lapses in care.

Supplementary Data

Supplementary materials are available at *Open Forum Infectious Diseases* online. Consisting of data provided by the authors to benefit the reader, the posted materials are not copyedited and are the sole responsibility of the authors, so questions or comments should be addressed to the corresponding author.

Acknowledgments

Financial support. This work was funded by the National Institutes of Health (Grant T32AI052071).

Potential conflicts of interest. All authors: No reported conflicts.

All authors have submitted the ICMJE Form for Potential Conflicts of Interest. Conflicts that the editors consider relevant to the content of the manuscript have been disclosed.

References

1. Miller CJ, Baker JV, Bormann AM, et al. Adjudicated morbidity and mortality outcomes by age among individuals with HIV infection on suppressive antiretroviral therapy. *PLoS One* **2014**; *9*:e95061.
2. Paisible AL, Chang CC, So-Armah KA, et al. HIV infection, cardiovascular disease risk factor profile, and risk for acute myocardial infarction. *J Acquir Immune Defic Syndr* **2015**; *68*:209–16.
3. Hanna DB, Guo M, Bůžková P, et al. HIV infection and carotid artery intima-media thickness: pooled analyses across five cohorts of the NHLBI HIV-CVD Collaborative. *Clin Infect Dis* **2016**; 1–8.
4. Sainz T, Álvarez-Fuente M, Navarro ML, et al. Subclinical atherosclerosis and markers of immune activation in HIV-infected children and adolescents. *J Acquir Immune Defic Syndr* **2014**; *65*:42–49.
5. Abd-Elmoniem KZ, Unsal AB, Eshera S, et al. Increased coronary vessel wall thickness in HIV-infected young adults. *Clin Infect Dis* **2014**; *59*:1779–86.
6. Nou E, Lo J, Grinspoon SK. Inflammation, immune activation, and cardiovascular disease in HIV. *AIDS* **2016**; *1495*–1509.
7. Sainz T, Diaz L, Navarro ML, et al. Cardiovascular biomarkers in vertically HIV-infected children without metabolic abnormalities. *Atherosclerosis* **2014**; *233*:410–4.

8. Miller TI, Borkowsky W, DiMeglio LA, et al. Metabolic abnormalities and viral replication are associated with biomarkers of vascular dysfunction in HIV-infected children. *HIV Med* **2012**; 13:264–75.
9. Bavinger C, Bendavid E, Niehaus K, et al. Risk of cardiovascular disease from antiretroviral therapy for HIV: a systematic review. *PLoS One* **2013**; 8: e59551.
10. El-Sadr W, Lundgren JD, Neaton JD, et al. CD4+ count-guided interruption of antiretroviral treatment. *N Engl J Med* **2006**; 355:2283–2296.
11. Charakida M, Donald AE, Green H, et al. Early structural and functional changes of the vasculature in HIV-infected children: impact of disease and antiretroviral therapy. *Circulation* **2005**; 112:103–9.
12. Farley J, Gona P, Crain M, et al. Prevalence of elevated cholesterol and associated risk factors among perinatally HIV-infected children (4-19 years old) in Pediatric AIDS Clinical Trials Group 219C. *J Acquir Immune Defic Syndr* **2005**; 38:480–7.
13. Gilbert JM, Fitch KV, Grinspoon SK. HIV-related cardiovascular disease, statins, and the REPRIEVE trial. *Top Antivir Med* **2015**; 23:146–9.