

Central Tendon Injuries of Hamstring Muscles

Case Series of Operative Treatment

Lasse Lempainen,^{*†} MD, PhD, Jussi Kosola,[†] MD, PhD, Ricard Pruna,[‡] MD, PhD, Jordi Puigdellivol,[‡] MD, Janne Sarimo,[†] MD, PhD, Pekka Niemi,[†] MD, PhD, and Sakari Orava,[†] MD, PhD

Investigation performed at the Sports Trauma Research Unit, Hospital Mehiläinen NEO, Turku, Finland

Background: As compared with injuries involving muscle only, those involving the central hamstring tendon have a worse prognosis. Limited information is available regarding the surgical treatment of central tendon injuries of the hamstrings.

Purpose: To describe the operative treatment and outcomes of central tendon injuries of the hamstrings among athletes.

Study Design: Case series; Level of evidence, 4.

Methods: Eight athletes (6 top level, 2 recreational) with central hamstring tendon injuries underwent magnetic resonance imaging and surgical treatment. The indication for surgery was recurrent ($n = 6$) or acute ($n = 2$) central hamstring tendon injury. All patients followed the same postoperative rehabilitation protocol, and return to play was monitored.

Results: Magnetic resonance imaging found a central tendon injury in all 3 hamstring muscles (long head of the biceps femoris, semimembranosus, and semitendinosus) with disrupted tendon ends. In acute and recurrent central tendon injuries, full return to play was achieved at 2.5 to 4 months. There were no adverse events during follow-up.

Conclusion: Central tendon injuries of the hamstrings can be successfully repaired surgically after acute and recurrent ruptures.

Keywords: central tendon rupture; hamstring; MRI; surgical treatment; return to play

As recently pointed out, the central or paramuscular tendons of the hamstrings may be the site of chronic and recurrent hamstring injuries.³ These central tendon tears are mainly located 10 to 20 cm distally from the origin of the hamstrings, and they are often difficult to diagnose,³ as they can mimic a simple muscle strain injury.

The hamstrings have a complete or near-complete intra- or paramuscular tendon extending down the entire length

*Address correspondence to Lasse Lempainen, MD, PhD, Sports Trauma Research Unit, Hospital Mehiläinen NEO, Turku, Finland (email: lasse.lempainen@utu.fi).

[†]Sports Trauma Research Unit, Hospital Mehiläinen NEO, Turku, Finland.

[‡]FC Barcelona, Medical Services, FIFA Center of Excellence, Barcelona, Spain.

The authors declared that they have no conflicts of interest in the authorship and publication of this contribution.

Ethical approval for this study was obtained from Mehiläinen NEO local ethics committee.

The Orthopaedic Journal of Sports Medicine, 6(2), 2325967118755992

DOI: 10.1177/2325967118755992

© The Author(s) 2018

of the muscle belly. This tendon may be described as the *central tendon*.^{8,26} There are also anatomic variations of this central tendon, as some are completely surrounded by muscle tissue and some run beside the muscle tissue itself.¹¹ The central tendons of the hamstrings run from the ischial tuberosity to different insertion sites medially (the semimembranosus and semitendinosus muscles) and laterally (the biceps femoris [BF] muscle) around the knee joint.

The injury patterns of the hamstrings vary. For an athlete, it is important to know which part of the specific muscle or tendon is injured.²³ Magnetic resonance imaging (MRI) is the most accurate and reliable imaging method to classify hamstring injuries.⁶ It can be particularly useful for assessing injuries involving the central tendon.¹⁹

Although most hamstring muscle strains seem to heal well without surgery,²⁰ there are also clear indications for surgical treatment. Early surgical treatment is recommended in acute complete hamstring avulsions^{14,16,20,21} and in some cases of incomplete hamstring tears, especially among athletes.^{12,13} However, some hamstring injuries may become chronic and recur,²⁵ possibly owing to involvement of the central tendon.³

TABLE 1
Characteristics of Case Examples With Central Tendon Rupture^a

Case	Age, y	Sport	Sex	Injury Type	Injured Central Tendon	Primary Injury to Surgery, mo ^b	Presurgery Recurrence	Repair Type	RTP, mo	Follow-up, mo
1 ^c	21	Pole vaulting	Male	Recurrent	Long head of BF	9	Third injury	Suturation by anchor reinforcement	3.5	12
2 ^c	19	Soccer	Male	Recurrent	Long head of BF	3	Second injury	Suturation by anchor reinforcement	4	12
3	19	Soccer	Male	Recurrent	Long head of BF	6	Several	Z-plasty suturation + anchor reinforcement	4	8
4	21	Soccer	Male	Recurrent	Long head of BF	10	Several	Z-plasty suturation + anchor reinforcement	4	24
5	18	Soccer	Male	Recurrent	Long head of BF	6	Second injury	Z-plasty suturation + anchor reinforcement	4.5	24
6 ^c	18	Soccer	Female	Recurrent	SM	12	Third injury	Suturation tendon repair by Z-plasty	4	12
7 ^c	43	Recreational runner	Male	Acute	SM	7 d	First injury	Suturation tendon repair	3-4	12
8 ^c	45	Recreational runner	Male	Acute	Long head of BF + ST	10 d	First injury	Suturation by anchor reinforcement	2.5	12

^aBF, biceps femoris; RTP, return to play to former level; SM, semimembranosus; ST, semitendinosus.

^bValues are presented as months unless noted otherwise.

^cFigure with case representation available.

So far, there is only limited information on the surgical treatment of central tendon injuries and the outcome. The aim of this study was to demonstrate the operative results of central hamstring tendon ruptures after acute or recurrent injuries.

METHODS

This study was approved by the local ethics committee. The series consisted of 8 patients (Table 1). The mechanism of central hamstring tendon injuries was similar to that of the typical hamstring injuries: a rapid change of direction during fast sprinting or overstretching of the hamstring while falling. Indications for surgery in acute cases were a clear gap between the central hamstring tendon ends, whereas in chronic cases, the patients had recurrent disabling injuries and were not able to fully participate in competitive sports at their former levels. The patients who underwent surgery were imaged with axial, sagittal, and coronal fat-suppressed T1- and T2-weighted MRI of the pelvis and both thighs (Figures 1-5). The central tendon injuries occurred in the long head of the BF (cases 1-5, 8), semimembranosus (cases 6 and 7), and semitendinosus (case 8) muscles. Before imaging, a skin marker was placed at the maximal pain site. White arrows in the figures mark the central tendon injury and the retraction of the tendon. Notably, the sciatic nerve in case 8 is marked with an asterisk (*) in Figure 5.

Surgical Technique

For surgery, the patient was positioned prone and a pillow placed under the feet to hold the knee in slight flexion to relax the hamstring muscles. A vertical incision was made

over the injured area. A fasciotomy was made in the line of the skin incision. The ruptured central tendon was identified inside or beside the affected muscle belly. Care was taken not to harm the sciatic nerve, which could run near the injured area (Figure 5B). In acute injuries, it is also essential to restore the tonus of the ruptured and often retracted muscle back to normal (Figure 6); however, the injured structures should not be overtightened. In recurrent injuries, the operative finding was fibrotic scarring and a too tightly healed central tendon inside the affected muscle. In these cases, the injured tendon was repaired with a gliding Z-plasty and suturing (No. 3-0 or 0 polydioxanone absorbable sutures), which released the tension of the overtightened central tendon (Figure 6A). In cases where the central tendon rupture was located near (eg, 8-12 cm) the ischial tuberosity, the ruptured area was repaired by inserting a single suture anchor into the ischial tuberosity for reinforcement (Figure 6B). If the rupture was acute and located more distally from the ischial tuberosity (approximately 15-20 cm), suturing was done without suture anchors, and the attachments of the sutures were taken from the healthy proximal part of the affected tendon (Figure 6, C and D).

Postoperative Rehabilitation

During early postoperative rehabilitation, prolonged sitting was avoided for the first 2 to 3 weeks to allow the skin incision to heal properly. Also, overly active stretching of the operated hamstrings was avoided. No hip-knee bracing was used. The patient was immediately mobilized with crutches for pain-free full weightbearing. The rehabilitation process advanced during weeks 3 to 4 to include aqua training, followed by stationary biking with light resistance

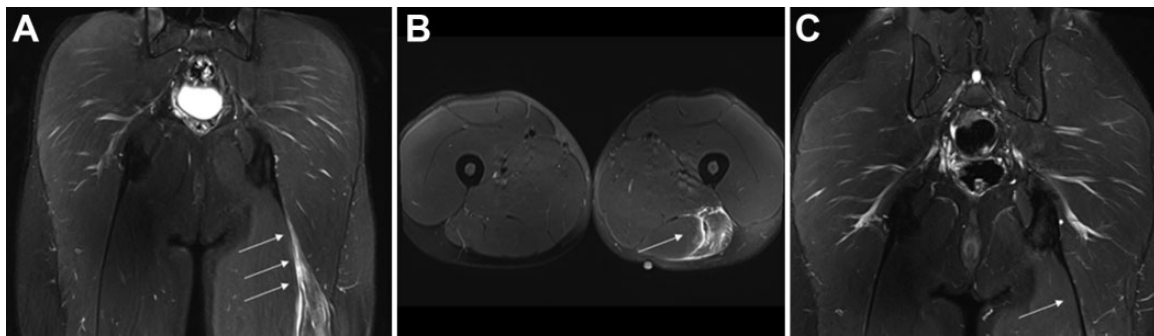


Figure 1. (A and B) Case 1: recurrent injury (third rupture) of the biceps femoris central tendon with evident retraction (arrows). (C) Five-month postoperative magnetic resonance imaging showed well-healed central tendon (arrow). Technique: suture with anchor reinforcement.

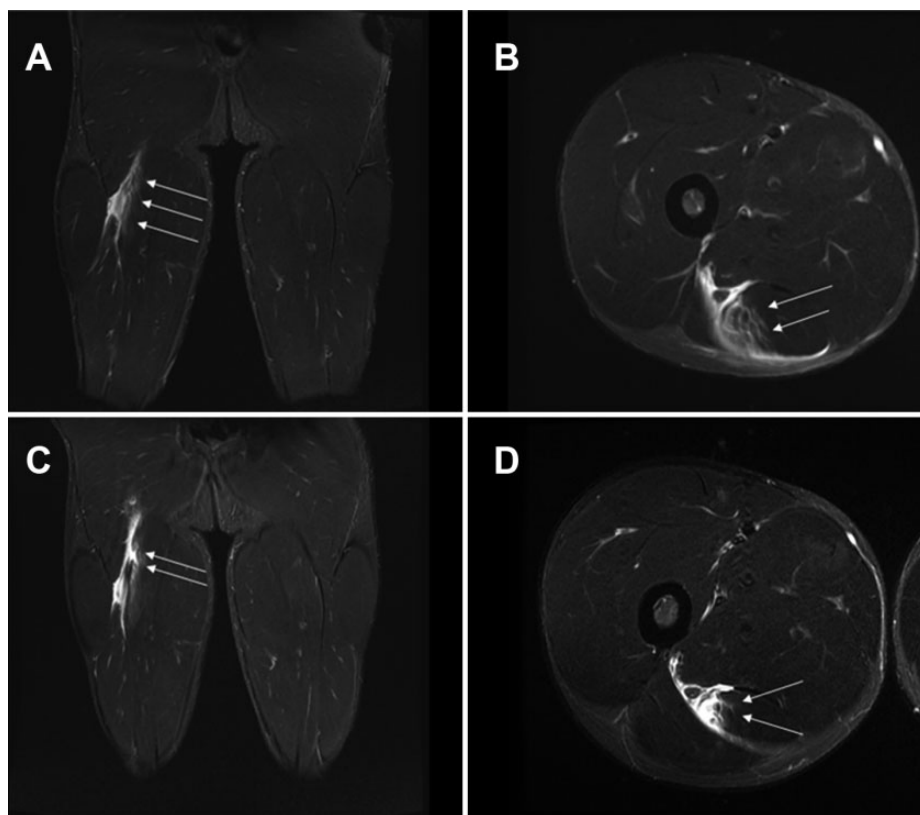


Figure 2. (A and B) Case 2: Initial magnetic resonance images show incomplete rupture of the central tendon of the biceps femoris (arrows). (C and D) Repeated imaging was taken 10 days later and revealed a clear gap between the retracted central tendon ends (arrows). Technique: suture with anchor reinforcement.

and antigravity treadmill running. After early rehabilitation and when the normal range of movement of the hamstrings was achieved, we adapted a 4-step model for on-field return to play (RTP). The first step was circuit training on dry sand to reduce the impact forces to the hamstring.² After sufficient proprioception had been reached, the athlete progressed to the second step: limited sports-specific movements, such as ball control in soccer. The third step focused on decreasing the peak forces to the hamstrings caused by running; this was achieved by up- and downhill

running.^{10,18} The fourth and final step was return to full sports-specific skills without any restrictions.

RESULTS

Overall, 8 athletes with central hamstring tendon injuries (acute, $n = 2$; recurrent, $n = 6$) were included in this study (Table 1). The recurrent injuries were seen in younger top-level athletes, while the acute injuries were seen in

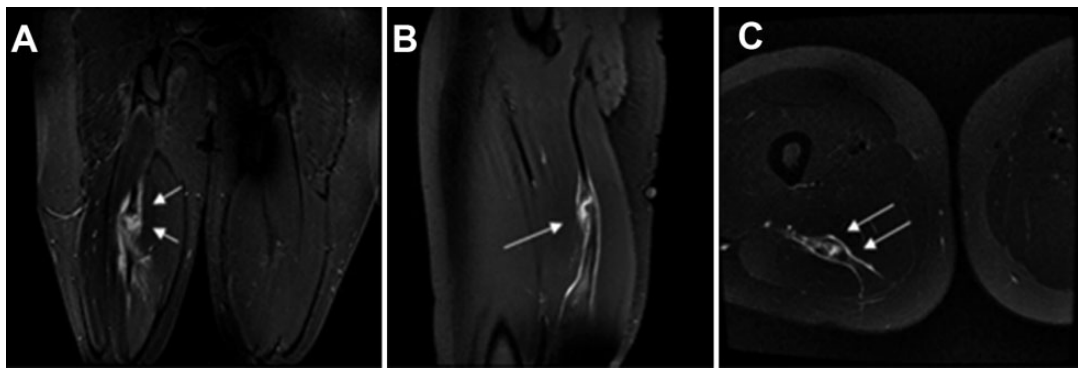


Figure 3. (A-C) Case 6: Because of the recurrent hamstring injury (third disabling injury), the player missed the whole competitive season. Magnetic resonance images showed total central tendon rupture of the semimembranosus (arrows). Technique: suture-tation.

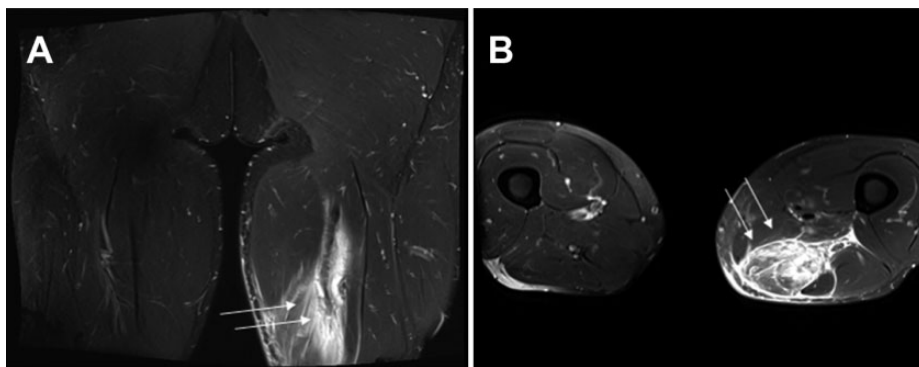


Figure 4. (A and B) Case 7: Ruptured central tendon of the semimembranosus with a 6-cm gap between the tendon ends (arrows). Technique: suture-tation.

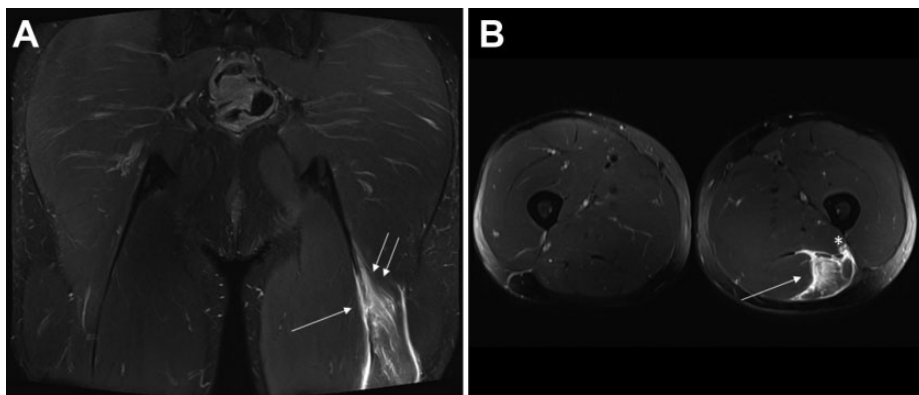


Figure 5. (A and B) Case 8: Central tendon ruptures of the biceps femoris (single arrow) with concurrent rupture of the semitendinosus tendon (double arrows). Observe that the sciatic nerve (*) runs close to the ruptured central tendon. Technique: suture-tation with anchor reinforcement.

recreational athletes. The central tendon of the BF long head was the most commonly ruptured; 5 athletes were professional soccer players. All soccer players had a history of several hamstring injuries.

Figures 1 to 5 show the detailed MRI findings associated with the intraoperative findings. The size of the gap

between ruptured tendon ends was approximately 2 to 6 cm, and these cases were treated by suture-tation ($n = 4$). Z-plasty was required for cases 3 to 6 because of scarred, tight, and thickened tendon. All athletes achieved RTP by 2.5 to 4.5 months. All athletes regained their preinjury levels of competition.

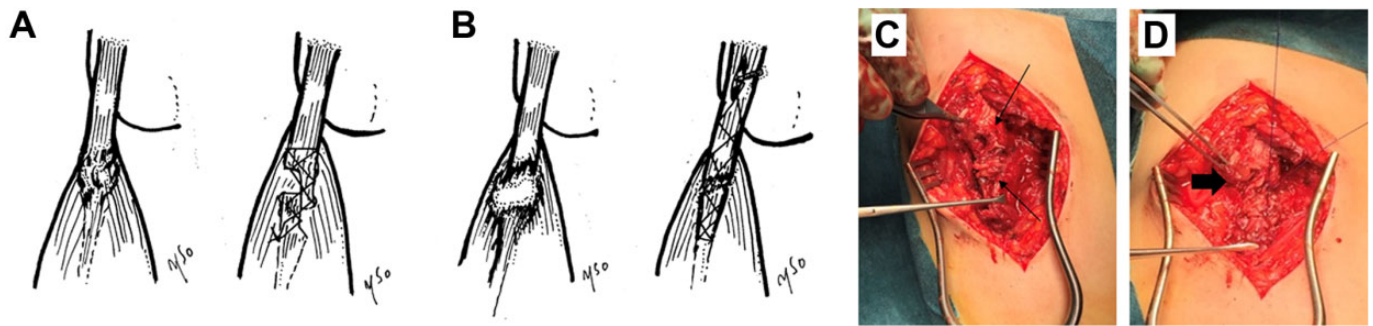


Figure 6. Schematic drawings and perioperative images of central hamstring tendon surgery. (A) Tight and scarred rupture (partial, recurrent) of central tendon following debridement of adhesions with Z-plasty. (B) Rupture of central tendon (8-12 cm from ischial tuberosity) sutured by anchor inserted into the ischial tuberosity for reinforcement. (C) Acute rupture of biceps femoris central tendon showing tendon ends (arrows) with gap. (D) Central tendon of the biceps femoris has been sutured (arrow).

DISCUSSION

We demonstrate good outcomes following surgical treatment of central hamstring tendon ruptures, with no adverse events during follow-up. Our patients had sustained acute and recurrent injuries. It is vital to the athlete to know whether these recurrent hamstring injuries could jeopardize only the competitive season⁷ but also his or her entire career.

Previous studies mainly reported on the benefits of surgical treatment of proximal and distal ruptures of the hamstring tendon.^{12-14,16,20,21} There is a paucity of information on central hamstring tendon injuries and the outcome of operative treatment.⁴ In our institute, we conduct several consultations per year regarding various hamstring injuries. The cases involved in the present study were collected during the last 2.5 years, including follow-up time. The severity of central tendon injuries varies widely. Based on recent experience, in our institute, operative treatment is selected for the majority of the severe or recurrent central tendon injuries of athletes. Early diagnosis and treatment interventions may be warranted, and physicians treating these central tendon ruptures need to understand that surgical treatment is an option, especially for recurrent central hamstring tendon injuries.

Our findings emphasize the role of MRI as the primary diagnostic tool. MRI has not been recommended for follow-up, and studies have claimed that it lacks clinical relevance for assessing the time to RTP after a hamstring injury.^{5,9,12} Our case examples were diagnosed with MRI, which showed the central tendon entity of all 3 hamstring muscles. The severity of the central tendon rupture can sometimes become more apparent only with repeated MRI examinations, as shown by case 2 (see Figure 2). MRI seems also to identify recurrent isolated central tendon injuries. In our case series, the central tendon of the semimembranosus muscle was clearly ruptured with retraction of the 2 tendon heads, which might lead to chronic disabling pain and dysfunction of the affected muscle (case 6) (see Figure 3).¹⁵ Given this experience, we highlight the need for MRI examinations for prompt diagnosis.

Comprehensive epidemiologic studies have not been carried out regarding the incidence of central hamstring

tendon ruptures, although Comin et al⁴ reported a rather high number ($n = 12$) of central tendon lesions of the long head of the BF in a total series of 45 BF injuries. However, they did not record whether the central tendon was retracted, nor did they mention if there was a gap between the tendon ends. On the basis of our experience, we surgically treated those acute as well as recurrent central hamstring tendon injuries that had a clear gap between the tendon ends. Patients who were acutely treated had RTP within 2.5 and 4 months—figures similar to the ones reported by Comin et al⁴ (91 days). In our study, the long head of the BF central tendon was the most common structure involved.

The central hamstring tendon has been discussed in the current literature. According to Woodley and Mercer,²⁶ the central tendon extends almost at full length into the muscle belly of all 3 hamstring muscles. The classical assumption that muscle tissue differentiates into tendon only gradually is not true for the anatomy of the hamstrings. In view of this circumstance, MRI can identify the central tendons of all 3 hamstring muscles. In our study, the findings at surgery correlated precisely with the MRI findings (see Figures 1-5). Therefore, we recommend that physicians suspect an actual tendon structure injury even in cases where the injured area per MRI is located at the previously mentioned musculotendinous area. If a central tendon injury is present, the athlete should be informed that RTP will be postponed and that high-loading exercises should be completely pain-free before RTP, in order to reduce the risk of recurrent injury.

Recurrence is the most common complication of hamstring injuries. Seward et al²² reported that the recurrence rate of hamstring muscle injuries is as high as 34% in the Australian Football League, while Woods et al²⁷ reported a rate of 12% among English professional soccer players. The cumulative risk of recurrence may be high, as Orchard¹⁷ showed with 30.6% of cumulative recurrences during the entire 22-week season. In the present study, recurrent central tendon ruptures occurred mainly in younger patients. As Brukner and Connell³ concluded, these central tendon injuries need more time to recover, and these patients probably developed recurrent central tendon injury because of

too early RTP. The severity of the initial injury is often underestimated, and the central tendon injury might be missed, increasing the risk of recurrent injuries. In high-level sports, hamstring injuries tend to recur, and sufficient healing for RTP takes a substantial amount of time.¹³ Thus, we recommend a high suspicion of central tendon injury when hamstring injuries tend to recur.

For the athlete, hamstring injuries may jeopardize one's entire professional career.^{1,13} No recurrent injuries were seen during the follow-up after operation, and RTP was achieved at 2.5 to 4.5 months in our series. Comin et al⁴ reported that it takes 84 to 91 days for the ruptured central tendon of the BF to recover after surgery, which is in line with what we report in the present study. The type of postoperative rehabilitation protocol may influence the rate of treatment failure following hamstring injuries.²⁴ Our patients did not report any adverse events during rehabilitation.

Currently, the treatment strategy of central tendon injuries is not well established. Our series implies that operative treatment of central tendon injuries seems to lead to a good overall outcome for the high-level athlete. However, future studies are needed to resolve the question of whether these injuries should be operated on more acutely if tendon heads are clearly separated from each other on MRI.

There are some limitations in our study. First, there was no nonoperatively treated control group. However, we emphasize that all young top-level athletes had recurrent injuries and were initially treated nonoperatively with poor results. Before operation, they were not able to compete at their level as top-performing athletes. Second, the sample size was small, and more experience is needed for patients undergoing operatively treated central hamstring tendon rupture.

CONCLUSION

Acute and recurrent central hamstring tendon injuries were successfully treated surgically, and all 8 athletes in the series returned to their previous levels of competition. If a central tendon injury is suspected, MRI needs to be performed for confirming and classifying the extent of the injury and for assessing the best treatment option.

ACKNOWLEDGMENT

The authors acknowledge FC Barcelona physical therapist Juanjo Brau with the whole physical therapy team for collaboration.

REFERENCES

1. Askling C, Saartok T, Thorstensson A. Type of acute hamstring strain affects flexibility, strength, and time to return to pre-injury level. *Br J Sports Med.* 2006;40:40-44.
2. Binnie MJ, Dawson B, Arnot MA, Pinnington H, Landers G, Peeling P. Effect of sand versus grass training surfaces during an 8-week pre-season conditioning programme in team sport athletes. *J Sports Sci.* 2014;32:1001-1012.
3. Brukner P, Connell D. "Serious thigh muscle strains": beware the intramuscular tendon which plays an important role in difficult hamstring and quadriceps muscle strains. *Br J Sports Med.* 2016;50:205-208.
4. Comin J, Malliaras P, Baquie P, Barbour T, Connell D. Return to competitive play after hamstring injuries involving disruption of the central tendon. *Am J Sports Med.* 2013;41:111-115.
5. Connell DA, Schneider-Kolsky ME, Hoving JL, et al. Longitudinal study comparing sonographic and MRI assessments of acute and healing hamstring injuries. *AJR Am J Roentgenol.* 2004;183:975-984.
6. Crema MD, Yamada AF, Guermazi A, Roemer FW, Skaf AY. Imaging techniques for muscle injury in sports medicine and clinical relevance. *Curr Rev Musculoskelet Med.* 2015;8:154-161.
7. Ekstrand J, Hägglund M, Waldén M. Epidemiology of muscle injuries in professional football (soccer). *Am J Sports Med.* 2011;39:1226-1232.
8. Garrett WE Jr, Califf JC, Bassett FH. Histochemical correlates of hamstring injuries. *Am J Sports Med.* 1984;12:98-103.
9. Gibbs NJ, Cross TM, Cameron M, Houang MT. The accuracy of MRI in predicting recovery and recurrence of acute grade one hamstring muscle strains within same the season in Australian Rules football players. *J Sci Med Sport.* 2004;7:248-258.
10. Gottschall J, Kram R. Ground reaction forces during downhill and uphill running. *J Biomech.* 2005;38:445-452.
11. Koulouris G, Connell D. Hamstring muscle complex: an imaging review. *Radiographics.* 2005;25:571-586.
12. Lempainen L, Banke IJ, Johansson K, et al. Clinical principles in the management of hamstring injuries. *Knee Surg Sports Traumatol Arthrosc.* 2015;23:2449-2456.
13. Lempainen L, Sarimo J, Heikkilä J, Mattila K, Orava S. Surgical treatment of partial tears of the proximal origin of the hamstring muscles. *Br J Sports Med.* 2006;40:688-691.
14. Lempainen L, Sarimo J, Mattila K, Heikkilä J, Orava S. Distal tears of the hamstring muscles: review of the literature and our results of surgical treatment. *Br J Sports Med.* 2007;41:80-83.
15. Opar DA, Williams MD, Timmins RG, Dear NM, Shield AJ. Knee flexor strength and bicep femoris electromyographical activity is lower in previously strained hamstrings. *J Electromyogr Kinesiol.* 2013;23:696-703.
16. Orava S, Kujala UM. Rupture of the ischial origin of the hamstring muscles. *Am J Sports Med.* 1995;23:702-705.
17. Orchard J. Management of muscle and tendon injuries in footballers. *Aust Fam Physician.* 2003;32:489-493.
18. Padulo J, Powell D, Milia R, Ardigo L. A paradigm of uphill running. *PLoS One.* 2013;8:e69006.
19. Pollock N, James SL, Lee JC, Chakraverty R. British athletics muscle injury classification: a new grading system. *Br J Sports Med.* 2014;48:1347-1351.
20. Sallay PI, Friedman RL, Coogan PG, Garrett WE. Hamstring muscle injuries among water skiers: functional outcome and prevention. *Am J Sports Med.* 1996;24:130-136.
21. Sarimo J, Lempainen L, Mattila K, Orava S. Complete proximal hamstring avulsions: a series of 41 patients with operative treatment. *Am J Sports Med.* 2008;36:1110-1115.
22. Seward H, Orchard J, Hazard H, Collinson D. Football injuries in Australia at the elite level. *Med J Aust.* 1993;159:298-301.
23. Sherry M. Examination and treatment of hamstring related injuries. *Sports Health.* 2012;4:107-114.
24. Sherry MA, Best TM. A comparison of 2 rehabilitation programs in the treatment of acute hamstring strains. *J Orthop Sports Phys Ther.* 2004;34:116-125.
25. Sonnerly-Cottet B, Daggett, Gardon R, Pupim B, Clechet J, Thauat M. Surgical management of recurrent musculotendinous hamstring injury in professional athletes. *Orthop J Sports Med.* 2015;3:2325967115606393.
26. Woodley SJ, Mercer SR. Hamstring muscles: architecture and innervation. *Cells Tissues Organs.* 2005;179:125-141.
27. Woods C, Hawkins RD, Maltby S, Hulse M, Thomas A, Hodson A. The Football Association Medical Research Programme: an audit of injuries in professional football—analysis of hamstring injuries. *Br J Sports Med.* 2004;38:36-41.