

Original Article

Socioeconomic and regional differences in the treatment of cervical spondylotic myelopathy

Sheri K. Palejwala, Anand I. Rughani¹, G. Michael Lemole Jr., Travis M. DumontDivision of Neurosurgery, Banner University Medical Center, Tucson, Arizona, USA, ¹Maine Medical Partners, Neurosurgery and Spine, Scarborough, Maine, USAE-mail: *Sheri K. Palejwala - Spalejwala@gmail.com; Anand I. Rughani - Arughani@mmc.org; G. Michael Lemole Jr. - Mlemole@surgery.arizona.edu;Travis M. Dumont - Tdumont@surgery.arizona.edu

*Corresponding author

Received: 01 December 16 Accepted: 02 March 17 Published: 26 May 17

Abstract

Background: Cervical spondylotic myelopathy (CSM) is the leading cause of spinal cord dysfunction in the world. Surgical treatment is both medically and economically advantageous, and can be achieved through multiple approaches, with or without fusion. We used the Nationwide Inpatient Sample (NIS) database to better elucidate regional and socioeconomic variances in the treatment of CSM.

Methods: The NIS database was queried for elective admissions with a primary diagnosis of CSM (ICD-9 721.1). This was evaluated for patients who also carried a diagnosis of anterior (ICD-9 81.02) or posterior cervical fusion (ICD-9 81.03), posterior cervical laminectomy (ICD 03.09), or a combination. We then investigated variances including regional trends and disparities according to hospital and insurance types.

Results: During 2002–2012, 50605 patients were electively admitted with a diagnosis of CSM. Anterior fusions were more common in Midwestern states and in nonteaching hospitals. Fusion procedures were used more frequently than other treatments in private hospitals and with private insurance. Median hospital charges were also expectedly higher for fusion procedures and combined surgical approaches. Combined approaches were found to be significantly greater in patients with concurrent diagnoses of ossification of the posterior longitudinal ligament (OPLL) and CSM. Ultimately, there has been an increased utilization of fusion procedures versus nonfusion treatments, over the past decade, for patients with cervical myelopathy.

Conclusions: Fusion surgery is being increasingly used for the treatment of CSM. Expensive procedures are being performed more frequently in both private hospitals and for those with private insurance, whereas the most economical procedure, posterior cervical laminectomy, was underutilized.

Key Words: Cervical spondylotic myelopathy, disparity, nationwide inpatient sample, regional, spine fusion, socioeconomic

Access this article online

Website:www.surgicalneurologyint.com**DOI:**

10.4103/sni.sni_471_16

Quick Response Code:

This is an open access article distributed under the terms of the Creative Commons Attribution-NonCommercial-ShareAlike 3.0 License, which allows others to remix, tweak, and build upon the work non-commercially, as long as the author is credited and the new creations are licensed under the identical terms.

For reprints contact: reprints@medknow.com

How to cite this article: Palejwala SK, Rughani AI, Lemole GM Jr, Dumont TM. Socioeconomic and regional differences in the treatment of cervical spondylotic myelopathy. *Surg Neurol Int* 2017;8:92.

<http://surgicalneurologyint.com/Socioeconomic-and-regional-differences-in-the-treatment-of-cervical-spondylotic-myelopathy/>

INTRODUCTION

Cervical spondylotic myelopathy (CSM) is the leading cause of spinal cord dysfunction worldwide.^[7,11] It is an age-related and progressive degradation of the cervical spine characterized by disk degeneration, buckling, and hypertrophy of the ligamentum flavum, loss of natural cervical lordosis, and the development of osteophytic spurs that lead to stenosis of the cervical canal with compression of the cervical spinal cord.^[2,6] Without surgical intervention, 20–60% of those with mild CSM will deteriorate over time.^[8,13]

The surgical treatment options are centered around decompression with or without stability augmentation through fusion. There are multiple surgical approaches for the disease including anterior (anterior cervical discectomy and fusion or corpectomy), posterior (laminectomy, laminectomy and fusion, or laminoplasty), and combined approaches.^[14,15,23] Defining a superior approach or developing an algorithm for the surgical treatment of CSM has not been presented in the literature, possibly because the decision-making is complex and dependent on multiple factors including patient pathology, comorbidities, and surgeon preference.^[14,15]

We used the Nationwide Inpatient Sample (NIS), a large, nationwide, multihospital, inpatient database, to evaluate for trends in the surgical techniques used in the treatment of CSM and to elucidate regional or socioeconomic disparities.

MATERIALS AND METHODS

The NIS was queried for elective admissions with a primary diagnosis of CSM (721.1) based on the WHO International Classification of Diseases, Ninth Revision (ICD-9). The years 2002–2012 were assessed because elective admission is a variable which first appeared during this period. A total of 50605 cases were identified. A subset of patients ($n = 182$, <0.4%) with ossification of the posterior longitudinal ligament (OPLL, ICD-9 723.7) as a secondary diagnosis were separately compared to patients without OPLL. Treatment was stratified based on the type of surgery performed, anterior fusion (ICD-9 81.02), posterior fusion (ICD-9 81.03), laminectomy (ICD 03.09), or combinations of anterior and posterior approaches. Cases with upper cervical fusions and thoracolumbar fusions were eliminated ($n = 374$, <0.8%). Revision surgeries were not included in the analysis ($n = 398$, <0.8%). Vague codes such as 80.50–80.51 (discectomy), 80.99 (excision of joint), 81.00 (spinal fusion NOS), 84.51 (insert interbody fusion device), 84.59 (insert spinal device) were excluded from the analysis ($n = 445$, <0.9%). Cases without procedures performed during

admission were eliminated ($n = 1302$, 2.5%). Because of the infrequent use of disk replacement for this pathology (70 cases, <0.2%), these cases were also eliminated from the analysis. In total, 48016 (95%) of all CSM cases identified were included for the analysis.

The treatment strategy was then compared between different hospital types, primary insurer type, and region were compared with Chi-square statistics and are presented as a percentage of the total cases. Mean hospital charges for each treatment strategy were compared with analysis of variance (ANOVA) and presented in US dollars \pm SEM. Statistical analyses were performed using Graphpad Prism (GraphPad Prism version 6.00 for Windows, GraphPad Software, La Jolla California USA, www.graphpad.com).

RESULTS

During 2002–2012, 50605 patients were electively admitted with a primary diagnosis of CSM, and 48016 cases were included for analysis (see above for details). Of these, 7851 (16%) patients had surgery without fusion and 40535 (84%) underwent fusions. In addition, 28465 (59%) had anterior fusions, 14197 (30%) posterior approaches, and 5354 (11%) patients had combined anterior/posterior approaches.

We found that in the Midwest, anterior fusions (64%) were used with relatively greater frequency ($P < 0.0001$) for the treatment of CSM than that in other regions [Figure 1]. Figure 2 shows that 86% of the patients with private insurance who were undergoing elective surgery for cervical myelopathy were treated with fusion procedures as opposed to 82% of those with Medicare or Medicaid ($P < 0.0001$). In nonteaching urban hospitals, fusion procedures were the preferred treatment modality, used in 86% of the elective CSM admissions ($P < 0.0001$), as compared to 83% in teaching hospitals [Figure 3]. Furthermore, anterior approaches were also significantly more common in these nonteaching hospitals (68%) than in teaching hospitals (54%),

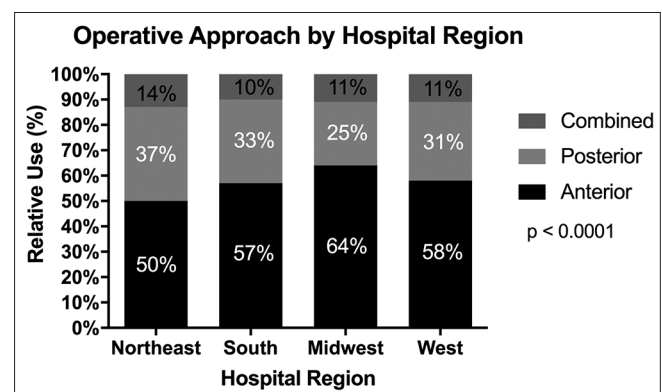


Figure 1: Surgical approach stratified by region

where posterior approaches were nearly 1.5 times more prevalent ($P < 0.0001$) [Figure 4]. Subgroup analysis looking at patients with a diagnosis of CSM and OPLL showed that patients with both diagnoses were over twice as likely ($P < 0.0001$) to undergo combined anterior/posterior approaches than their counterparts without OPLL [Figure 5].

Not surprisingly, hospital charges were greater for posterior fusion surgeries than anterior or nonfusion procedures but were over two and a half times greater for combined anterior-posterior approaches. Fusion procedures were also expectedly associated with higher hospital charges than nonfusion surgeries [Figure 6]. Over the decade queried we found that fusions have become more common than

nonfusion surgeries for the elective treatment of cervical myelopathy [Figure 7].

DISCUSSION

CSM is the leading cause of spinal cord impairment in the world.^[5,6,11,13] It is a progressive, degenerative disease that can lead to hand weakness, gait instability, bowel and bladder dysfunction, and even tetraplegia.^[5,20] The exact prevalence of CSM is unknown, however, it is estimated

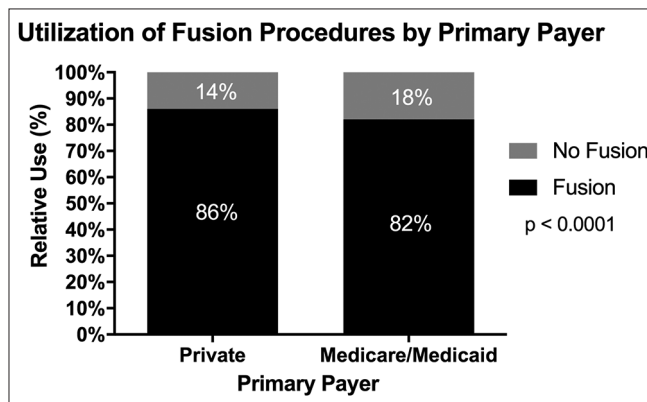


Figure 2: Treatment modality based on insurance type

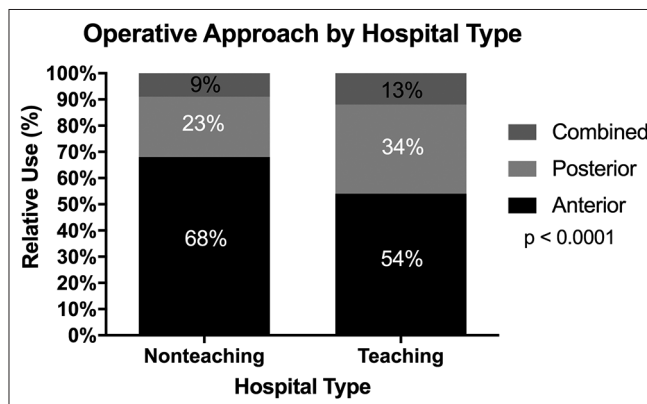


Figure 4: Surgical approach stratified by hospital type

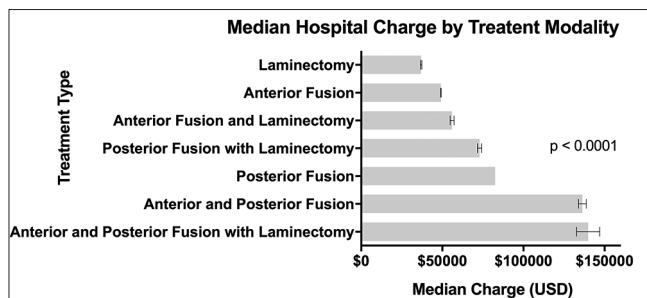


Figure 6: Median hospital charge based on treatment modality

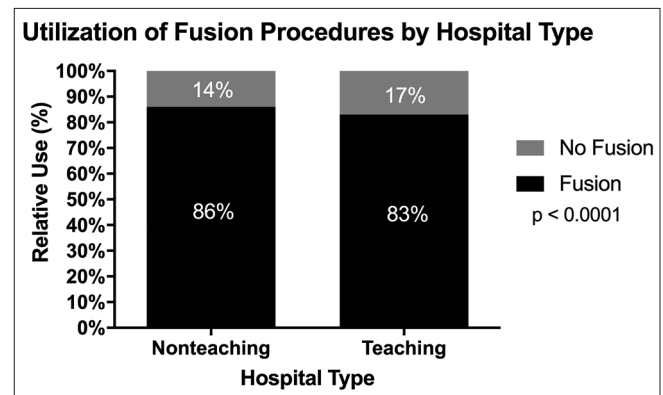


Figure 3: Treatment modality based on hospital type

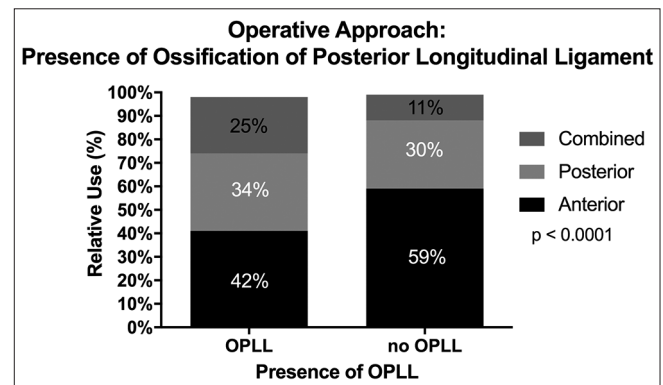


Figure 5: Surgical approach per the presence of OPLL

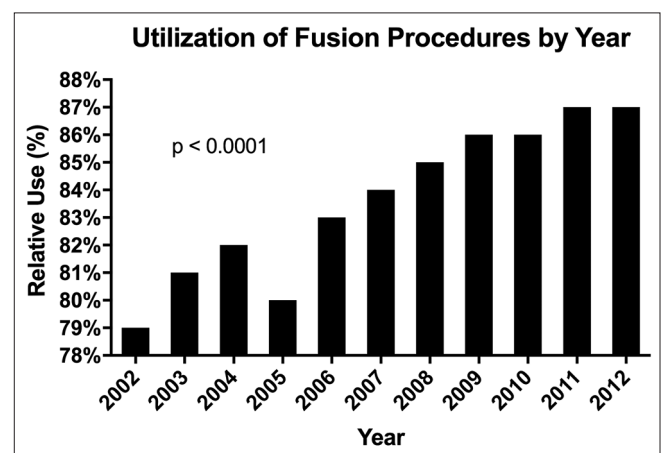


Figure 7: Fusion for CSM treatment from 2002-2012

that 1.6 per 100,000 people have clinically symptomatic CSM requiring surgery.^[3] Furthermore, as spondylosis is an age-related phenomenon and the disease is progressive, the prevalence only stands to increase with our aging population.^[2,13] Considering the widespread nature of the disease and potential severity of symptoms, it is clear why CSM poses such a large healthcare and economic burden.

The natural history of CSM is such that degeneration will progress both over time and exponentially with age. Those with radiographically diagnosed asymptomatic CSM were found to progress to clinical myelopathy at a rate of 8% at 1-year and 23% at 4-year follow-up.^[13] Without surgical intervention, 20–60% of those with mild CSM will deteriorate clinically over 3–6 years on follow-up.^[8,13] In addition, conservative, nonsurgical interventions for CSM were found to be equivocal in the setting of mild myelopathy, and led to inferior outcomes, when compared to surgery, for patients with moderate to severe myelopathy.^[8] Surgery for CSM has proven to be widely successful in terms of health-related outcomes as well as economically with a cost of over \$25000 USD per quality-adjusted life year (QALY).^[5,7,11] Based on the WHO benchmarks, CSM surgery is considered highly cost-effective in terms of life-years garnered.^[5]

The efficacy of decompressive surgery for cervical degenerative myelopathy, in terms of both neurologic functional recovery and long-term health-related outcomes, is well established and widely accepted. The ideal approach, though it is doubtful that such a procedure exists, is the subject of much debate.^[15] Many factors must be taken into account when choosing the appropriate approach in treating CSM, including the directionality of compression, cervical alignment, radiculopathy, axial pain, presence of OPLL, number of levels involved, patient age and comorbidities, and surgeon familiarity and preferences.^[14,15] Anterior options include anterior discectomy and fusion, discectomy without fusion, disk arthroplasty, corpectomy, discectomy-corpectomy hybrids, and multilevel combinations of the above. Posterior approaches include laminectomy alone, skip laminectomy, laminectomy with posterior fusion, and laminoplasty. Finally, combined approaches comprise both an anterior and posterior approach.^[15] Anterior approaches are better for addressing focal anterior osteophytes, focal disk herniations, and retrovertebral disease through corpectomies, for example; however, are also associated with higher rates of dysphagia.^[14,22,23] Alternatively, posterior approaches provide wider canal decompression and allow access to multiple levels simultaneously, but are less effective at correcting kyphotic deformity and are associated with higher rates of infection and peri-operative pain.^[14] There is also a paucity of quality clinical studies that compare pre- and

post-operative outcomes across a variety of anterior and posterior approaches using established outcome measures such as JOA, neck disability index (NDI), and SF-36. Several systematic reviews have been published examining compare anterior versus posterior approaches, and ultimately have found there is clinical equipoise between the various approaches.^[14] There is, however, an ongoing randomized controlled trial comparing anterior and posterior approaches for the treatment of CSM, that might provide greater insight.^[10] Ultimately, surgical decision making for the “ideal” approach in the treatment of CSM is multifaceted and should be dependent on the patient, their pathoanatomy, and comorbidities.^[7,14,15,23]

Surgery for CSM has increased up to 90% in the United States during 1990–2000 based on a survey of the NIS.^[19,24] Similarly, Wang *et al.* described a 206% increase in cervical spine fusions performed in Medicare patients during 1992–2005.^[24] We also describe a 70% increase in all cervical spine surgeries performed specifically for CSM during 2002–2012. There are many hypotheses for this trend, including an aging population, as well as increased expectation of quality of life, expanding indications for cervical surgery, improved diagnostic modalities, and improved surgical techniques.^[19]

Consistent with other studies, we found that anterior fusions were the most common cervical surgery performed; however, in our analysis were found to be more frequent in the Midwest as opposed to the South, which was reported in previous studies.^[19,24] Menger *et al.* noted that surgeons in the Midwest were reimbursed \$1475 per single-level ACDF as compared to spine surgeons in the West (\$849) for the same CPT code, 22551.^[17] This could, in part, explain the statistically higher rate of anterior fusions in the Midwest that we observed.

Furthermore, we found that fusion procedures have significantly higher median hospital charges and are more common in nonteaching urban hospitals and in those with private payer insurance. Fusions are costlier procedures that were performed at a greater frequency in private hospitals (86%) than in teaching institutions (83%). Spine fusions are a consistent and leading source of revenue for hospitals, provided patients are adequately insured and hospital charges can be collected. Hospital reimbursement declines, however, with increased complications and readmissions. Of these fusions procedures, anterior fusions were the most commonly performed subtype. Anterior approaches are widely accepted as efficient and well-reimbursed, and in our study were found to be significantly more common in nonteaching institutions than teaching hospitals.^[11] Conversely, posterior-only and combined approaches were more commonly performed in teaching institutions.^[9,23]

One conjecture for this is that posterior and combined approaches are more cumbersome, requiring longer hospital stays and have a higher rate of complications, and are thus referred to tertiary care centers.^[21]

Fusions were also more common in those with private payer insurance as compared to Medicare or Medicaid. One recent study found that patients with private insurance were 19% more likely to receive an anterior fusion and 17% less likely to receive a posterior-only approach than CMS beneficiaries.^[16] This might be even more exaggerated as Medicare requires cervical spine surgery to be performed on an inpatient basis, whereas private payers allow for outpatient procedures, which would not be captured by our study and could be underrepresented.^[24] Private insurance status was found to be a predictor of anterior cervical fusions for the treatment of CSM, which was also found to be the approach with the lowest mortality.^[4,16] The increased use of fusion surgery in patients with private insurance could be explained by the increased rate of collection of hospital charges from private payers in comparison to Medicare/Medicaid.^[18]

We also found that posterior cervical laminectomy, the most economical treatment modality for CSM, is underused compared to fusion surgeries, irrespective of the approach. This may be, in part, related to studies showing up to a 21% incidence of post-laminectomy kyphosis within 4 years of posterior cervical laminectomy performed for CSM.^[12] Another recent study indicated that posterior-only approaches are associated with a higher rate of mortality, which might also explain the decreased utilization of posterior approaches as compared to anterior fusions.^[4]

The benefit of using the NIS database is the ability to examine large volumes of patients across the United States over a large period. Some of the limitations of this study include those inherent to the NIS, including the potential exclusion of those patients who had ambulatory or outpatient surgery. Moreover, additional radiographic and clinical information about individual patients and cases is not available. Based on an administrative database, our findings are dependent on the accurate coding of both diagnoses and procedures.

CONCLUSION

Overall, there is clinical equipoise regarding the surgical approach when treating CSM. There are regional and socioeconomic differences in the utilization of anterior and posterior approaches for the surgical treatment of CSM. The most common approach is an anterior fusion surgery whereas the most economical approach is

posterior laminectomy alone, which is also the least used surgical treatment modality.

Financial support and sponsorship

Nil.

Conflicts of interest

There are no conflicts of interest.

REFERENCES

- Alvin MD, Lubelski D, Abdullah KG, Whitmore RG, Benzel EC, Mroz TE. Cost-utility analysis of anterior cervical discectomy and fusion with plating (ACDFP) versus posterior cervical foraminotomy (PCF) for patients with single-level cervical radiculopathy. *Spine J* 2013;13:120S-1.
- Baptiste DC, Fehlings MG. Pathophysiology of cervical myelopathy. *Spine J* 2006;6:190S-7.
- Boogaarts HD, Bartels RHM. Prevalence of cervical spondylotic myelopathy. *Eur Spine J* 2013;24:139-41.
- David Kaye I, Marascalchi BJ, Macagno AE, Lafage VA, Bendo JA, Passias PG. Predictors of morbidity and mortality among patients with cervical spondylotic myelopathy treated surgically. *Eur Spine J* 2015;24:2910-7.
- Fehlings MG, Jha NK, Hewson SM, Massicotte EM, Kopjar B, Kalsi-Ryan S. Is surgery for cervical spondylotic myelopathy cost-effective? A cost-utility analysis based on data from the AOSpine North America prospective CSM study. *J Neurosurg Spine* 2012;17:89-93.
- Fehlings MG, Tetreault L, Wilson JR, Skelly AC. Cervical spondylotic myelopathy: Current state of the art and future directions. *Spine* 2013;38:S1-8.
- Fehlings MG, Wilson JR, Kopjar B, Yoon ST, Arnold PM, Massicotte EM, et al. Efficacy and Safety of Surgical Decompression in Patients with Cervical Spondylotic Myelopathy. *J bone Jt Surg Am* 2013;95:1651.
- Fehlings MG, Wilson JR, Yoon ST, Rhee JM, Shamji MF, Lawrence BD. Symptomatic progression of cervical myelopathy and the role of nonsurgical management: A consensus statement. *Spine* 2013;38:S19-20.
- Fineberg SJ, Oglesby M, Patel A, Pelton M, Singh K. Outcomes of cervical spine surgery in teaching and non-teaching hospitals. *Spine* 2013;38:1089-96.
- Ghogawala Z, Benzel EC, Heary RF, Riew KD, Albert TJ, Butler WE, et al. Cervical spondylotic myelopathy surgical trial: Randomized, controlled trial design and rationale. *Neurosurgery* 2014;75:334-46.
- Kalsi-Ryan S, Singh A, Massicotte EM, Arnold PM, Brodke DS, Norvell DC, et al. Ancillary outcome measures for assessment of individuals with cervical spondylotic myelopathy. *Spine* 2013;38:S111-22.
- Kaptain GJ, Simmons NE, Replogle RE, Pobereskin L. Incidence and outcome of kyphotic deformity following laminectomy for cervical spondylotic myelopathy. *J Neurosurg* 2000;93:199-204.
- Karadimas SK, Erwin WM, Ely CG, Dettori JR, Fehlings MG. Pathophysiology and natural history of cervical spondylotic myelopathy. *Spine* 2013;38:S21-36.
- Lawrence BD, Jacobs WB, Norvell DC, Hermsmeyer JT, Chapman JR, Brodke DS. Anterior versus posterior approach for treatment of cervical spondylotic myelopathy: A systematic review. *Spine* 2013;38:S173-82.
- Lawrence BD, Shamji MF, Traynelis VC, Yoon ST, Rhee JM, Chapman JR, et al. Surgical management of degenerative cervical myelopathy: A consensus statement. *Spine* 2013;38:S171-2.
- McClelland III S, Marascalchi BJ, Passias PG, Protopsaltis TS, Frempong-Boadu AK, Errico TJ. Impact of Race and Insurance Status on Surgical Approach for Cervical Spondylotic Myelopathy in the United States: A Population-Based Analysis. *Spine* 2016 [Epub ahead of print].
- Menger RP, Wolf ME, Kukreja S, Sin A, Nanda A. Medicare payment data for spine reimbursement; important but flawed data for evaluating utilization of resources. *Surg Neurol Int* 2015;6:S391-7.
- Molina CA, Zadnik PL, Gokaslan ZL, Witham TF, Bydon A, Wolinsky JP, et al. A cohort cost analysis of lumbar laminectomy - Current trends in surgeon and hospital fees distribution. *Spine J* 2013;13:1434-7.
- Patil PG, Turner D, Pietrobon R. National trends in surgical procedures for

- degenerative cervical spine disease: 1990-2000. *Neurosurgery* 2005;57:753-8.
20. Rao R. Neck pain, cervical radiculopathy, and cervical myelopathy: Pathophysiology, natural history, and clinical evaluation. *Instr Course Lect* 2002;52:479-88.
 21. Shamji MF, Cook C, Pietrobon R, Tackett S, Brown C, Isaacs RE. Impact of surgical approach on complications and resource utilization of cervical spine fusion: A nationwide perspective to the surgical treatment of diffuse cervical spondylosis. *Spine J* 2009;9:31-8.
 22. Shamji MF, Cook C, Tackett S, Brown C, Isaacs RE. Impact of preoperative neurological status on perioperative morbidity associated with anterior and posterior cervical fusion. *J Neurosurg Spine* 2008;9:10-6.
 23. Shamji MF, Massicotte EM, Traynelis VC, Norvell DC, Hermsmeyer JT, Fehlings MG. Comparison of anterior surgical options for the treatment of multilevel cervical spondylotic myelopathy: A systematic review. *Spine* 2013;38:S195-209.
 24. Wang MC, Kreuter W, Wolfla CE, Maiman DJ, Deyo R. Trends and variations in cervical spine surgery in the United States: Medicare beneficiaries, 1992 to 2005. *Spine* 2009;34:955-61