



Integrating clinical research in an operative screening and diagnostic breast imaging department: First experience, results and perspectives using microwave imaging

Daniel Álvarez Sánchez-Bayuela^{a,b,*}, Rubén Giovanetti González^a, Paul Martín Aguilar Angulo^a, Lina Marcela Cruz Hernández^a, María del Pilar Sánchez-Camacho González-Carrato^a, Ana Rodríguez Sánchez^a, Gianluigi Tiberi^{c,d}, Cristina Romero Castellano^a

^a Breast Imaging Department, Radiology Service, Complejo Hospitalario Universitario de Toledo, 45007, Toledo, Spain

^b Faculty of Chemical Science and Technology, Instituto Regional de Investigación Científica Aplicada, University of Castilla, La Mancha, 13001, Ciudad Real, Spain

^c UBT—Umbria Bioengineering Technologies, 06081, Perugia, Italy

^d School of Engineering, London South Bank University, London, SE1 0AA, United Kingdom

ARTICLE INFO

Keywords:

Breast lesions
Microwave breast imaging
Microwave imaging
Breast imaging research
Breast cancer

ABSTRACT

Rationale and objectives: Clinical research is crucial for evaluating new medical procedures and devices. It is important for healthcare units and hospitals to minimize the disruptions caused by conducting clinical studies; however, complex clinical pathways require dedicated recruitment and study designs.

This work presents the effective introduction of novel microwave breast imaging (MBI), via MammoWave apparatus, into the clinical routine of an operative screening and diagnostic breast imaging department for conducting a multicentric clinical study.

Materials and methods: Microwave breast imaging, using MammoWave apparatus, was performed on volunteers coming from different clinical pathways. Clinical data, comprising demographics and conventional radiologic reports (used as reference standard), was collected; a satisfaction questionnaire was filled by every volunteer. Microwave images were analyzed by an automatic clinical decision support system, which quantified their corresponding features to discriminate between breasts with no relevant radiological findings (NF) and breasts with described findings (WF).

Results: Conventional breast imaging (DBT, US, MRI) and MBI were performed and adapted to assure best clinical practices and optimum pathways. 180 volunteers, both symptomatic and asymptomatic, were enrolled in the study. After microwave images' quality assessment, 48 NF (15 dense) and 169 WF (88 dense) breasts were used for the prospective study; 48 (18 dense) breasts suffered from a histology-confirmed carcinoma. An overall sensitivity of 85.8 % in breasts lesions' detection was achieved by the microwave imaging apparatus.

Conclusion: An optimum recruitment strategy was implemented to assess MBI. Future trials may show the clinical usefulness of microwave imaging, which may play an important role in breast screening.

* Corresponding author. Breast Imaging Department, Radiology Service, Complejo Hospitalario Universitario de Toledo, 45007, Toledo, Spain.
E-mail addresses: Daniel.alvarez@uclm.es, dalvarez@sescam.jccm.es (D. Álvarez Sánchez-Bayuela).

1. Introduction

Breast cancer (BC) is the most prevalent form of cancer among women worldwide, with over 2.2 million new cases, and 684,996 associated deaths in 2020 [1]. Health strategies, aimed to reduce BC burden and mortality through early detection and diagnosis, have been implemented through population-based screening (under Regional or National Cancer Control programs) via Full-Field Digital Mammography (FFDM) and, more recently, Digital Breast Tomosynthesis (DBT). Several studies have proved the effectiveness of these breast screening programs [2–4]; but there are some discrepancies between specialists concerning target age ranges, screening frequency and, in general, mammography cost effectiveness, especially in women with dense breasts.

Regular mammographic screening is frequency-limited due to exposure to X-ray ionizing radiation, whose cumulative effect may increase women's risk of developing radiation-induced BC [5]. Premenopausal breast is more sensitive to radiation, leading important organizations like the European Commission Initiative on Breast Cancer (ECIBC) and the United States Preventive Services Task Force suggest regular screening in women between 45 and 74 years old [6,7]. Consequently, younger women are excluded for breast screening programs despite accounting for 18.9 % of BC cases worldwide [1]. Nevertheless, ongoing discussion persists and recently the United States Preventive Service Task Force drafted a recommendation statement to start regular mammographic breast screening at age 40 [8]. Furthermore, some studies indicate that while mammographic screening decreases BC mortality, the issue of over-diagnosis remains uncertain and required further research [9]. Traditional mammography has also shown reduced effectiveness in women with dense breast tissue [10,11]. Although technology advancements such as DBT, detecting BC in women with dense breasts remains challenging, and false positives are still happening due to the high proportion of glandular tissues [12,13]. Additionally, the discomfort and pain experienced during breast compression in mammography serve as important reasons for women to decline regular screening [14]. These limitations highlight the current unmet need for safer mass screening techniques that can overcome the drawbacks of the current gold standard.

Over the last years researchers have increased their attention to new technologies such as Microwave Breast Imaging (MBI) for early cancer detection. These techniques do not require the use of ionizing radiation and are able to discriminate, using radiofrequency (RF) signals, between the dielectric properties of healthy and malignant breast tissues in the spectrum of microwave frequencies [15]. Malignant cells exhibit higher water and bound sodium accumulation compared to healthy cells, resulting in strong scattering of electromagnetic fields associated with greater dielectric properties (conductivity and permittivity) [16–19]. However, introducing MBI into clinical settings has faced several challenges, including limited resolution in non-morphological images, issues of repeatability, standardization of patient positioning and scanning processes, and the absence of large-scale trials to analyze various factors such as breast size, density, and a range of heterogeneous breast lesions [20]. Different MBI prototypes have been started clinical validation [21–24], being MammoWave (UBT srl, Italy) one of them. In 2020, a multicentric, international, prospective study (ClinicalTrials.gov Identifier: NCT04253366) was activated in our center to assess MammoWave's performance for breast lesions detection in the framework of the European Project *Cutting edge microwave imaging device for safe and accurate breast cancer screening* [25].

This paper addresses the first experience of our center with MBI. A dedicated recruitment strategy was developed for assessing the novel microwave breast imaging technique in an operative screening and diagnostic breast imaging department. This work presents the recruitment process in detail with the tailored introduction of the new test to the department clinical pathways. A summary of trials' results is provided; limitations and future perspectives of the novel imaging technique are also discussed.

2. Materials and Methods

2.1. Clinical study

The study was entitled “A multicentric, single arm, prospective, stratified clinical investigation to evaluate the ability of MammoWave in breast lesions detection”. It was activated in 2020 and involved three centers: two sites in Italy, and one in Spain. The study was registered with the U.S. National Library of Medicine (ClinicalTrials.gov NCT04253366).

The study was conducted in accordance with the principles outlined in the Declaration of Helsinki and the guidelines of Good Clinical Practice issued by the International Council for Harmonization (ICH). The investigation protocol was approved by the corresponding Ethics Committee (ID: 440) and the Spanish Agency of Medicines and Medical Devices (ID: 760/19/EC).

This investigation is the first of its type in which symptomatic and asymptomatic women were scanned using novel microwave imaging for breast lesions detection. It was a study designed to evaluate the capability of MammoWave device in distinguishing between breasts without relevant lesions (i.e., BI-RADS 1) and breasts with relevant radiological lesions (i.e., any other BI-RADS category), having as reference conventional imaging. More details about the clinical protocol and overall study results are provided in Refs. [26,27].

2.2. MammoWave microwave breast imaging system

Microwave breast imaging was performed using MammoWave, which works with harmless low-power radiofrequency (RF) signals, instead of ionizing radiation, and does not require breast squishing. The system is composed of two moving (azimuthally) antennas, operating in air, and connected to a vector network analyzer: one transmitting antenna (Tx) that emits the electromagnetic fields in the microwave band (1–9 GHz), and one receiving antenna (Rx), which detects the corresponding scattered fields. Placed on top, there is

an examination table, where the woman lies in prone position inserting her breast (one per scan) in a plexiglass cup to allow a non-compressive and non-invasive imaging test (Fig. 1). Finally, scattered microwave signals are collected from Rx, sent to an external server, and processed through a dedicated imaging algorithm based on Huygens Principle (HP), that renders a two-dimensional intensity map representing the homogeneity of breast tissues' dielectric properties. The system includes a computerized clinical decision support system (CDSS) that performs a dedicated images' analysis to quantify their homogeneity based on several images' features. More acquisition, hardware, and software details are provided in Refs. [27,28].

2.3. Study population

The inclusion and exclusion criteria proposed for the study is included in Table 1. The study enrolled both asymptomatic and symptomatic women with diagnosed breast disease, including benign lesions (such as cysts and fibroadenoma, among others) and malignant tumors (invasive ductal carcinoma, invasive lobular carcinoma, ductal carcinoma in situ). Although not listed as exclusion criteria, certain conditions were agreed by the investigators to avoid microwave images' artifacts due to incorrect acquisition, resulting in the exclusion of women who met the following criteria: bra cup size equal to or larger than C, women with mastectomies or previous breast surgery, and women with disabilities or impairments.

Therefore, the clinical study included six groups of volunteers: (1) asymptomatic women undergoing screening mammogram; (2) symptomatic women with a pre-diagnosed breast cancer (histological assessment available at least 7 days before the MammoWave exam); (3) symptomatic women with a post-diagnosed breast cancer (core needle biopsy performed after the MammoWave exam); (4) symptomatic women with any benign condition (not biopsied) under imaging follow-up; (5) symptomatic women with a pre-diagnosed benign condition (histological assessment available at least 7 days before the MammoWave exam); and (6) symptomatic women with a post-diagnosed benign breast condition (core needle biopsy performed after the MammoWave exam).

It is important to mention that a minimum of 7 days was considered as the required time for women who underwent a biopsy to be included in the study, as biopsy-related hematoma could distort the imaging results. Microwave signals caused by the high dielectric constant of blood could lead to undesired regions of interest (ROIs) in microwave images that are not associated with actual lesions.

2.4. Clinical pathways and volunteers' recruitment

A dedicated approach was developed to integrate Microwave Breast Imaging (MBI) into the routine clinical practice of the Breast Imaging Department for conducting this clinical investigation. The primary objective was to minimize the impact of adding an extra examination (MBI) to the traditional imaging workflow by reducing patient time and stress. Efficiently optimizing clinical pathways and resources played a crucial role in the successful execution of the study, especially given the high workload of the public institution where it was conducted. All enrolled women had already undergone initial imaging using conventional techniques, as required by the inclusion criteria, which was later supplemented with additional clinical information, if available.

Formally, the Breast Imaging Department follows three distinct imaging pathways for women:

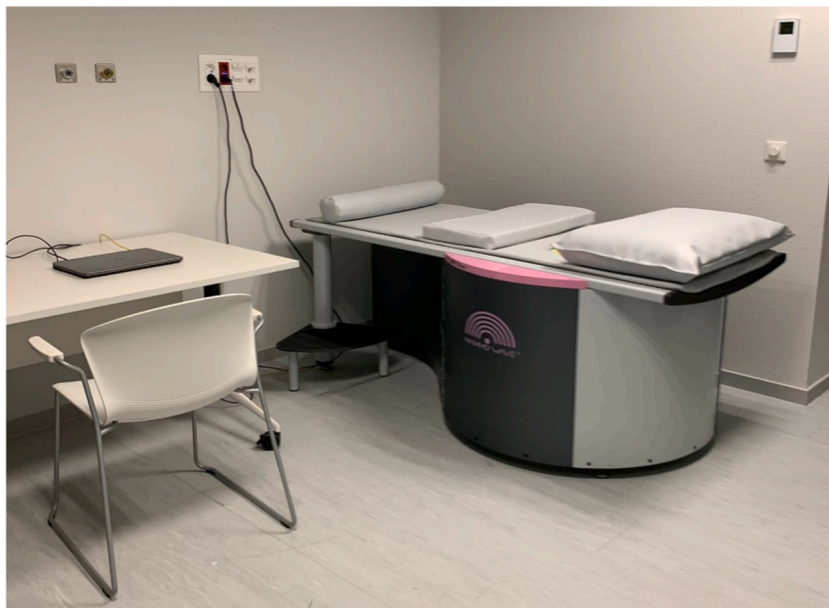

Fig. 1. MammoWave system, installed at Breast Imaging Department.

Table 1
Inclusion and exclusion criteria for clinical study.

Inclusion Criteria
1. Women.
2. Adult (≥18 years old).
3. With signed informed consent form.
4. Having a reported radiological study from any conventional exam within the last month, including digital full-field mammography and/or digital breast tomosynthesis, and/or ultrasonography and/or magnetic resonance imaging.
5. Having intact breast skin.
6. Volunteer willing to comply clinical study recommendations and protocol.
Exclusion criteria
1. Women enrolled in any other clinical study.
2. Belonging to any vulnerable group.
3. Women with implanted electronics.
4. Women who undergone breast biopsy less than 7 days before MammoWave test.
5. Women with breast implants.
6. Women with nipple piercings (if removed before MammoWave scan, it does not constitute an exclusion criteria).
7. Women included in any other clinical study within the last month prior to MammoWave test.
8. Pregnant or breastfeeding women.

1. The Regional Breast Screening Program for biennial regular screening in asymptomatic women age between 45 and 70 years [29]. It involves independent double reading of mammograms by expert breast radiologists using Digital Breast Tomosynthesis, with arbitration. If further examination is deemed necessary, women are recalled for additional tests. Otherwise, a letter is sent to inform women of their mammogram results.
2. An opportunistic clinical circuit that caters to women (with age below 45 or above 70 years old) who have noticed any breast lumps or other symptoms and seek medical attention for evaluation.
3. A pathologic clinical circuit intended for women (in screening age) with suspicious findings or confirmed breast diseases who require additional imaging for accurate diagnosis.

In order to meet the requirements of the study protocol, the latter two clinical pathways were primarily utilized for recruiting volunteers. However, women who had undergone a screening mammogram within the previous month were also invited to voluntarily participate in the trial. This included both women with normal results (asymptomatic or confirmed benign condition) and those suspected of having or later confirmed to have carcinoma. Recruitment and the execution of MBI for these participants were conducted according to the specific clinical pathways outlined below:

- (1) Women with a negative screening mammogram (BI-RADS 1) underwent MBI after their initial mammogram. Recruitment for this group was achieved through an effective study dissemination strategy. Women who were aware of the study (through media, press, or word-of-mouth) and expressed their willingness to participate contacted the Breast Imaging Department. An appointment was then scheduled for them to undergo MBI after their screening mammogram results were reviewed.

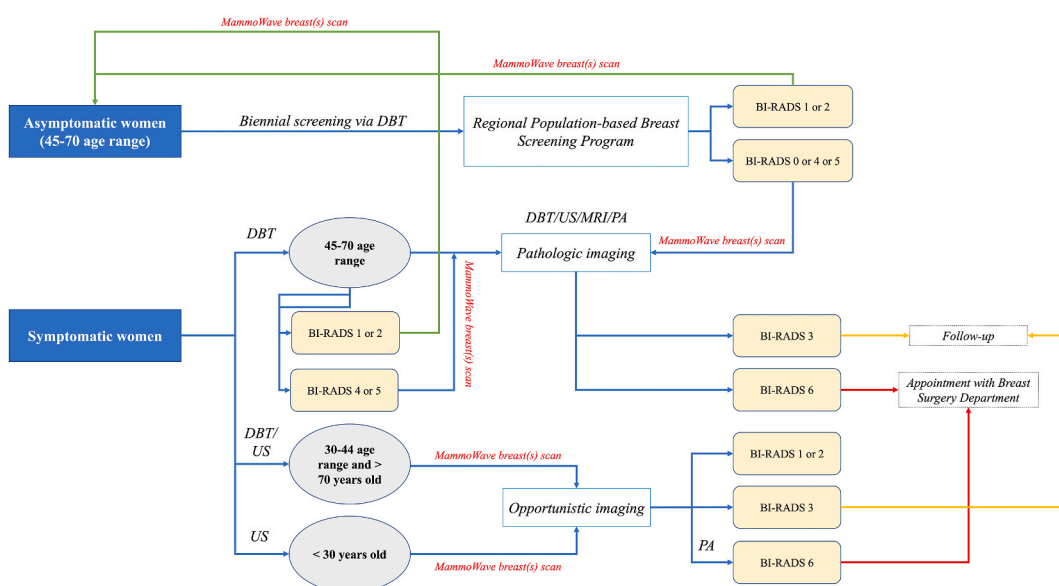


Fig. 2. Flow chart of recruitment process and MBI realization under Department's clinical pathways.

- (2) Women with pre-diagnosed breast cancer (confirmed through core needle biopsy with available histological assessment at least 7 days prior to the MammoWave exam) underwent MBI on the same day before their staging MRI.
- (3) Women with suspicious lesions and no prior diagnosis underwent a comprehensive diagnostic pathway in a single visit. This involved diagnostic DBT, and ultrasound examinations followed by MBI prior to the corresponding core needle biopsy.
- (4) Women with any benign condition (not requiring biopsy) undergoing imaging follow-up were scanned with MBI on the same day as their scheduled follow-up imaging test
- (5) Women with pre-diagnosed benign conditions (confirmed through core needle biopsy with available histological assessment at least 7 days before the MammoWave exam) underwent MBI on the same day after their follow-up or screening mammogram.
- (6) Women with benign breast conditions requiring core needle biopsy were scanned with MBI on the same day before the scheduled biopsy procedure.

By following this recruitment and MBI execution procedures, the study ensured the inclusion of participants from various clinical pathways while adhering to the study protocol. A detailed diagram about the clinical trials' procedure and clinical pathways is reported in Fig. 2.

The recruiter, who was a radiologist from the investigators' group, ensured that each participant met the inclusion criteria and did not have any exclusion criteria. A comprehensive explanation of the clinical protocol, study purpose, device functioning, and technology was provided to each participant. Women who agreed to participate in the study signed and dated the informed consent form.

Subsequently, each participant underwent the MammoWave examination in both breasts if they agreed to it. Each scan had a duration of 13 min, including the overall examination time, which included study explanations and participant questions, totaling approximately 30 min. The microwave data obtained during the examination was automatically transferred to an external server for image reconstruction and analysis. The processing time for each acquisition was approximately 10 min. A report consisting of a set of 2D images in the coronal plane and the corresponding final output automatically generated by MammoWave's CDSS software, indicating either "breast with no finding" or "breast with finding," was sent back to the MammoWave PC unit.

Furthermore, each volunteer was asked to report any adverse events and was required to complete a satisfaction questionnaire regarding their experience with MammoWave. The questionnaire included inquiries about pleasantness, pain, comfort, and duration. Additionally, all these parameters were evaluated in comparison to DBT. The Net Promoter Score index, which ranges from 0 to 10, was also collected. One week after the MBI scan, participants were followed up to monitor for any adverse events that may have occurred.

It is important to note that clinical decisions were based on the conventional and standard radiological reports.

2.5. Conventional imaging assessment: radiological and histological data collection

The main objective of the study was to assess MammoWave's sensitivity for any breast lesion, including malignant lesions (BC). For this purpose, conventional imaging techniques were taken as reference, collecting BI-RADS assessment (ACR standards, 5th edition [30]), as well as histology and immunohistochemistry (when available). Each breast was classified into one of two groups: breasts without any radiological findings (referred to as BI-RADS 1) and breasts with radiological findings, categorized as clearly benign (BI-RADS 2), in follow-up (BI-RADS 3), or confirmed malignant (BI-RADS 6). Intermediate BI-RADS categories (4, 4 A, 4 B, 4C) observed in conventional imaging exams underwent additional examinations following the protocols and guidelines of the Department.

In this paper, breasts without radiological findings are referred to as "NF" (non-findings), while breasts with relevant radiological findings are referred to as "WF" (with findings). Conventional imaging was performed using Digital Breast Tomosynthesis (Selenia Dimensions System, Hologic), Ultrasonography (Epiq 7, Philips), and Magnetic Resonance Imaging (3T Magnetom Vida, Siemens). Additional procedures for histologic and immunohistochemistry assessments followed established clinical standards. Breast samples were obtained through US-guided fine needle aspiration biopsy, US-guided core needle biopsy, and stereotactic (mammography-guided) breast biopsy.

To ensure data privacy and adherence to the protocol and International Council for Harmonization of Technical Requirements for Pharmaceuticals for Human Use - Good Clinical Practice (ICH-GCP) guidelines, a data capture system utilizing an electronic case report form (eCRF) was employed in this study. All collected data is anonymized, and each participant is identified by a subject number.

2.6. Microwave breast imaging assessment

The clinical study was conducted in two phases. Phase 1 involved scanning a set of breasts without radiological findings (NF) to calibrate MammoWave's CDSS software. This calibration process established thresholds for distinguishing between NF and breasts with relevant radiological findings (WF). In Phase 2, the prospective assessment of the MammoWave device was carried out. The presence of radiological findings in microwave images was automatically quantified by evaluating the non-homogeneous behavior using various features. Binary scores were then utilized as a rule-of-thumb to differentiate between negative (NF) and positive (WF) breasts, as already introduced in Ref. [28]. In this prospective study, investigators were not required to read or interpret any microwave image.

2.7. Data analysis and results

Upon completion of the clinical study recruitment, the data analysis was conducted by a Clinical Research Organization (Medical Trials Analysis Swiss SA, Lugano, Switzerland). Two datasets were defined for the analysis: the full analysis dataset (FAS), which included volunteers' information and corresponding MammoWave's output from phase 2 participants, and the per protocol dataset (PPS), which comprised data from phase 2 clinical trials, excluding microwave exams discarded by a central assessor. An independent scientist, acting as the central assessor, reviewed the reconstructed microwave images without access to the reference standard information. Any spurious peaks or image artifacts in the MammoWave images were identified, leading to the exclusion of those exams (with "spurious peaks" we indicate a peak which is out of scale as defined in our previous clinical trials [28]). The performance of MammoWave in breast lesion detection was evaluated by calculating the sensitivity (true-positive rate) and specificity (true-negative rate) among other metrics, comparing MammoWave against the reference standard. Stratification based on breast density was also performed. Additionally, the percentage of correctly localized breast lesions in terms of quadrants was measured by comparing MammoWave's output images with the reference standard images (DBT, US, and/or MRI). The assessment focused on three scenarios to determine MammoWave's ability to accurately localize breast lesions in relation to conventional imaging exams: complete match, partial match, and no match. A complete match was recorded when both the conventional imaging and MBI identified lesions in the same quadrants. A partial match was noted when the lesion matched in at least one quadrant.

3. Results

The Breast Imaging Department of our Hospital integrated microwave breast imaging into its clinical routine as a complementary technique for participants in a research study. A total of 180 participants, with a mean age of 49 ± 10 (SD), ranging from 20 to 78 years old, were recruited for the clinical investigation and underwent MBI. Phase 1 of the trials involved 15 women with NF breasts, while phase 2 included 165 volunteers with both NF and WF breasts, prospectively evaluated in comparison to conventional imaging. In phase 2, microwave images were collected from 322 breasts, with 157 volunteers undergoing MammoWave examination on both breasts and 8 subjects on one breast only. No deviations in the inclusion/exclusion criteria were observed, and there were no adverse events during the MammoWave scanning.

Conventional radiologic studies were performed on all the subjects, including DBT on 174 subjects (96.6 %), US on 159 subjects (88.3 %), MRI on 70 subjects (38.3 %), and histologic assessment in 82 subjects (45.5 %). Phase 1 of the clinical study involved 15 volunteers whose both breasts were scanned using MammoWave. According to radiologic reports, 95 NF breasts (34 dense) and 227 WF breasts (123 dense) were analyzed and compared with MammoWave's output in phase 2 of the study (322 breasts in total). A central assessor discarded 118 breasts, included both in phase 1 and 2, due to the presence of images' artifacts, resulting in the Per Protocol dataset (PPS) used for the final analysis. A significant portion of the initially collected breast cases (118 out of 352) were discarded, accounting for more than one third of the dataset. Further details about the study population are provided in Table 2.

For instance, considering the Per Protocol dataset, 217 breasts were evaluated in phase 2 of the study: 48 breasts (15 dense) were observed without radiological findings (NF), while 169 breasts (88 dense) exhibited radiological abnormalities according to conventional radiologic studies. Among the WF breasts, 121 (70 dense) were classified as benign, encompassing various conditions such as simple cysts, duct ectasia, solid fibroadenoma nodules, benign microcalcifications, glandular asymmetries, and mammographic architectural distortions later identified as radial scars, sclerosing lesions, adenosis, or fat necrosis. In 48 WF breasts (18 dense), a malignant condition was found, including invasive ductal carcinoma (IDC), invasive lobular carcinoma (ILC), and ductal carcinoma in situ (DCIS). Suspicious nodules with or without associated microcalcifications, asymmetries and mammographic architectural distortions, were biopsied according to Department's clinical protocols. A summary of radiological study review, including final BI-RADS assessment via conventional imaging techniques and histology, is given in Table 3. A wide range of malignant (histology-confirmed) lesions were included in this study, coming from different radiological findings (spiculated, irregular nodules, with/without associated microcalcifications, isolated clusters of microcalcifications, mammographic architectural distortions, etc.) with varying sizes from 5 mm to 80 mm. Table 4 provides a detailed overview of the analyzed malignant lesions in this study, including their MammoWave's rule

Table 2
Summary of recruited volunteers' demographics and radiological study review.

Summary of recruited volunteers' demographics. Number of dense breasts are included in brackets.		
	Full Analysis Set	Per Protocol Set
Total number of volunteers included in the study	180	149
Average age of participants	49	49
Number of participants aged between 20 and 44	59	49
Number of participants aged between 45 and 69	119	99
Number of participants aged >69	2	1
Total number of breasts included in the study	352 (175)	234 (115)
Number of breasts included in phase 1 of the study	30 (18)	17 (12)
Number of breasts included in phase 2 of the study	322 (157)	217 (103)
Summary of radiological study review for the 322 breasts analyzed prospectively in phase 2. Number of dense breasts are included in brackets.		
Number of breasts without radiological findings (NF)	95 (34)	48 (15)
Number of breasts with any radiological finding (WF), including histology-confirmed cancer	227 (123)	169 (88)
Number of breasts with histology-confirmed cancer	62 (23)	48 (18)

Table 3

Summary of the radiological study review by finding typology and BI-RADS assessment; malignant lesions' assessment by histology.

Summary of the radiological study review by DBT and/or US finding typology (WF) of the cases included for comparison with MammoWave (phase 2, PPS). Number of dense breasts (ACR C and D) indicated inside brackets.	
Simple cysts and/or dispersed duct ectasia	92 (51)
Nodules of solid fibroadenoma	16 (12)
Dispersed/grouped microcalcifications	8 (4)
Spiculated nodules with/without associated microcalcifications	43 (14)
Architectural distortions	10 (7)
TOTAL	169 (88)
Summary of the radiologists' final BI-RADS assessment considering DBT and/or US and/or MRI and/or histopathology output of breasts included in the study for comparison with MammoWave (phase 2, PPS). Number of dense breasts (ACR C and D) indicated inside brackets.	
BI-RADS 1	48 (15)
BI-RADS 2	102 (55)
BI-RADS 3	19 (15)
BI-RADS 6	48 (18)
TOTAL	217 (103)
Summary of histological types of cancer collected during the clinical study (phase 2, PPS). In brackets, number of cancers in dense breasts (ACR C and D).	
Ductal Carcinoma in Situ (DCIS)	6 (5)
Invasive Ductal Carcinoma (IDC)	37 (10)
Invasive Lobular Carcinoma (ILC)	5 (3)
TOTAL	48 (18)

of thumb output (i.e., whether the breasts which contain these lesions were classified as WF or NF).

Several compelling clinical cases were examined using both conventional and microwave imaging. As illustrated in Fig. 3-5, three volunteer studies are presented. Each case exhibits three microwave images reconstructed with varying conductivity values (0.3, 0.4, and 0.5 S/m). Additionally, conventional technique images are provided for each case, along with subject-specific details such as age and breast density. The radiologist's study review and findings, histology assessment (including the Nottingham score), and MammoWave's CDSS output are also included to provide a comprehensive analysis of each case. Figs. 3 and 4 depict the case of a 40-year-old woman with ACR D breast density who visited the Breast Imaging Department after discovering a lump in her left breast. In Fig. 3, the healthy right breast is shown with a DBT and US assessment classified as BI-RADS 1. On the other hand, Fig. 4 displays the initial DBT and US evaluation of the left breast, which was classified as BI-RADS 4 A. It reveals an 18 mm oval, circumscribed nodule with uniform hypo echogenicity in the lower outer quadrant. The nodule was subsequently biopsied, and the histology confirmed it to be a fibroadenoma. Fig. 5 depicts the case of a 64-year-old woman with ACR B breast density who was re-called after her screening mammogram due to an architectural distortion (BI-RADS 4C) in the upper outer quadrant and outer interquadrant of the left breast. Ultrasonography depicted a 5 mm nodule highly suggestive of malignancy; MRI showed a pathologic enhancement of $4 \times 4 \times 5$ mm. The nodule was subsequently biopsied, and the histology confirmed it to be a grade I invasive ductal carcinoma. Immunohistochemistry was performed and allowed its assessment as luminal A like cancer. MammoWave's CDSS accurately identified all the presented WF breasts, as evident from the microwave images. The lesions were correctly indicated by a prominent peak, marked by the red arrows. For more examples of malignant conditions collected in this clinical study, refer to Ref. [31].

Table 5 displays the performance of MammoWave's CDSS system in detecting breast lesions compared to the reference standard. The table also includes the sensitivity values for both benign and malignant lesions. In terms of accurately locating lesions, the Per Protocol dataset (PPS) revealed that 33.64 % of the microwave images successfully depicted lesions in the correct quadrants, while in the 29.49 % of cases a partial match occurred.

All participants in the study completed the satisfaction questionnaire, with a unanimous 100 % expressing their willingness to recommend the MammoWave scan. Moreover, an overwhelming 99.4 % of participants felt reassured by this innovative technology and considered themselves sufficiently informed about the MammoWave system and microwave-based technology. The majority of participants found the MammoWave exam to be less unpleasant, painful, and uncomfortable compared to DBT, although they noted that it was longer in duration. The average Net Promoter Score achieved was 9.44, indicating high satisfaction. Detailed responses from the questionnaire can be found in Table 5. Importantly, no adverse events were reported by any of the participants during the follow-up call.

4. Discussion

The Breast Imaging Department of our hospital successfully incorporated microwave breast imaging into its clinical pathways as part of a multicentric, prospective clinical investigation. This study aimed to evaluate the effectiveness of the MammoWave device for detecting breast lesions in both asymptomatic and symptomatic women. Our center accounted for 50.8 % of the total study recruitment across all three sites. Our findings revealed a sensitivity of 85.8 % in detecting breast lesions using the MammoWave device, with a slightly lower sensitivity of 80.7 % in dense breasts. The device demonstrated the ability to accurately classify both benign conditions (85.1 %) and malignant cases (87.5 %) as "lesions". Furthermore, the trial participants provided positive feedback on the MammoWave device, stating that the imaging technique was not unpleasant, not painful, and overall comfortable to undergo. This study represents the initial implementation of microwave breast imaging in our clinical practice, offering promising insights into its potential as a valuable tool for detecting breast lesions. However, further research is needed to establish clear guidelines and determine its optimal

Table 4

Subjects' age, affected breast, breast density, conventional imaging details, histology and immunohistochemistry assessments for malignant conditions included in PPS. Lesions' sizes are provided according to their maximum axis, confirmed by MRI. Following Department protocols, intermediate lesions' BI-RADS assessment is selected by combining DBT and US studies. MammoWave CDSS *rule-of-thumb* output is also provided.

Age	Breast (L or R)	ACR Breast Density	Notes from conventional imaging reports	Lesions' size (in mm)	DBT + US BI-RADS	Histology	Molecular subtype	MammoWave CDSS output
34	R	B	Spiculated nodule in inner interquadrant	17	5	IDC, Grade II	Triple-negative	WF
64	R	A	Spiculated nodule in UO/outer interquadrant	25	4C	ILC, Grade II	Negative e-cadherin	WF
43	L	D	Spiculated nodule in UO quadrant	40	5	IDC, Grade II	n. a.	WF
46	L	C	Arch. Distortion in UI quadrant	14	4 A	ILC, Grade I	Int. Luminal	NF
52	L	C	Two spiculated nodules + microcalcifications in UO quadrant	10, 8	5	IDC, Grade III	n. a.	WF
50	R	B	Multifocal microcalcifications in two groups, dispersed in UO quadrant	16, 10	4 A	IDC, Grade III	Luminal B	NF
43	R	C	Spiculated nodule in outer interquadrant and UO quadrant	31	4C	DCIS, Grade n. a.	n. a.	WF
66	L	A	Spiculated nodule retroareolar	23	5	IDC, Grade II	Int. Luminal	WF
54	R	B	Spiculated nodule in outer interquadrant	64	5	IDC, Grade II	Luminal	WF
67	R	B	Nodular mass in lower interquadrant	8	5	IDC, Grade II	Luminal A	WF
51	L	B	Group of nodules with microcalcifications in outer quadrants	64	5	IDC, Grade II	n. a.	WF
62	L	B	Spiculated nodule in UO quadrant	17	5	IDC, Grade II	n. a.	WF
35	R	B	Two lesions in lower quadrants	40, 8	5	IDC, Grade III	Luminal B	WF
65	R	B	Irregular nodule in LO quadrant	15	4C	IDC, Grade II	n. a.	WF
47	R	C	Irregular nodule in UO quadrant	18	4C	IDC, Grade I	n. a.	WF
46	R	B	Spiculated nodule in LO quadrant	54	5	ILC, Grade II	Int. Luminal	WF
53	R	B	Nodule with associated microcalcifications in upper quadrants	27	5	IDC, Grade III	Luminal A	WF
49	R	A	Spiculated nodule in lower interquadrant	18	5	IDC, Grade II	n. a.	WF
38	L	C	Nodule in UO quadrant	45	4C	IDC, Grade II	Luminal B	NF
59	L	B	Nodule with microcalcifications in LI quadrant	26	5	IDC, Grade III	Her2+	WF
54	L	B	Spiculated nodule with associated microcalcifications in upper quadrants	27	5	IDC, Grade II	Int. Luminal	WF
65	L	B	Spiculated nodule in upper quadrants	16	5	IDC, Grade III	n. a.	WF
57	R	B	Irregular nodule in outer interquadrant	5	4C	IDC, Grade II	Her2+	WF
63	L	B	Two irregular nodules in UO and outer quadrants	25, 18	4C	IDC, Grade II	Triple-negative	WF
52	R	B	Spiculated nodule in upper quadrants	11	5	IDC, Grade I	n. a.	WF
60	R	B	Arch. distortion and microcalcifications in UO quadrant	22	4C	IDC, Grade III	Luminal B	WF
43	L	C	Irregular nodule in outer interquadrant	23	5	IDC, Grade II	Int. Luminal	WF
54	L	C	Spiculated nodule in UO quadrant	35	5	IDC, Grade I	Luminal	WF
46	R	B	High risk microcalcifications in lower interquadrant	n. a.	4 B	DCIS, Grade n. a.	n. a.	WF
66	L	C	Arch. distortion and microcalcifications in UO quadrant	20	4C	DCIS, Grade n. a.	n. a.	WF
44	L	B	Spiculated nodule in UI quadrant	16	5	IDC, Grade II	Int. Luminal	WF
61	R	B	Spiculated nodule in UI quadrant	17	5	IDC, Grade II	n. a.	WF
66	L	D	Cluster of microcalcifications in lower quadrants (mostly in LI)	50	4 B	DCIS, Grade n. a.	n. a.	WF

(continued on next page)

Table 4 (continued)

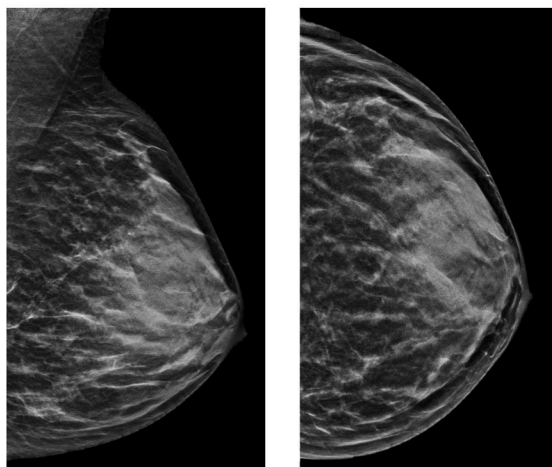
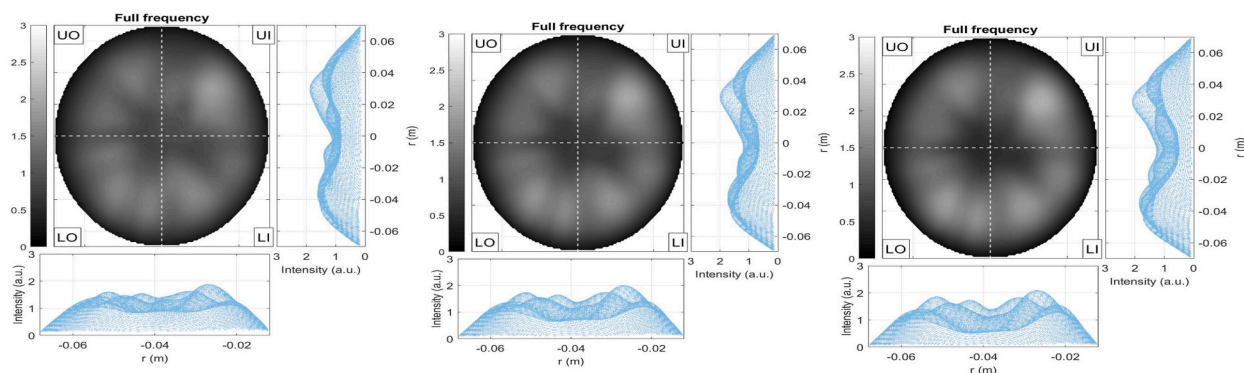
Age	Breast (L or R)	ACR Breast Density	Notes from conventional imaging reports	Lesions' size (in mm)	DBT + US BI-RADS	Histology	Molecular subtype	MammoWave CDSS output
59	L	B	Spiculated nodule in LI quadrant	20	5	IDC, Grade II	Luminal A	WF
37	L	C	Dispersed high risk microcalcifications along UO, LI and upper interquadrant	52	4C	DCIS, Grade n. a.	n. a.	WF
63	R	A	Spiculated nodule in outer interquadrant	13	5	IDC, Grade I	n. a.	WF
49	R	C	Glandular asymmetry in DBT described as nodule in US; located in upper quadrants	20	4C	IDC, Grade II	Luminal	WF
61	L	B	Suspicious nodule in UO quadrant	11	4	IDC, Grade II	Luminal B	WF
60	L	C	Spiculated nodule in retroareolar area	10	5	IDC, Grade I	Int. Luminal	WF
58	L	A	Suspicious mass in retroareolar area	8	4 A	IDC, Grade III	Luminal A	NF
57	L	C	Spiculated nodule in upper and outer interquadrant	80	5	IDC, Grade III	Luminal B	WF
48	L	D	Spiculated nodule in outer interquadrant	13	5	ILC	n. a.	NF
64	L	B	High suspicious mass in outer interquadrant	5	4C	IDC, Grade I	Luminal A	WF
65	L	D	Spiculated nodule in tail and UO quadrant	6	5	IDC, Grade II	n. a.	WF
54	R	C	Arch. distortion in UO quadrant	15	4C	ILC, Grade n. a.	n. a.	NF
63	L	B	Spiculated nodule in UO quadrant	14	5	IDC, Grade I	Luminal A	WF
55	L	C	Arch. distortion and microcalcifications in upper quadrants and retroareolar area	30	4C	DCIS, Grade n. a.	n. a.	WF
55	L	A	Spiculated nodule in UO quadrant	14	5	IDC, Grade I	Luminal A	WF

clinical applications, especially for breast cancer detection.

Microwave imaging-based devices such as MammoWave holds particular promise for breast screening purposes. As introduced, screening asymptomatic women offers numerous benefits, such as early detection and increased chances of survival. Currently, mammography serves as the most effective screening technique for early breast cancer detection in asymptomatic individuals, leading to a reduction in breast cancer-related deaths. Nonetheless, mammography has its drawbacks, including patient discomfort, limited effectiveness in dense breast tissue, and the utilization of ionizing radiation. Nowadays, modern mammographic systems are designed to apply less compressive force during the procedure; however, pain is still reported [32]. Researchers are also exploring the integration of Artificial Intelligence-based systems to assist in reading mammograms, aiming to reduce false positives, alleviate workload, and improve detection capabilities, particularly in dense breast tissue [33–37]. Nevertheless, the utilization of ionizing radiation, even in minimal amounts, continues to be a significant limiting factor when determining screening protocols, including factors such as appropriate age ranges and frequency of tests.

Currently, the scientific community and medical breast societies have not issued any official recommendations regarding the integration of microwave breast imaging into clinical pathways. This is because these emerging technologies are still in the early stages of clinical validation, with various prototypes being evaluated, including the one described in this study [22,38]. Up to date, this work represents the first implementation of MBI in a dedicated workflow aimed at optimizing recruitment and volunteers' experience within the context of a clinical study. However, further dedicated trials are needed to investigate the impact of MBI on cancer detection, its ability to overcome false positives, its effectiveness in dense breast tissue and detection limitations related to artifact issues in microwave images. Additionally, it is crucial to establish standardized clinical terminology and protocols for MBI that can be agreed upon by the scientific community. Mounting clinical evidence about the use of these new technologies, especially regarding its valuable application in clinical settings, may foster organizations such as the American College of Radiology (ACR) to include MBI in its standards. Breast imaging involves the utilization of multiple imaging techniques to screen and diagnose various breast pathologies, often in conjunction with invasive procedures like biopsies. Given the complexity of this field, especially in Breast Imaging Departments' management, it is imperative to conduct dedicated clinical studies to assess the potential gap or clinically useful applications in which microwave imaging systems like MammoWave can be effectively utilized.

Several clinically relevant issues were identified in the presented investigation regarding the use of MammoWave device. Firstly, MammoWave's set-up currently does not fix breast location inside the cup; movements and/or bad positioning may produce artifacts, i. e., spurious peaks, on microwave images (36 % of acquired images in our center were considered "with artifact" and discarded). Thus, we recommend equipping and test MammoWave with dedicated ergonomic cushion to facilitate subject positioning and reducing subjects' severe movements. Also, we recommend to further investigate the origin of these artifacts. Moreover, the axillary region of the breast is not captured within MammoWave's cup, as it is not within the field of view determined by the current configuration of the transmitting and receiving antennas during acquisition. Thus, the detection of positive (cancer-affected) axillary lymph nodes are out of MammoWave's capabilities. Long acquisition times were observed during the trial, as reported by participants, and this may pose a

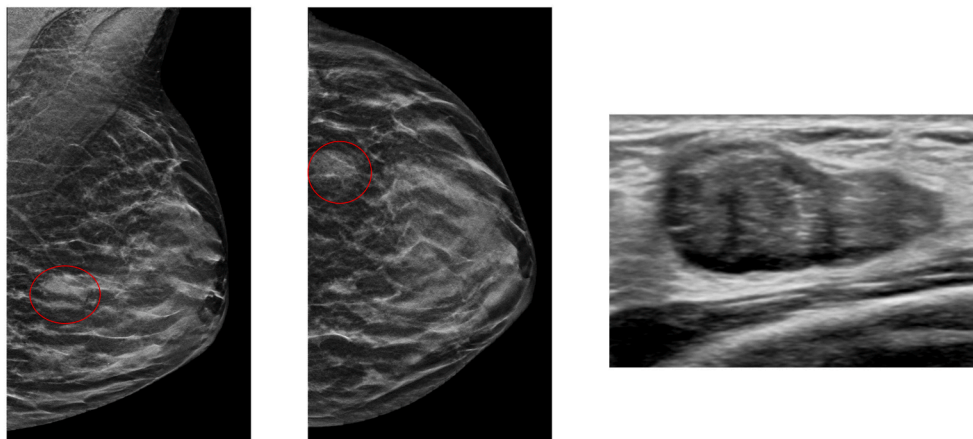
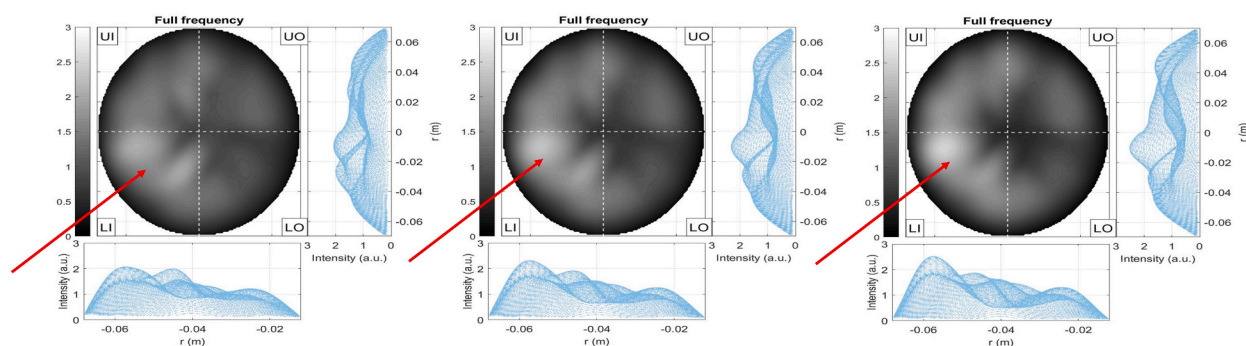


Age	Breast	ACR breast density	DBT BI-RADS	Radiologist' study review	MammoWave's CDSS output
40	Left	D	1	NF	Breast with no finding

Fig. 3. 40 years old woman, mammographic extremely dense (ACR D) left breast, with conventional imaging assessment (DBT and echography) BI-RADS 1. Accordingly, the breast was classified as NF. Microwave images are given for three different reconstructed conductivities (from left to right: 0.3 S/m, 0.4 S/m, and 0.5 S/m, respectively) as 2D intensity maps in coronal plane. Moreover, 1D intensity projection on X and Y is displayed in the inserts. X and Y are given in meters; intensity is in arbitrary units. MammoWave's CDSS classifies this breast as “with no finding”.

limitation for certain applications such as mass screening; however, a novel acquisition configuration has already been implemented and is currently undergoing clinical validation with the aim of reducing the duration of MammoWave scans to just 8 min [39]. Far from conventional imaging, MammoWave offers a set of 2D images representing the homogeneity of breast tissues' dielectric properties. As expected, reconstructed images lack detailed morphological definition (i.e., lesions' shape/size/margins cannot be visually inspected from images), which does not allow lesions' classification; research is ongoing towards morphological definition through optimizing HP reconstruction [40], as well as towards implementing 3D imaging to MammoWave [41]. Moreover, this study did not consider women pre-menstrual information; the influence of tissues' variations or factors, such as weight gain, on microwave imaging requires further investigation.

Finally, future studies should approach the discrimination of benign and malignant lesions via MammoWave, also when applying artificial intelligence, which may enhance MammoWave capabilities for breast imaging [42]. The utilization of artificial intelligence algorithms in microwave-based data, especially through machine learning techniques, may improve the interpretability and efficiency of microwave imaging systems. Currently, two European projects, namely RadioSpin (grant ID 101017098) and MammoScreen (grant ID 101097079) are currently focused on developing, implementing, and clinically validating artificial intelligence-based systems in microwave imaging using the MammoWave device for the dedicated detection of breast cancer. These projects aim to generate scientific evidence supporting the use of MammoWave equipped with AI software, particularly in population-based breast screening programs.



Age	Breast	ACR breast density	DBT + US BI-RADS	Radiologist' study review	Radiologic studies' details	Histologic assessment	MammoWave's CDSS output
40	Right	D	4A	NF	18 mm noduli in LO quadrant	Fibroadenoma	Breast with finding

Fig. 4. 40 years old woman, mammographic extremely dense (ACR D) right breast, with conventional imaging assessment (DBT and echography) BI-RADS 4 A of an 18 mm noduli in lower outer quadrant. Accordingly, the breast was classified as WF. Histologic assessment confirmed this finding as fibroadenoma. Microwave images are given for three different reconstructed conductivities (from left to right: 0.3 S/m, 0.4 S/m, and 0.5 S/m, respectively) as 2D intensity maps in coronal plane. Moreover, 1D intensity projection on X and Y is displayed in the inserts. X and Y are given in meters; intensity is in arbitrary units. All microwave images show a non-homogeneous behavior, with a main peak indicated by the red arrows. MammoWave's CDSS classifies this breast as "with finding". (For interpretation of the references to colour in this figure legend, the reader is referred to the Web version of this article.)

5. Conclusions

Microwave imaging represents a highly promising technology, with systems like MammoWave showing particular relevance in the realm of breast cancer detection. By utilizing harmless low-power radiofrequency signals and employing a non-compressive scan approach, microwave imaging may represent a complementary solution for making screening programs more inclusive, without safety restrictions such as age or frequency of use.

However, in order to fully comprehend the capabilities of microwave imaging and ascertain its optimal role within clinical imaging pathways and healthcare settings, further focused research must be performed. Specifically, comparative studies with conventional imaging techniques, such as mammography, are already planned (also equipping MammoWave with dedicated AI algorithms, trained using data collected in the trials presented here) to evaluate the efficacy of microwave imaging as a standalone or complementary tool for breast cancer screening and diagnosis. In addition, research efforts will be directed towards understanding the cost-effectiveness and practical implementation of microwave imaging in various healthcare settings. This includes considerations of infrastructure requirements, training needs for healthcare professionals, and patient acceptance. By addressing these aspects, we can determine the true value and impact of microwave imaging in improving breast cancer detection rates, enhancing patient outcomes, and ultimately shaping the future of breast imaging practices.

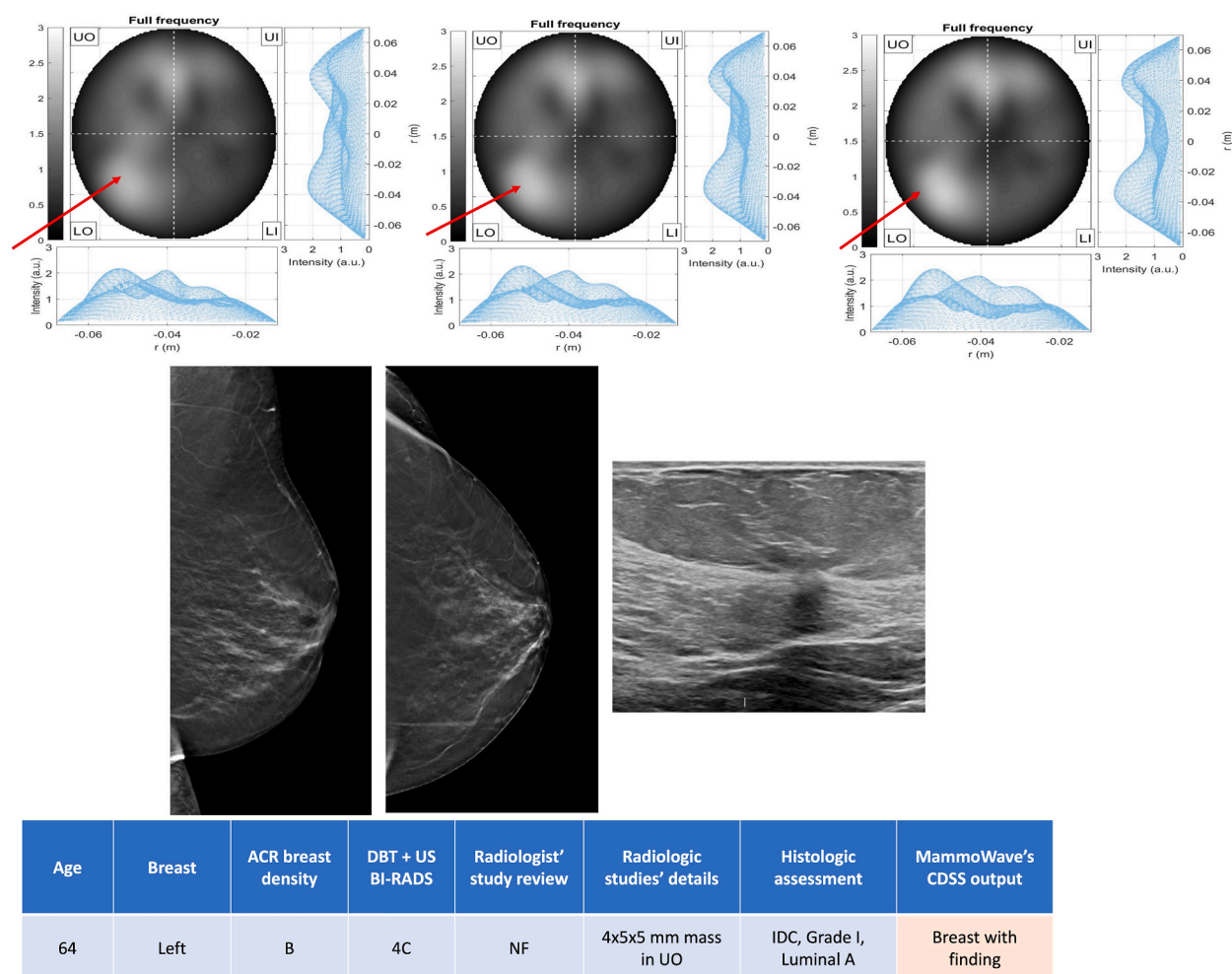


Fig. 5. 64-year-old woman with scattered areas of fibroglandular density (ACR B) who was re-called after her screening mammogram due to an architectural distortion (BI-RADS 4C) in the upper outer quadrant and outer interquadrant of the left breast. Ultrasonography depicted a 5 mm noduli highly suggestive of malignancy; MRI showed a pathologic enhancement of $4 \times 4 \times 5$ mm. Accordingly, the breast was classified as WF. Histologic assessment confirmed it to be a grade I invasive ductal carcinoma; immunohistochemistry classified it as luminal A like cancer. Microwave images are given for three different reconstructed conductivities (from left to right: 0.3 S/m, 0.4 S/m, and 0.5 S/m, respectively) as 2D intensity maps in coronal plane. Moreover, 1D intensity projection on X and Y is displayed in the inserts. X and Y are given in meters; intensity is in arbitrary units. All microwave images show a non-homogeneous behavior, with a main peak indicated by the red arrows. MammoWave's CDSS classifies this breast as "with finding". (For interpretation of the references to colour in this figure legend, the reader is referred to the Web version of this article.)

Data availability statement

There are no restrictions about data sharing. Thus, the minimal anonymized data set necessary to replicate our study findings can be found in the following stable, public repository: London South Bank University, UK, <https://doi.org/10.18744/lbu.9457q>.

CRedit authorship contribution statement

Daniel Álvarez Sánchez-Bayuela: Writing – original draft, Investigation, Funding acquisition, Formal analysis, Data curation. **Rubén Giovanetti González:** Writing – original draft, Validation, Resources, Investigation. **Paul Martín Aguilar Angulo:** Validation, Resources, Investigation. **Lina Marcela Cruz Hernández:** Validation, Resources, Investigation. **María del Pilar Sánchez-Camacho González-Carrato:** Validation, Resources, Investigation. **Ana Rodríguez Sánchez:** Validation, Resources, Investigation. **Gianluigi Tiberi:** Writing – review & editing, Supervision, Software, Project administration, Methodology, Funding acquisition, Formal analysis, Conceptualization. **Cristina Romero Castellano:** Writing – review & editing, Validation, Supervision, Project administration, Investigation, Formal analysis, Conceptualization.

Table 5

MammoWave CDSS performance (Discrimination of NF and WF breasts) against reference standard in PPS; results considering dense breasts (ACR C and D) are also provided; volunteers' satisfaction questionnaires results.

MammoWave CDSS performance (Discrimination of NF and WF breasts) against reference standard in PPS; Results considering dense breasts (ACR C and D) are also provided.					
		Total	Dense breasts		
Sensitivity	All WF breasts	85.8% [145/169]	80.7% [71/88]		
	Benign findings	85.1% [103/121]	81.4% [57/70]		
	Malignant findings	87.5% [42/48]	77.8% [14/18]		
Specificity		39.6% [19/48]	66.7% [10/15]		
Accuracy		75.6% [164/217]	78.6% [81/103]		
Volunteers' satisfaction related to their experience using MammoWave, in general.					
	Not at all	A little	Moderately	Sufficiently	A lot
Unpleasant	169	8	2	1	0
Painful	180	0	0	0	0
Uncomfortable	117	45	11	5	2
Long-lasting	36	88	37	14	5
Reassured	0	0	1	0	179
Informed	0	0	0	0	180
Volunteers' satisfaction related to their experience using MammoWave when compared to DBT.					
	Less	Equal	More		
Unpleasant	177	3	0		
Painful	180	0	0		
Uncomfortable	162	10	8		
Long-lasting	3	35	142		

Declaration of competing interest

The authors declare the following financial interests/personal relationships which may be considered as potential competing interests: Gianluigi Tiberi reports a relationship with Umbria Bioengineering Technologies that includes: employment and equity or stocks. If there are other authors, they declare that they have no known competing financial interests or personal relationships that could have appeared to influence the work reported in this paper.

Acknowledgments

This project has received funding from the European Union's Horizon 2020 research and innovation programme under grants agreement Nr. 830265 and 101097079.

References

- [1] H. Sung, et al., Global cancer statistics 2020: GLOBOCAN estimates of incidence and mortality worldwide for 36 cancers in 185 countries, *Ca - Cancer J. Clin.* 71 (3) (May 2021) 209–249, <https://doi.org/10.3322/caac.21660>.
- [2] M. Broeders, et al., The impact of mammographic screening on breast cancer mortality in Europe: a review of observational studies, *J. Med. Screen* 19 (1_suppl) (Sep. 2012) 14–25, <https://doi.org/10.1258/jms.2012.012078>. Available: <http://journals.sagepub.com/doi/10.1258/jms.2012.012078>.
- [3] Y. Iwamoto, S. Kaucher, E. Lorenz, T. Bärnighausen, V. Winkler, Development of breast cancer mortality considering the implementation of mammography screening programs – a comparison of western European countries, *BMC Publ. Health* 19 (1) (Dec. 2019) 823, <https://doi.org/10.1186/s12889-019-7166-6>. Available: <https://bmcpublichealth.biomedcentral.com/articles/10.1186/s12889-019-7166-6>.
- [4] C. Romero Castellano, et al., Breast cancer mortality after eight years of an improved screening program using digital breast tomosynthesis, *J. Med. Screen* (Mar. 2021), 096914132110025, <https://doi.org/10.1177/09691413211002556>. Available: <http://journals.sagepub.com/doi/10.1177/09691413211002556>.
- [5] D.L. Miglioretti, et al., Radiation-induced breast cancer incidence and mortality from digital mammography screening, *Ann. Intern. Med.* 164 (4) (Feb. 2016) 205, <https://doi.org/10.7326/M15-1241>. Available: <http://annals.org/article.aspx?doi=10.7326/M15-1241>.
- [6] C. Canelo-Aybar, et al., Benefits and harms of annual, biennial, or triennial breast cancer mammography screening for women at average risk of breast cancer: a systematic review for the European Commission Initiative on Breast Cancer (ECIBC), *Br. J. Cancer* 126 (4) (2022) 673–688, <https://doi.org/10.1038/s41416-021-01521-8>. Mar.
- [7] A.L. Siu, Screening for breast cancer: U.S. Preventive Services Task force recommendation statement, *Ann. Intern. Med.* 164 (4) (2016) 279, <https://doi.org/10.7326/M15-2886>. Feb.
- [8] Breast Cancer Screening, U.S. Preventive Services Task Force Draft Recommendation Statement." Available: <https://uspreventiveservicestaskforce.org/uspstf/draft-recommendation/breast-cancer-screening-adults>. [Accessed: May 20, 2023].
- [9] H. Nehmat, H. Nehmat, Overdiagnosis of breast cancer in population screening: does it make breast screening worthless? *Cancer Biol Med* 14 (1) (2017) 1–8, <https://doi.org/10.20892/j.issn.2095-3941.2016.0050>. Available: <http://www.cancerbiomed.org/index.php/cocr/article/view/1003>.
- [10] S.S. Nazari, P. Mukherjee, An overview of mammographic density and its association with breast cancer, *Breast Cancer* 25 (3) (May 2018) 259–267, <https://doi.org/10.1007/s12282-018-0857-5>. Available: <http://link.springer.com/10.1007/s12282-018-0857-5>.
- [11] E.U. Ekpo, M. Alakhras, P. Brennan, Errors in mammography cannot be solved through technology alone, *Asian Pac. J. Cancer Prev. APJCP* 19 (2) (Feb. 2018) 291–301, <https://doi.org/10.22034/APJCP.2018.19.2.291>. Available: <http://www.ncbi.nlm.nih.gov/pubmed/29479948>.
- [12] E.H. Dibble, A.P. Lourenco, G.L. Baird, R.C. Ward, A.S. Maynard, M.B. Mainiero, Comparison of digital mammography and digital breast tomosynthesis in the detection of architectural distortion, *Eur. Radiol.* 28 (1) (Jan. 2018) 3–10, <https://doi.org/10.1007/s00330-017-4968-8>. Available: <http://link.springer.com/10.1007/s00330-017-4968-8>.
- [13] J. Lei, P. Yang, L. Zhang, Y. Wang, K. Yang, Diagnostic accuracy of digital breast tomosynthesis versus digital mammography for benign and malignant lesions in breasts: a meta-analysis, *Eur. Radiol.* 24 (3) (Mar. 2014) 595–602, <https://doi.org/10.1007/s00330-013-3012-x>. Available: <http://link.springer.com/10.1007/s00330-013-3012-x>.

- [14] P. Whelehan, A. Evans, M. Wells, S. MacGillivray, The effect of mammography pain on repeat participation in breast cancer screening: a systematic review, *Breast* 22 (4) (Aug. 2013) 389–394, <https://doi.org/10.1016/j.breast.2013.03.003>. Available: <https://linkinghub.elsevier.com/retrieve/pii/S096097761300057X>.
- [15] N. Nikolova, Microwave imaging for breast cancer, *IEEE Microw. Mag.* 12 (7) (Dec. 2011) 78–94, <https://doi.org/10.1109/MMM.2011.942702>. Available: <http://ieeexplore.ieee.org/document/6031961/>.
- [16] W.T. Joines, Y. Zhang, C. Li, R.L. Jirtle, The measured electrical properties of normal and malignant human tissues from 50 to 900 MHz, *Med. Phys.* 21 (4) (Apr. 1994) 547–550, <https://doi.org/10.1118/1.597312>. Available: <https://doi.org/10.1118/1.597312>.
- [17] L. Sha, E.R. Ward, B. Stroy, A review of dielectric properties of normal and malignant breast tissue,” in Proceedings IEEE SoutheastCon (2002) 457–462, <https://doi.org/10.1109/SECON.2002.995639>, 2002 (Cat. No. 02CH37283), IEEE, <http://ieeexplore.ieee.org/lpdocs/epic03/wrapper.htm?arnumber=995639>.
- [18] M. Lazebnik, et al., A large-scale study of the ultrawideband microwave dielectric properties of normal, benign and malignant breast tissues obtained from cancer surgeries, *Phys. Med. Biol.* 52 (20) (Oct. 2007) 6093–6115, <https://doi.org/10.1088/0031-9155/52/20/002>.
- [19] E. Canicatti, et al., Dielectric characterization of small breast biopsy via miniaturized open-ended coaxial probe, IEEE International Symposium on Antennas and Propagation and USNC-URSI Radio Science Meeting (AP-S/URSI), IEEE (2022) 1332–1333, <https://doi.org/10.1109/AP-S/USNC-URSI47032.2022.9886564>. Jul. 2022.
- [20] D. O’Loughlin, M. O’Halloran, B.M. Moloney, M. Glavin, E. Jones, M.A. Elahi, Microwave breast imaging: clinical advances and remaining challenges, *IEEE Trans. Biomed. Eng.* 65 (11) (Nov. 2018) 2580–2590, <https://doi.org/10.1109/TBME.2018.2809541>.
- [21] M.A. Aldhaebee, K. Alzoubi, T.S. Almonneef, S.M. Bamatraf, H. Attia, O.M. Ramahi, Review of microwaves techniques for breast cancer detection, *Sensors* 20 (8) (Apr. 2020) 2390, <https://doi.org/10.3390/s20082390>. Available: <https://www.mdpi.com/1424-8220/20/8/2390>.
- [22] M. Shere, I. Lyburn, R. Sidebottom, H. Massey, C. Gillett, L. Jones, M.5 Maria®, A multicentre clinical study to evaluate the ability of the Micrima radio-wave radar breast imaging system (MARIA®) to detect lesions in the symptomatic breast,” *Eur J Radiol* 116 (Jul. 2019) 61–67, <https://doi.org/10.1016/j.ejrad.2019.04.017>. Available: <https://linkinghub.elsevier.com/retrieve/pii/S0720048X19301512>.
- [23] A. Vispa, et al., UWB device for breast microwave imaging: phantom and clinical validations, *Measurement* 146 (Nov. 2019) 582–589, <https://doi.org/10.1016/j.measurement.2019.05.109>. Available: <https://linkinghub.elsevier.com/retrieve/pii/S0263224119306116>.
- [24] L. Sani, et al., MammoWave breast imaging device: a procedure for device’s characterization via phantom measurements and subsequent clinical trials’ preliminary results, in: IEEE Conference on Antenna Measurements & Applications (CAMA), IEEE, Nov. 2021, 2021, pp. 483–486, <https://doi.org/10.1109/CAMA49227.2021.9703532>.
- [25] Cutting edge microwave imaging device for safe and accurate breast cancer screening.”doi: <https://doi.org/10.3030/830265>. Available: <https://cordis.europa.eu/project/id/830265>. [Accessed: Jun. 09, 2023].
- [26] N. Ghavami, et al., MammoWave Breast Imaging Device: An International and Multicentric Clinical Investigation,” in 2023 17th European Conference on Antennas and Propagation (EuCAP), IEEE, Mar. (2023) 1–5, <https://doi.org/10.23919/EuCAP57121.2023.10133493>.
- [27] D. Álvarez Sánchez-Bayuela, et al., A multicentric, single arm, prospective, stratified clinical investigation to evaluate MammoWave’s ability in breast lesions detection, *PLoS One* 18 (7) (Jul. 2023), e0288312, <https://doi.org/10.1371/journal.pone.0288312>.
- [28] L. Sani, et al., Breast lesion detection through MammoWave device: empirical detection capability assessment of microwave images’ parameters, *PLoS One* 16 (4) (Apr. 2021), e0250005, <https://doi.org/10.1371/journal.pone.0250005>. Available: <https://dx.plos.org/10.1371/journal.pone.0250005>.
- [29] Servicio de Salud de Castilla - La Mancha, Best Practice, NCD Prevention, Optimized Population-Based Screening and Diagnostic Pathway for Breast Cancer Detection, 2021.
- [30] C. D’Orsi, E. Sickles, E. Mendelson, E. Morris, ACR BI-RADS® Atlas, Breast Imaging Reporting and Data System, American College of Radiology, Reston, VA, 2013.
- [31] D. Álvarez Sánchez-Bayuela, et al., Detection capabilities of the Microwave Breast Imaging system MammoWave on different malignant lesions, *EPOS™* (2023), <https://doi.org/10.26044/ecr2023/C-13089>.
- [32] H.D. Nelson, M. Pappas, A. Cantor, J. Griffin, M. Daeges, L. Humphrey, Harms of breast cancer screening: systematic review to update the 2009 U.S. Preventive Services Task force recommendation, *Ann. Intern. Med.* 164 (4) (2016) 256, <https://doi.org/10.7326/M15-0970>. Feb.
- [33] J.L. Raya-Povedano, S. Romero-Martín, E. Elías-Cabot, A. Gubern-Mérida, A. Rodríguez-Ruiz, M. Álvarez-Benito, AI-based strategies to reduce workload in breast cancer screening with mammography and tomosynthesis: a retrospective evaluation, *Radiology* 300 (1) (2021) 57–65, <https://doi.org/10.1148/radiol.2021203555>. Jul.
- [34] S.L. van Winkel, et al., Impact of artificial intelligence support on accuracy and reading time in breast tomosynthesis image interpretation: a multi-reader multi-case study, *Eur. Radiol.* 31 (11) (Nov. 2021) 8682–8691, <https://doi.org/10.1007/s00330-021-07992-w>.
- [35] L. Kerschke, S. Weigel, A. Rodríguez-Ruiz, N. Karssemeijer, W. Heindel, Using deep learning to assist readers during the arbitration process: a lesion-based retrospective evaluation of breast cancer screening performance, *Eur. Radiol.* 32 (2) (Feb. 2022) 842–852, <https://doi.org/10.1007/s00330-021-08217-w>.
- [36] M. Larsen, et al., Artificial intelligence evaluation of 122 969 mammography examinations from a population-based screening program, *Radiology* 303 (3) (Jun. 2022) 502–511, <https://doi.org/10.1148/radiol.212381>.
- [37] A.D. Lauritzen, et al., An artificial intelligence-based mammography screening protocol for breast cancer: outcome and radiologist workload, *Radiology* 304 (1) (2022) 41–49, <https://doi.org/10.1148/radiol.210948>. Jul.
- [38] B.M. Moloney, et al., Microwave imaging in breast cancer – results from the first-in-human clinical investigation of the wavelia system, *Acad. Radiol.* 29 (Jan. 2022) S211–S222, <https://doi.org/10.1016/j.acra.2021.06.012>.
- [39] D. Álvarez Sánchez-Bayuela, et al., A multicentric, single arm, prospective, stratified clinical investigation to confirm MammoWave’s ability in breast lesions detection, *Diagnostics* 13 (12) (Jun. 2023), <https://doi.org/10.3390/diagnostics13122100>, 2100.
- [40] B. Khalid, et al., 3D Huygens principle based microwave imaging through MammoWave device: validation through phantoms, *IEEE Access* 10 (2022) 106770–106780, <https://doi.org/10.1109/ACCESS.2022.3211957>.
- [41] E. Canicatti, N. Ghavami, G. Tiberi, A. Monorchio, Accuracy Improvement of the Huygens’ Principle-based Method for UWB Microwave Imaging,” in 2023 17th European Conference on Antennas and Propagation (EuCAP), IEEE, Mar. (2023) 1–5, <https://doi.org/10.23919/EuCAP57121.2023.10133293>.
- [42] L. Papini, et al., Breast Cancer Detection using Machine Learning Approaches on Microwave-based Data,” in 2023 17th European Conference on Antennas and Propagation (EuCAP), IEEE, Mar. (2023) 1–5, <https://doi.org/10.23919/EuCAP57121.2023.10133340>.